SOCIETAS · CHIRURGICA · AMERICANA
INSTIT · A · D · MDCCCLXXX

Second Copy

SHL
WITHDRAWN

TRANSACTIONS

ROYAL SOCIETY OF MEDICINE
16 JAN 1922

OF THE

AMERICAN SURGICAL ASSOCIATION

VOLUME THE THIRTY-EIGHTH

EDITED BY

JOHN H. JOPSON, M.D.

RECORDER OF THE ASSOCIATION

PRINTED FOR THE ASSOCIATION

FOR SALE BY

WILLIAM J. DORNAN, PHILADELPHIA

1920

Copyright, 1920, by John H. Jopson, M.D. Recorder of the Association

DORNAN, PRINTER
PHILADELPHIA, PA.

ROYAL SOCIETY OF MEDICINE
16 JAN 1922

CONTENTS

Officers of the Association vi
List of Presidents of the Association viii
Fellows of the Association xi
Senior Fellows xxxiii
Honorary Fellows xxxv
Deceased Fellows xxxvii
Report of the Committee on Necrology:
Francis T. Stewart, M.D. xliii
Kenneth Alexander James Mackenzie, M.D. xliv
Charles Knox Cole, M.D. xlv

Presidential Address. Including Record of Service during the World War of Members of the American Surgical Association. By George Emerson Brewer, M.D. 1
Treatment of Chronic Empyema. By Th. Tuffier 36
Observations on Empyema. By Astley P. C. Ashhurst, M.D. . 63
Operation for Empyema in Young Adults. By Frank E. Bunts, M.D. 156
The Etiology of Chronic Empyema. By Walton Martin, M.D. . 162
The Morelli Method of Aspiration Drainage for Acute Empyema. By Lincoln Davis, M.D. 189
Empyema: A Syllabus of Operative Treatment. By Howard Lilienthal, M.D. 199
Observations on the Treatment of Chronic Empyema. By George J. Heuer 204
Restoration of Function of Facial Nerve Five Years after Anastomosis with Hypoglossal. Spontaneous Rupture of the Deep Epigastric Artery. By Herbert A. Bruce, M.D. 228
Amputation Neuromas: Their Development and Prevention. By G. Carl Huber, M.D., and Dean Lewis, M.D. 231
The Radical Treatment of Roentgen-ray Burns. By John Staige Davis, M.D. 272
An Operation for Cure of Large Ventral Hernia. By Charles L. Gibson, M.D. 278
Traumatic Fat Necrosis of the Female Breast and Its Differentiation from Carcinoma: with a Report of Two Cases. By Burton J. Lee, M.D., and Frank E. Adair, M.D. 294

The Requirements of Technic in Operations for Cancer of the Breast. By JABEZ N. JACKSON, M.D. 314
Diverticula of the Esophagus. By ARTHUR DEAN BEVAN, M.D. . 334
The Calloused Ulcer of the Posterior Wall of the Stomach. By W. J. MAYO, M.D. 348
Hyperplastic Tuberculosis of the Small Intestine. By JOSEPH RANSOHOFF, M.D. 360
Failure of Primary Rotation of the Intestine (Left-sided Colon) in Relation to Intestinal Obstruction. By EMMET RIXFORD, M.D. . 368
Acute Intestinal Obstruction: The Cause of the Continued High Mortality and How It May Be Reduced. By JOHN E. SUMMERS, M.D. 377
Mesenteric Thrombosis: With a Report of Six Cases. By GEORGE G. ROSS, M.D. 385
Causes of Death after Operation for Acute Appendicitis. By ARCHIBALD MACLAREN, M.D. 405
The Relationship Between Ranula and Branchiogenetic Cysts. By JAMES E. THOMPSON, M.D. 417
Cancer of the Ovary, with Invasion of the Sigmoid Flexure. By P. E. TRUESDALE, M.D. 435
Blood Transfusion in Association with Other Surgical Procedures in the Treatment of Pernicious Anemia: with Report of Cases. By NELSON MORTIMER PERCY, M.D. 451
Fatal Postoperative Pulmonary Thrombosis. By A. J. OCHSNER, M.D. and CHESTER C. SCHNEIDER, M.D. 464
Etiology, Pathology and Clinical Features of Benign Exostoses. By ELLSWORTH ELIOT, M.D. 500
Sarcoma of the Clavicle—End-results Following Total Excision. By WILLIAM B. COLEY, M.D. 506
Reduction of Old Dislocations of the Hip by Open Incision. By J. J. BUCHANAN, M.D. 547
Adventitious Ligaments Simulating Cervical Ribs. By ARTHUR AYER LAW, M.D. 566
The Recognition of Dead Bone, Based on Pathological and *X*-ray Studies. By DALLAS B. PHEMISTER, M.D. 574
Notes on Charcot Joints. By FREDERICK J. COTTON 601
Diaphragmatic Hernia. By FRANK S. MATHEWS, M.D., and H. M. IMBODEN, M.D. 614
One Year's (1919) Work in Hysterectomy in the Lankenau (formerly the German) Hospital, Philadelphia—Including the Writer's Experience with Radium in Uterine Conditions during the Year. By JOHN B. DEAVER, M.D. With Remarks upon Pathology. By STANLEY P. REIMANN, M.D. 626

Special Consideration of Toxic Adenoma in Relation to Exophthalmic Goiter. By George W. Crile, M.D. 637
A "Tourniquet Operation" in Toxic and Other Goiters. By Leonard Freeman, M.D. 642
Adenoma with Hyperthyroidism. By C. H. Mayo, M.D. 648
Toxic Goiter. By Wallace I. Terry, M.D. 658
Results of Operations for Adenoma with Hyperthyroidism and Exophthalmic Goiter. By E. S. Judd, M.D. 662
Goiter: A Clinical Study of 139 Cases. By Miles F. Porter, M.D. 671
Original Contributions of America to Medical Sciences—A Supplementary Note. By Edmond Souchon, M.D. 690
Indications for Active Immediate Mobilization in the Treatment of Joint Injuries. By Colonel Ch. Willems 694
Technical Problems in the Operation for Disconnecting Gastro-enterostomy Stomas. By E. Wyllys Andrews, M.D. 698

OFFICERS OF THE ASSOCIATION

ELECTED MAY, 1920

PRESIDENT

JOHN B. ROBERTS, M.D.

VICE-PRESIDENTS

HARVEY G. MUDD, M.D.

JAMES F. MITCHELL, M.D.

SECRETARY

JOHN H. GIBBON, M.D.,
1608 Spruce St., Philadelphia.

TREASURER

CHARLES H. PECK, M.D.,
30 West Fiftieth St., New York City.

RECORDER

JOHN H. JOPSON, M.D.,
1824 Pine Street, Philadelphia, Pa.

COUNCIL

THOMAS W. HUNTINGTON, M.D.

LEWIS S. PILCHER, M.D.

GEORGE E. BREWER, M.D.

JOHN B. ROBERTS, M.D.
JOHN H. GIBBON, M.D.
CHARLES H. PECK, M.D.
JOHN H. JOPSON, M.D.
} *Ex-officio.*

PUBLICATION COMMITTEE

RECORDER, SECRETARY AND TREASURER, *ex-officio.*

COMMITTEE ON ANNUAL MEETING

JOHN M. T. FINNEY, M.D. WILLIAM M. ESTES, M.D.
PRESIDENT, SECRETARY, RECORDER AND THE CHAIRMAN OF THE ADJUNCT LOCAL COMMITTEE OF ARRANGEMENTS, *ex-officio.*

COMMITTEE ON ARCHIVES

(Report by Title.)

JOHN B. ROBERTS, M.D., *Chairman*
ARPAD G. GERSTER, M.D.
CHARLES N. DOWD, M.D.

Place of next meeting:

TORONTO, CANADA

ADJUNCT LOCAL COMMITTEE OF ARRANGEMENTS

ALEXANDER PRIMROSE, M.B.
F. N. G. STARR, M.D.
HERBERT A. BRUCE, M.D.

LIST OF THE PRESIDENTS

OF THE

ASSOCIATION FROM THE TIME OF ITS INSTITUTION

ELECTED

1880. ‡SAMUEL DAVID GROSS, M.D., LL.D., D.C.L (Oxon.), LL.D. (Cantab.), LL.D. (Edin.)—Founder of the Association.
1883. ‡EDWARD MOTT MOORE, M.D., LL.D.
1884. ‡WILLIAM THOMPSON BRIGGS, M.D.
1885. ‡MOSES GUNN, A.M., M.D., LL.D.
1886. ‡HUNTER McGUIRE, M.D., LL.D.
1887. ‡D. HAYES AGNEW, M.D., LL.D.
1888. ‡DAVID WILLIAMS CHEEVER, M.D., LL.D.
1889. ‡DAVID W. YANDELL, M.D.
1890. ‡CLAUDIUS HENRY MASTIN, M.D., LL.D.
1891. ‡PHINEAS SANBORN CONNER, M.D., LL.D.
1892. ‡NICHOLAS SENN, M.D., Ph.D., LL.D.
1893. ‡JAMES EWING MEARS, A.M., M.D., LL.D.
1894. FREDERIC SHEPARD DENNIS, M.D.
1895. ‡LOUIS McLANE TIFFANY, A.M. (Cantab.), M.D.
1896. JOHN COLLINS WARREN, M.D., LL.D. (Jefferson) Hon. F.R.C.S. (Eng.).
1897. ‡THEODORE F. PREWITT, M.D.
1898. WILLIAM W. KEEN, A.M., M.D., LL.D., Hon. F.R.C.S. (Eng. and Edin.).
1899. ROBERT F. WEIR, A.M., M.D., Hon. F.R.C.S. (Eng.).
1900. ‡ROSWELL PARK, M.D.
1901. ‡DE FOREST WILLARD, A.M., M.D., Ph.D.
1902. ‡MAURICE H. RICHARDSON, A.B., M.D.
1903. ‡NATHANIEL P. DANDRIDGE, M.D.
1904. ‡GEORGE BEN JOHNSTON, M.D.
1905. ALBERT VANDER VEER, M.D.
1906. ‡DUDLEY P. ALLEN, M.D., LL.D.
1907. WILLIAM H. CARMALT, M.D.
1908. C. B. G. de NANCRÈDE, A.M., M.D., LL.D.

‡ Deceased.

ELECTED

1909. RUDOLPH MATAS, M.D.
1910. RICHARD H. HARTE, M.D.
1911. ARPAD G. GERSTER, M.D., CHIR.D.
1912. CHARLES A. POWERS, A.M., M.D.
1913. WILLIAM J. MAYO, A.M., M.D., D.SC., F.R.C.S. (EDIN.), LL.D. (TOR.).
1914. GEORGE E. ARMSTRONG, C.M., M.D.
1915. ROBERT G. LE CONTE, A.B., M.D.
1916. SAMUEL J. MIXTER, S.B., M.D.
1917. THOMAS W. HUNTINGTON, A.B., M.D., LL.D.
1918. LEWIS S. PILCHER, A.M., M.D., LL.D.
1919. GEORGE E. BREWER, M.D.
1920. JOHN B. ROBERTS, M.D.

NOTICE

This volume of TRANSACTIONS contains the papers read before the Association at the Meeting held May 3, 4 and 5, 1920.

The Association assumes no responsibility for the statements and opinions published in this volume.

FELLOWS

OF THE

AMERICAN SURGICAL ASSOCIATION

MAY, 1920

* Denotes Original Fellows.
† Denotes Senior Fellows.
‡ Denotes Deceased Fellows.

ELECTED

†1890. ABBE, ROBERT, M.D., 13 West Fiftieth Street, New York. Senior Surgeon to St. Luke's Hospital. *Vice-President*, 1901. *Council*, 1908.

†1890. ALLIS, OSCAR HUNTINGTON, A.M., M.D., 1604 Spruce Street, Philadelphia. Surgeon to the Presbyterian Hospital.

1902. ANDREWS, E. WYLLYS, A.M., M.D., 122 S. Michigan Avenue, Chicago, Ill. Professor of Surgery, Northwestern University Medical School; Surgeon to St. Luke's Hospital and Michael Reese Hospital; Surgeon-in-Chief to Cook County Hospital; Consulting Surgeon to the Provident Hospital.

1916. ARCHIBALD, EDWARD WILLIAM, B.A., M.D., C.M., 160 Metcalfe Street, Montreal, Canada. Lecturer in Clinical Surgery, McGill University; Assistant Surgeon, Royal Victoria Hospital; Associate Surgeon, Children's Memorial Hospital.

1901. ARMSTRONG, GEORGE E., M.D., C.M., C.M.G., LL.D. (Queens), D.Sc. (Liverpool), 320 Mountain Street, Montreal. Professor of Surgery and of Clinical Surgery, McGill University; Chief Surgeon to the Royal Victoria Hospital, Consulting Surgeon to the Montreal General Hospital, the Western Hospital and to the Protestant Hospital for the Insane, Verdun; Colonel, C.A.M.C. *President*, 1914.

ELECTED

1913. ASHHURST, ASTLEY PASTON COOPER, A.B., M.D., 1629 Spruce Street, Philadelphia. Instructor in Surgery in the University of Pennsylvania; Surgeon to the Episcopal Hospital; Surgeon to the Philadelphia Orthopædic Hospital and Infirmary for Nervous Diseases; Colonel, Medical Reserve Corps, U. S. Army.

1920. BALCH, FRANKLIN G., A.M., M.D., F.A.C.S., 279 Clarendon Street, Boston, Mass. Chief of East Surgical Service, Massachusetts General Hospital; Surgeon at the Faulkner Hospital; Associate in Surgery, Graduate Courses in Medicine, Harvard Medical School.

1917. BALFOUR, DONALD CHURCH, M.B., M.D., Rochester, Minn. Associate Professor of Surgery, University of Minnesota; Surgeon to St. Mary's Hospital, Rochester.

1906. BARROW, DAVID, M.D., 148 Market Street, Lexington, Ky. Surgeon to St. Joseph and Good Samaritan Hospitals; recently, Lieut.-Col., M.C.; Commanding Officer, Base Hospital 40.

†1882. BARTON, JAMES M., A.M., M.D., 32 North New Hampshire Ave., Atlantic City, N. J.

1915. BESLEY, FREDERIC A., M.D., F.A.C.S., 104 South Michigan Avenue, Chicago, Ill. Professor of Surgery, Northwestern University Medical School; Attending Surgeon to the Mercy and Cook County Hospitals.

1900. BEVAN, ARTHUR DEAN, M.D., 122 S. Michigan Boulevard, Chicago. Professor and Head of the Department of Surgery, Rush Medical College, University of Chicago; Surgeon to Presbyterian Hospital.

1901. BINNIE, J. F., M.A., M.B., C.M. (Aberdeen), 917 Rialto Bldg., Kansas City, Mo. *Vice-President*, 1907 and 1919.

1918. BLAIR, VILRAY PAPIN, M.D., 4654 Pershing Ave., St. Louis, Mo. Professor of Oral Surgery, Washington University Dental School; Associate in Surgery, Washington University Medical School; Visiting Surgeon, St. Luke's Hospital; Assistant Surgeon in St. Louis Children's Hospital and Barnes Hospital.

1906. BLAKE, JOHN BAPST, A.M., M.D., 657 Boylston Street, Boston, Mass. Assistant Professor in Surgery, Harvard Medical School; Surgeon-in-Chief to the Boston City Hospital; Consulting Surgeon to Long Island Hospital; Consulting Surgeon to Boston Insane Hospital; Consulting Surgeon to the Reformatory for Women, Framingham, Mass.

ELECTED

1902. Blake, Joseph A., M.D., 116 East 53rd Street, New York, N. Y.

1901. Bloodgood, Joseph Colt, B.S. (Wisc., 1888), M.D. (Penna., 1891); office, 904 N. Charles St., Baltimore, Md.; residence, 18 Midvale Road, Roland Park, Md. Associate Professor of Clinical Surgery, Johns Hopkins University; Surgeon to St. Agnes's Hospital, Baltimore.

1901. Bosher, Lewis C., M.D., 422 East Franklin Street, Richmond, Va. Emeritus Professor of Genito-urinary Surgery and Practice of Surgery, Medical College of Virginia; Visiting Surgeon, Stuart Circle Hospital and Memorial Hospital.

1913. Bottomley, John T., A.B., LL.D., M.D., 165 Beacon Street, Boston. Surgeon-in-Chief, Carney Hospital.

†1890. Bradford, Edward Hickling, A.B., M.D., 133 Newbury Street, Boston. Surgeon to the Children's and the Samaritan Hospitals; Assistant Professor of Orthopedic Surgery, Harvard University.

1900. Brewer, George Emerson, M.D., 16 East Sixty-fourth Street, New York City. Emeritus Professor of Surgery in College of Physicians and Surgeons, Columbia University; Consulting Surgeon to the Presbyterian Hospital, Roosevelt, City, Woman's, St. Vincent's, Manhattan Eye, Ear, Nose and Throat Hospitals, and to the Ophthalmic and Aural Institute, New York; to the Muhlenberg Hospital of Plainfield, N. J., the Flushing and Perth Amboy Hospitals. *Vice-President*, 1913. *President*, 1919.

1917. Brewster, George W. W., A.B., M.D., F.A.C.S., 213 Beacon Street, Boston, Mass. Associate in Surgery, Harvard Graduate School; Visiting Surgeon, Massachusetts General Hospital; Consulting Surgeon to Frost Hospital, Chelsea, Mass.; Leonard Morse Hospital, Natick, Mass.; Milford Hospital, Milford, Mass.

1915. Brinsmade, W. B., A.B., M.D., 172 Clinton St., Brooklyn, N. Y. Consulting Surgeon to St. Christopher's Hospital; Senior Surgeon, Brooklyn Hospital; Commander, U.S.N.R.F., M.C.

1911. Bruce, Herbert A., M.D. (Toronto Univ.), L.R.C.P. (London), F.R.C.S. (England), 64 Bloor Street East, Toronto, Canada. Associate Professor of Clinical Surgery, University of Toronto; Surgeon to the Toronto General Hospital; Colonel, Canadian Army Medical Corps and

ELECTED

Royal Army Medical Corps; Late Consulting Surgeon to the British Armies in France.

1911. BUCHANAN, J. J., A.M., M.D., Ph.D., 1409 N. Highland Avenue, Pittsburgh, Pa. Emeritus Professor of Surgery, University of Pittsburgh; Surgeon to Mercy Hospital.

1900. BUNTS, FRANK E., M.D., Euclid Avenue and 93rd Street, Cleveland, Ohio. Professor of Principles of Surgery and Clinical Surgery in Medical College of Western Reserve University; Visiting Surgeon and Chief of Staff to St. Vincent's Charity Hospital.

†1885. CARMALT, WILLIAM H., A.M., M.D., 261 St. Ronan Street, New Haven, Conn. Emeritus Professor of Surgery in Yale University; President and Consulting Surgeon to the New Haven Hospital. *President*, 1907; *Vice-President*, 1895; *Member of Council*, 1908.

1909. CARREL, ALEXIS, L.B., Sc.B., M.D., Rockefeller Institute for Medical Research, Sixty-sixth Street and Avenue A, New York, N. Y.

1896. CARSON, NORMAN BRUCE, M.D., 303 Humboldt Bldg., St. Louis, Mo. Surgeon to St. Louis, Mullanphy Hospital and to the St. Vincent Insane Asylum, etc. *Vice-President*, 1903.

1920. CLINTON, MARSHALL, M.D., 556 Franklin Street, Buffalo, New York. Associate Professor of Surgery, University of Buffalo, Department of Medicine; Professor of Oral Surgery, University of Buffalo, Dental Department; Attending Surgeon, Buffalo General, Erie County, and Buffalo City Hospitals.

1910. CLOPTON, MALVERN BRYAN, M.D., 405 Humboldt Building, St. Louis, Mo. Associate in Surgery, Washington University Medical School; Visiting Surgeon, St. Luke's Hospital; Assistant Surgeon, Barnes Hospital; Associate Surgeon, St. Louis Children's Hospital.

1916. CODMAN, ERNEST AMORY, A.B., M.D., 227 Beacon St., Boston, Mass.

1898. COLEY, WILLIAM B., M.D., 6 West Fiftieth Street, New York. Attending Surgeon to the Memorial Hospital; Associate Surgeon to the Hospital for Ruptured and Crippled, New York.

ELECTED

1914. COTTON, FREDERICK J., A.B., M.D., A.M., 520 Commonwealth Avenue, Boston, Mass. Visiting Surgeon to the Boston City Hospital; Associate in Surgery, Harvard School for Graduate Instruction in Medicine; Consultant in Surgery, United States Public Health Service, Northeastern District; also Consultant in Surgery, New England Hospital for Women and Children.

1905. CRILE, GEORGE W., M.D., Euclid Avenue and 93rd Street, Cleveland, Ohio. Professor of Surgery, School of Medicine, Western Reserve University; Visiting Surgeon to Lakeside Hospital.

1906. CUSHING, HARVEY, A.M., M.D., ScD., LL.D., F.R.C.S., The Peter Bent Brigham Hospital, Boston. Professor of Surgery, Harvard University.

†1896. CUSHING, HAYWARD WARREN, A.B., M.D., 70 Commonwealth Avenue, Boston, Mass. Consulting Surgeon, Boston City Hospital.

1897. DA COSTA, JOHN CHALMERS, M.D., 2045 Walnut Street, Philadelphia. Samuel D. Gross Professor of Surgery, Jefferson Medical College; Surgeon to the Hospital of the Jefferson Medical College; Consulting Surgeon to the Philadelphia General Hospital, Saint Joseph's Hospital and Misericordia Hospital.

1917. DARRACH, WILLIAM, A.B., M.A., M.D., 19 East 65th Street, New York City. Associate Professor of Surgery and Dean of the Medical Faculty, College of Physicians and Surgeons, Columbia University; Consulting Surgeon, Memorial Hospital, Morristown, N. J.

1916. DAVIS, CARL B., A.B., M.D., 122 South Michigan Boulevard, Chicago, Ill. Assistant Professor of Surgery, Rush Medical College; Associate Surgeon, Presbyterian Hospital, Chicago.

1917. DAVIS, JOHN STAIGE, Ph.B., M.D., F.A.C.S., 1200 Cathedral Street, Baltimore, Md. Instructor in Clinical Surgery, Johns Hopkins University; Visiting and Plastic Surgeon, Union Protestant Infirmary, Hospital for the Women of Maryland, Children's Hospital School; Assistant Visiting Surgeon and Dispensary Surgeon, Johns Hopkins Hospital.

1919. DAVIS, LINCOLN, A.B., M.D., 217 Beacon St., Boston, Mass. Associate in Surgery, Harvard Graduate School of Medicine; Visiting Surgeon, Massachusetts General Hospital; Consulting Surgeon, Massachusetts Charitable Eye and Ear

ELECTED

Infirmary, Heywood Memorial Hospital, Gardner, Milford Hospital, Milford.

1912. DEAVER, HARRY C., M.D., 1701 Spruce Street, Philadelphia. Professor of Surgery, Woman's Medical College of Pennsylvania; Surgeon-in-Chief to Kensington Hospital for Women; Surgeon to the Episcopal Hospital and to the Children's Hospital of the Mary Drexel Home.

1892. DEAVER, JOHN B., M.D., Sc.D., LL.D., 1634 Walnut Street, Philadelphia. John Rhea Barton Professor of Surgery, University of Pennsylvania, Philadelphia; Surgeon-in-Chief to the Lankenau Hospital, Philadelphia.

1910. DELATOUR, H. BEECKMAN, M.D., 73 Eighth Avenue, Brooklyn, N. Y. Attending Surgeon, St. John's and Norwegian Hospitals; Consulting Surgeon, Kingston Avenue Hospital, Brooklyn, St. Mary's Hospital, Jamaica, and Northport Hospital.

†1882. DENNIS, FREDERIC SHEPARD, M.D., F.R.C.S. (Eng.), 62 East Fifty-fifth Street, New York. Professor Emeritus of Clinical Surgery, Cornell University, New York City; Consulting Surgeon to the Bellevue and Attending Surgeon to St. Vincent's Hospitals; Consulting Surgeon to St. Joseph's Hospital, Yonkers, and Montefiore Home, New York City, Litchfield County Hospital, Winsted, Conn. *President*, 1894; *Vice-President*, 1887; *Member of Council*, 1889.

1910. DOWD, CHARLES N., A.M., M.D., 127 West Seventy-second Street, New York, N. Y. Professor of Clinical Surgery, Columbia University; Attending Surgeon, Roosevelt Hospital; Consulting Surgeon, Memorial Hospital and St. Mary's Free Hospital for Children, New York.

1914. DOWNES, WILLIAM A., M.D., 424 Park Avenue, New York, N. Y. Assistant Professor of Clinical Surgery, Columbia University, College of Physicians and Surgeons; Attending Surgeon, St. Luke's, Memorial and Babies' Hospitals; Consulting Surgeon, Manhattan State Hospital, Hospital for Ruptured and Crippled, Infirmary for Women and Children, New York, United Hospital, Port Chester, N. Y.

1919. EASTMAN, JOSEPH RILUS, A.M., B.Sc., M.D., F.A.C.S., 331 N. Delaware St., Indianapolis, Ind. Professor of Surgery, Indiana University School of Medicine; Visiting Surgeon to City Hospital.

ELECTED

1901. ELIOT, ELLSWORTH, JR., M.D., 34 East Sixty-seventh Street, New York. Surgeon to tbe Presbyterian Hospital.

†1893. ELLIOT, JOHN WHEELOCK, A.M., M.D. (Harvard), 124 Beacon Street, Boston. Surgeon to Massachusetts General Hospital, 1893–1907; Clinical Instructor in Gynecology, 1888–9, and Lecturer on Surgery, 1900–5, Harvard Medical School; Chairman, N. E. Surgical Dressings Committee, 1917.

1911. ELTING, ARTHUR W., A.B., M.D., LL.D., 119 Washington Avenue, Albany, N. Y. Professor of Surgery in the Albany Medical College; Surgeon to the Albany Hospital, and Surgeon to the Child's Hospital, Albany, N. Y.

†1896. ESTES, WILLIAM LAWRENCE, A.M., M.D., South Bethlehem, Pa. Director and Surgeon-in-Chief of St. Luke's Hospital, Lecturer on Hygiene at Lehigh University.

1898. EVE, DUNCAN, A.M., M.D., Eve Building, Nashville, Tenn. Professor of Surgery and Clinical Surgery, Medical Department, Vanderbilt University; Chief Surgeon of the N. C. & St. Louis Railway; Consulting Surgeon to Nashville City, St. Thomas and Woman's Hospitals.

1899. FINNEY, JOHN M. T., M.D., 1300 Eutaw Place, Baltimore, Md. Associate Professor of Surgery, Johns Hopkins University.

1915. FLINT, JOSEPH MARSHALL, B.S., M.A., M.D., 320 Temple Street, New Haven, Conn. Professor of Surgery at Yale University.

1904. FRAZIER, CHARLES HARRISON, M.D., 1724 Spruce Street, Philadelphia, Pa. Professor of Clinical Surgery, University of Pennsylvania; Surgeon to the University Hospital.

1898. FREEMAN, LEONARD, B.S., M.D., 424 Metropolitan Building, Denver, Col. Professor of Surgery, Medical Department, University of Colorado; Surgeon to Denver City and County, St. Joseph's, and National Jewish Hospitals; Consulting Surgeon, Children's and Mercy Hospitals, Denver, Col. *Vice-President*, 1908.

1910. GAGE, HOMER, A.M., M.D., 72 Pearl Street, Worcester, Mass. Surgeon-in-Chief to Memorial Hospital; Consulting Surgeon to Worcester City and St. Vincent's Hospitals.

1919. GAUB, OTTO CARL, M.D., F.A.C.S. Hotel Schenley, Pittsburgh, Pa. Surgeon to Allegheny General Hospital and to Columbia Hospital.

†1882. GAY, GEORGE WASHINGTON, A.M., M.D., 665 Boylston Street, Boston, Mass. Senior Surgeon to the Boston City Hospital. *Member of Council*, 1882.

ELECTED

‡1892. GERRISH, FREDERIC HENRY, A.M., M.D. (Bowdoin), LL.D. (University of Michigan and Bowdoin), 675 Congress Street, Portland, Maine. Professor Emeritus of Surgery in the Bowdoin Medical School; Consulting Surgeon to the Maine General Hospital.

†1890. GERSTER, ARPAD G., M.D., Chir.D., 34 East Seventy-fifth Street, New York. Emeritus Professor of Surgery in the New York Polyclinic, former Professor of Clinical Surgery, Columbia University; Consulting Surgeon to Lenox Hill and Mount Sinai Hospitals.

1906. GIBBON, JOHN H., M.D., *Secretary*, 1608 Spruce Street, Philadelphia. Professor of Surgery, Jefferson Medical College and Surgeon to the Jefferson College Hospital; Surgeon to the Pennsylvania Hospital and Consulting Surgeon to the Bryn Mawr Hospital.

1906. GIBSON, C. L., M.D., 72 East Fifty-fourth Street, New York, N. Y. Professor of Surgery, Cornell University Medical College; Attending Surgeon to the First Surgical (Cornell Medical) Division of the New York Hospital; Consulting Surgeon to St. Luke's, City, and General Memorial Hospitals. *Vice-President*, 1915.

1920. GRAHAM, EVARTS A., A.B., MD., Euclid Avenue and Kingshighway, St. Louis, Mo. Professor of Surgery, Washington University Medical School, St. Louis, Missouri; Surgeon-in-Chief to Barnes Hospital and St. Louis Children's Hospital; Consulting Surgeon, City Hospital No. 20.

1911. GREENOUGH, ROBERT B., A.B. (Harvard), M.D. (Harvard), 8 Marlborough Street, Boston, Mass. Assistant Professor of Surgery, Harvard Medical School; Visiting Surgeon, Massachusetts General Hospital.

1916. HAGGARD, WILLIAM D., M.D., F.A.C.S., 706 Church Street, Nashville, Tenn. Professor of Surgery, Vanderbilt University; Surgeon to St. Thomas' Hospital.

1909. HALSTEAD, ALBERT E., M.D., 30 N. Michigan Avenue, Chicago, Ill. Professor of Surgery, School of Medicine, University of Illinois; Attending Surgeon to the St. Luke's and Cook County Hospitals; Consulting Surgeon to the Illinois Charitable Eye and Ear Infirmary; Lieut.-Col., M.C., U.S.A.

†1892. HALSTED, WILLIAM STEWART, A.B. (Yale University, 1874), M.D. (Columbia University, College of Physicians and

ELECTED

Surgeons, N. Y., 1877), LL.D. (Yale University, 1904, and University of Edinburgh, 1905), Sc.D. (Columbia University, 1904), 1201 Eutaw Place, Baltimore, Md. Foreign Corresponding Member, Harveian Society, London; Honorary Fellow, Royal College of Surgeons, England, 1900; Edinburgh, 1905 and College of Surgeons of America, 1913; Membre corresp. étranger de la société de chirurgie, Paris, 1909; Membre titulaire de l'association française de chirurgie, 1914; Ehrenmitglied der deutschen Gesellschaft für Chirurgie, 1914; Hon. Member Societas medicorum Sverana, Stockholm, 1918; Foreign member Royal Swedish Academy of Science, 1918; Member of the National Academy of Sciences; Surgeon-in-Chief, the Johns Hopkins Hospital; Professor of Surgery and Director of the Surgical Clinic of the Johns Hopkins University.

1909. HAMANN, CARL A., M.D., 416 Osborn Bldg., Cleveland, Ohio. Professor of Applied Anatomy, Western Reserve University; Visiting Surgeon to Charity and City Hospitals.

1900. HARRIS, MALCOLM L., M.D., 25 E. Washington St., Chicago, Ill. Professor of Surgery, Chicago Policlinic; Attending Surgeon, Alexian Brothers' Hospital, Henrotin Hospital, Passavant Hospital; Consulting Surgeon to Maurice Porter Hospital for Children.

1895. HARTE, RICHARD H., M.D., C.M.G., 1503 Spruce Street, Philadelphia. Emeritus Surgeon to the Pennsylvania Hospital and Consulting Surgeon to St. Mary's, St. Timothy's, Abington, and Bryn Mawr Hospitals; Colonel M.R.C., U.S.A; formerly Director Base Hospital No. 10, U.S.A., and later O. C. No. 16, General Hospital, B.E.F. *President*, 1910.

1916. HARTWELL, JOHN A., Ph.B., M.D., 27 East Sixty-third Street, New York. Associate Professor of Surgery and Professor of Clinical Surgery, Cornell University Medical College; Director of Surgery, Cornell University Division, Bellevue Hospital; Consulting Surgeon to Lincoln Hospital, Lawrence Hospital, Bronxville, N. Y., and United Hospital, Port Chester, N. Y.

1918. HODGE, EDWARD BLANCHARD, A.B., M.D., 2019 Spruce St., Philadelphia, Pa. Surgeon to Presbyterian and Children's Hospitals; Out-patient Surgeon to Pennsylvania Hospital; Associate Surgeon to Widener Memorial School.

1909. HOTCHKISS, LUCIUS WALES, A.B., M.D., 11 East Forty-eighth Street, New York. Professor of Clinical Surgery, Columbia

ELECTED

University; Consulting Surgeon to Bellevue, Knickerbocker, Flushing and Greenwich Hospitals; Junior Surgeon to Roosevelt Hospital, New York City.

1918. HUBBARD, JOSHUA C., M.D., 86 Bay State Road, Boston, Mass. Visiting Surgeon, Boston City Hospital; Surgeon, Newton Hospital; Consulting Surgeon, Norwood Hospital and Leonard Morse Hospital.

†1901. HUNTINGTON, THOMAS W., A.B., M.D., LL.D., 960 Mills Building, San Francisco, California. Professor of Clinical and Operative Surgery (Emeritus), College of Medicine, University of California; Consulting Surgeon, St. Luke's Hospital, San Francisco; Chief Surgeon, Western Pac. R. R. *Vice-President*, 1906; *President*, 1917.

1919. HUPP, FRANK LE MOYNE, A.M., M.D., 61 Fourteenth St., Wheeling, W. Va. Attending Surgeon, Ohio Valley General Hospital; Consulting Surgeon, Reynolds Memorial Hospital, Glendale; Sheltering Arms Hospital, Hansford.

1913. HUTCHISON, JAMES ALEXANDER, M.D., L.R.C.P. and S. (Edin.), 354 MacKay Street, Montreal. Professor of Surgery and Clinical Surgery, McGill University; Attending Surgeon, Montreal General Hospital.

1909. HUTCHINSON, JAMES P., M.D., 133 South Twenty-second Street, Philadelphia. Surgeon to the Pennsylvania, Methodist, Children's, St. Timothy's and Bryn Mawr Hospitals.

1913. JACKSON, JABEZ N., A.M., M.D., 425 Argyle Building, Kansas City, Mo. Surgeon and Chief of Staff of Christian Church Hospital; Surgeon, Kansas City General Hospital.

†1905. JOHNSON, ROBERT W., A.B., M.D., 101 W. Franklin Street, Baltimore, Md. Professor of Principles and Practice of Surgery, Baltimore Medical College; Surgeon to Maryland General Hospital, Church Home and Infirmary, and St. Agnes' Hospital. Retired.

1901. JONAS, A. F., M.D., 512 McCayne Bldg., Omaha, Nebraska. Professor of Surgery, Omaha Medical College; Surgeon to the Methodist Episcopal Hospital and to the Douglas County Hospital; Captain, M.C. *Vice-President*, 1906.

1917. JONES, DANIEL FISKE, A.B., M.D., 195 Beacon Street, Boston. Mass. Visiting Surgeon, Massachusetts General Hospital; Consulting Surgeon to the New England Hospital for Women and Children, Brockton City Hospital, Union

ELECTED

Hospital of Fall River, Sturdy Hospital of Attleboro and the Addison Gilbert Hospital of Gloucester, Mass.

1910. JOPSON, JOHN HOWARD, M.D., *Recorder*, 1824 Pine Street, Philadelphia, Pa. Professor of Surgery, the Graduate School of Medicine, University of Pennsylvania; Associate in Surgery, University of Pennsylvania; Surgeon to Presbyterian Hospital, Children's Hospital and Bryn Mawr Hospital.

1914. JUDD, EDWARD STARR, M.D., Rochester, Minn., Surgeon to Mayo Clinic.

†1899. KAMMERER, FREDERIC, M.D., 51 East Sixty-sixth Street, New York City. Professor of Clinical Surgery, Columbia University; Attending Surgeon to the Lenox Hill Hospital; Consulting Surgeon to St. Francis Hospital, New York.

1913. KANAVEL, ALLEN B., A.B., M.D., 30 North Michigan Avenue, Chicago, Ill. Professor of Surgery, Northwestern University Medical School; Attending Surgeon to Wesley Memorial and Cook County Hospitals.

*†1880. KEEN, WILLIAM WILLIAMS, A.M., M.D., LL.D., Hon. F.R.C.S. (Eng. and Edin.), Hon. Ph.D. (Upsala), Hon. Sc.D. (Jeff.), Hon. F.A.C.S., 1729 Chestnut Street, Philadelphia. Emeritus Professor of Surgery in the Jefferson Medical College; Consulting Surgeon to the Jefferson Medical College Hospital and to the Woman's and St. Agnes' Hospitals; Membre Correspondant Etranger de la Société de Chirurgie de Paris; Membre Honoraire de la Société Belge de Chirurgie; Honorary Member, Clinical Society of London, etc. *President*, 1898; *Vice-President*, 1892; *Member of Council*, 1899–1901.

1916. LAW, ARTHUR AYER, M.D., F.A.C.S., 420 Syndicate Building, Minneapolis, Minn. Associate Professor of Surgery, University of Minnesota Medical School, and Mayo Foundation; Surgeon to the Northwestern Hospital; Surgeon to and Assistant Chief of the University Hospital; Lieut.-Col., M.C. (discharged), Commanding University of Minnesota Base Hospital No. 26 in A.E.F.

1901. LE CONTE, ROBERT G., A.B., M.D., 2000 Spruce Street, Philadelphia. Surgeon to the Pennsylvania Hospital; Consulting Surgeon to the Germantown, the Bryn Mawr and the Gynecean Hospitals. *President*, 1915.

ELECTED

1919. Lee, Burton James, Ph.B., M.D., F.R.C.S., 128 East 73d Street, New York. Clinical Professor of Surgery, Cornell Medical School; Associate Attending Surgeon, New York Hospital; Consulting Surgeon, Sharon (Connecticut) Hospital.

1912. Lewis, Dean D., M.D., 122 S. Michigan Ave., Chicago, Ill. Professor of Surgery, Rush Medical College; Attending Surgeon to the Presbyterian Hospital, Chicago; Consulting Surgeon to the Annie Durand Hospital for Contagious Diseases.

1910. Lilienthal, Howard, A.B., M.D., 52 East Eighty-second Street, New York. Attending Surgeon, Mount Sinai Hospital; Visiting Surgeon to Bellevue Hospital; Consulting Surgeon, Hospital for Joint Diseases, Jewish Maternity Hospital and Har Moriah Hospital; Professor of Clinical Surgery, Cornell Medical College; formerly Lieut.-Col., M.C., U.S.A.

1908. Lothrop, Howard Augustus, A.M., M.D., 101 Beacon St., Boston, Mass. Assistant Professor of Surgery, Harvard Medical School; Surgeon-in-Chief, Boston City Hospital.

1916. Lower, William E., M.D., Euclid Avenue and 93d Street, Cleveland, Ohio. Associate Professor of Genito-urinary Surgery, School of Medicine, Western Reserve University; Director of Surgery, Mount Sinai Hospital; Associate Surgeon in charge of Genito-urinary Surgery, Lakeside Hospital; Visiting Surgeon, Lutheran Hospital and White Hospital (Ravenna).

1910. Lund, Frederick Bates, M.D., 527 Beacon Street, Bostón, Mass. Associate in Surgery, Harvard Medical School; Surgeon-in-Chief, Boston City Hospital; Consulting Surgeon, Burbank Hospital, Fitchberg, Newton Hospital, Newton; lately Lieut.-Col., M.C., U.S.A.

1917. Lyle, Henry H. M., M.D., 117 East Fifty-sixth Street, New York City. Professor of Clinical Surgery, College of Physicians and Surgeons, Columbia University; Attending Surgeon, St. Luke's Hospital.

1901. McArthur, L. L., M.D., 122 S. Michigan Boulevard, Chicago, Ill. Professor of Clinical Surgery, Post-Graduate Medical School; Assistant Professor of Clinical Surgery, Rush Medical College; Senior Surgeon to St. Luke's and Michael Reese Hospitals.

ELECTED

†1882. McGraw, Theodore A., M.D., 73 Case Street, Detroit, Mich. Professor of Surgery in the Detroit Medical College; Surgeon to St. Mary's and Harper Hospitals. *Vice-President*, 1896.

1917. McGuire, Stuart, M.D., LL.D., 513 East Grace Street, Richmond, Va. Professor of Surgery, Medical College of Virginia; Surgeon in Charge of St. Luke's Hospital; Visiting Surgeon to Memorial Hospital.

†1903. McMurtry, Lewis S., A.M., M.D., LL.D., 542 Atherton Building, Louisville, Ky. Professor of Gynecology and Abdominal Surgery in the Medical Department, University of Louisville; Surgeon to the Louisville City Hospital.

1915. McRae, Floyd W., M.D., Peters Building, Atlanta, Ga. Chief Surgeon to the Piedmont Sanatorium; Visiting Surgeon to St. Joseph's Infirmary; Consulting Surgeon to Grady Hospital.

1918. McWilliams, Clarence A., M.A., M.D., 19 East Sixty-fifth Street, New York, N. Y. Associate Surgeon, Presbyterian Hospital, Instructor in Surgery, Columbia University.

1904. MacLaren, Archibald, M.D., B.S., 914 Lowry Building, St. Paul, Minn. Professor of Clinical Surgery, University of Minnesota. *Vice-President*, 1915.

1914. MacLaren, Murray, B.A., M.B.C.M., M.D., M.R.C.S. (Eng.), C.M.G. (Order of Avis), LL.D., 75 Coburg Street, St. John's, N.B., Canada. Surgeon to the General Public Hospital; Colonel, C.A.M.C.

1920. Maes, Urban, M.D., 1671 Octavia Street, New Orleans, Louisiana. Professor of Clinical and Operative Surgery, Tulane University of Louisiana School of Medicine; Junior Surgeon, Charity Hospital, Touro Infirmary; Senior Surgeon, New Orleans Dispensary for Women and Children.

1898. Martin, Edward, A.M., M.D., LL.D., 135 S. 18th Street, Philadelphia. Commissioner of Health of Pennsylvania; Professor of Surgical Physiology, University of Pennsylvania; Consulting Surgeon to State Hospitals, Norristown and Wernersville, Pa.; Colonel, M.R.C., U.S.A.

1915. Martin, Walton, Ph.B., M.D., 151 East Sixty-third Street, New York. Professor of Clinical Surgery, Columbia University; Attending Surgeon, St. Luke's Hospital; Consulting Surgeon, White Plains Hospital and Loomis Sanatorium.

†1895. Mastin, William McDowell, M.D., LL.D., Northeast corner of Joachim and Conti Streets, Mobile, Ala. Surgeon to the Mobile City Hospital and Providence Infirmary.

ELECTED

1895. MATAS, RUDOLPH, M.D., LL.D., 2255 St. Charles Avenue, New Orleans, Louisiana. Professor of Surgery, Tulane University of Louisiana, School of Medicine; Professor (Emeritus), Graduate Medical School, Tulane University; Senior, Surgical Division, Touro Infirmary; Chief of Surgical Service, Visiting Staff, Charity Hospital; Consulting Surgeon, Eye, Ear, Nose and Throat Hospital; Major, Reserve Corps, U. S. Army. *President*, 1909; *Vice-President*, 1901.

1918. MATHEWS, FRANCIS STUART, B.S., M.D., F.A.C.S., 62 West Fiftieth Street, New York. Professor of Clinical Surgery, Columbia University; Surgeon to St. Luke's Hospital and St. Mary's Hospital for Children.

1903. MAYO, CHARLES H., A.M., M.D., LL.D., D.Sc., F.A.C.S., Rochester, Minn. Professor of Surgery, Medical School, University of Minnesota; Surgeon to Mayo Clinic (St. Mary's Hospital).

1899. MAYO, WILLIAM J., A.M., M.D. (Mich.), D.Sc. (Columbia and Mich.), F.R.C.S. (Eng. and Edin.), LL.D. (Tor., Md. and Penna.), C.E., Soc. de Chir. de Paris, F.A.C.S., 701 College Hill, Rochester, Minn. Surgeon to St. Mary's Hospital. *Vice-President*, 1903; *President*, 1915.

1901. MEYER, WILLY, M.D., 700 Madison Avenue, New York. Professor of Surgery in the New York Post-Graduate Medical School and Hospital; Attending Surgeon to the Lenox Hill Hospital; Consulting Surgeon to the New York Infirmary for Women and Children, New York Skin and Cancer Hospital, Hospital for Deformities and Joint Diseases and the Montefiore Hospital.

1919. MILLER, ROBERT TALBOTT, A.B., M.D., 1226 Murray Hill Avenue, Pittsburgh, Pa. Professor of Surgery, University of Pittsburgh; Surgeon to Mercy Hospital.

1917. MITCHELL, CHARLES F., M.D., 332 South Fifteenth Street, Philadelphia, Pa. Attending Surgeon to the Germantown, Bryn Mawr and Pennsylvania Hospitals.

1912. MITCHELL, JAMES F., A.B., M.D., 1344 Nineteenth Street, Washington, D. C. Clinical Professor of Surgery, Georgetown and George Washington Universities; Chief Surgeon, Emergency Hospital. *Vice-President*, 1920.

†1893. MIXTER, SAMUEL JASON, S.B. (Massachusetts Institute of Technology), M.D. (Harvard), 180 Marlborough Street, Boston. Consulting Surgeon to Massachusetts General

ELECTED

Hospital and to Massachusetts Charity Eye and Ear Infirmary. *President*, 1916.

1920. MIXTER, WILLIAM JASON, B.Sc., M.D., 180 Marlborough Street, Boston, Massachusetts. Assistant Surgeon, Massachusetts General Hospital; Surgeon, Anna Jaques Hospital, Newburyport; Consulting Surgeon, Leonard Morse Hospital, Natick, Charitable Eye and Ear Infirmary, Boston, Cable Memorial Hospital, Ipswich.

†1896. MONKS, GEORGE HOWARD, A.B. (Harvard), M.D. (Harvard), M.R.C.S. (Eng.), 51 Commonwealth Ave., Boston. Consulting Surgeon, Boston City Hospital; Professor of Oral Surgery, Harvard Dental School.

1914. MOSCHCOWITZ, ALEXIS V., M.D., 925 Madison Ave., New York, N. Y. Professor of Clinical Surgery, College of Physicians and Surgeons, Columbia University; Attending Surgeon, Mount Sinai Hospital.

1904. MUDD, HARVEY G., M.D., Humboldt Bldg., St. Louis, Mo. Clinical Professor of Surgery, Medical Department, Washington University; Surgeon to St. Luke's Hospital; Consulting Surgeon to the Barnard Free Skin and Cancer Hospital. *Vice-President*, 1920.

1919. MÜLLER, GEORGE P., M.D., 1930 Spruce St., Philadelphia, Pa. Professor of Surgery, Graduate School of the University of Pennsylvania; Associate in Surgery, Medical School of the University of Pennsylvania; Surgeon to the Misericordia and St. Agnes Hospitals; Consulting Surgeon to the Chester County Hospital, West Chester, Pa.

1913. MURPHY, FRED T., A.B., M.A., M.D., 2248 Penobscot Bldg., Detroit, Michigan.

†1898. MURRAY, FRANCIS W., M.D., 32 West Thirty-ninth Street, New York City. Consulting Surgeon, New York Hospital, St. Luke's Hospital, New York Eye and Ear Infirmary, Paul Kimball Hospital, Lakewood, Goshen Emergency Hospital.

†1882. DE NANCRÈDE, C. B. G., A.M. (University of Pennsylvania), A.M. (University of Michigan), M.D. (University of Pennsylvania and Jefferson Medical College), LL.D. (Jefferson and University of Michigan), 900 Forest Avenue, Ann Arbor, Michigan. Professor of Surgery in the University of Michigan; Professor of Surgery, Dartmouth Medical College. *President*, 1908; *Vice-President*, 1889 and 1899.

ELECTED

1903. NEILSON, THOMAS R., M.D., 1937 Chestnut Street, Philadelphia, Pa. Surgeon to the Episcopal Hospital and to St. Christopher's Hospital for Children; Clinical Professor of Genito-urinary Diseases in the University of Pennsylvania.

1915. NICHOLS, EDWARD HALL, A.B., A.M., M.D., 294 Marlborough Street, Boston, Massachusetts. Clinical Professor of Surgery, Harvard University Medical School; Senior Visiting Surgeon, Boston City Hospital; Consulting Surgeon, City Hospital, Quincy, and Framingham Hospital, Framingham.

1900. OCHSNER, A.J., B.S., F.R.M.S., M.D. (Eng.), LL.D.; F.A.C.S., 710 Sedgwick Street, Chicago. Professor of Clinical Surgery, College of Physicians and Surgeons; Surgeon-in Chief of Augustana and St. Mary's Hospitals.

1900. OLIVER, J. C., M.D., 628 Elm Street, Cincinnati, Ohio. Acting Dean and Professor of Surgery, Medical Department, University of Cincinnati; Director of Second Surgical Service, Cincinnati General Hospital; Surgeon to the Christ Hospital.

1915. OLMSTED, INGERSOLL, M.B., 215 James Street, South, Hamilton, Ontario. Surgeon to City Hospital.

†1882. OWENS, JOHN E., M.D., 1017–18 Venetian Building, Chicago, Ill. Professor of Principles and Practice of Surgery and Clinical Surgery in the Chicago Medical College; Surgeon to St. Luke's Hospital. *Vice-President*, 1900.

1899. PARHAM, FREDERICK WILLIAM, M.D., 3513 Prytania Street, New Orleans, La. Professor of General Clinical Surgery, New Orleans Polyclinic (Post-Graduate Department of Tulane University of Louisiana); Chief of Staff to Charity Hospital and to Touro Infirmary.

†1893. PARMENTER, JOHN, M.D., 519 Franklin Street, Buffalo, N. Y. Late Professor of Clinical Surgery, Medical Department, University of Buffalo.

1908. PECK, CHARLES HOWARD, *Treasurer*, M.D., 30 W. Fiftieth St., New York City. Professor of Clinical Surgery, Columbia University; Senior Attending Surgeon to the Roosevelt Hospital; Consulting Surgeon to French Hospital, Memorial Hospital and Hospital for Ruptured and Crippled, New York City; Vassar Brothers Hospital, Poughkeepsie, N. Y.; Nyack Hospital, Nyack, N. Y.; White Plains Hospital,

ELECTED

White Plains, N. Y.; United Hospital, Portchester and Rye, N. Y.; Stamford Hospital, Stamford, Conn.; Greenwich Hospital, Greenwich, Conn.; Hackensack Hospital, Hackensack, N. J.

1919. PERCY, NELSON MORTIMER, M.D., F.A.C.S., 2106 Sedgwick Street, Chicago, Ill. Associate Professor of Clinical Surgery, Medical Department of the University of Illinois; Attending Surgeon to the Augustana and St. Mary's of Nazareth Hospitals.

1917. PHEMISTER, DALLAS B., B.S., M.D., 122 South Michigan Ave., Chicago, Ill. Assistant Professor in Surgery, Rush Medical College; Associate Attending Surgeon, Presbyterian Hospital.

†1889. PILCHER, LEWIS STEPHEN, A.M., M.D., LL.D. (Dickinson and University of Michigan), 145 Gates Avenue, Brooklyn, N. Y. Consulting Surgeon to the St. John, Norwegian, Jewish, Bushwick and Deaconess Hospitals. *Vice-President*, 1893, 1914. *President*, 1918.

1914. PLUMMER, SAMUEL C., A.B., M.D., 4539 Oakenwald Avenue, Chicago, Ill. Attending Surgeon, St. Luke's Hospital; Chief Surgeon, C. R. I. & P. Ry. Co.

1914. POOL, EUGENE HILLHOUSE, A.B., M.D., 107 East Sixtieth Street, New York, N. Y. Attending Surgeon, New York Hospital; Associate Professor of Surgery, Columbia University; Consultant Surgeon to French Hospital, New York Orthopedic, Manhattan State Hospital, Home for Incurables and United Hospital at Portchester.

1904. PORTER, CHARLES ALLEN, A.M., M.D., 116 Beacon Street, Boston, Mass. Chief of West Surgical Service, Massachusetts General Hospital; Professor of Clinical Surgery, Harvard Medical School.

1915. PORTER, MILES FULLER, M.A., M.D., Walnut Place, Fort Wayne, Ind. Professor of Surgery in the Indiana University School of Medicine; Surgeon to St. Joseph's Hospital; Consulting Surgeon in the Indiana School for Feeble-minded Youths.

†1896. POWERS, CHARLES A., A.M., M.D., University Club, Denver, Col. Professor of Surgery, Emeritus, in the University of Colorado; Consulting Surgeon to the Denver City and County Hospital, to the Mercy Hospital, and to the State Home for Children. *President*, 1912; *Vice-President*, 1903; *Treasurer*, 1906–1912; *Member of Council*, 1906–1916.

ELECTED

1908. PRIMROSE, ALEXANDER, C.B., M.B., C.M. (Edin.), M.R.C.S. (Eng.), 100 College Street, Toronto, Canada. Surgeon to the Toronto General Hospital and Consulting Surgeon to the Hospital for Sick Children, Toronto; Professor of Clinical Surgery in the University of Toronto.

†1886. RANSOHOFF, JOSEPH, M.D., F.A.C.S., F.R.C.S. (Eng.), Livingston Bldg., 707 Race Street, Cincinnati, Ohio. Professor of Surgery, University of Cincinnati; Director, First Surgical Service, Cincinnati General Hospital; Dean, Jewish Hospital. *Vice-President*, 1911.

1901. RIXFORD, EMMET, B.S., M.D., 1795 California Street, San Francisco, Cal. Professor of Surgery in Stanford University School of Medicine; Surgeon to the San Francisco and Lane Hospitals; Member of the Society of Clinical Surgery. *Vice-President*, 1905.

†1882. ROBERTS, JOHN B., A.M., M.D., 313 South Seventeenth Street, Philadelphia. Professor of Surgery in the University of Pennsylvania Graduate School of Medicine. *Vice-President*, 1888 and 1894; *Treasurer*, 1892–93; *President*, 1920.

1914. ROSS, GEORGE GORGAS, M.D., 1721 Spruce Street, Philadelphia, Pa. Visiting Surgeon, Germantown Hospital; Assistant Surgeon, Lankenau Hospital; Visiting Surgeon to the Stetson and Methodist Hospitals; Assistant Surgeon to the University Hospital; Associate in Surgery, University of Pennsylvania.

1917. ROWAN, CHARLES J., A.B., M.D., Iowa City, Iowa. Professor and Head of Department of Surgery, College of Medicine, State University of Iowa; Director of the University Hospital.

†1882. RUSHMORE, JOHN DIKEMAN, M.D., 129 Montague Street, Brooklyn, N. Y. Professor of Operative and Clinical Surgery, Emeritus, Long Island College Hospital; Surgeon to St. Peter's Hospital; Consulting Surgeon to Long Island College Hospital, Kings County Hospital, Swedish and Lutheran Hospitals.

1909. SCUDDER, CHARLES L., M.D., A.B., Ph.B., 209 Beacon Street, Boston, Mass. Assistant Professor of Surgery, Harvard Medical School; Chief of the East Surgical Service, Massachusetts General Hospital; Member of the Administrative Board of the Graduate School of Medicine, Harvard University.

ELECTED

1919. SEELIG, M. G., A.B., M.D., 4952 Park View Place, St. Louis, Mo. Professor of Surgery, St. Louis University; Visiting Surgeon to the Jewish Hospital and to the St. Louis City Hospital.

†1902. SHEPHERD, FRANCIS J., M.D., LL.D., F.R.C.S. (Eng.), 152 Mansfield Street, Montreal, Canada. Emeritus Professor in McGill University; Consulting Surgeon to the Montreal General Hospital and Royal Victoria Hospital, Montreal.

1905. SHERMAN, HARRY M., A.M., M.D., 350 Post Street, San Francisco, Cal. Surgeon to St. Luke's Hospital, San Francisco; Orthopedic Surgeon to the Children's Hospital, San Francisco.

1920. SISTRUNK, WALTER E., M.D., F.A.C.S., Surgeon to Saint Mary's and the Colonial Hospitals (Mayo Clinic), Rochester, Minn.; Associate Professor of Surgery, Mayo Foundation, University of Minnesota.

1918. SMITH, REA, M.D., 22 Chester Place, Los Angeles, Cal. Surgeon, California Hospital and Los Angeles County Hospital.

†1895. SOUCHON, EDMOND, M.D., 2403 St. Charles Avenue, New Orleans, La. Professor of Anatomy and of Clinical Surgery, Tulane University; Surgeon to Charity Hospital; Consulting Surgeon to the Eye, Ear, Nose, and Throat Hospital. Honorary Fellow of American College of Surgeons; Former President of Louisiana State Board of Health, 1898–1905. *Vice-President*, 1899.

1919. SPEED, KELLOGG, S.B., M.D., F.A.C.S., 122 South Michigan Avenue, Chicago, Ill. Assistant Professor of Surgery, Rush Medical College, Attending Surgeon, Cook County and Provident Hospitals; Assistant Surgeon, Presbyterian Hospital; Consulting Surgeon, U. S. P. H. S. Hospital No. 2.

1918. STARR, CLARENCE LESLIE, M.B., M.D., 224 Bloor St., West, Toronto, Canada. Associate Professor of Surgery, University of Toronto; Surgeon-in-Chief, Hospital for Sick Children; Consultant in Surgery, Toronto General Hospital; Surgeon to St. John's Hospital; Lieut.-Col.-Consultant, C. A. M. C.

1914. STARR, FREDERIC NEWTON GISBORNE, C.B.E., M.B., M.D., C.M., 112 College Street, Toronto, Canada. Associate Professor of Clinical Surgery, University of Toronto; Surgeon to Hospital for Sick Children, and to St. John's Hospital for Women; Senior Assistant Surgeon, Toronto General Hospital.

ELECTED

1915. STEWART, GEORGE DAVID, M.D., 61 West Fiftieth Street, New York. President, New York Academy of Medicine; Professor of Surgery, New York University Medical School; Visiting Surgeon to St. Vincent's and Bellevue Hospitals; Consulting Surgeon to Hospital for Ruptured and Crippled of New York, to St. Joseph's Hospital, Yonkers, to St. Mary's Hospital, East Orange, N. J., to South Side Hospital, Babylon, L. I., to Englewood Hospital, Englewood, N. J., and to the United Hospital, Portchester, N. Y.

1909. STILLMAN, STANLEY, M.D., 2101 Webster Street, San Francisco, Cal. Professor of Surgery, Stanford University Medical School; Commander, M. C., U. S. N. R. F.; Surgeon to Lane and Stanford University Hospitals.

1912. STOKES, CHARLES F., A.M., M.D., D.Sc., LL.D., 6 West 77th Street, New York City. Former Surgeon-General, U. S. N.

1909. SUMMERS, JOHN EDWARD, M.D., 618 Brandeis Theatre Bldg., Omaha, Neb. Professor of Clinical Surgery, University of Nebraska Medical School; Surgeon to the University Hospital and to the Clarkson Memorial, the Wise Memorial, and the Douglas County Hospitals, Omaha, Neb.

1920. TAYLOR, ALFRED S., B.P., A.M., M.D., 115 W. 55th Street, New York. Professor of Clinical Surgery, Cornell Medical School; Visiting Surgeon, Fordham Hospital and Neurological Institute; Neurological Surgeon, Hospital for Ruptured and Crippled; Consulting Surgeon to Memorial Hospital, New York City, Tarrytown Hospital, New York, White Plains Hospital, New York, Overlook Hospital, Summit, N. J.

1900. TAYLOR, WILLIAM J., M.D., 1825 Pine Street, Philadelphia. Surgeon to the Orthopædic Hospital and Infirmary for Nervous Diseases, and to St. Agnes' Hospital; Consulting Surgeon to the West Philadelphia Hospital for Women and to the Woman's Hospital.

1916. TERRY, WALLACE I., B.S., M.D., 240 Stockton Street, San Francisco, Cal. Professor of Surgery, University of California; Chief Surgeon, University of California Hospital, San Francisco.

1909. THOMPSON, JAMES E., M.B., B.S. (London), F.R.C.S. (Eng.), F.A.C.S., 3224 Broadway, Galveston, Texas. Professor of Surgery in the University of Texas; Surgeon to the John Sealy Hospital.

ELECTED

1920. TINKER, MARTIN B., B.S., M.D., 101 South Aurora Street, Ithaca, N. Y. Surgeon to the Ithaca City Hospital and the Cornell Infirmary.

1918. TRUESDALE, PHILEMON EDWARDS, M.D., 177 Winter St., Fall River, Mass. Surgeon to St. Anne's and Highland Hospitals; Consulting Surgeon to Fall River City Hospital.

†1882. VANDER VEER, ALBERT, A.M., M.D., Ph.D., LL.D., 28 Eagle Street, Albany, N. Y. Surgeon-in-Chief, Albany Hospital; Consulting Surgeon, Albany Free Dispensary Association, Benedictine Hospital, Kingston, N. Y., and Champlain Valley Hospital, Plattsburgh, N. Y. *President*, 1905; *Vice-President*, 1898; *Member of Council*, 1907.

1910. VANDER VEER, EDGAR ALBERT, Ph.B., M.D., 28 Eagle Street, Albany, N. Y. Attending Surgeon, Albany Hospital; Consulting Surgeon, Champlain Valley Hospital and Benedictine Hospital, Kingston, N. Y.

1902. VAUGHAN, GEORGE TULLY, M.D., LL.D., 1718 I Street, Washington, D. C. Professor of Principles and Practice of Surgery and Head of the Surgical Department, Georgetown University; Chief Surgeon, Georgetown University Hospital; Surgeon, Tuberculosis Hospital; Consulting Surgeon, Government Hospital for the Insane, Washington, D. C., U. S. Public Health Service and Washington Asylum Hospital; Commander, M. C., Reserve Force, U. S. N.

1920. VERDI, WILLIAM FRANCIS, A.M., M.D., 27 Elm Street, New Haven, Connecticut. Clinical Professor of Surgery, Yale University School of Medicine; Chief Surgeon, Hospital of St. Raphael; Attending Surgeon, New Haven Hospital; Consulting Surgeon, St. Vincent's Hospital, Bridgeport, St. Mary's Hospital, Waterbury, Middlesex Hospital, Middletown.

1918. WAINWRIGHT, JONATHAN M., A.B., A.M., M.D., 912 Clay Ave., Scranton, Pa. Surgeon-in-Chief, Moses Taylor Hospitals (Scranton and Buffalo); Chief Surgeon, D. L. & W. R. R. Co.

1891. WALKER, EDWARD W., M.D., 30 Garfield Place, Cincinnati, Ohio. Professor of Surgery, Miami Medical College.

1909. WALKER, JOHN B., M.D., 51 East Fiftieth Street, New York City. Surgeon to Bellevue Hospital and Hospital for Ruptured and Crippled, New York; Professor of Clinical Surgery, College of Physicians and Surgeons, Columbia University, N. Y.

†1882. WARREN, JOHN COLLINS, M.D., LL.D. (Jefferson, Harvard and McGill), Hon. F.R.C.S. (Eng. and Edin.), 58 Beacon Street, Boston, Mass. Emeritus Professor of Surgery in Harvard University; Consulting Surgeon to the Massachusetts General Hospital. *President*, 1896; *Vice-President*, 1890; *Member of Council*, 1897.

†1896. WATSON, FRANCIS SEDGWICK, A.B., M.D., 92 Marlborough St., Boston. Surgeon to the Boston City Hospital; Instructor in Genito-Urinary Surgery, Harvard Medical School.

1913. WATTS, STEPHEN H., M.A., M.D., Department of Surgery, University of Virginia, Charlottesville, Va. Professor of Surgery and Gynecology in the University of Virginia; Surgeon-in-Chief, University of Virginia Hospital.

†1889. WEIR, ROBERT F., A.M., M.D., Hon. F.R.C.S. (Eng.), Cor. Mem. Surg. Soc., Paris, 1155 Park Avenue, New York. Professor of Surgery in the College of Physicians and Surgeons, Columbia University; Surgeon to the Roosevelt Hospital. *President*, 1899; *Member of Council*, 1893–1896; 1901–03.

†1892. WHARTON, HENRY R., A.M., M.D., 1725 Spruce Street, Philadelphia. Surgeon to the Presbyterian and Children's Hospitals.

1914. WINSLOW, RANDOLPH, A.B., M.D., A.M., LL.D., 1900 Mt. Royal Terrace, Baltimore, Md. Professor of Surgery, University of Maryland; Chief Surgeon, University Hospital; Consulting Surgeon, Hebrew Hospital, Baltimore, Union Hospital, Elkton, Md., and to James L. Kernan Hospital for Crippled Children, Baltimore.

1918. WOOD, ALFRED CONARD, M.D., 2035 Walnut St., Philadelphia, Pa. Assistant Professor of Surgery, University of Pennsylvania; Surgeon to the University, Philadelphia General, Howard, St. Timothy's and Rush Hospitals.

1901. WOOLSEY, GEORGE, M.D., 117 East Thirty-sixth Street, New York City. Professor of Clinical Surgery, Cornell University; Surgeon to Bellevue Hospital; Consulting Surgeon to Memorial, Peekskill and St. John's Riverside, Yonkers.

1916. YATES, J. L., Ph.B., B.S., M.D., F.A.C.S., 141 Wisconsin Street, Milwaukee, Wis. Chief of Staff, Milwaukee County Hospital; Attending Surgeon, Columbia Hospital.

SENIOR FELLOWS OF THE ASSOCIATION

Abbe, Robert, M.D., 13 West Fiftieth Street, New York.
Allis, Oscar H., A.M., M.D., 1604 Spruce Street, Philadelphia, Pa.

Barton, James M., A.M., M.D., 32 North New Hampshire Ave., Atlantic City, N. J.
Bradford, E. H., A.B., M.D., 133 Newbury Street, Boston, Mass.

Carmalt, William H., A.M., M.D., 261 St. Ronan St., New Haven, Conn.
Carson, Norman Bruce, M.D., 303 Humboldt Bldg., St. Louis, Mo.
Cushing, Hayward Warren, A.B., M.D., 70 Commonwealth Ave., Boston, Mass.

Dennis, Frederic Shepard, M.D., F.R.C.S. (Eng.), 62 East 55th Street, New York, N. Y.

Elliott, John Wheelock, A.M., M.D., 124 Beacon Street, Boston, Mass.
Estes, William Lawrence, A.M., M.D., South Bethlehem, Pa.

Gay, George W., A.M., M.D., 665 Boylston Street, Boston, Mass.
‡Gerrish, Frederic H., A.M., M.D., LL.D., 675 Congress Street, Portland, Me.
Gerster, Arpad G., M.D., Chir.D., 34 East Seventy-fifth Street, New York, N. Y.

Halsted, Wm. Stewart, A.B., LL.D., S.C.D., M.D., Hon. F.R.C.S. (Eng. and Edin.), Hon. F.A.C.S., 1201 Eutaw Place, Baltimore, Md.
Huntington, Thomas W., A.B., M.D., LL.D., 960 Mills Building, San Francisco, Cal.

Johnson, Robert W., A.B., M.D., 101 W. Franklin St., Baltimore, M.D.

Kammerer, Frederic, M.D., 51 East Sixty-sixth Street, New York City.

Keen, W. W., A.M., M.D., LL.D., Hon. F.R.C.S. (Eng. and Edin.), Hon. F.A.C.S., 1729 Chestnut Street, Philadelphia, Pa.

Mastin, Wm. M., M.D., LL.D., Northeast corner Joachim and Conti Streets, Mobile, Ala.

McGraw, Theodore A., M.D., 73 Case Street, Detroit, Mich.

McMurtry, Lewis S., A.M., M.D., LL.D., 542 Atherton Building, Louisville, Ky.

Mixter, Samuel Jason, S.B., M.D., 180 Marlborough St., Boston, Mass.

Monks, George H., A.B., M.D., M.R.C.S., 51 Commonwealth Avenue, Boston, Mass.

Murray, Francis W., M.D., 32 West Thirty-ninth Street, New York, N. Y.

de Nancrède, C. B. G., A.M., M.D., LL.D., 900 Forest Avenue, Ann Arbor, Mich.

Owens, John E., M.D., 1201 Venetian Building, Chicago, Ill.

Parmenter, John, M.D., 519 Franklin Street, Buffalo, N. Y.

Pilcher, Lewis S., A.M., M.D., LL.D., 145 Gates Avenue, Brooklyn, New York. President, 1918.

Powers, Charles A., A.M., M.D., University Club, Denver, Colo.

Ransohoff, Joseph, M.D., F.R.C.S., F.A.C.S. (Eng.), 707 Race Street, Cincinnati, Ohio.

Roberts, John B., A.M., M.D., 313 South Seventeenth Street, Philadelphia, Pa.

Rushmore, John D., M.D., 129 Montague Street, Brooklyn, N. Y.

Shepherd, Francis J., M.D., LL.D., F.R.C.S. (Eng.), 152 Mansfield Street, Montreal, Canada.

Souchon, Edmund, M.D., 2403 St. Charles Ave., New Orleans, La.

Vander Veer, A., A.M., M.D., Ph.D., LL.D., 28 Eagle Street, Albany, N. Y.

Warren, J. Collins, M.D., LL.D., Hon. F.R.C.S. (Eng. and Edin.), 58 Beacon Street, Boston, Mass.

Watson, Francis S., A.B., M.D., 92 Marlborough Street, Boston, Mass.

Weir, Robert F., A.M., M.D., Hon. F.R.C.S. (Eng.), 1155 Park Avenue, New York, N. Y.

Wharton, Henry R., A.M., M.D., 1725 Spruce Street, Philadelphia, Pa.

HONORARY FELLOWS OF THE ASSOCIATION

ELECTED

1907. BALLANCE, CHARLES ALFRED, K.C.M.G., C.B., M.V.O., M.B., M.S., University of London, F.R.C.S. (Eng.), 106 Harley Street, London. Consulting Surgeon to St. Thomas's Hospital and to the National Hospital for Paralysis and Epilepsy, Queen Sq.

1919. BASTIANELLI, RAFFAELLE, rue Delle Terne 83, Rome, Italy.

1919. BOWLBY, SIR ANTHONY A., K.C.B., K.C.M.G., V.C.V.O., 25 Manchester Square W., London, England. Consulting Surgeon to St. Bartholomew's Hospital and to Queen Alexandra's Military Hospital.

1891. CHIENE, JOHN, F.R.C.S. (Edin.), M.D. (Edin.), Aithernie Davidsons Mains, Edinburgh. Emeritus Professor of Surgery, University of Edinburgh.

1916. DEPAGE, PROF. DR. ANTOINE, Le Panne, Belgium.

‡1916. GORGAS, WILLIAM C., Surgeon-General, A.B., M.D., Sc.D., LL.D., War Department, Washington, D. C.

1919. HARTMANN, DR. HENRI, 4 Place Malesherbes, Paris, France. Professor of Clinical Surgery, Faculté de Médecine de Paris and Surgeon to the Hotel Dieu.

1920. KEEN, W. W., A.M., M.D., LL.D., Hon. F.R.C.S. (Eng. and Edin.), Hon. Ph.D. (Upsala), Hon. Sc.D. (Jeff.), Hon. F.A.C.S., 1729 Chestnut Street, Philadelphia.

1918. KEOGH, SIR ALFRED, KY., K.C.B., Royal Army Medical Corps, England.

1894. MACEWEN, SIR WILLIAM, M.D., M.B., M.S., 3 Woodside Crescent, Glasgow, Scotland. Professor of Surgery, The University, Glasgow.

1918. MAKINS, SIR GEORGE, Surgeon General, K.C.M.G., C.B., F.R.C.S., England.

‡ Deceased.

ELECTED

1920. MANOURY, GABRIEL, Dr., Rue Bonneval 26, Chartres, France, Ex-President of French Surgical Association.

1908. MOYNIHAN, SIR B. G. A., M.S. (Lond.), F.R.C.S., 33 Park Square, Leeds, England. Surgeon to the Leeds Infirmary.

1907. MYLES, SIR THOMAS, M.D., F.R.C.S.I., 33 Merrion Square, N., Dublin, Ireland.

1903. ROBSON, A. W. MAYO, C.V.O., M.D., F.R.C.S., D.Sc., 8 Park Crescent, Portland Place, London, W., England. Vice-President, Royal College of Surgeons of England; Hunterian Professor of Surgery and Pathology.

1882. SMITH, STEPHEN, A.M., M.D., LL.D., 574 Madison Avenue, New York. Professor of Clinical Surgery in the University Medical College of New York; Surgeon to the Bellevue and St. Vincent's Hospitals. *Vice-President*, 1890.

1912. STILES, HAROLD JALLAND, M.B., F.R.C.S. (Edin.), 9 Great Stuart Street, Edinburgh, Scotland. Surgeon to Chalmers Hospital and to the Royal Edinburgh Hospital for Sick Children, Edinburgh.

1914. THOMSON, ALEXIS, B.M., M.S., M.D., (Edin.), M.R.C.S. (Eng.), 39 Drumsheugh Gardens, Edinburgh, Scotland. Professor of Surgery, University of Edinburgh.

1918. TUFFIER, TH., M.D., 42 Avenue Gabriel, Paris, France.

1920. WALLACE, SIR CUTHBERT, K.C.M.G., C.B., 26 Upper Wimpole St., W., London, Eng.; Surgeon to St. Thomas's Hospital, London.

1920. WALTHER, CHARLES, M.D., 68 Rue de Belle-Chasse, Paris, France. Ex-President of French Surgical Association.

DECEASED FELLOWS OF THE ASSOCIATION

Name	Date of death
Agnew, D. Hayes	March 22, 1892
Allen, Dudley Peter	January 6, 1915
Annandale, Thomas	1907
Ashhurst, John, Jr.	July 7, 1900
*Atlee, John Light	October 1, 1885
Beckman, Emil Hessel	November 7, 1916
Benham, Silas Nelson	November 3, 1890
*von Bergmann, Ernst	Died since 1906 Meeting
*Bigelow, Henry Jacob	October 30, 1890
*Billings, John Shaw	March 11, 1913
*Billroth, Albert Christian Theodor	January 5, 1894
Bontecou, R. B.	1906–1907
Briggs, William Thompson	June 13, 1894
Brinton, John Hill	March 18, 1908
Bristow, Algernon Thomas	March 26, 1913
Brock, Hugh W.	April 24, 1882
Bryant, Joseph Decatur	April 7, 1914
*Bryant, Thomas	1914–1915
Bull, William Tillinghast	February 22, 1909
Burrell, Herbert Leslie	1910
Byrd, William Andrew	August 14, 1887
Cabot, Arthur Tracy	November 4, 1912
Campbell, Henry Fraser	December 15, 1891
Cheever, David Williams	December 27, 1915
Cole, Charles Knox	February 27, 1920
Conner, Phineas Sanborn	March 26, 1909
Cunningham, Francis Deane	September 11, 1885
*Czerny, Prof. Dr. Vincenz	October 3, 1916
Dandridge, Nathaniel P.	1911–1912
Davis, Gwilym G.	June 16, 1918

* Honorary.

Name	Date of death
Davis, John Staige	July 18, 1885
Dawson, William Wirt	February 16, 1893
Dugas, Louis Alexander	October 19, 1884
Dunn, James Henry	June 16, 1904
Dunott, Thomas Justus	May 20, 1893
*Durham, Arthur Edward	May 7, 1895
*Erichsen, Sir John Eric	September 23, 1896
*von Esmarch, Friedrich	1907
Fenger, Christian	March 7, 1902
Ferguson, Alexander Hugh	October 20, 1911
Forbes, William Smith	December 17, 1905
Fowler, George Ryerson	February 6, 1906
*Friedrich, Paul Leopold	January 5, 1916
Gaston, James McFadden	November 17, 1903
Greene, W. Warren	September 10, 1881
Gross, Samuel David	May 6, 1884
Gross, Samuel Weissel	April 16, 1889
Gunn, Moses	November 4, 1887
*Gussenbauer, Karl	June 19, 1903
Guthrie, George Washington	June 1, 1915
Harrington, Francis B.	1914–1915
*Harrison, Reginald	1907
Hearn, W. Joseph	December 20, 1917
Hodge, H. Lenox	June 16, 1881
Hodgen, John T.	April 28, 1882
Homans, John	February 7, 1903
*Horsley, Sir Victor Alexander, C. B.	July 16, 1916
Horwitz, Orville	January 28, 1913
*Horwitz, Phineas J.	September 28, 1904
Hughes, J. C.	August 10, 1881
*Humphrey, Sir George Murray	September 24, 1896
*Hunt, William	January 5, 1897
Jacobson, Nathan	September 16, 1913
Johnson, Alexander B.	September 4, 1917

* Honorary.

Name	Date of death
Johnston, George Ben	December 20, 1916
Johnston, Christopher	October 11, 1891
King, Alfred	June 4, 1916
Kinloch, Robert Alexander	December 23, 1891
*Kocher, Theodor	July 27, 1917
Lane, Levi Cooper	February 18, 1902
*von Langenbeck, Bernhardt	September 30, 1887
Levis, Richard J.	November 12, 1890
*Lister (Lord), Joseph	February 11, 1912
Little, James Lawrence	April 4, 1885
Lutz, Frank Joseph	March 24, 1916
McCann, James	1893
McCosh, Andrew J.	December 3, 1908
McGuire, Hunter	September 19, 1900
*MacCormac, Sir William	December 4, 1901
MacDonald, Willis Goss	December 30, 1910
Mackenzie, Kenneth Alexander James	March 15, 1920
MacMonagle, Beverly	May 22, 1912
Markoe, Francis Hartman	1907
Marks, Solon	1916
Mastin, Claudius Henry	October 3, 1898
Mears, J. Ewing	May 28, 1919
Michael, J. Edwin	December 7, 1895
*Mikulicz-Radecki, John V.	
Miles, Albert B.	August 5, 1894
Millard, Perry H.	February 1, 1897
Miller, Truman W.	May 31, 1900
*Moore, Edward Mott	March 3, 1902
Moore, James E.	November 2, 1918
Mudd, Henry Hodgen	November 20, 1899
Mumford, James Gregory	October 18, 1914
Munro, John C.	December 6, 1910
Murphy, John B.	August 11, 1916
Norris, Basil E.	October, 1895
*von Nussbaum, J. N.	October 31, 1890

* Honorary.

Name	Date of death
*Ollier, Leopold	1900–1901
Oviatt, Charles W.	October 31, 1912
*Paget, Sir James	December 30, 1899
Pancoast, William H.	January 5, 1897
Park, Roswell	February 15, 1914
*Parker, Willard	April 25, 1884
Parkes, Charles T.	March 28, 1891
Parkhill, Clayton	January 16, 1902
*Péan, Jules E.	January 30, 1898
Peck, Washington F.	December 30, 1891
Pilcher, Paul Monroe	January 4, 1917
Porter, Charles Burnham	May 21, 1909
Porter, William Gibbs	January 30, 1906
*Pozzi, Samuel	1918
Prewitt, Theodore F.	October 17, 1904
Prince, David	December 19, 1889
Reed, Thomas Baird	April 1, 1891
Richardson, Maurice Howe	July 31, 1912
Richardson, Tobias Gibson	May 26, 1892
Rodman, William Louis	March 8, 1915
Sabine, Thomas Taunton	August 23, 1888
Sayre, Lewis A.	1900–1901
*Schede, Max	1902
Senn, Nicholas	January 2, 1908
*Sims, J. Marion	November 13, 1883
Squire, Truman Hoffman	November 27, 1889
Stewart, Francis T.	February 4, 1920
*Terrier, Louis Felix	1908
*Thiersch, Karl	April 28, 1895
Thompson, Joseph Ford	February 1, 1917
Thompson, Joseph W.	March 30, 1886
Thomson, William	August 3, 1907
Tiffany, Louis McLane	October 23, 1916
Varick, Theodore Romeyn	November 23, 1887
*Verneuil, Aristide A. S.	June 11, 1895
*von Volkmann, Richard	November 28, 1889

* Honorary.

Name	Date of death
Watson, Beriah Andrew	December 22, 1892
Weeks, Stephen Holmes	September 1, 1909
Weist, Jacob Rowland	May 14, 1900
*Wells, Sir Thomas Spencer	January 31, 1897
White, James William	April 24, 1916
Wight, Jarvis S.	November 16, 1901
Willard, DeForest	October 14, 1910
Wood, James R.	May 4, 1882
*Yandell, David Wendell	May 2, 1898

* Honorary.

REPORT OF COMMITTEE ON NECROLOGY

FRANCIS T. STEWART

Francis T. Stewart died suddenly from uremia at his home in Philadelphia, February 4, 1920. The day before his death he had carried on his work as usual and his death was consequently a great surprise and shock to his colleagues and his other friends.

He was born in Philadelphia in 1876 and graduated in medicine from Jefferson Medical College in 1896. He served as interne at the Philadelphia Polyclinic and Pennsylvania Hospitals and as chief resident physician in the latter. Subsequently he held many hospital positions and early became a teacher of surgery. His progress in surgery was rapid and deserved, for application and hard work were his striking characteristics. Among the early positions he held were those of surgeon to the out-patient department of the Pennsylvania Hospital, associate in surgery, Philadelphia Polyclinic, and chief of the surgical clinic of the Jefferson Medical Hospital. Later he was surgeon to the Germantown Hospital and professor of surgery at the Philadelphia Polyclinic. At the time of his death he was professor of clinical surgery at the Jefferson Medical College and surgeon to the Pennsylvania Hospital.

Early in his career he became a frequent contributor to surgical literature, making some eight contributions while still serving as a hospital interne. Among his notable later papers are those dealing with the surgery of the heart and bloodvessels, a field in which his experience was unusual. He wrote the section dealing with this subject in the *American Practice of Surgery* (1909). In 1907 was published his *Manual of Surgery*, which has passed through several editions, and is probably the best text-book of its size for students in the English language. Many of his best papers were read before this Association; the one dealing with his method of breast amputation, read at the meeting in 1915, is particularly worthy of note. Clearness of thought and terseness of expression characterized all of his writings.

Probably Dr. Stewart's most striking personal characteristics were frankness and honesty. These were so manifest at times as to

suggest brusqueness, or lack of consideration for the feelings of others, but never were so interpreted by those who knew him. As a surgeon he displayed a great deal of original and independent thought and, without being egotistical, did not allow the opinions of others to swerve him from a course of thought or action which he believed to be the right one. His judgment was always sound, and he was a skilful operator. In his earlier days he was a poor teacher, and realized it, but in his characteristic way he determined to overcome this deficiency, and at the time of his death he was one of the best and sanest of teachers. By application and hard work after his graduation in medicine he acquired an excellent working knowledge of both French and German.

Every Fellow of this Association who knew Dr. Stewart well will feel that in his death the Association and American surgery have suffered a great loss. J. H. G.

KENNETH ALEXANDER JAMES MACKENZIE, M.D.

Kenneth Alexander James Mackenzie, M.D., died in Portland, Oregon, his home, on March 15, 1920.

He was born in Cumberland House, Manitoba, Canada, January 13, 1859, son of Roderick Mackenzie, who was of Ross-shire, Scotland, and was Chief Factor, Hudson Bay Company, and Jane Mackenzie, daughter of Roderick Mackenzie. Dr. Mackenzie received his preliminary education in The Nest, Jedburgh, Scotland, and in Upper Canada College, Toronto, and his medical degree from McGill University, Montreal, in 1881. In 1882 he won the degrees of L.R.C.P. and L.R.C.S., Edin.

His professional career was begun in Portland, Ore., in 1882, where he continued in active practice until his death. He was professor of the theory and practice of medicine, University of Oregon Medical School from 1887–1906; professor of operative and clinical surgery (1906–1920) and also Dean of the faculty 1913 to 1920.

He was chief surgeon of the Union Pacific Railroad System in Oregon, 1895–1920, chief of staff, Sr. Vincent's Hospital, Portland, Ore., consulting surgeon, Port of Portland, and medical aide to the Governor of Oregon, 1917–19.

His first wife, Cora Hardy Scott, daughter of Pliny Hardy, of Opelousa, La., lawyer and Secretary of State of Louisiana, died in 1901. In 1905 he married Marion Higgins Brown, who died in 1916. Four children survive him.

Dr. Mackenzie led a most active life. In addition to carrying on an extensive private and clinic practice and manifold duties in the medical college, he found time for numerous other important activities: He was a director in the United States National Bank; director of the Lewis and Clark Exposition; State Chairman, Council of National Defense, Medical Section, 1916–19; State Chairman, American Red Cross, 1917–18. In 1906 he was head of the Oregon Relief Corps at the time of the San Francisco earthquake. Under Colonel Torney, afterward Surgeon-General, U. S. A., he established a temporary hospital in one of the school buildings of San Francisco which had escaped the fire.

With his wide acquaintance and his sterling character, being well known in his community, he was able to secure a large campus for the University of Oregon Medical School. He was a Fellow of the American Surgical Association from 1908; Fellow of the American College of Surgeons; Member of the International Surgical Association; Member of Portland City and County Medical Society (President, 1915), Oregon State Medical Association (President, 1915); North Pacific Surgical Association (President, 1919); Member of the American Thoracic Society; State Chairman of the American Society for the Control of Cancer.

One of his confrères writes: "Dr. Mackenzie was easily the leader in the medical profession of the entire Northwest, and not only that, he was also a man of great public spirit outside of his profession, and his loss was deeply felt by all of us."

E. R.

CHARLES KNOX COLE, M.D.

Charles Knox Cole, M.D., died suddenly at Pasadena, California, on February 27, 1920.

Dr. Cole was noted not only as a physician and surgeon, but was one of the rare examples of a man achieving distinction in three separate and widely different fields of endeavor—namely, as a physician and surgeon, as a law-maker and public official, and also as a leader in banking, manufacturing, mining and industrial circles.

He was born in 1852, at Plainfield, Illinois. Upon graduation from Lincoln University, where he received the degree of Bachelor of Arts and later that of Master of Arts, he took up the study of medicine and graduated from the Miami Medical College at Cincinnati in 1879. After postgraduate studies in New York and Chicago, and in the

hospitals of Paris, London, Berlin and Vienna, he began the practice of medicine in Helena, Mont.

Among medical honors held by Dr. Cole were Chief Surgeon Montana Central Railway, 1887; President of the American Academy of Railway Surgeons, 1894; Secretary and Treasurer of the American Association of the State Examining and Licensing Boards, 1892; Fellow of the American Surgical Association; Chairman of the Council, American International Congress on Tuberculosis, 1906; Member of the American Medical Association; Member of the Medical Association of Montana; and various offices were held by him in State and County Societies.

During the later years of his life Dr. Cole devoted his activities to manufacturing.

He was married in 1881 to Miss Harriet Gillett, of Jacksonville, Ill., and is survived by his wife, a daughter, Alma Gillett Cole, and a son, Dr. Philip Gillett Cole.

H. B. D.

PRESIDENTIAL ADDRESS

By GEORGE EMERSON BREWER, M.D.
NEW YORK

My first thought in addressing you this morning is one of gratitude and appreciation for the honor you have conferred upon me in electing me your presiding officer for this meeting; my second is a desire to extend a cordial greeting to the Fellows and our invited guests on this the forty-first annual conference of the Association; and my third is to express our united thanks to Dr. Mudd and his associates of the Local Committee of Arrangements for their painstaking efforts to provide for our comfort and entertainment.

It has always been the custom of our Association to allow the President a large measure of latitude in selecting the subject of his inaugural address, and while in the majority of instances the subjects presented have been strictly professional, in that they have dealt with some live surgical problem, on not a few occasions the topics chosen have been of historical or biographical interest, or have presented thoughts on medical education, professional ethics, public health or military preparedness.

That the interest of the surgical profession here and elsewhere has been acutely centered, during the past few years, upon the various military phases of our art, is evidenced by the large number of communications presented at our last meeting, which dealt with the treatment of battle casualties and with their associated infections; or the new and improved methods employed in the care of those who had been injured by the novel and cruelly destructive agencies of modern warfare, which by their diabolical ingenuity have far outclassed in their mutilating effects anything

which the world has ever known; and if it were not for the fact that in our present session a part of our program is made up of papers dealing with these same topics, I feel that I might have yielded to the strong impulse to present on this occasion some personal observations and experiences in front area work.

I have, however, elected to speak to you this morning upon two matters, not strictly germane to either the scientific or practical aspect of our professional work, but which I venture to hope may be of interest. The first is a report on the activities of the Fellows of this Association in war work, and the other is a consideration of the duties and responsibilities of the civil practitioner in time of war, or, perhaps to state it more definitely, the relationship between the Army Medical Corps and the trained civil surgeon when called to active military service.

When we consider that our Association embraces in its membership the great majority of the recognized leaders of surgery in America, that owing to the conditions of fellowship, over 90 per cent. of its active members are well above the military age and were under no moral obligation to enter the Government service, it is a matter of genuine pride and satisfaction to know that over 83 per cent. of our Fellows promptly volunteered and gave generously of their time and effort to the cause. I know of no other body of men of equal standing in the community who gave so much and at a greater sacrifice of personal interests.

It is fitting therefore that some record of their activities be preserved and made a part of our Association Archives, not only to record the historical facts but to furnish an example to those who may follow, in the event of another and similar national emergency.

I have therefore attempted to collect all available data as to the service rendered by members of this Association, and will give you a brief summary of the result.

The total number of Fellows, active and senior, who offered their services to the Government or engaged in actual war work was 153, the average age of these was 56½ years. It is worthy of note that of the 33 Senior Fellows, 25 volunteered or engaged in active service, the average age of this group being 70.

Number holding commissions in the U. S. Army including two contract surgeons	96
Number holding commissions in the British Army	4
Number holding commissions in Canadian Army	6
Number holding commissions in French Army	1
Members of the Reserve Corps, who volunteered but were not called to active duty, or were rejected on account of age or physical disability	6
Volunteer surgeons serving with British Army previous to 1917	5
Volunteer Surgeons serving with French Army previous to 1917	13
Commissioned Officers in the U. S. Navy	8
Fellows serving in the Red Cross Society	12
Fellows serving in the Medical Advisory Committee of the Council of National Defense	8
Enrolled in the Volunteer Medical Service Corps	11
Serving in local military or examining boards, State organizations or detailed to give instruction in military surgery	34

Of the 107 who held commission in our own or one of the Allied armies, there were:

Brigadier General	1
Colonels	25
Lt. Colonels	37
Majors	31
Captains	7
1st Lieutenants	4

In two instances the rank was not mentioned.

Of these, 57 served in France with the A. E. F., 48 in the United States and 11 in the French or British armies. As a number of officers served at different times in two or more of the Allied armies, and in different organizations in our own army, the total in this and the following groups obviously will not correspond to the exact number of commissioned officers:

Number serving in Base or General Hospitals	55
Number serving in Evacuation or Casualty Clearing Stations	12
Number serving in Mobile Hospitals	3
Number serving in Camp Hospitals	6
Number serving as Heads of Surgical Teams	19
Number serving as Consultants	26
Number serving at Headquarters in Washington	8
Number serving at Headquarters A. E. F.	2
American Delegates to Interallied Surgical Conference in Paris	6
Fellows receiving one or more promotions	77
Fellows receiving decorations	22
Fellows receiving citations	10
Fellows mentioned in Dispatches	4
Fellows serving in front area during one or more of the great battles	47

This is but a brief and incomplete statement of the actual service rendered by our members, and is introduced here merely to give a general idea of the important and responsible positions they held during the World War. I have prepared a fuller record of the services rendered by each of the fellows, which will be appended to this address and published in the *Transactions*.

Let us now consider my second topic, the duties and responsibilities of the trained civil surgeon when called to active military service.

That he has a definite responsibility cannot be questioned when we consider that in time of war or active mobilization the Medical Corps of the Army is of necessity greatly augmented by the enlistment of men from the reserve corps and from civil practice. To illustrate the extent of this augmentation, allow me to call attention to the fact that at the time of our declaration of war the Medical Corps of our Army consisted of about 500 medical officers. At the time of the Armistice the number of commissioned medical officers was considerably over 30,000, which indicates that at that time more than fifty-nine sixtieths of the medical service of the army was rendered by civilian practitioners, including surgeons, internists, sanitary experts, laboratory workers and other specialists.

The chief function of the Medical Corps of an Army is to render the best possible sanitary service to the troops, to keep them in the best physical condition and to provide individual care and skilled professional attention for the sick and injured.

During peace this is not difficult; the number of sick and injured is small, the skill and experience of the officers are well known and they easily can be assigned to duties which they are qualified to assume. In time of war or active mobilization, however, the problem is far more difficult, for it necessitates a complete reorganization of the Corps; the assimilation of thousands of new men who are ignorant of army routine and whose professional qualifications are to a large extent unknown.

When we consider the magnitude of the problem and the difficulties under which the Surgeon-General labored during our

recent mobilization the marvel is that so much in the way of efficient organization was accomplished.

Laying aside for the moment the activities of the medical, sanitary, laboratory and special departments, what was the chief surgical problem to be solved? I take it you will all agree with me that it was to render prompt and skilled surgical care to the man wounded in battle. The man who has the courage, patriotism and determination to go into battle and give every ounce of energy and strength which he possesses to defeat the enemy, who cheerfully faces death and the chance of mutilating and disabling injury, is certainly entitled, when wounded, to the best surgical skill which his Government is able to provide. If he receives anything less than this he is not getting a square deal.

How best can this be accomplished, to what extent was this accomplished in our Army during its participation in the great war? In answering the first question, I believe that one of the most important factors is to avoid *misfits*. By that I mean men who are assigned to duties they are not qualified to fulfil or retained in such positions after their unfitness has been demonstrated. To obtain the best results only men of adequate surgical training and of large experience should be selected as operating surgeons in advanced hospitals where the wounded receive their first surgical treatment; and the work of these men should under no circumstances be hampered or interfered with by men of higher rank but without skill, training or experience in modern surgical procedures. Likewise in the base hospitals to which the wounded are quickly transferred from the front area there should be a sufficient number of trained surgeons to oversee and direct the work of a larger number of junior officers, younger men, who have had at least some preliminary training in modern surgical technic.

That this ideal arrangement has not been generally carried out in the past will be evident to anyone who will take pains to read the medical and surgical histories of any of the great wars of modern times. In the majority of instances these failures have been due, not to indifference on the part of a Government

to the fate of its wounded soldiers, but to misfits in the professional personnel; expert surgeons who are assigned to purely executive duties, medical men who are assigned to responsible surgical posts; oculists, aurists, dermatologists and roentgen-ray operators who are obliged to work in medical or surgical wards or in some speciality not their own, when their skill is urgently needed elsewhere; men well trained in laboratory methods but without experience in clinical work, obliged to give their entire attention to clinical problems.

All of these misfits I have personally observed in innumerable instances, have watched their bungling unproductive work and have listened to a recital of their many efforts made through channels to be given work which they felt themselves competent to carry out. I am not now speaking alone of our Army, but of experiences gathered while serving with the French or British forces; and I think it only fair to state that while numerous examples could be pointed out of such misfits in our own organization, my observations lead me to believe that there were fewer such instances in the A. E. F. than in the other Allied forces; and that it was far easier with us to effect satisfactory transfers, largely through the cordial relations which existed between our chief surgeon and the commanding officers of our sanitary groups.

One of the causes of this difficulty in the past has been due to the fact that ranking officials in the administrative bureaus, while perhaps possessing expert ability in executive matters, fail to recognize how highly specialized medicine has become during the past half-century; to realize that the battle casualties of modern warfare present in perhaps the majority of instances the gravest of surgical problems, and to appreciate how utterly futile it is to expect these problems to be successfully met by men without or with but limited training or experience. As one British officer stated. "The men at headquarters feel that every man possessing a medical diploma is capable of any and all kinds of professional work."

Another and perhaps the chief cause of misfits is the appointment of men to positions of grave professional responsibility on

account of rank or previous service rather than professional qualifications. But the question is asked how could this be otherwise without demoralizing the morale of the corps. The army is an organization into which men enlist for life. They begin at the bottom and gradually work their way to the higher ranks by years of painstaking conscientious work, and when a man of mature age, after fifteen to twenty years of faithful service, reaches the rank of Major, Lieut.-Colonel or Colonel is he not qualified to accept grave responsibility, and in the event of war, is it fair that he should be cast aside and replaced by a civilian who has never served in the Regular Army and knows nothing of military routine.

Let us meet the issue squarely and consider it from every angle, bearing in mind the paramount duty of the Government, which is to render to the wounded soldier the best possible surgical skill.

In the Regular Army the medical officer at the time of his enlistment is a highly qualified man but with limited experience. During the first eight to ten years of his service he is assigned to one or several military posts, where he has the care of a limited number of physically fit men and the families of the officers. Between these assignments he may be stationed at a military hospital, where he may have purely administrative duties, or may serve in medical or surgical wards. At other times he may have bureau work at Washington or at some Divisional Headquarters. As he advances in rank he is given more responsible duties of an administrative character with a progressive diminution in actual professional work. As one major expressed it to the writer: "I have been seventeen years in the service. During my first six years my work was largely professional, during the next four or five years it was about equally divided between professional and administrative duties, and for the past six years I have had practically no professional responsibility."

Certainly, the army in peace time is not an ideal school for the training of surgeons, and while there are, of course, notable exceptions of men who have had long periods of service in hospitals on account of special aptitude for medical, surgical or

special work, the opportunities for intensive surgical training are few and the majority of army surgeons who have served perhaps fifteen or more years, and have reached the rank of Major or Lieut.-Colonel, while they may be expert administrative officials, cannot be regarded as highly qualified modern surgeons. Such an experience cannot qualify even the most gifted man to meet the emergencies or assume the grave responsibilities of treating battle casualties.

With the recent civilian graduate who has chosen surgery as his special life-work it is different. From the time he leaves the medical school his entire energy is directed in a single channel. He passes through the positions of surgical intern, house surgeon or resident surgeon, out-patient surgeon, assistant surgeon to the wards, associate or junior surgeon; and at the age when our military surgeon reaches the rank of Major or Colonel the civilian practitioner, if capable and industrious, has reached the goal of his ambition, is an attending surgeon to some hospital, a position gained by fifteen to twenty years of continuous, intensive surgical training.

If in the necessary reorganization of the Army Medical Corps in time of war, the general policy was followed of selecting highly qualified civilian surgeons, but without army experience, to positions of purely professional responsibility, where a knowledge of army administrative methods is not essential; and of the highly qualified members of the regular corps to positions of high administrative command, where their knowledge and experience are most needed, it would provide promotion and dignified positions for all the capable ranking men of the service, and would in no way tend to demoralize the morale of the department. It would also prevent in a large measure the misfits to which I have alluded, and would be the greatest factor in providing for the wounded soldier the highest type of surgical skill.

This was the general policy in our army during the recent war; but with a less enlightened and broad-minded Surgeon-General it might not be the policy in a future war. Moreover, the line was never definitely drawn between administrative and profes-

sional control, and most of us who served in France saw examples of men of high rank holding executive positions, issuing orders which if carried out to the letter would have sadly interfered with the orderly carrying on of modern surgical procedures.

This brings me to the second factor in accomplishing the highest degree of professional service to the wounded man; and that is, the plan of dual control in all hospitals and all organizations in which the medical department has important activities. I realize that the term dual control of any military formation will be said to be a blow at the very foundation of military discipline. Yet I venture to approve the plan for the reason that I believe it to be fundamentally sound, that it was first suggested and put into operation by our own Surgeon-General, and also for the reason that I think it can be shown that by a reasonable interpretation it will not affect or interfere with military discipline in the slightest degree.

It will be recalled that long before we entered the war the Surgeon-General authorized the organization of fifty Red Cross Base Hospitals, with the understanding that in the event of war they would be taken over by the War Department and made an integral part of the army. The plan of organization was to supply for each a Commanding Officer appointed from the medical corps of the Regular Army, who would have complete administrative and disciplinary control of the unit, and a Director who would be responsible for the actual care of the patients. By this plan these hospitals were placed on the same basis as our own best civil hospitals, in which the Board of Trustees or administrative department is entirely separate from the professional, and in no way interferes with or attempts to dictate the scientific activities of the professional staff, but at all times is in absolute control as they have the power of appointment and removal.

The success of the plan was, I think, generally admitted. In the unit to which I was attached, and in a number of others in which there was a reasonable coöperation between the commanding officer and director there was not the slightest friction

and no question of authority was ever raised. The director recognized that the commanding officer was his superior officer, and the commanding officer recognized the professional responsibilities of the director and never interfered with the clinical work of the unit.

In the late autumn of 1917 orders were sent from Washington to the A. E. F. to organize a group of professional consultants to take over the responsibility of the care of patients in the various divisions as they became ready for active duty. Without going into detail in regard to the organization of this group, with which you doubtless are all familiar, I may briefly state that there was a chief consultant in surgery, a chief consultant in medicine, and a chief consultant in the laboratory specialities. Under each of these departments there were a number of subdivisions, those in surgery being:

General surgery.
Orthopedics.
Urology.
Otology and laryngology.
Ophthalmology.
Faciomaxillary surgery.
Neurological surgery.
Experimental surgery.

Special divisional consultants were first appointed in general surgery, orthopedic surgery and urology. Later, consultants in medicine, neurology and some of the other specialities were appointed to divisional, corps and army headquarters. At a still later period, surgical consultants were sent to a number of the large base hospital centers, where they would direct and supervise the professional work of the various hospital units.

Shortly after the creation of the consulting board, the chief surgeon of the A. E. F. authorized the chief consultant in surgery to organize surgical teams for active service at the front, relying upon his judgment in the selection of the officers to head each team. More than one hundred such teams, representing the best surgical talent in the overseas army, were organized and

sent to the front to take over the operative work in the evacuation and advanced hospitals in the three or four great battles in the summer and autumn of 1918.

During this active period the chief consultant arranged frequent conferences in which a number of front area divisional or corps consultants took part, and at these meetings general rules regarding the surgical care and operative treatment of the various types of battle casualties were freely discussed and adopted, and instructions issued to all consultants to be transmitted to the heads of the surgical teams. These instructions in general conformed with the suggestion issued by the Interallied surgical conference, modified to some extent by the experience of our own men.

While few of our operating surgeons heading surgical teams had had any experience in the treatment of battle casualties, they were nearly all men of experience, with adequate surgical training, and in not a few instances had had opportunities to observe the best type of military surgical procedures in some of the best French, English and Belgian hospitals as well as in our own Evacuation Hospitals Nos. 1 and 2, which were organized early, in quiet sectors, and in which some of our most experienced men were operating and giving instruction in the technic of modern military surgery. This and the fact that nearly all of our consultants in the front area had had previous experience in the British, French or Belgian Armies made it possible for our advanced hospitals to render such excellent service during the periods of great activity.

While I would not have you believe that this advanced service in any way approached perfection, I think I can truthfully say that, taken as a whole, it was better than I had previously observed in any sector of the same size during a period of active military operations. When failure or disaster occurred it was not the result of lack of skilful operative measures, but was rather due to overcrowding, delayed transportation and absence of forethought in providing adequate hospital accommodations, teams,

nurses and supplies. In other words it was due to administrative rather than professional errors.

From this brief statement regarding the general plan of dual control I feel that you will all agree that it represented a wise and honest attempt on the part of our Surgeon-General to improve the quality of the service rendered to our wounded men. That it was not more satisfactory in its operation was due to a number of circumstances.

In the first place the plan should have been carefully considered and its organization thoroughly effected before we entered the war.

Specific regulations should have been adopted defining the duties of the administrative and professional chiefs, so that there should be no conflict of authority.

Copies of these regulations should have been sent to all commanding officers, and to chief divisional, corps and army surgeons well in advance of assigning consultants to duty.

The official orders to consultants should have been uniform, explicit and delivered at the time of appointment.

Had this been done, the status of the consultant would have been established. As it was, the arrival of the consultant at divisional headquarters was often the first intimation the chief divisional surgeon had that such a position had been created; and if, as frequently happened, the consultant's orders were not explicit, his presence was resented and looked upon as an attempt to destroy the prestige and undermine the authority of the divisional chief. In a few instances this resulted in open hostility and complete lack of coöperation, rendering the consultant's position extremely trying and greatly interfering with his usefulness.

Lack of uniformity or great delay in issuing orders was a frequent source of misunderstanding. On more than one occasion I was sent to various parts of the line without any written orders. At other times my orders would read "Will proceed to this or that headquarters and report to the divisional or corps surgeon." On other occasions my orders would be explicit and state "Will proceed to ——— Division; will supervise and direct

the surgical work in all divisional hospitals and all evacuation hospitals assigned to or situated in that sector; operate himself when deemed advisable and in general carry out the orders of the chief surgeon A. E. F. and chief consultant in surgery," thus clearly indicating that in professional authority he was responsible only to the chief consultant or the chief surgeon of the Expeditionary Force.

When we consider that the plan was an entirely new one, was not mentioned in the *Manual*, was hastily considered in Washington and transmitted to the A. E. F. without definite instructions, that no definite rules were established for its operation, that orders were not uniform, were frequently vague and often greatly delayed, and that the line officers were generally left in complete ignorance of the plan and the status and authority of the consultants, it is a marvel that it succeeded as well as it did. In my opinion its limited success was due to the vision and broad-minded attitude of General Ireland and his able assistants at the Chaumont Headquarters and to the honest efforts of the consultants themselves and the hearty and intelligent coöperation of the majority of the regular officers.

I am thoroughly convinced that had the war lasted another six months and had General Ireland's wise policy been continued in the A. E. F., after his promotion to the position of Surgeon-General, all obstacles would have been overcome and the American system of professional control would have been declared an unqualified success.

In these few remarks I have attempted to answer briefly the two questions propounded in the opening paragraphs of this part of my address, but there is now another and more important question to be considered, and that is, what in the light of our past experience can be done now to ensure better treatment for our wounded men in the event of another war or to provide better care of our mobilized men if laws should be enacted authorizing universal military training?

In answer to this question permit me to say that in my opinion we cannot do better than to adopt in principle the plan of dual control proposed by our Surgeon-General.

I sincerely believe, as stated above, that it is fundamentally sound, and the only plan that will ensure to the wounded the highest degree of professional service.

That it was far from perfect in its operation during the late war we will admit, but its imperfections and disadvantages were trivial in comparison to the advantages it presented and easily could be remedied by more perfect organization. While doubtless it would be desirable to modify to some extent the regulations in force during the war, the plan should be essentially the same and should embody the appointment of a chief consulting surgeon, a man of the broadest experience chosen from the civilian profession, possessing the highest qualities of surgical judgment and technical skill, who has had previous military experience, and who is also possessed of organizing ability. His headquarters should be in the office of the Surgeon-General, and to him all questions dealing with the actual surgical care of patients should be referred for his expert advice. That this chief consultant should have a number of deputies or assistant chief consultants, also men of conspicuous surgical ability and large experience. One of these to be assigned to headquarters of each army to coöperate with the administrative chief of the medical service. Under this deputy chief consultant there should be an adequate number of active consultants who could be assigned to corps or divisional areas in charge of the surgical work of the various hospital units, and who would be responsible through the army and chief consultant to the Surgeon-General for the carrying out of the most approved modern surgical methods in the treatment of the wounded men. This plan would obviously include a similar organization of the departments of internal medicine and sanitary service, with as many subdivisions of each as would be found to be necessary.

This, I beg you to bear in mind, is but the expression of my own personal view. I do not suggest it as a plan to be blindly followed or adopted without the fullest and freest discussion, in a conference composed of Regular Army officials and civilian practitioners who have had actual military experience; but I

think that the time is now ripe for such a conference and interchange of views, and that now in time of peace some plan should be worked out to give to the American Army the best professional service which it is possible to organize, which will ensure to the sick or injured soldier the same degree of professional skill that he could receive in the best organized and equipped civil hospital in the country.

While such a plan would be an emergency measure, and while the consulting staffs would be members of the Reserve Corps, and not on duty in peace time, it should be organized now, down to the last detail, so that in the event of our country facing another military crisis it would not be necessary to devise ways and means to meet the emergency in haste, during a period of stress, excitement, anxiety, and feverish activity.

I do not feel that we as an association of civilian surgeons should apologize for considering this problem, or should hesitate to offer to the military authorities our suggestions on a subject which so deeply concerns us. If in time of war we are to bear such a large proportion of the burden of responsibility, we are certainly entitled to a voice in the making of plans and regulations under which we are to assume it. It is for this reason that I have brought this matter to your attention this morning. I have been so overwhelmingly impressed with the importance of this subject that it seems to me it would be a gross neglect of duty if I were to have chosen for this address another and perhaps more conventional topic.

My message comes from the heart of one who has been an eye-witness to the monstrous and cruel toll in mortality and wrecked lives which war inflicts upon the flower of the youth and promising manhood of a nation; and I urge upon you as members of the most distinguished group of surgeons in America to be prepared, if the opportunity is offered, to coöperate with our Government officials in proposing some enlightened plan which will raise the standard of our military medical service to a plane never before reached in the world's history.

Record of Service during the World War of Members of the American Surgical Association

Active Fellows

Dr. E. Wyllys Andrews, U. S. Army, commissioned Major 1917. Not on active service.

Dr. Edward W. Archibald, Canadian Army, commissioned Major October, 1914. Served in General Hospital No. 3 at Camiers, France, B. E. F., and later at Boulogne; Surgical Specialist at No. 1 Canadian Casualty Clearing Station at Bailleul.

Dr. George E. Armstrong, Canadian Army, commissioned Lt.-Col. 1916. Consulting Surgeon with Headquarters at London, England. Made several official trips to France. Promoted to Colonel. Decoration: C.M.G.

Dr. Astley P. C. Ashhurst, U. S. Army, commissioned Major June, 1917, promoted to Lt.-Colonel June, 1918, to Colonel November, 1918. Director of Base Hospital No. 34; Chief of Surgical Team No. 23; Consultant in General Surgery to Hospital Centers at Savenay, St. Nazaire, Nantes and Camp Hospitals at Coetquidan and Meucon. Returned to U. S. January, 1919, and served as Chief Surgeon to Walter Reed Hospital. Served at front with French Army at Crevecour and with U. S. Army at Cantigny, Montdidier, during the second battle of the Marne, St. Mihiel and Argonne offensives. Citation April, 1919.

Dr. David Barrow, U. S. Army, commissioned Major June, 1917. Director of Base Hospital No. 40. Served at Base Hospitals at Bazoilles and Toul. Promoted to Lt.-Colonel. At front during St. Mihiel drive. Citation.

Dr. Frederick A. Besley, U. S. Army, commissioned Major April, 1917. Director of Base Hospital No. 12. Later Consultant in Surgery, A. E. F. Served at front with Second Army Corps. Promoted to Lt.-Colonel. Citation.

Dr. John F. Binnie, U. S. Army, commissioned Major September, 1917. Director of Base Hospital No. 28; Consulting Surgeon to Third Corps, and later at Limoges Hospital Center. Served at front with First Army Corps at Château-Thierry, and Third Army Corps in Argonne. Promoted to Lt.-Colonel.

Dr. Vilray P. Blair, U. S. Army, commissioned Captain April, 1917. Served at Base Hospital at Ft. Oglethorpe. Later as Chief of Oral and Plastic Surgery, Division of the Head in Surgeon-General's Office. Also as Senior Consultant in Maxillo-Facial Surgery, A. E. F. Served at front during battle of Château-Thierry and Argonne. Promoted to Major and later to Lt.-Colonel.

Dr. Joseph A. Blake, U. S. Army and American Ambulance Service in Paris, commissioned Major July, 1917. Later promoted to Lt.-Colonel and Colonel. Served from August, 1914, to February, 1919; in American Ambulance in Paris; in Hospital V. R. 76 Ris Orangis as Medecin Chef; later in Charge of American Red Cross Hospital No. 2, Paris, and in November, 1918, appointed Consulting Surgeon for Paris Area. Decorations D.S.M. and Chevalier Legion d'Honneur.

Dr. Joseph C. Bloodgood, U. S. Army, commissioned Major December, 1917. Medical Aide to Governor of Maryland; Senior Consultant and Commissioner in Surgeon-General's Office.

Dr. John T. Bottomley, U. S. Army Reserve Corps. Captain 1914. President of Examining Board for Officers for Boston.

Dr. George E. Brewer, U. S. Army, Commissioned Major April, 1917. Director of Base Hospital No. 2; Consulting Surgeon to the 42d Division, the 5th Division and Chief Consulting Surgeon to the First Corps First Army. U. S. Delegate to Interallied Snrgical Conferences 1917, 1918 and 1919. Present at British Offensive in Flanders, 1917, as Head of Surgical Team; also served at Battles of Chalons, Château-Thierry, St. Mihiel and Argonne. Volunteer Surgeon with French Army as Medecin Chef of Hospital B, American Ambulance, at Juilly, Seine et Marne, 1915. Promoted to Lt.-Colonel and Colonel. Citation April, 1919.

Dr. William B. Brinsmade, U. S. Navy, commissioned Lt.-Commander April, 1917. Organized Base Hospital No. 1, U. S. N.; Surgical Director at Brest; Charge of pavilion, French Hospital at Orleans; Surgical Director, Base Hospital No. 202 at Orleans; Surgical Director, Mobile Hospital No. 7; Surgical Consultant, Brest Group of Hospitals. Served in front area with Mobile Hospital No. 7. Promoted to Commander. Citation.

Dr. Herbert A. Bruce, Canadian Army, commissioned Lt.-Colonel April, 1915. Inspector General, C.A.M.C. Later Consultant Surgeon, B. E. F., in France. Served in Casualty Clearing Stations during most of the great battles in 1917 and 1918. Promoted to Colonel. Twice mentioned in dispatches by Marshal Haig.

Dr. John J. Buchanan, Chairman of Medical Advisory Board, Mercy Hospital, Pittsburgh, Pa.; Chairman of Auxiliary Committee for National Defense of Allegheny County, Pa.; Member of Pennsylvania State Committee of National Defense; Chairman of State Committee for Pennsylvania Volunteer Medical Service Corps.

Dr. Frank E. Bunts, U. S. Army, Commissioned Major June, 1917. Chief of Surgical Service Base Hospital, Camp Travis, Texas; Commanding Officer, Base Hospital No. 4, A. E. F. Promoted to Lt.-Colonel.

Dr. Alexis Carrel, French Army, commissioned 2d Lt. 1901. Served in front area from 1915 to 1918. Promoted to 1st Lt. to Captain to Major. Decorations: Commandeur Legion d'Honneur and several others. Developed the Carrel-Dakin method of wound treatment.

Dr. Ernest A. Codman, U. S. Army, commissioned Major August, 1918. Served as Post Surgeon, Regimental Surgeon, and Chief of Surgical Service of Base Hospital in U. S.

Dr. William B. Coley, U. S. Army, commissioned Major July, 1917. Not called to active duty. Gave instruction in hernia operations.

Dr. Frederick J. Cotton, U. S. Army, commissioned Major January, 1917. Served at Walter Reed Hospital and General Hospital No. 10, U. S.

Dr. George W. Crile, U. S. Army, commissioned Major April, 1917. Director of Base Hospital No. 4; Senior Consultant, Surgical Research, A. E. F. Served in front area during British offensive in Flanders 1917, Messines, Passchendaele, third battle of Ypres and in the Argonne and Meuse offensives. Promoted to Lt.-Colonel to Colonel. Decorations: D.S.M., and Companion of the Bath by British Government.

Dr. Harvey Cushing, U. S. Army, commissioned May, 1917. Director of Base Hospital No. 5; Senior Consultant in Neurological Surgery, A. E. F. Served in front area July to November, 1917, Passchendaele-Messines offensive, also at Pernes during German offensive in Lys sector; at Château-Thierry, Champagne operations, St. Mihiel and Argonne offensives. Promoted to Lt.-Colonel to Colonel. Decorations: Companion of Order of Bath by British Government.

Dr. John C. Da Costa, U. S. Navy, commissioned Lt.-Commander March, 1912. Hospital duty in the United States and Transport Service. Promoted to Commander.

Dr. William Darrach, U. S. Army, commissioned Captain May, 1917. Surgical Chief of Base Hospital No. 2; Surgical Director of Base Hospital No. 2; Commanding Officer, Base Hospital No. 2; Head of Surgical Team; Consulting Surgeon to the 42d Division; Assistant Consultant, 1st Corps, First Army; Senior Consultant in Surgery, Third Army. Served in front area during British offensive in Flanders 1917; also in battles of Château-Thierry, St. Mihiel, Argonne and with the Army of Occupation. Promoted to Major to Lt.-Colonel to Colonel.

Dr. Carl B. Davis, in charge of course of intensive training for military officers in Chicago. Also placed on essential list to keep up surgical work at Rush Medical College.

Dr. John S. Davis, U. S. Army, commissioned Captain April, 1917. President of Examining Board, Medical Corps for Maryland. Was prevented from going with Base Hospital No. 18 on account of physical disability.

Dr. Lincoln L. Davis, U. S. Army, commissioned Major June, 1917. Chief Surgical Service Base Hospital No. 6; Head of Surgical Team; Consulting Surgeon to A. E. F. in Italy and later Commanding Officer Base Hospital No. 6. Served in front area at Vittorio-Veneto on Piave, Italy. Promoted to Lt.-Colonel.

Dr. Harry C. Deaver, Chairman of Medical Advisory Draft Board.

Dr. John B. Deaver, U. S. Army Medical Reserve Corps. Not on active service. Promoted from Captain to Major.

Dr. Henry B. Delatour, U. S. Army, commissioned Major January, 1918. Chief of Surgical Service at Camp Upton.

Dr. Charles N. Dowd, U. S. Army, commissioned Major, June, 1917. Chief of Medical Department Selective Service State of New York; Medical Aide to Governor of New York. Instructor to groups of military surgeons at Roosevelt Hospital. Organized complete reserve unit for Base Hospital No. 15.

Dr. William A. Downes, U. S. Army, commissioned Major October, 1918. Chief, Surgical Service, Camp Jackson; Chief Surgeon, Camp Upton.

Dr. Joseph R. Eastman, U. S. Army, commissioned Major November, 1917. Aide to Governor of Indiana. Member of General Medical Board Council of National Defense.

Dr. Ellsworth Eliot, Jr., U. S. Army, commissioned Major April, 1917. Chief Surgeon, Evacuation Hospital, A. E. F. Served in front area at Château-Thierry and Argonne.

Dr. Arthur W. Elting, U. S. Army, commissioned Major August, 1917. Director, Base Hospital No. 33. Served in front area during battles of Château-Thierry, St. Mihiel, Argonne, Champagne and Flanders. Promoted to Lt.-Colonel.

Dr. Duncan Eve, Member of General Board of National Defense; Volunteer in Medical Service Corps. Served in Surgeon-General's Office.

Dr. J. M. T. Finney, U. S. Army, commissioned Major May, 1917. Director of Base Hospital No. 18; Chief Consultant in Surgery, A. E. F. Present at several great battles in 1918. Promoted to Lt.-Colonel to Colonel to Brigadier-General. Decorations: D. S. M., Commandeur de l'ordre de la Couronne, Officier de la Legion d'Honneur. U. S. Delegate to Interallied Surgical Conference, 1917–1918.

Dr. Joseph M. Flint, U. S. Army, commissioned Major July, 1917., Council of National Defense Medical Board; Commanding Officer, Base Hospital No. 39; Commanding Officer, Mobile Hospital No. 39. Liason officer Chief Surgeon, 12th region, French; Liason

officer, French War Office for Mobile and Sanitary formations. Was largely instrumental in organizing mobile hospitals for A. E. F. Served in front area at Aisne offensive and also at St. Mihiel and November offensives with Second Army. Promoted to Lt.-Colonel to Colonel. Citations: D. S. M.; Officier Instruction Publique from French Government.

Dr. Charles H. Frazier, U. S. Army, commissioned Major March, 1918. Chief Neurological Service, General Hospitals No. 11 and No. 41; Consultant in Neuro-Surgery, Surgeon-General's Office. Promoted to Lt.-Colonel.

Dr. Leonard Freeman, Volunteered for Army Service but refused on account of age. Served on State Committee of National Defense.

Dr. Homer Gage, U. S. Army, commissioned 1st Lt. March, 1917. Assigned to Base Hospital at Camp Devons and later Chief of Surgical Service at Camp Devens. Promoted to Captain to Major to Lt.-Colonel.

Dr. Otto C. Gaub, Member of Medical Advisory Board, Allegheny Hospital, Pittsburgh, Pa.

Dr. John H. Gibbon, U. S. Army, commissioned Major May, 1917. Surgical Chief of Base Hospital No. 10; Later Consultant in Surgery, 1st Division, 26th Division and Chief Consultant in Surgery, Third Corps. Served in front area during British offensive in Flanders in 1917 and St. Mihiel offensive in 1918. U. S. Delegate to Interallied Surgical Conference, 1919. Promoted to Lt.-Colonel to Colonel.

Dr. Charles L. Gibson, U. S. Army, commissioned Major April, 1917. Director of Base Hospital No. 9. Served in France from July, 1917, to February, 1918.

Dr. Robert B. Greenough, U. S. Navy, commissioned Lt.-Commander July, 1917. Stationed at U. S. Naval Hospital at Chelsea, Mass., as Surgeon, later as Chief of Surgical Service. Served as Volunteer Surgeon in American Ambulance at Paris, 1915. Promoted to Commander and Medical Inspector.

Dr. William D. Haggard, U. S. Army, commissioned Major May, 1917. Medical Aide to Governor of Tennessee. Advisory Board, General Surgery, Surgeon-General's Office. Served as Consulting Surgeon at Mesves Hospital Center, France; served in front area with Evacuation Hospital at Toul, November, 1918, to December, 1918. Promoted to Lt.-Colonel.

Dr. Albert E. Halsted, U. S. Army, commissioned Major 1917. Chief of Surgical Service Base Hospital at Camp Hancock and at Base Hospital No. 53, A. E. F. Served in front area at Toul July and August, 1918. Promoted to Lt.-Colonel.

Dr. Carl A. Hamann, acted as Chairman of Ohio State Council of National Defense, Medical Section; appointed Instructor to medical officers.

Dr. M. L. Harris, appointed by President and Governor Medical Member of Appeal Board, Northern District of Illinois. Member of Medical Committee of Council of National Defense.

Dr. Richard H. Harte, U. S. Army, commissioned Major May, 1917. Director of Base Hospital No. 10. Later Commanding Officer of Base Hospital No. 10; Head of Surgical Team. Served in front area during British offensive in Flanders in 1917; served as Volunteer Surgeon with French Army in American Ambulance in Paris, 1915. U. S. Representative to Interallied Surgical Congress, 1917 and 1918. Promoted to Lt.-Colonel to Colonel. Decorations: C.M.G., British Government; mentioned in dispatches by Marshal Haig.

Dr. John A. Hartwell, U. S. Army, commissioned Major June, 1918. Director of Course of Instruction in Fracture and War Surgery at Bellevue Hospital. Served as National Advisor of Surgical Supplies, American Red Cross; served in front area with Chief Surgeon, First Army, during Argonne offensive, also in Evacuation and Field Hospitals.

Dr. Edward B. Hodge, U. S. Army, commissioned Lt. March, 1917. Served at Base Hospital No. 10. Commanded Mobile Hospital No. 8. Served in front areas at Amiens and in the Argonne-Meuse offensive. Promoted to Captain, to Major to Lt.-Colonel.

Dr. Lucius W. Hotchkiss, U. S. Army, commissioned Major January, 1918. Member of Alternate Staff, Base Hospital No. 15. Not called to active service.

Dr. Joshua Hubbard, U. S. Army, commissioned Major January, 1918. Chief of Surgical Service of Base Hospital at Camp Greene; Base Hospital No. 85, A. E. F.; Evacuation Hospitals Nos. 1 and 37, A. E. F. Promoted to Lt.-Colonel.

Dr. Frank L. Hupp, appointed January, 1918. Member of Medical Advisory Board of West Virginia; Council of National Defense, Medical Section. Prevented from active service on account of illness.

Dr. James A. Hutchinson, Canadian Army, commissioned Lt.-Colonel February, 1916. Served in General Hospitals in France and later Consultant in Surgery in England. Promoted to Colonel. Decoration: Commander of the British Empire.

Dr. James P. Hutchinson, U. S. Army, commissioned Major July, 1917. Served as Volunteer Surgeon with French at American Ambulance, Paris, 1915, 1916 and 1917. Later Chief Surgeon to Military Hospital No. 1; Commanding Officer of Military Hospital No. 1. Promoted to Lt.-Colonel to Colonel.

Dr. Robert W. Johnson, Member of Local Draft Board No. 4, Baltimore City, Md. Chairman of Medical Division of Volunteer Medical Reserve Corps.

Dr. August P. Jonas, U. S. Army, commissioned Captain December, 1917. Aide to Governor of Nebraska.

Dr. Daniel F. Jones. U. S. Army, commissioned Major July, 1918. Chief Surgeon to Base Hospital No. 131, A. E. F.; Consultant to Base Hospital No. 114 and later Consultant to Beau Desert Hospital Center and Bordeaux Center. Previously served with British Army, 1916, at General Hospital No. 22, B. E. F., with relative rank of Lt.-Colonel, R. A. M. C. Promoted to Lt.-Colonel, U. S. A.

Dr. John H. Jopson, U. S. Army, commissioned Major April, 1917. Commanding Officer of Hospital Unit A. Later Head of Surgical Team and Chief Surgeon to Evacuation Hospital No. 1, A. E. F.;

Consultant to Base Hospital at Camp Dix; Chief Surgeon to General Hospital No. 41. Was present in front area April to November, 1918, and during St. Mihiel battle. Also served at Base Hospital No. 18, A. E. F. Promoted to Lt.-Colonel.

Dr. Edward S. Judd, U. S. Army, commissioned Major 1917. Director of Military Medical School at Rochester, Minn.

Dr. Frederick Kammerer, U. S. Army, commissioned Major 1917. Director of Base Hospital No. 16; Chief of Surgical Division, U. S. A. General Hospital No. 12 U. S.

Dr. Allen B. Kanavel, U. S. Army, commissioned Major 1917. Attached to Surgeon-General's Office, Department of Surgery. Later assigned as Consultant at Neufchâteau, France. Served in front area during Argonne offensive. Promoted to Lt.-Colonel to Colonel.

Dr. Arthur A. Law, U. S. Army, commissioned Major June, 1917. Commanding Officer of Base Hospital No. 26; Chief Surgeon to Evacuation Hospital No. 104. Served in front area at Beauvais. Promoted to Lt.-Colonel. Citation.

Dr. Robert G. Le Conte, U. S. Navy, commissioned Lt.-Commander June, 1917. In charge of operating naval teams in front area. Medical Liason officer for U. S. Naval Forces in France; Naval Representative on the International Naval Board of Health. U. S. Naval Base Hospital No. 5. Present in front area during British, French and American offensives, 1917–1918. Promoted to Commander. Decorations: Naval Cross and Legion d'Honneur.

Dr. James B. Lee, U. S. Army, commissioned Captain April, 1917. Operating Surgeon to Base Hospital No. 9; Consulting Surgeon to Second Division, A. E. F. Served on Commission to determine best methods of blood transfusion. Was present in front area during all great battles of 1918. Promoted to Major to Lt.-Colonel. Decorations: D. S. M., and Croix de Guerre with one star.

Dr. Dean D. Lewis, U. S. Army, commissioned Major April, 1917. Director of Base Hospital No. 13, Chief Surgical Team No. 71; Chief of Surgical Service at Evacuation Hospital No. 5. Served in front area at Coulumier, Château-Thierry, Villers-Cotterets,

Ville-sur-Cousannes, La Veuve and Staden, Belgium. Promoted to Lt.-Colonel.

Dr. Howard Lilienthal, U. S. Army, commissioned Major 1917. Director of Base Hospital No. 3; Chief of Surgical Team No. 39; detached service at Base Hospitals No. 101 and No. 34 and Evacuation Hospital No. 6. Ordered by Surgeon-General's Office to prepare section on thoracic surgery for Surgical History of War. Served in front area at St. Mihiel, Argonne and Meuse offensives. Promoted to Lt.-Colonel.

Dr. William E. Lower, U. S. Army, commissioned Major April, 1917. Assistant Director of Surgical Service at Base Hospital No. 4, and later Commanding Officer of Base Hospital No. 4 (British General No. 9). Served in front area at third battle of Ypres. Promoted to Lt.-Colonel.

Dr. Frederick B. Lund, U. S. Army, commissioned Major April, 1917. Chief Surgical Service at Camp Wheeler, and at Base Hospital No. 51; Surgeon to U. S. A. No. 15, Camp Crane; Assistant Chief Surgeon to Columbia University Hospital No. 1. Served in France with British in Harvard University Unit, 1916.

Dr. H. H. M. Lyle, U. S. Army and Red Cross, commissioned Major April, 1917. Commanded Recruit Battalion B, Ft. Benjamin Harrison; Commanding Officer of Evacuation Hospital No. 2, A. E. F.; Consulting Surgeon to 77th Division; Director of Ambulance Medical Transportation and evacuation of wounded with First Army; Consulting Surgeon to First Army. Served as Volunteer Surgeon with French at American Ambulance Hospital B, Juilly as Medecin Chef, 1915; with Anglo-French Red Cross attached to 10th and 3d French Armies, 1916; as Medecin Chef, Ambulance Chirurgical Annel, 1916. Served in front area in Battle of Somme, 1916, and at the Vesle-Aisne, St. Mihiel, Argonne-Meuse offensives, 1918. Promoted to Lt.-Colonel to Colonel. Citation.

Dr. L. L. McArthur, U. S. Army and Red Cross, commissioned Major January, 1917. Medical Aide to Governor of Illinois. Director of Base Hospital No. 14; Chairman of State Committee Red Cross. Refused permission to accompany Unit abroad by Overseas Board on account of alleged physical disability.

Dr. Stuart McGuire, U. S. Army, commissioned Major 1917. Chief of Surgical Service at Base Hospital No. 45; Commanding Officer of Base Hospital No. 45. Served in front area at Château-Thierry. Promoted to Lt.-Colonel. Decorations: Citation, Medal of Honor from French Government.

Dr. Lewis S. McMurtry, U. S. Army, commissioned 1st Lt. November, 1917. Medical Aide to Governor of Kentucky. Organized and supervised work of Medical Advisory Board of State of Kentucky.

Dr. Floyd W. McRae, served as Chairman of State Committee Medical Section, Council of National Defense. Rejected for active service on account of age.

Dr. Clarence A. McWilliams, U. S. Army, commissioned Captain April, 1917. Served with Base Hospital No. 15, A. E. F., and also with Evacuation Hospital No. 1; Head of Surgical Team. Served in front area at Bois de Belleau and Château-Thierry in advanced hospitals until disabled on account of illness. Promoted to Major to Lt.-Colonel. Decoration: Officer de l'Instruction Publique by French Government.

Dr. Kenneth A. MacKenzie, U. S. Army, commissioned Captain 1917. Medical Aide to Governor of Oregon. In charge of Local and Medical Advisory Boards. Chairman of State Committee, Council of National Defense. Chairman of Portland Chapter of Red Cross.

Dr. Archibald MacLaren, U. S. Army, commissioned Captain. Medical Aide to Governor of Minnesota. In charge of Medical Side of Draft, including Local and Advisory Boards.

Dr. Murray MacLaren, Canadian Army, commissioned Lt.-Colonel 1889. Commanding Officer of No. 1 Canadian General Hospital, and later Granville Special Hospital. Deputy Director of Medical Services, Overseas Forces of Canada. Promoted to Colonel. Decorations: Companion of Order of St. Michael and St. George (British); Commandeur of Order of Avis (Portugal); 1914–1915 Star; Victory Medal; British War Medal.

Dr. Edward Martin, U. S. Army, commissioned Major September, 1917. Served as Chief Instructor in Surgery, Ft. Oglethorpe School for Training Medical Officers; Chief Surgeon, Ft. Oglethorpe Hospital. Promoted to Lt.-Colonel to Colonel.

Dr. Walton Martin, Member of Medical Advisory Committee, Council of National Defense. Served with French Army, 1914–1915, American Ambulance at Paris, and as Medecin Chef, Hospital B at Juilly, France.

Dr. Rudolph Matas, U. S. Army and Red Cross, commissioned Major 1917. Director of Base Hospital No. 24; Director of Officer's School for Intensive Training in War Fractures and Military Surgery; Chairman of Research Committee of State of Louisiana Council of National Defense; Member on National Committee for American Physicians for Preparedness. Unable to accompany Unit overseas on account of fatal illness of wife.

Dr. Frank Mathews, served on Medical Advisory Board, Council of National Defense.

Dr. Charles H. Mayo, U. S. Army, commissioned Major May, 1917. Chief Consultant of Surgical Service, Surgeon-General's Office. Member of Medical Section, Council of National Defense. Governor's Aide, State of Minnesota. Promoted to Lt.-Colonel to Colonel. Decoration D.S.M.

Dr. William H. Mayo, U. S. Army, commissioned Major April, 1917. Chief Consultant of all Surgical Services during the war in Surgeon-General's Office. Member of Medical Advisory Committee, Council of National Defense. Promoted to Colonel. Decoration: D. S. M.

Dr. Willy Meyer, U. S. Army, commissioned Major April, 1917.

Dr. Robert T. Miller, U. S. Army, commissioned Major June, 1917. Director of Base Hospital No. 27; Chief of Surgical Service of Mobile Hospital No. 1. Served in front area with French Ambulance at Amiens drive and also at Coulumiers, Château-Thierry, Argonne and St. Mihiel. Promoted to Lt.-Colonel.

Dr. Charles F. Mitchell, U. S. Army, commissioned Captain, 1917. With Base Hospital No. 10 serving with the British at General Hospital No. 15; charge of QY General Hospital, B. E. F. Head of Surgical Team at 61 Casualty Clearing Station during British offensive in Flanders, 1917. Promoted to Major to Lt.-Colonel.

Dr. James F. Mitchell, U. S. Army, commissioned Major August, 1917. Chief of Surgical Service and later Commanding Officer of Evacuation Hospital No. 32. Served on Empyema Commission. Promoted to Lt.-Colonel.

Dr. Alexis V. Moschcowitz, U. S. Army, commissioned June, 1916.

Dr. Harvey G. Mudd, U. S. Army, commissioned Major April, 1918. President of Missouri State Committee Medical Section, Council of National Defense.

Dr. George P. Muller, U. S. Army, commissioned Major October, 1918. Contract Surgeon; Chairman of Medical Advisory Board, Surgeon-General's Office. Promoted to Lt.-Colonel.

Dr. Fred T. Murphy, U. S. Army, commissioned Major April, 1917. Surgical Director of Base Hospital No. 21, which served with British at General Hospital No. 12, B. E. F. Later represented G-4, G. H. Q., and Chief Surgeon of First Army in establishing evacuation hospitals and railheads for transportation of wounded. Later served as Chief Surgeon, Hospital Section of American Red Cross, Paris. Served in front area during British offensive in Flanders, 1917, and also at battles of Cantigny, Soissons, Château-Thierry, Fismes, 1918. Promoted to Lt.-Colonel and Colonel. Decoration: D. S. M.

Dr. Edward H. Nichols, U. S. Army, commissioned Major April, 1918. Chief Surgeon to Base Hospital No. 7, A. E. F., 1915. Served with British Army as Chief of Surgical Staff to Base Hospital No. 22, B. E. F., with relative rank of Lt.-Colonel. During 1918 served in the front area during battle of Château-Thierry. Promoted to Lt.-Colonel.

Dr. Albert J. Ochsner, U. S. Army, commissioned Major June, 1916. Organized Base Hospital No. 11. Member of Surgical Consulting Board of Surgeon-General's Office.

Dr. Ingersoll Olmsted, volunteered his services but was not accepted on account of disability.

Dr. F. W. Parham, U. S. Army, commissioned Major April, 1917. Served as Chairman of Medical Advisory Committee in First District of Louisiana Draft Service.

Dr. Charles H. Peck, U. S. Army, commissioned Major May, 1917. Director of Base Hospital No. 15; Senior Consultant in General Surgery, A. E. F.; Chief of Department of Surgery, Surgeon-General's Office, Washington; U. S. Delegate to Interallied Surgical Conferences, 1917, 1918. Served in front area at Vassany-sur-Vesle during the battle of Chemin des Dames. Honorary member of the 69th Battalion Chasseurs Alpine, French Army, for services rendered to the French Army during the battle of Chemin des Dames. Promoted to Lt.-Colonel and Colonel. Decoration: D. S. M.

Dr. Nelson M. Percy, U. S. Army, commissioned Major December, 1917. Organized Base Hospital No. 11, accompanied it to France and served as Chief of Surgical Service. Served in front area September to November in Evacuation Hospital No. 1. Promoted to Lt.-Colonel.

Dr. Dallas B. Phemister, U. S. Army, commissioned Captain September, 1917. Served with Base Hospital No. 13, A. E. F. Was present in front area as Head of Surgical Team No. 72 at second battle of Marne and also battles of Argonne, St. Mihiel and Champagne. Promoted to Major.

Dr. Samuel C. Plummer, U. S. Army, commissioned Major, 1917. Chief of Surgical Service of Base Hospital No. 114; later Consulting Surgeon to Hospital Center Le Mans, France. Previous to going abroad served at Camp Custer and in Chicago. Citation.

Dr. Eugene H. Pool, U. S. Army, commissioned Major April, 1917. Chief Surgeon to Base Hospital No. 9; Head of Surgical Team; served in Evacuation Hospital No. 1; later appointed Consultant in General Surgery, A. E. F.; served in front area in the battles of St. Mihiel, Argonne-Verdun; in 1916 served as Volunteer Surgeon to French Army at Château de Passy No. 32. Promoted to Lt.-Colonel.

Dr. Charles A. Porter, served with first Harvard Unit with British Army at Base Hospital No. 22, Camiers, France. Relative rank Lt.-Colonel.

Dr. Miles F. Porter, U. S. Army, organized Hospital Unit M. Denied privilege of service on account of age. Served on District Board, Division No. 2, State of Indiana.

Dr. Alexander Primrose, Canadian Army, commissioned Lt.-Colonel March, 1915. Served in No. 4 Canadian General Hospital; later as Consultant in Surgery to Canadian Forces in England. Front area service in Salonika. Promoted to Colonel. Decoration: Companion of the Bath; mentioned in dispatches.

Dr. George G. Ross, U. S. Navy, commissioned Lt.-Commander June, 1917. Served with Base Hospital No. 5, U. S. N. at Brest in charge of Surgical Service. Front line service; head of Surgical Team at battle of Château-Thierry. Promoted to Commander. Decorations: Navy Cross.

Dr. Charles J. Rowan, U. S. Army, Contract Surgeon, commissioned October, 1917. Attached to S. A. T. C. Unit, University of Iowa.

Dr. Charles S. Scudder, Medical Advisory Board; Chairman, Instruction to Army Officers in Surgery at Massachusetts Hospital, Boston.

Dr. M. G. Seelig, U. S. Army, commissioned Lieutenant May, 1917. Head of Section on Surgery of Head, Surgeon-General's Office. Promoted to Lt.-Colonel. Later served with Division of General Surgery, Office of Surgeon-General, Washington.

Dr. Harry M. Sherman, U. S. Army, commissioned Major April, 1917. Chief of Surgical Service at Post Hospital, Ft. Rosecrans, San Diego and at Rockwell Field.

Dr. Rae E. Smith, U. S. Navy, commissioned Lt.-Commander June, 1917. Served in front area during 1918. Promoted to Commander.

Dr. Kellog Speed, U. S. Army, also British Army, commissioned Lt.-Colonel March, 1916, in charge of Surgical Division, General Hospital No. 23, B. E. F. Commissioned Major, U. S. A. May, 1917. Served in Base Hospital, Evacuation Hospital and 42d Division. Served as head of Surgical team in front area at second battle of Ypres, and in battles of Château-Thierry, St. Mihiel and Argonne. Promoted to Lt.-Colonel. Sustained severe hand infection in line of duty in France.

Dr. Clarence L. Starr, Canadian Army, commissioned Lt.-Colonel September, 1916. Head of Special Surgical Service and later Surgical Consultant at Headquarters. Served in front area during British offensive in Flanders, 1917. Mentioned in dispatches for Distinguished Service.

Dr. Frederick N. G. Starr, British Army, commissioned Major September, 1918. Served in General Hospitals in France and at Casualty Clearing Stations. Commanding Officer of Surgical Division No. 8, Stationary Hospital. Served in front area during autumn advance, 1918. Decorations: C. B. E.; mentioned in dispatches.

Dr. George D. Stewart, served on Council of National Defense of State of New York and in Volunteer Medical Service Corps.

Dr. Stanley Stillman, U. S. Navy, commissioned Lt.-Commander May, 1917; Chief Surgeon, U. S. N. Base Hospital No. 2. Served at Headquarters, London, and at Strathpeffer, Scotland. Promoted to Commander.

Dr. John E. Summers, Chairman of Council of National Defense Medical Section, Nebraska. Volunteered for active service but was not accepted on account of age.

Dr. William J. Taylor, U. S. Army, commissioned Captain March, 1917. Served in U. S. Base Hospital No. 10 as Senior Captain in Surgery; later Chief of Surgical Service. Promoted to Major to Lt.-Colonel.

Dr. Wallace I. Terry, U. S. Army, commissioned Major April, 1917. Resigned on account of ill health.

Dr. James E. Thompson, U. S. Army, commissioned Major, 1917.

Dr. P. E. Truesdale, U. S. Army, commissioned Captain July, 1917. Served in Mobile Hospital No. 39. Front area service April to November, 1918. Promoted to Major.

Dr. Edgar A. Vanderveer, U. S. Army, commissioned Captain February, 1917. Served as Surgeon to Medical Advisory Board No. 28. Resigned in June, 1918, owing to fact that two younger brothers were in service.

Dr. George Tully Vaughan, U. S. Navy, commissioned Lt.-Commander April, 1917. Served as Chief Surgeon and later as Chief of all the medical services on U. S. S. Leviathan. Promoted to Commander.

Dr. Jonathan M. Wainwright, U. S. Army, commissioned Major May, 1917. Chief of Surgical Service in Base Hospital, Camp Greene. Later Commanding Officer of Base Hospital No. 54, A. E. F. Promoted to Lt.-Colonel. Decorations received: Distinguished Service Certificate.

Dr. John B. Walker, U. S. Army, commissioned Major July, 1917. Organized Base Hospital No. 116; served as its Commanding Officer in A. E. F.; later made Surgical Consultant. Observer in various hospitals in front areas. Promoted to Lt.-Colonel and Colonel.

Dr. Stephen H. Watts, was unable to enter the service on account of the fact that the teaching staff of the University was so depleted that he was obliged to remain.

Dr. Randolph Winslow, Member of Reserve Corps, but not given active service on account of age limit.

Dr. Alfred C. Wood, Volunteered services to Government but not accepted.

Dr. George Woolsey, U. S. Army, commissioned Major April, 1917. Served on teaching staff at Cornell Medical College and Bellevue Hospital.

Dr. John L. Yates, U. S. Army, commissioned Captain October, 1917. Served in the Experimental Laboratory at Dijon, France, Department of Thoracic Surgery, also served in front area from July 18 to November, 1918, as Head of Surgical Team in the Department of Thoracic Surgery. Promoted to Major to Lt.-Colonel.

Senior Members

Dr. Robert Abbe, Medical Reserve Corps, Red Cross. Served on Medical Examining Board and as President of Bar Harbor War Relief Association. Not called upon for active service.

Dr. Oscar H. Allis, American Red Cross. Beyond age limit for active service, but took active part in surgical dressings in Church Committees.

Dr. James M. Barton, Volunteer Medical Service Corps. Consulting Surgeon for Local Board for Examining Recruits.

Dr. E. H. Bradford, American Red Cross. Served on Public Safety Committee and Appeal Selective Service Board for Boston. Disqualified for active service on account of age and partial blindness.

Dr. W. H. Carmalt, Volunteered for Selective Service, but not called upon on account of age and disability.

Dr. F. S. Dennis, Volunteer Medical Service Corps, American Red Cross; Chairman of New England Surgical Dressings Committee.

Dr. William L. Estes, U. S. Army, commissioned Captain 1917. Served in Base Hospital for munition workers of Bethlehem Steel Works. Organized Red Cross Societies in Northampton County, Pa.; Chairman of Advisory Medical Board; Acted as Chairman of Local Committees of Medicine and Sanitation; State Committee of National Defense; organized Volunteer Medical Service Corps of Northampton County.

Dr. George W. Gay, Volunteer Medical Service Corps. Not in active service on account of age.

Dr. Frederic H. Gerrish. Not accepted for active service on account of age.

Dr. Arpad G. Gerster, Medical Reserve Corps, Member of Volunteer Medical Service Corps; Chairman of Hungarian Racial Group; acted on sub-committee of all Liberty Loan Campaigns.

Dr. Thomas W. Huntington, U. S. Army and Red Cross, commissioned Major May, 1917. Member of American Red Cross Commission to Italy. Visited all front areas.

Dr. W. W. Keen, Medical Reserve Corps. Appointed Major April, 1917. Member of Council of National Defense, Medical Section. Member of National Research Council. Gave addresses to aid volunteer enlistments.

Dr. William M. Mastin, on account of age and health was not able to secure commission for overseas duty. Contract surgeon for S. A. T. C. in section of Mobile, Ala.

Dr. Samuel J. Mixter, U. S. Army, commissioned Major April, 1917. Member of Surgical Advisory Board in Surgeon-General's Office. Served as Consultant at Camp Devens and Meade. Promoted to Lt.-Colonel.

Dr. George H. Monks, American Red Cross. Medical Advisor of New England Division Red Cross. Member of Volunteer Medical Service Corps.

Dr. Francis W. Murray, Volunteered for Active Service but was refused on account of age. Member of Volunteer Medical Service Corps.

Dr. John Parmenter, passed Medical Examining Board of New York City May, 1917, but application rejected by Surgeon-General on account of age.

Dr. Lewis S. Pilcher, Medical Advisory Committee, Council of National Defense. Member of Volunteer Medical Service Corps.

Dr. Joseph Ransohoff, organized Base Hospital No. 25. Applied for commission but refused by Surgeon-General on account of age.

Dr. Charles A. Powers, U. S. Army, commissioned Major April, 1917. Served as Surgeon at Military Hospital No. 1 (American Ambulance). Served as Volunteer Surgeon at same hospital during 1916 and 1917. Promoted to Lt.-Colonel.

Dr. John B. Roberts, U. S. Army, Contract Surgeon. Instructor in Civilian School of Plastic and Oral Surgery.

Dr. John D. Rushmore, Volunteer Medical Service Corps. Served in Surgical Service of St. Peter's Hospital, Brooklyn.

Dr. Francis J. Shepherd, served as Medical Advisor to a number of Military Hospitals in Canada.

Dr. A. Vanderveer, American Red Cross. Served as Member of National Committee Medical Service American Red Cross.

Dr. Henry R. Wharton, Selective Service Corps, served as Chairman of Medical Advisory Board, Presbyterian Hospital, Philadelphia.

It is deeply regretted that a number of Fellows failed to reply to the questionnaire sent out with a view to collecting the data necessary for this report.

TREATMENT OF CHRONIC EMPYEMA

By TH. TUFFIER
PARIS, FRANCE

By chronic empyema is meant a suppuration of the pleura with no tendency to spontaneous cure. This chronic character in itself is always grave. The frequency of the condition has diminished since our better knowledge of the manner of treating acute infections.

From the month of August, 1914, to the month of December, 1919, I operated 91 acute and chronic suppurations of the pleuræ.

I. Treatment of Acute Suppurations — Preventive Treatment of Chronic Suppuration. (1) One must first determine the bacteriological nature of the effusion. Exploratory puncture is here of value. It is, in fact, of the first importance. Pneumococcic pleurisies are usually mild and are often cured by simple aspiration, while streptococcic pleurisies are grave and most often require thoracotomy. (2) If repeated punctures leave a residuum, as shown by radioscopy, thoracotomy is done at the point of election in the posterior axillary line under local anesthesia. (3) Evacuation of adhesions and disinfection of the pleura follow. In certain cases the pleura can be closed, *completely and immediately*. Example, 3 cases (2 pneumococcic with cure, 1 staphylococcic with return of suppuration and secondary disinfection with Dakin solution, secondary closure and cure). In most cases we prefer drainage by siphon after thoracotomy. This is the most simple procedure. Radioscopic examination shows progressive diminution of the pleuritic process. For bad conditions persisting in spite of

drainage (as to pulse, temperature and general condition) and a continued large infected cavity in the pleura we proceed thus: Extensive thoracotomy and pleuroscopy under local anesthesia, permitting a view of the form and dimensions of the pleuritic cavity; disinfection by the Dakin method, numerous Carrel tubes placed in all corners of the cavity. If a bronchopleural fistula

FIG. 1.—Use of armed rubber tubes for exploratory purposes.

exists, discontinuous injections of oxygen are substituted for the Dakin solution. When the culture curve has reached zero and a dry compress placed at the opening of the cavity remains dry for twenty-four hours, complete closure is made of the surgical orifice, resection of the edges of the fistula, tamponing of the pleura to avoid discharge of blood into the interior and complete

suture of the wound. One thus transforms the former pyothorax into an aseptic pneumothorax, which is spontaneously cured by bringing back the parietal pleura into contact with the lung.

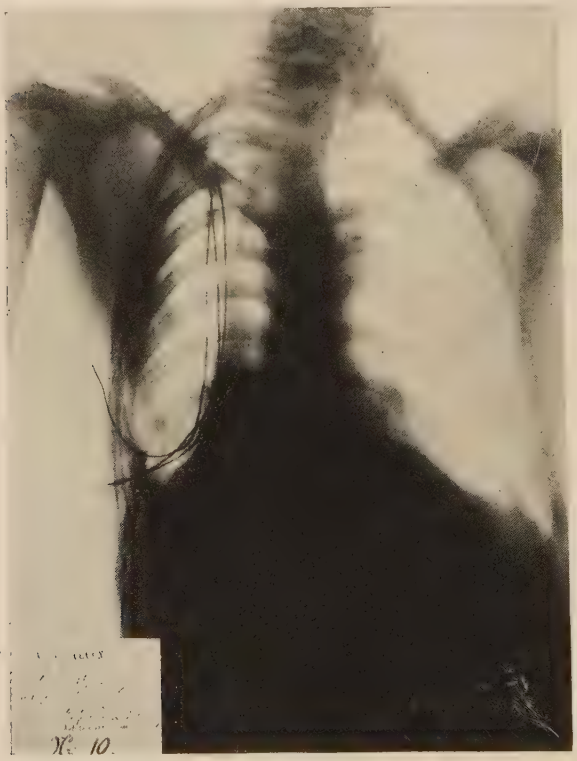

FIG. 2.—Use of armed rubber tubes for purposes of exploration. (Gagneux.)

Volumes of the operated cavities were as follows:

6 had a content of 2 to 3 liters.

5 had a content of 1 to 2 liters.

7 cases showed enormous cavities, exact size not given.

2 cases showed rapid cure.

7 cases were lost, all of acute pleurisy medically treated, this variety being always more grave than suppurating and operated pleurisy.

With regard to the time of thoracotomy of the 7 patients succumbing after intervention, 5 were operated early after the pleural effusion had occurred, when suppuration had scarcely begun and general evidences of infection were intense. All 5 cases were streptococcic. Case 12 was cyanosed, with arterial hypotension of marked degree. Case 20 after a three months'

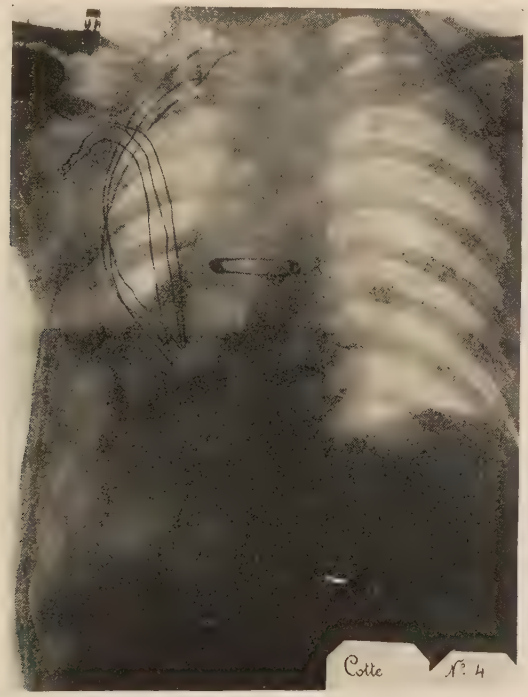

FIG. 3.—Use of armed rubber tubes for purpose of exploration. (Cotte.)

pregnancy presented the same symptoms, with intense dyspnea and oliguria. Case 23 added to these symptoms an edema of the thoracic wall. Patients affected with purulent pleurisy recent in origin or with post-grippal or originally purulent pleurisy were ill but a few days (8 to 15 at most). Onset was sudden and all cases presented the septicemic type characterized by more or less cyanosis of the face and extremities, dyspnea whose intensity

was more in relation to the toxemia than with the quantity of pleural effusion and pharyngolaryngeal symptoms. To these phenomena of intoxication were added in three of the cases (22, 24, 25) external evidences of the general infection (facial erysipelas, diffuse phlegmon, erysipelas of the costal wall on the side affected), which developed with the greatest rapidity.

FIG. 4.—Empyemic cavity filled with bismuth for purposes of exploration.

Thoracentesis done before operation brought no relief to these cases. The abundant effusion, invading the entire pleura, was an ill-looking, dirty yellow, serosanguineous liquid, often of putrid odor and containing adhesions of greater or less density.

In case 24 we were able to verify the septicemic character of the infection by spleen changes (enormous size and doughy consist-

ence), the pleurisy being thus but a local manifestation of the general condition. In these 5 cases the blood culture was positive for streptococcus. Another of the cases (No. 22), cured, is of the same kind. In these, the operative intervention was later, and we repeated several times before and after operation intravenous injections of antistreptococcic serum.

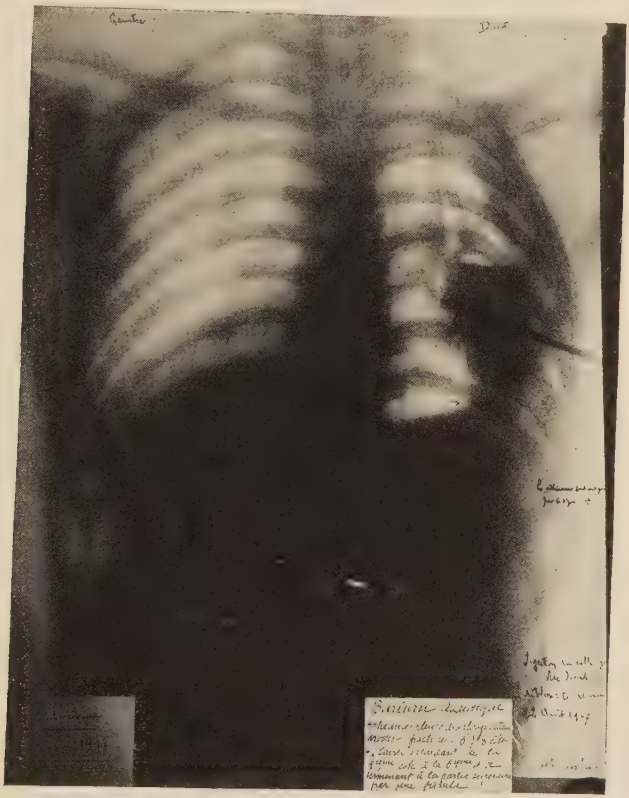

FIG. 5.—Empyemic cavity filled with bismuth for purposes of exploration.

Analysis of the events following intervention at the height of the infection prove that the pleural effusion was only an epiphenomenon and that it is the general infection which was in no wise modified by the evacuation of the effusion which brought these

patients to us. I will not venture to draw the conclusion that one must temporize in the treatment of suppurating pleurisies and to wait until they play the role of operation abscess before being incised. At all events, these facts plead against immediate thoracotomy in the non-surgical pleurisies which concern us. If the effusion causes untoward conditions, remedy of it by puncture is better than a more complete operation.

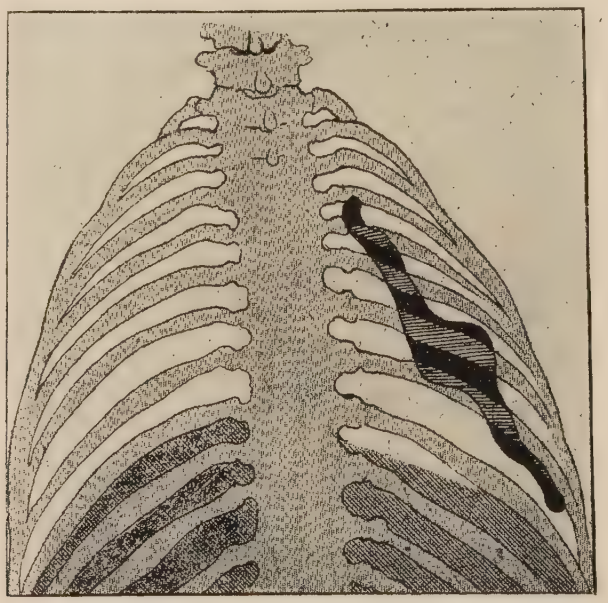

FIG. 6.—Showing empyemic cavity filled by an injection of bismuth.

Notwithstanding other treatment, 4 acute cases became chronic, causation being as follows:

Pleural diverticula and *bronchopleural fistulæ* rendered disinfection impossible. One could easily locate the seat of a chronic infection by seeking out the situation of the microbic attack. When in a pleural cavity that appeared to be aseptic one sought in various regions for the microbic focus, one found a single and persistent septic cavity. By means of electric pleuroscopy one thus diagnoses a diverticulum of the pleura which is not reached

by the antiseptic solutions injected and which empties itself very incompletely.

Bronchial fistulæ are equally factors in producing chronic conditions because of the septic features which they entail. I have noticed two effects of this sort of infection, the first being a

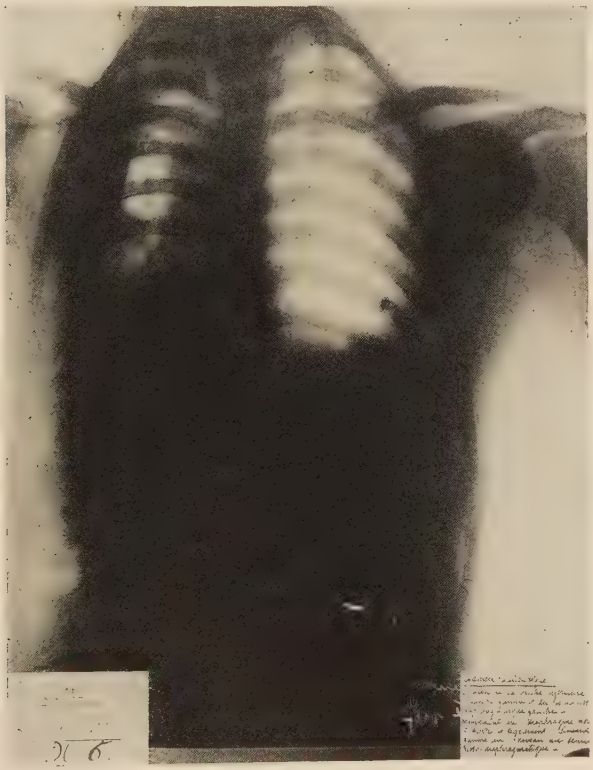

Fig. 7.—Showing radio-opacity in the lower half of the left lung. (Cotte, June 2, 1917.)

necrosed bronchial cartilage, the course and termination of which were followed under conditions described below, viz.:

The patient (Case 11), before entering our service, had spent a month being treated and several thoracenteses had been made. Some days being operation, injection of methylene blue was

made into the pleura, with the production of attacks of a minor grade of vomiting ("spitting blue"). After operative intervention, disinfection of the pleura by Dakin solution was very badly borne and induced incessant coughing. Pleuroscopy then revealed, on the pulmonary pleura at the level of the interlobular

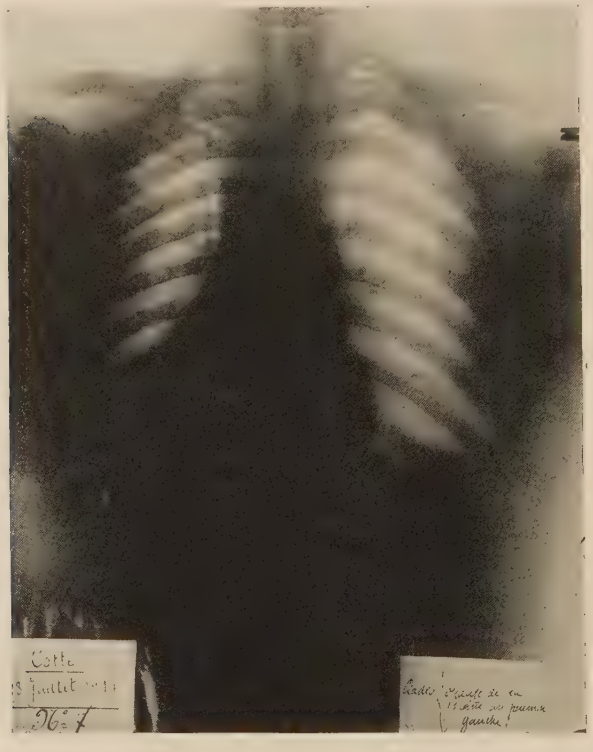

FIG. 8.—Showing radio-opacity in the middle of the left lung. (Cotte, July 8, 1917.)

fissure, a little sphacelated plaque, grayish-green in color, irregular and about the size of a dime. It could not be detached by the forceps and contact with it provoked pain and cough.

Instillations of Dakin solution at this point determined diagnosis of an eschar and probable bronchial fistula (cough and discharge of Dakin solution from the mouth). From December 18,

1918, to January 22, 1919, discontinuous insufflations of oxygen were resorted to in order to disinfect the pleura, the Dakin solution not being tolerated. The bronchial eschar becoming then more and more limited by granulating pleura, disinfection with Dakin solution was resumed. By February 9 the eschar was reduced to the size of a pea and no further signs were caused by it.



Fig. 9.—Incision in the intercostal space.

There are also anatomical or pathological diverticula which one can diagnose *de visu* by electric illumination of the pleura. Such diverticula are described in case 12.

When bronchial fistulæ are recent and without necrosis of cartilage they do not embarrass closure of the pleura. I have operated two bronchopleural fistulæ of some weeks' duration

only and after the opening of a pleurisy into the bronchi before operation. The cavity was asepticized, the costal orifice closed and the patient cured as simply as if he had never had a fistula.

There is another variety of chronic fistula especially grave, ending generally in gangrenous processes following pulmonary injury. Here the orifice is located at the bottom of the pleural cavity and one clearly sees a suppuration which nothing can

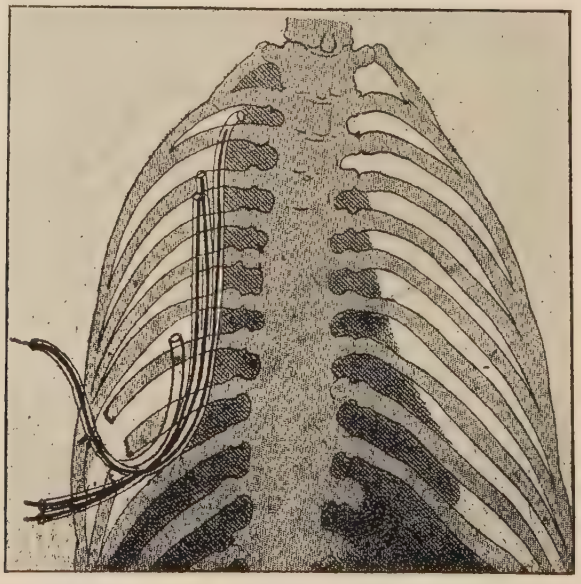

FIG. 10.—Rubber tubes, armed, introduced into the fistula for purposes of disinfection.

control. Cough is frequent, expectoration of pus more or less abundant, no disinfectant can stop the infection. In such cases I have tried to close the costal wall only to fail.

The second effect referred to is that of bronchopleural fistula with bronchial ectasia around the fistula. In removing adhesions about the fistula in a case of this kind I found a series of cavities varying from the volume of a large pea to that of a filbert, containing pus and constituting areolæ like veritable honeycomb.

In short, such a case shows a bronchial focus, localized, and with pulmonary sclerosis. Incision and opening of these cavities are indicated but are unsatisfactory. In one case still under treatment, bronchial suppuration persisted. One must resort to extirpation of the pulmonary nidus by incision (partial pneumectomy) into healthy tissue. The bronchial fistula may

FIG. 11.—Use of armed rubber tubes for purpose of disinfection. (Case of Cotte, see Figs. 3, 7, 8.)

become permanent by direct continuation with the thoracic wall of a small orifice which closes during expiration. An example is seen in a case which I operated during childhood, twenty-five years ago, the fistula persisting without the least embarrassment from infection. It has always resisted every freshly attempted treatment.

Small abscesses may be remarked in the visceral pleura, visible by electric pleuroscopy and being capable of retarding cure. At their site the serous membrane was markedly thinned, having the appearance of onion skin, ready to break and consequently leaving an ulceration or perhaps a bronchial fistula, splendid avenue of communication for the transfer of infection between the pulmonary tissue and the pleura.

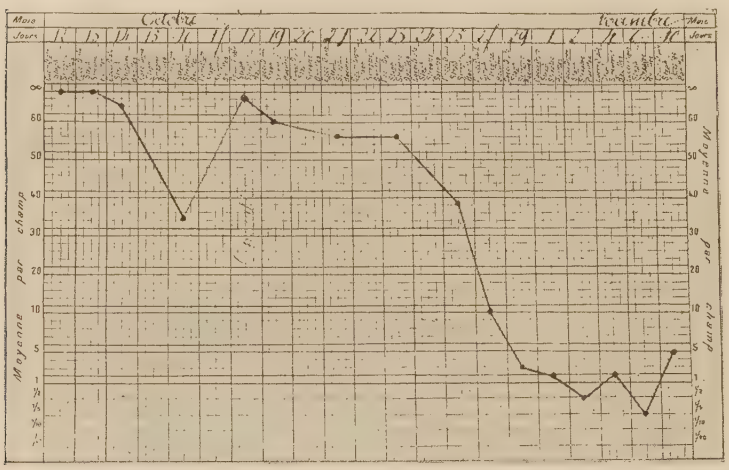

FIG. 12.—Microbe curve: showing progressive diminution of infection under treatment.

In cases 26 and 28, we diagnosed, by pleuroscopy, similar ulcerations located at the middle of the median lobe of the lung. In fact, they were multiple intrapleural abscesses as in case 23.

What the cause of chronicity, once induced it requires a long and difficult treatment. The cavity may be indurated, fixed, fibrous, inelastic or completely calcareous, with thick walls. I have operated cases lined with calcareous plaques like oyster shells.[1]

To fill this cavity the lung must return to its contact with the pleural membrane or the pleura must advance to a contact with the retracted lung. The ill-advised operation of Estlander

[1] Tuffier and Gy: Revue de Chirurgie, 1907, pp. 329–346.

consisted in obliterating the costal opening, which permitted the skin and muscles to heal before the lung was in good condition; it meant abolition of pulmonary function in the affected region, with all the trouble incident to it. Our object is precisely the contrary. It consists in every case where possible in removing the pleural shell to permit the lung to return to its proper position in the thoracic cage, intact or nearly so, continuing a nearly normal function.

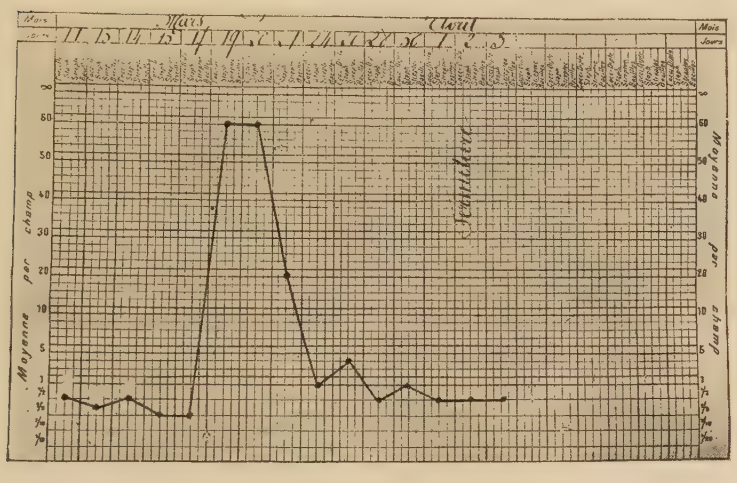

FIG. 13.—Microbic curve, showing effect of drainage and disinfection.

II. TREATMENT OF CHRONIC EMPYEMAS, RECENT AND OLD. Cases are those of pleural fistula. Treatment should always be preceded by a methodical exploration of the cavity, which includes noting its extent and form and examining the pulmonary mobility during expiration and inspiration and the effort necessary, the degree of pulmonary expansion being thus ascertained. The resulting information indicates application of one of two methods, viz.: Disinfection of the cavity and respiratory exercise, or closing of the surgical wound by the method of Depage and Tuffier. If the cavity is intractable, pleuropulmonary decortication, partial or total, may be practised.

Exploration. 1. Radioscopy and Radiography: The pleural fistula is often narrowed, leading to a cavity; radiography permits exact knowledge of its form and extent. By introducing several rubber tubes carrying wire, one ascertains extent, direction and form. If this method is insufficient, injection is made of a paste of bismuth or barium. Radioscopy should show the extent of the cavity during inspiration and expiration and the degree of effort. It permits thus a study of pulmonary expansion; one learns the minimum volume of the cavity and the play of the lung antero-posteriorly and laterally and therefore one knows the location of

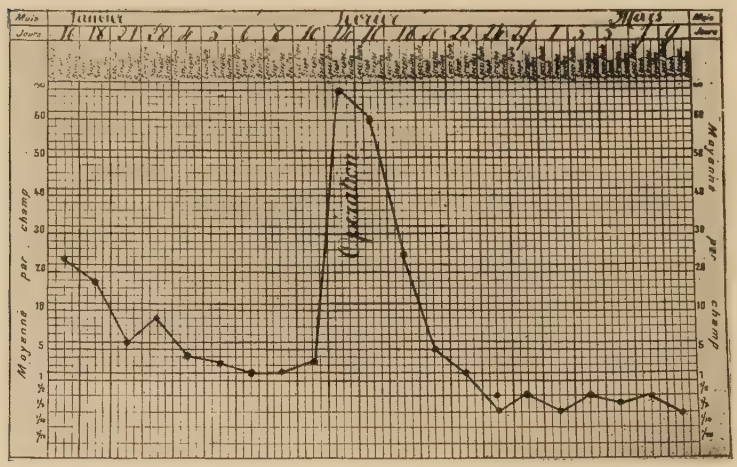

FIG. 14.—Microbic curve, showing effect of drainage and disinfection.

points of adhesions which must be attacked. I have noticed cases in which the cavity during forced expiration disappeared completely, prognosis being especially favorable.

Radioscopy permits at the same time to follow the involution and diminution of the cavity during disinfection. Respiratory exercises with forced expiration are continued during the entire term of exploration and disinfection.

2. Pleuroscopy: This enables investigation of the obstacles to contact of the lung with the thoracic wall. If the fistula is large, one does pleuroscopy through the orifice, as in cystoscopy.

Essentials to be noted are color of the cavity, surface of its walls, irregularities, diverticula, bronchial fistulas, the regions suppurating.

3. Bacteriological and Microscopic Examination: This establishes the number and nature of the bacteria, their location, and gives the base of the culture curve during disinfection. Note the varieties most often encountered:

4. Surgical Exploration: This may be followed immediately by the surgical treatment. Method: Local or general anesthesia; lighting by the frontal lamp; wide thoracotomy following

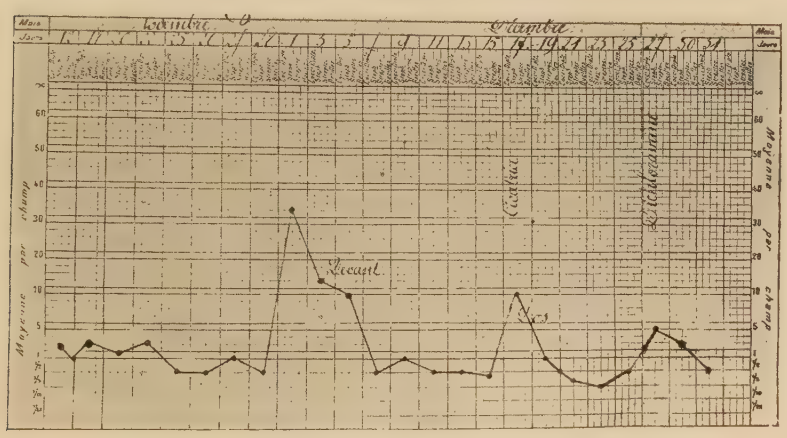

FIG. 15.—Microbe curve, showing average number of organisms in the microscopic field.

along the intercostal space corresponding to the fistula, resection of its borders and of the bony callus which surrounds and results from the fusion of the ribs; removal of adhesions; separation of the edges of the cavity by means of a special instrument (separator). One thus learns the extent of the cavity and the consistence of its walls in different regions. Three forms of pathology may be found: (1) A fistulous tract sometimes very long, extending from the base of the thorax to the upper ribs; (2) a regular cavity with considerable retraction of the lung, always difficult to cure; (3) a fissured cavity, narrow but with a very long principal

diameter, often directed from above downward and backward, which diminishes considerably during respiratory effort. These cases may present diverticula, of which the most difficult of cure are those which form pockets, bilobed or multilobed, with constrictions between each lobe. If the cavity is small and not

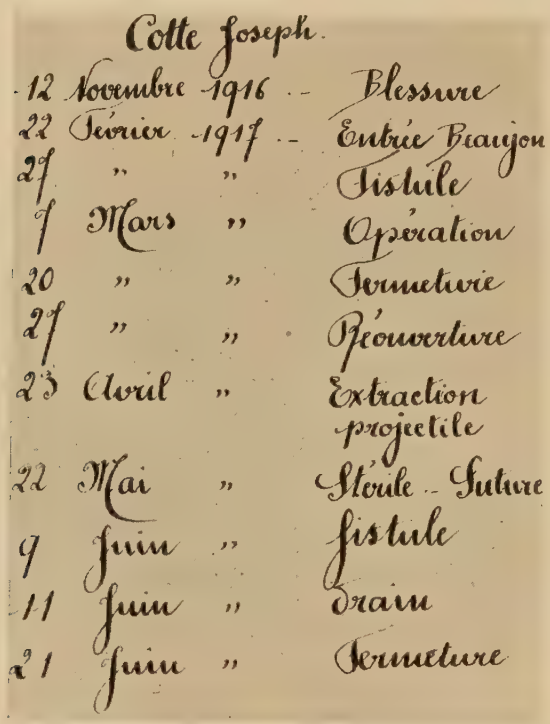

Cotte Joseph.

12	Novembre	1916	Blessure
22	Février	1917	Entrée Brayon
27	"	"	Fistule
1	Mars	"	Opération
20	"	"	Fermeture
27	"	"	Réouverture
23	Avril	"	Extraction projectile
22	Mai	"	Stérile - Suture
9	Juin	"	fistule
11	Juin	"	Drain
21	Juin	"	Fermeture

FIG. 16.—Syllabus of the various stages in the treatment of a case of chronic pleuritis and fistule following a perforating gunshot wound of the thorax.

greatly infected one can attempt immediate pleuropulmonary decortication or the resections necessary to a cure. We thus treated 8 cases (2 acute and 6 chronic), but this exploration should most often be followed by chemical disinfection of the cavity.

5. Disinfection of the Cavity: I prefer the Carrel-Dakin method when possible. Rubber tubes armed with silver wire,

very fine and pliable, are placed in such a fashion as constantly to irrigate the cavity and all diverticula. This procedure is indispensable and the essential of the method. It is necessary to have several tubes and to place the patient in a position permitting the antiseptic liquid to have access to the diverticula. Disinfection may be more or less rapid, but it is often very slow, Its progress is mapped by curves. This series shows some of these difficulties.

FIG. 17.—Microbic curve in the case of Cotte. (See Fig. 16.)

This procedure may be impracticable if there is a bronchopleural fistula. Irrigation produces cough and a chlorin taste in the mouth which cannot be borne. Therefore before placing the tubes introduce into the pleural cavity a wick of gauze to tampon the bronchial orifice and prevent flow of the liquid to the mouth. At the time of injection one can also place the patient in lateral decubitus, lying upon the fistula. These means are often insufficient at the beginning of treatment; later the liquid no longer passes into the bronchi, probably as a result of spontaneous narrowing of the bronchopleural orifice and disinfection becomes easy.

When all these means fail I replace them by continuous or

discontinuous aëration with oxygen gas, passed into all the recesses of the cavity as the Dakin liquid is distributed. This method was applied in 5 cases. Bacteriological examination of these cases showed 3 with streptococcus alone, 1 associated staphylococcus, diplococcus, streptococcus, coccidia and a mononucleated organism and 1 with no bacterial finding. All 5 patients were cured.

Naturally this disinfection is often difficult and stubborn. The cause must be sought. The location of the bacteria explains in certain cases the resistance of the septic process to treatment; for example, in case of a pleural diverticulum not reached by the disinfectant solution, and which must be located and treated, or again with a bronchial fistula demanding oxygen or tampon with a compress before employing the Dakin solution, the culture curve may be irregular, as may be readily noted. Two cases were operated in two stages: I first closed off the aseptic region and later instituted disinfection of infected locations. During the stage of disinfection respiratory exercises were continued as the cavity grew smaller. Extent of the treated cavities:

Content before operation,		360 c.c.	Content at time of closure,		150 c.c.
"	"	141 c.c.	"	"	0 c.c.
"	"	46 c.c.	"	"	8 c.c.
"	"	360 c.c.	"	"	60 c.c.
"	"	125 c.c.	"	"	25 c.c.
"	"	65 c.c.	"	"	20 c.c.
"	"	175 c.c.	"	"	15 c.c.

Early disinfection is essential; pulmonary decortication formerly done by Delorme's method nearly always failed. Before closure two conditions are important: (1) The culture curve must read zero, streptococci being absent; (2) the pleura, without further application of Dakin solution and dressed only by sterile gauze, should not secrete. One can then *close the parietal orifice* with no further concern about the cavity (Depage-Tuffier) or perform pleuropulmonary *decortication*. In cases in which decortication alone is applicable I operate before securing total disinfection.

THE DEPAGE–TUFFIER METHOD. The culture curve reading zero and the cavity no longer secreting the surgical incision is closed.

1. Introduce aseptically into the pleura a narrow wick in order to prevent entrance or stay of blood within the pleural cavity during the operation.

2. Under local anesthesia the edges of the orifice are resected throughout its depth and down to healthy tissue, all incisions are tamponed and perfect hemostasis of the wound is secured. Closing is done either in one plane with silkworm gut or in two planes, the deeper with catgut and the superficial with silkworm. Closure is complete with aseptic dressing applied.

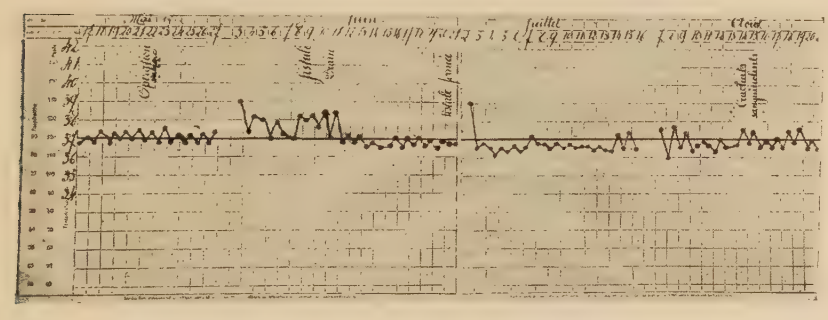

FIG. 18.—The later microbe curve in the case of Joseph Cotte (see Figs. 16 and 17), gunshot wound of lung.

This method is indicated in all cases in which the cavity is reducible by the respiratory effort, even in recent cases with uninfected bronchial fistula. Sutures are removed on the seventh day.

Should there be a bloody effusion into the pleura during or after the operation I insert a bundle of silkworm threads to drain the cavity for twenty-four hours. One can follow the regression of the cavity by radioscopy and auscultation. Usually resorption appears complete when the dressing is removed on the eighth day. If suppuration again complicates, I open the cavity anew.

PLEUROPULMONARY DECORTICATION. This operation was made in 9 intractable cases, 7 with total decortication and 2 with

partial decortication. The fistula had been present two hundred and eighty days in the non-surgical cases and ninety-three days in the traumatic cases. Cavities invariably contained streptococci. The period of disinfection averaged thirty-three days for the non-surgical cases, forty-three days for the surgical cases. The method is the method of election in old and obstinate cases, with cavities induated and not reducible by respiration. It includes two stages: (1) Thoracotomy with wide exploration and (2) decortication, complete or incomplete, total or partial.

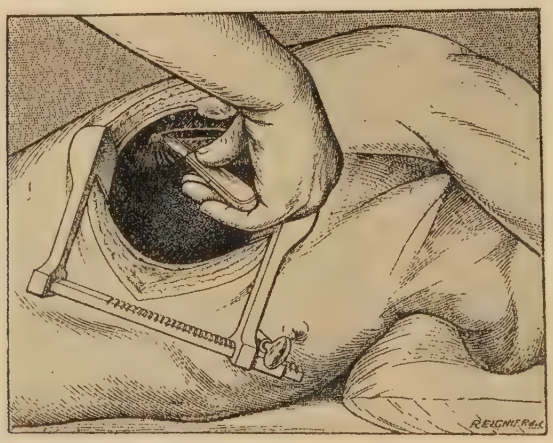

FIG. 19.—Dividing pleuroparietal adhesions at the bottom of the cavity.

Exploration is made by thoracotomy. Resection is made of the edges of the fistula and of the osseous plaques often due to the fusion of the ends of sectioned ribs. Wide separation, always difficult, of the surgical incision and the laying bare of all recesses and the entire cavity are practised. If prior disinfection of the cavity is thus obtained one continues with the decortication. If pumonary decortication by Delorme's method has not been successful it is only because it was not preceded by disinfection of the pleural cavity, and in my early operations I always saw decortication followed by a new infection.

Operative Method. Total Decortication. 1. Wide incision of the pleura is made to open the entire cavity thoroughly.

2. The cicatrix and osseous plaques about it are resected. Wide thoracotomy is done, beyond the limits of the cavity. Separation by a separator is made on the lips of the wound. One ascertains the plane of pleuroparietal cleavage at the level of the wound, this plane being often difficult to find. Stripping of the pleuroparietal region leading to the sinus of the cavity is done, here again amid grave difficulty in passing from the pleuro-

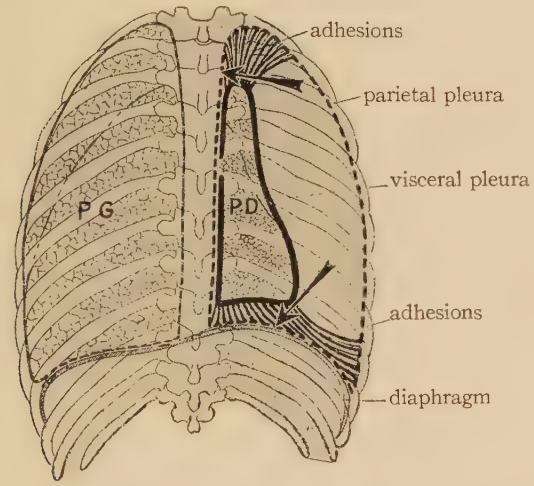

Fig. 20.—Points along which the incision should be carried at the periphery of the cavity.

parietal entrance to the pulmonary site. Adhesions are often intimate and thick at this level (see our figures). The false pulmonary membrane is stripped off and here the difficulties are especially great. If, in some cases, the plane of pleuropulmonary cleavage is easy to find and follow, adhesions are usually so intimate that stripping of the false membrane results in penetration into pulmonary tissue, with consequent bleeding. Total decortication has been successful with me only for cavities limited to the size of the two fists, and I have never decortified an entire pleural

cavity. Sometimes the process remains incomplete because of diverticula which cannot be reached or on account of deep adhesions involving the pericardium. Immediately after the removal of the false pulmonary membrane one sees the lung resume its expansion and again fill up the pleural cavity.

Pulmonary Decortication Alone. In 3 cases, after wide pleural incision, I liberated the cavity at the level of the pleuro-pulmonary adhesion by attacking the false pulmonary membrane, which permitted the lung to expand. I did not trouble about the pleuroparietal membranes. All these cases were cured.

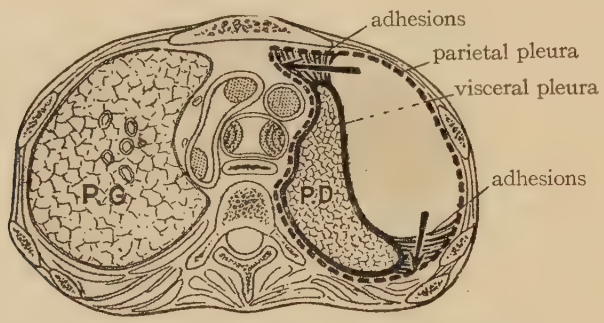

Fig. 21.—Diagram showing where the incisions should be carried in order to liberate the lung.

Partial and Segmented Decortication. (See figures). Adhesions between the pulmonary false membrane and the lung are such that one can extirpate them only in sections.

The periphery is incised at the union of the parietal and the pulmonary pleuræ to liberate the lung. One then attacks the false membrane in different places where it appears likely to yield more readily, leaving it untouched where the fusion is especially intimate. Islands of adhesions are thus left, of greater or less thickness, on the surface of the lung. One then thins out, by dissection, the thickness of the adhesions up to the pulmonary surface. I do not like to penetrate the pulmonary tissue, which always bleeds abundantly and thus constitutes an obstacle to cure.

In all these methods it may be necessary to resect one or two ribs more or less extensively. But in all cases preference is given to liberating the lung so that it may fill the pleural cavity. One resects the skeleton only when expansion is absolutely impossible.

If the raw surface left by decortication bleeds but little I completely close the surgical wound in one or two planes. If there is a slight bloody oozing I introduce a bundle of silkworm sutures to ensure drainage for twenty-four hours. If the oozing is very abundant I apply to the bleeding pulmonary surface a large wick to drain it, suturing completely at the end of twenty-four hours.

Complications of Operating Chronic Empyemas. In 11 cases the wound had to be reopened because of secondary suppuration, but the accumulation was much reduced in proportion to the original cavity.

In 2 cases the wound had to be opened twice. All of these were cured. Two other cases had to be reopened, 1 for an osseous fistula and the other for hemoptysis. Slight thoracic deformity was mentioned in 9 cases and considerable deformity in a case of seven months' duration.

Content after operation	15 c.c.	Content at closure,	3 c.c.
" "	120 c.c.	" "	45 c.c.
" "	17 c.c.	" "	4 c.c.
" "	37 c.c.	" "	4 c.c.

In 3 cases the pleural site was disinfected *de novo* and cured.

Subsequent medical treatment consisted in exercises for inspiration and expiration, the effect being watched by means of a registering pneumograph.

Final Results and Conclusions. All my cases have been seen six months to three years after operation. Thoracic deformity was slight. The radiographic reading was an interesting evidence of the thickness of former adhesions or of cicatrices shown to have almost completely disappeared. The costodiaphragmatic sinus alone was visible at its inferior portion.

To summarize, chronic purulent pleurisies are exceptional when acute effusions are well treated. Chronicity depends on a chronic pulmonary infection or on special anatomical peculiarities. Costal resection in the treatment of chronic empyema should be reduced to the minimum. Closure of the surgical incision and pleural decortication should be preceded by disinfection of the cavity and then gives success which was formerly unknown.

I have to thank Dr. Merrill A. M. Cross, Paris, for the translation of this article.

I. Record of 91 Cases from the Month of August, 1914, to the Month of December, 1919[1]

Forty-six cases of medical purulent pleurisy; 43 cases due to wounds of the lungs; 2 cases due to infection of the hemothorax. Out of the 46 medical cases 29 were opened by myself and treated by the Depage-Tuffier method.

The microscopic examinations showed: 15 cases of streptococci only; 5 cases of pneumococci only; 7 cases of associations of staphylococci, diplococci and streptococci; 1 case of streptococci and pneumococci; 1 case of streptococci and leukocytes. I practised the operation at the first sign of pleurisy in 9 cases from eight to twenty-two days; 13 cases from one to two and a half months; 4 cases from two and a half months; 1 case from four months; 2 cases from six months.

The duration of the sterilization was: 7 cases from six to twenty-four days; 3 cases from one month; 9 cases from one and a half to two and a half months; 4 cases from three to four months (case dating from several months). In certain cases the record was incomplete.

The volume of the cavity was about: 80 c.c. in 1 case; 200 c.c. in 2 cases; 300 c.c. in 2 cases; 700 c.c. in 1 case; 1100 c.c. in 2 cases; 1600 c.c. in 1 case; 1 liter in 1 case; 1 liter in 2 cases. Total, 11 cases.

In another case the cavity contained about 3 liters at the opening and more than 1½ liters at the closure of the pleura.

[1] Statistical table translated by Miss Carrie Patterson.

Six patients died almost immediately after the operation: 3 were streptococci and 3 were without a record of any kind. One case was opened and treated solely by oxygen; the microscopic examination showed streptococci and dated from three months; 3 were opened; they recovered but they were treated by simple drainage; 3 were opened and closed immediately, 2 pneumococcus success and 1 diplococcus failure. Two cases were sent to me already opened and had been already treated by "Dakin," they had been opened for over a month and showed streptococci. One dated from four months and had been sterilized in ten days, the other dated from three and a half years and had been sterilized in four months. Both recovered. Two cases were decorticated, 1 showing streptococci and the other was without record. One dated from three months, the other from one month. The sterilization was complete in eleven days. Result: recovery.

II. Consecutive Purulent Pleurisy from Wounds of the Lung in Forty-three Cases

Out of these 43 cases 19 were opened by myself and treated by the Depage-Tuffier method. The microscopic examination on the 19 cases showed 14 times association of staphylo-diplococci; strepto once and streptococci in 4 cases were not mentioned.

In 4 cases when I operated the wound dated from twenty days. In 2 cases it dated from one month and a few days; in 5 cases it dated from two months and a few days; in 2 cases it dated from three months; in 2 cases it dated from four months; in 2 cases it dated from five to seven months and in 2 cases there were no records.

The duration of the sterilization was in 5 cases fifteen days; 8 cases one month and a few days; 2 cases two and three months; 2 cases four months; 2 cases withour record.

In 1 case the closure took place the day of the operation. There was no sterilization. This dated from five and a half months.

Seventeen cases were sent to me *chronic*. Fourteen from one month (11 closed Depage-Tuffier method and 3 decortications).

The microscopic examinations showed 10 times associations staphlo-diplo-cocci, batonnets-strepto. Once pneumococci and bacillus of Friedlander. Three cases are not mentioned.

When I practised the operation the wound dated: Two cases two months and a few days; 3 cases three months; 3 cases four months; 3 cases five months; 3 cases seven months; 1 case eight months.

The duration of the sterilization was in 2 cases fifteen days; 4 cases one month and a few days; 3 cases two months and a few days; 1 case three months and a few days; 1 case six months and a few days.

In 3 cases the pleural site was reopened, disinfected anew and the result was recovery. Three in less than a month. The microscopic examinations showed: One pneumococci and bacillus of Friedlander; 1 associations of perfringens, anaërobes, staphylococci, vibrion septique; 1 without record.

All of these cases except 2 actually recovered. The 2 were 2 bronchial fistulæ with failures; dilatation of the bronchi.

OBSERVATIONS ON EMPYEMA

By ASTLEY P. C. ASHHURST, M.D.
PHILADELPHIA, PA.

At the meeting of the American Surgical Association, twenty-six years ago my father opened the discussion on Empyema. He laid down the following six propositions for discussion:

1. "No operation is justifiable"
   (*a*) "unless the presence of pus is certain;"
   (*b*) "unless thorough treatment by medicinal agents, blisters, etc., has failed;"
   (*c*) "or unless the symptoms, dyspnea, etc., are so urgent as to demand immediate relief."

2. "The first operation should consist of simple aspiration with antiseptic precautions."

3. "That when the fluid has partially reaccumulated, as it almost certainly will do if purulent, incision and drainage should be practised."

4. "That drainage is best effected by making two openings, one at the lowest available point, and carrying a large drainage tube through the cavity from one opening to the other."

5. "That drainage should be supplemented by washing out the cavity with mild antiseptic fluids. When the lung has expanded and discharge has nearly ceased the tube should be shortened, the upper opening being allowed to heal and the tube being then gradually withdrawn through the lower opening."

6. "That when the lung is so bound down by adhesions that it cannot expand, resection of one or more ribs should be practised (Estlander's operation, so called), in order to allow collapse

of the chest wall and to promote healing by bringing the costal and visceral layers of the pleura into contact. The more extensive operations of Schede and Tillmans, while probably justifiable in exceptional cases, are not to be recommended for general employment."

The mortality following operation for empyema at that time averaged from 20 to 30 per cent., and such it still remained in the hands of the average surgeon during the generation which has elapsed since 1894. It is true that in most of the fatal cases the operation is not to blame for the fatality, but merely fails to save life; and that death is due to the underlying disease—empyema.

It is my object in this discussion to see, if possible, in what ways we have made an advance over the teachings and practices of a generation ago.

In the first place, I call attention to the *first proposition:* "That no operation is justifiable except under one of these conditions," namely, (*a*) that the presence of pus is certain, (*b*) that medical treatment has failed, or (*c*) that the symptoms are very urgent. Is anyone at present ready to go beyond this and adopt operation under any other circumstances? Do we not always receive our patients from the physician whose treatment has failed? True it is that the physician almost invariably has made one or more punctures of the chest, with or without success in locating pus, before he calls the surgeon into consultation; and that similarly even when pus has been found he is often loath to turn the patient over to the surgeon until he finds that the pus does reaccumulate; and even under the latter circumstances he may persist in the attempt to cure the patient without surgical assistance, by means of antiseptic injections into the pleural cavity. So eminent and able a surgeon as John B. Murphy, it will not be forgotten, advocated and practised injections of a 2 per cent. solution of formalin in glycerin for the cure of empyema; but no statistics of this treatment, showing its results, have ever been published, so far as I am aware. Nor has the treatment been generally accepted, though it must be acknowledged that in perhaps 2 or 3 per cent. of cases in which

the first aspiration shows only sero-pus, not frank pus, it is possible that a cure may be secured either by repeated aspiration alone or by aspiration followed by injection of formalin-glycerin solution, flavin, etc. So much, therefore, for the contingency which renders operation proper when medical treatment has failed.

Now if the symptoms are very urgent, that is if there is extreme dyspnea, cyanosis, bulging interspaces, etc., everyone admits the propriety of aspirating the chest whether or not it is certain beforehand that pus, not serum, is the cause of the symptoms. Finally, if the presence of pus is certain, comparatively few surgeons deny the propriety of attempting to evacuate it.

But one may rejoin, How is it possible to be certain that pus is present except by aspiration? Are the clinical history, the physical signs, the roentgen-ray findings and the symptoms always sufficient to render a diagnosis certain? To this I think we must reply in the negative; but I submit we must at the same time recognize that there are cases in which the presence of pus is so nearly certain, even when it cannot be located by puncture, that it is not only justifiable but imperative for the surgeon to open the thorax, search for the encapsulated empyema and effect its evacuation and drainage.

Some years ago, before the Section on General Medicine of the College of Physicians of Philadelphia, I presented[1] a plea for exploratory thoracotomy in just such cases of encysted empyema as these—cases where repeated puncture failed to locate pus; where the physical signs were suggestive; and where the symptoms were urgent. Realizing that the patients would die of their empyema unless the pus were drained, it seemed better to me to run the risk of failure to relieve them by exploration, rather than to fold my surgical hands together in impotence, and reiterate to the physicians who called me as consultant, what I know they had heard before in similar circumstances from other surgeons, a request to the physician to find the pus, with the

[1] "Surgical Experiences with Encapsulated Empyema and Abscess of the Lung; a Plea for Exploratory Thoracotomy," Medical and Surgical Reports of the Episcopal Hospital, Philadelphia, 1916, iv, 226.

statement that then, and then *only* would the surgeon undertake to drain it! Some surgeons, I may add, are even more conservative than this, and even though pus has been found by puncture by the physician, refuse to undertake any operation unless they themselves succeed in finding pus by a puncture made on the operating table. To my mind, pus is pus, whether found by the physician or surgeon; and I believe if it is found within the pleura the chances that it will be absorbed and cause no further trouble are so very remote that unnecessary delay in resorting to operation is unjustifiable. In some cases, of course, it is possible that an undrained interlobar empyema will drain itself by rupture into a bronchus; but it has yet to be shown that this event improves the patient's chance of recovery. Of two cases in my series (Cases 8 and 13) only one recovered.

In the report to which allusion has already been made, I recorded:

1. A case of empyema encapsulated between the upper and middle lobes of right lung, discharging through the bronchus; punctures negative; empyema found on exploratory operation; death from exhaustion and sepsis (Case 8 of the present series).

2. A case of empyema encysted between the upper and middle lobes of the right lung. Numerous punctures negative; empyema not located at exploratory operation, but later burst into drainage tract; ultimate recovery (Case 18 of the present series).

3. A case of empyema encysted between the left lung and the diaphragm. Punctures negative; empyema found on exploratory operation; recovery (Case 24).

4. A case of empyema encapsulated between the upper and middle lobes of the right lung. Puncture negative; empyema found on exploration; recovery (Case 25).

5. A case of empyema encapsulated between the left lung and pericardium. Punctures negative; empyema not found at exploratory operation; death eight days later from continuing sepsis (Case 26).

Now I think it is worthy of note that in the last-mentioned case had a roentgen-ray examination been available before operation,

it is extremely probable that the empyema might have been located when the chest was opened; since roentgen-ray examination subsequent to operation (after necessary repairs to the roentgen-ray plant) showed distinctly the outlines of the abscess cavity (Fig. 18), and since autopsy showed that the interlobar dissection made at the time of the operation almost had reached the abscess (Fig. 16).

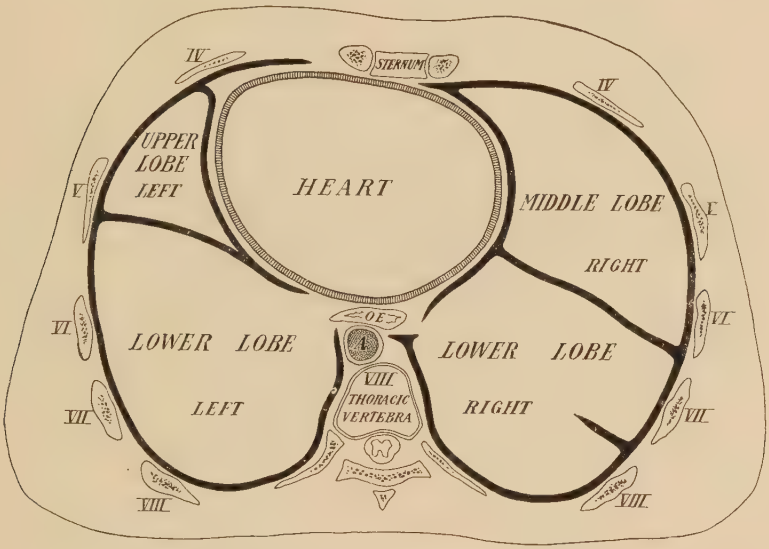

FIG. 1.—Cross-section of thorax at level of eighth thoracic vertebra. Pleural cavities outlined in black.

So that, with regard to the *first and second propositions* laid down twenty-six years ago, I think we must understand them as permitting and encouraging at the present time, *exploratory thoracotomy*, when symptoms are urgent, medical measures have failed, repeated punctures are negative and yet the presence of pus seems certain. Under these circumstances I have opened the thorax for exploration on six occasions (Cases 8, 18, 24, 25, 26, 30), and except in the two cases just mentioned (Cases 18 and 26) succeeded in finding and draining the empyema every

time; and while only 3 of these patients recovered, I am sure more patients would have died if I had not been willing to explore the thorax; and if I had been allowed to do exploratory thoracotomy sooner in Case 8, it is possible his life also might have been saved.

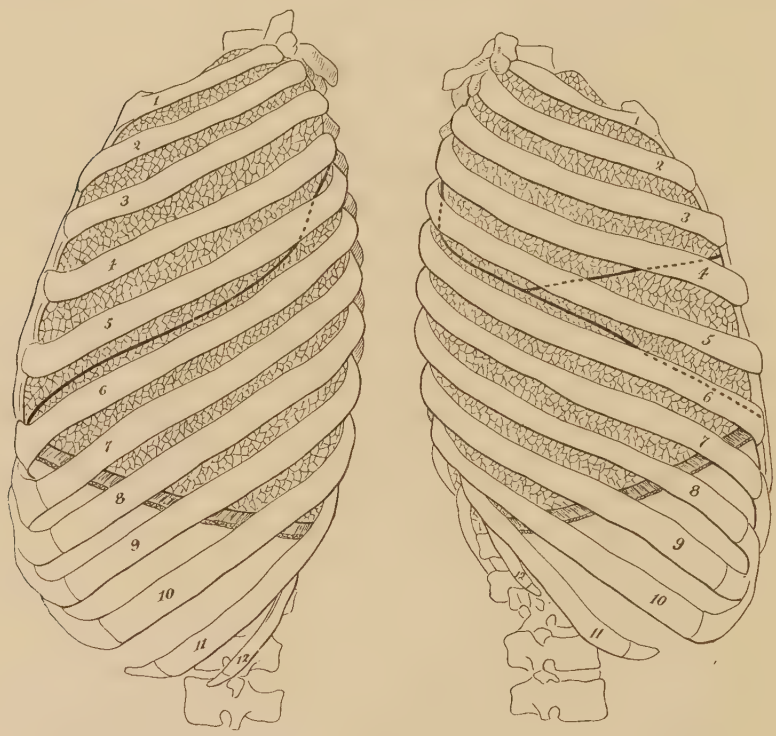

FIGS. 2 and 3.—Interlobar fissures and their relation to the ribs.

I must, however, put on record the following case, in which I opened the thorax after negative puncture and found no pus, the patient subsequently dying from pneumonia.

Mildred C., aged three years:

December 16, 1919. Admitted to the Episcopal Hospital, service of Dr. Carson, referred from Medical Dispensary by Dr. R. S. Hooker, with diagnosis of pneumonia. Has had a cold for

three weeks, with cough and expectoration; not confined to bed. Is fretful and unable to breathe properly at night. On admission: Temperature, 101° F. (by rectum); anemic, rachitic child, with Harrison's groove and rachitic rosary pronounced. Respirations very short and rapid. Expansion of chest very asymmetrical. Apex-beat of heart in midaxillary line about 6th interspace;

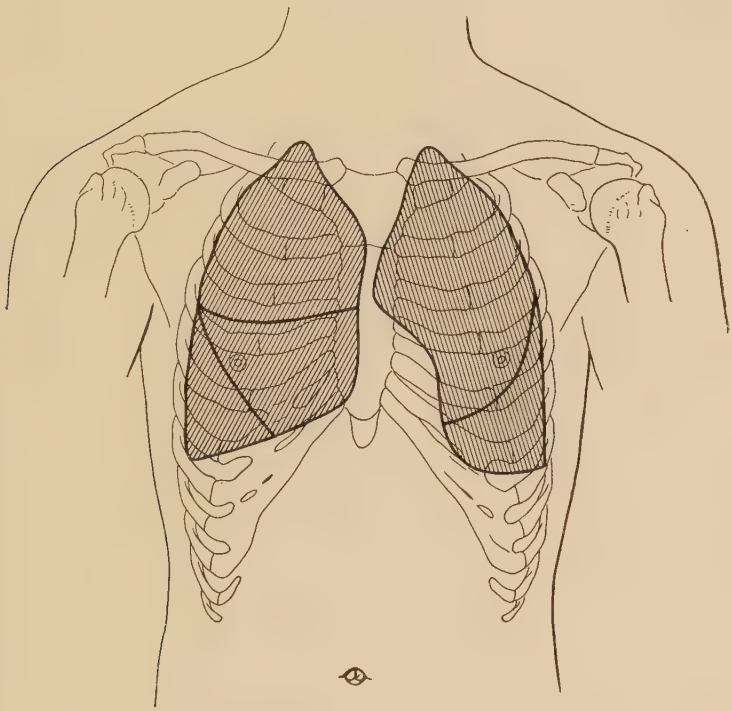

FIG. 4.—Fissures of the lungs viewed from the front.

marked pulsation over entire left chest. Rate rapid and sounds of good quality; no thrills or murmurs. Breath sounds rather harsh and many moist rales are heard over entire chest; no evidence of consolidation on percussion. Abdomen is distended, liver enlarged; no dulness in flanks. Extremities negative.

December 17. Slight cough, no expectoration. Throat is clear. Not restless.

December 21. Improving. Temperature 98° to 100° F.

December 30. Temperature steady at 99° for last two days. Much improved. Sent home.

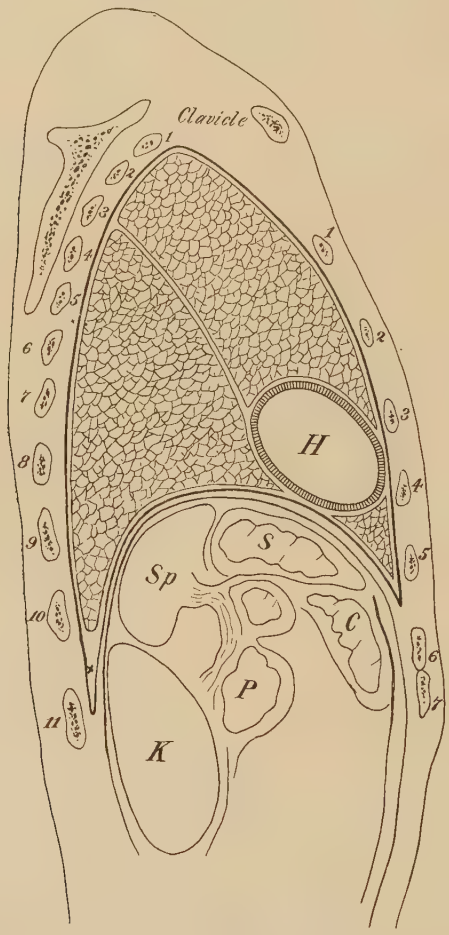

FIG. 5.—Sagittal section of thorax through middle of left clavicle.

January 6, 1920. Brought to Medical Dispensary and again seen by Dr. Hooker. Since being home the cough has continued and the child's general condition has been poor. Diagnosis of

left-sided empyema was made by Dr. Hooker from dulness and diminished breath sounds. Sent into Hospital and seen in receiving ward by Dr. Ashhurst. Puncture of left chest over area of impaired resonance is negative. Under local anesthesia 2 cm. of 10th left rib is resected, in midscapular line. Few adhesions between lung and diaphragm and between lobes of lung, but no pus found. Rubber tube inserted in expectation that pus will later rupture into drainage tract. Time of operation twenty minutes.

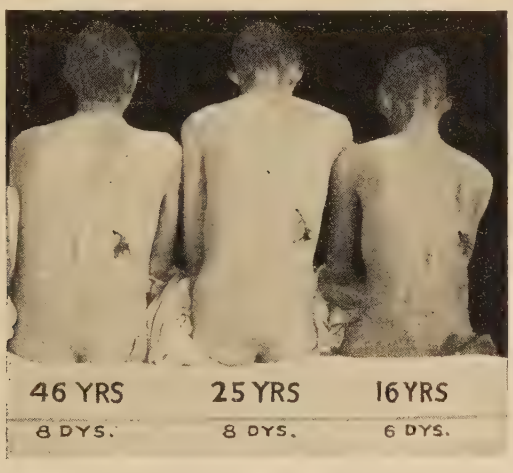

FIG. 6.—The site of election for draining an empyema; ninth, tenth or eleventh ribs posteriorly. The ages of the patients are given above, and the interval since operation below.

January 7. Condition poor. Lips cyanotic; respirations rapid and labored. No pus from tube. High-pitched, bronchial breathing at left apex.

January 8. Condition worse. Patient died at 5.15 P.M. Exploration of wound with finger after death could detect no adhesions between lobes and no evidence of empyema. Death from lobar pneumonia.

TECHNIQUE OF EXPLORATORY THORACOTOMY. Let me here repeat what I understand by exploratory thoracotomy:

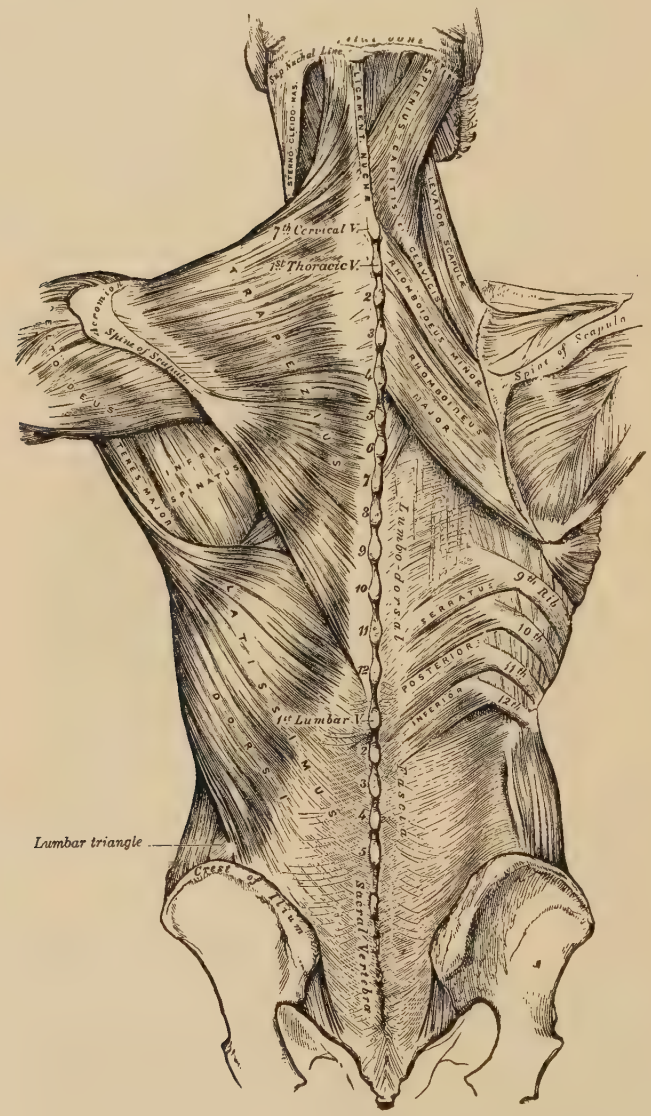

FIG. 7.—The ninth, tenth, eleventh and twelfth ribs exposed on the right side by removal of the latissimus dorsi. Note that the eighth and higher ribs are overlapped by the scapula. (From Gray's Anatomy.) Courtesy of Messrs. Lea & Febiger.

The patient is given, about thirty minutes before the commencement of the operation, a hypodermic injection of morphin (0.010 gm.) and atropin (0.00045 gm.); these doses may be larger in robust adults and smaller in children.

The patient is placed *prone* on the table, is made comfortable with pillows and his head is turned away from the side on which operation is to be done. The arms are placed above the head. Care is necessary to see that the patient lies flat on his abdomen and thorax and is *not turned on the healthy side*, as this will hinder respiration.

The proposed skin incision, over the 8th or 9th rib, back of the angle of the scapula, is then infiltrated with the local anesthetic;[1] and the intercostal nerves above and below the rib to be resected are blocked with an injection of about 2 c.c. each of the anesthetic fluid. These nerves are located by making the point of the needle impinge upon the rib above the nerve and then prodding the rib with the point of the needle until the lower border of the rib is found, when, after pushing the needle about 0.5 cm. further into the intercostal structures the injection is made. This should be at a point 8 to 10 cm. from the spinous processes. When the anesthetic has been properly injected the incision of the soft parts and the resection of the rib may be done absolutely painlessly. If, after the pleura has been opened and explored, more room is desired it is perfectly easy to resect the rib next above or below by (1) infiltrating the skin parallel to the spinal column upward or downward from the posterior end of the primary incision; (2) blocking a third intercostal nerve as already indicated; (3) raising the soft parts in a flap; and (4) resecting (subperiosteally) as much as is required of the next rib. Usually it is not necessary to divide the intercostal structures between the ribs resected, since when the ribs have been removed the intervening soft parts may be drawn aside by retractors. The length of rib to be resected depends on the size of the thorax and

[1] I prefer novocain, 1 to 400; but when this was not available, have used eucain 1 to 100; to every 30 c.c. of the solution is added one drop of adrenalin chloride solution (1 to 10,000); 30 to 90 c.c. usually are sufficient.

the extent of the intrathoracic exploration. As a rule, from 8 to 10 cm. is sufficient.

The pleura is opened between forceps, as the peritoneum is treated. Usually in cases of suspected empyema there is no collapse of the lung, which is adherent to the costal or diaphragmatic pleura. Even if the lung is not adherent it seldom collapses to less than half its bulk, when the patient is lying prone, and there is comparatively little respiratory disturbance. Wide opening of the pleura causes less dyspnea than a small and valve-like opening which favors the development of a tension pneumothorax.

After opening the pleura, and before conducting any exploration for an encysted empyema, the structures should be inspected. The lung may be so closely adherent to the diaphragm that it will be very difficult to recognize the line of junction. After ocular inspection, which may give a clue as to the first place to be searched for the abscess, the remainder of the pleural cavity should be walled off with hot moist gauze. Then with fingers, dissecting forceps or even knife and scissors (according to the density of the adhesions), the lung should be gently released. Usually it is well to clear the diaphragm first. If no pus is found here the packs are rearranged so as to protect the lower part of the pleural cavity, and a search is begun in the fissures of the lung. If the lung is not readily accessible its lower lobe is caught in two or three pairs of volsella forceps and maintained within reach. A single pair of volsella forceps is more apt to tear out and so damage the lung than are two or three simultaneously applied. Fixing the lung in the wound steadies the mediastinum, enables the diaphragm to resume its piston action, and thus ventilates the other lung. The lung is absolutely insensitive to these manipulations. Often it is not necessary to fix the lung in this way, and the surgeon proceeds at once to separate the lobes from each other. Usually where the adhesions are densest, pus will be found.

When pus is finally located, and has been evacuated, a rubber tube (with a lumen at least of 1 cm.) surrounded with loose

iodoform gauze is placed in the abscess cavity, the isolating packs are removed, and the wound is closed in layers, but not too tightly, around the drainage tract—the pleura and intercostal structures in one layer, then the skin.

The frequency of encapsulated empyema I am sure is not recognized. In my own experience it has been present almost in one-third of the cases. It is true of course, that every empyema is, in a sense, encapsulated; in other words, that it does not involve the entire pleural cavity. Pleuritis is in a way analogous to peritonitis: only so long as the effused fluid is sero-pus is it unconfined by adhesions. By the time frank pus has formed, in every case, whether in the peritoneum or the pleura, adhesions set certain limits, large or circumscribed, to the cavity in which pus is found. The only "free pus" that can exist in a body cavity such as the pleura or peritoneum is pus which is suddenly effused in overwhelming quantities into previously normal pleura or peritoneum, by the rupture of a localized abscess (appendicular or pelvic abscess, empyema of the gall-bladder, abscess of the liver or spleen, encysted empyema, etc.). But what I understand by encapsulated empyema is either one which comes into contact with the costal pleura at no point (Cases 18, 24, 25, 26, 27, 36) or over so small an area that it is difficult if not impossible to locate pus until after the thorax has been opened (Cases 7, 8, 28, 29, 35) or until an empyema necessitatis has formed. It should be recognized also that there may be more than one distinctly encapsulated empyema in the same patient (Cases 16, 29 and 35), and that occasionally an hour-glass empyema may exist, the channel of communication being large (as in Cases 37 and 43) or so small that drainage of one loculus is ineffective in producing cure of the other (as in Case 38). It is on account of the occurrence of cases such as these that I urge that, if the condition of the patient permits, exploration should be adequate to ensure that no such encapsulated foci are overlooked. (I am not prepared, however, to adopt Lilienthal's "major thoracotomy" under general anesthesia, so long as I continue to find a medium thoracotomy under local anesthesia satisfactory.) In

all cases with massive empyema, of course, removal of a large amount of the pus by aspiration should precede by one or two days the formal operation of thoracotomy, and in no case where the fluid can be removed by aspiration need drainage by thoracotomy be regarded as an emergency operation (*third proposition*).

Let me revert now to the *fourth proposition* I have quoted at the beginning of this discussion, namely, "That drainage is best effected by making two openings, one at the lowest available point, and carrying a large drainage tube through the cavity from one opening to the other." It seems to me that the doctrine of through-and-through drainage merely follows as a corollary in cases where the primary opening has been made too high; in other words, that if the primary opening is made at the site of election, which I regard as the 9th or 10th (occasionally the 11th or 12th) ribs near their angles (Fig. 6), it is unnecessary to make a counter-opening, as one is already at the "lowest available point." I repeat, that in cases of exploratory thoracotomy as well as in cases of massive empyema, I practise and recommend that the opening should be made at the site mentioned, even if the needle has shown pus in the 6th or 7th interspace. It is so nearly invariably the rule that the empyema cavity extends down to the diaphragm, and it is so easy after opening the pleura low down to drain an empyema which may extend already to within a few centimeters of the opening, by breaking through its limiting adhesions at their most dependent portion; and a higher opening unless supplemented by a counter-opening at the lowest available point gives rise to so very prolonged a convalescence, that I believe there are exceedingly few cases in which it is desirable to be limited in selecting the site for drainage by the location at which pus was found on puncture. Only once since I adopted this rule have I encountered an empyema situated so very high, and with the lower portion of the thorax so certainly intact, as to induce me to make a higher opening; in this patient (Case 28) the empyema appears to have formed between the lobes of the left lung and to have finally

come into contact with the parietal pleura between the vertebral column and the scapula at the level of the spine of the latter bone; and yet the drainage tract at this site, though it was nearly at the lowest level of the empyema cavity, nevertheless required over four months for healing.

Resection of a rib I regard as important in all cases. Intercostal incisions alone do not afford adequate drainage, and frequently secondary operations are required. I have employed it only once (Case 4) in a baby six months old; a month later it was necessary to resect a rib to improve the drainage, but two months after the first operation the patient died with unhealed sinus, probably from sepsis arising in the inefficiently drained pleura. In another case which came later under my care (Case 13), intercostal incision was employed by another surgeon, but this healed upon an infected cavity, and the empyema being undrained externally ruptured into a bronchus; finally, the original operative sinus opened again, and eventually I had to resect the 8th and 9th ribs; definitive healing then occurred in eight weeks. I have never seen necrosis of the rib ends and cannot believe the possibility of such an occurrence is to be regarded as contra-indicating rib resection.

Next we come to the *fifth proposition*, "That drainage should be supplemented by washing out the cavity with mild antiseptic fluids. When the lung has expanded and discharge has nearly ceased the tube should be shortened . . . and gradually withdrawn." With the very gradual shortening and withdrawal of the tube I am in entire accord, but I do not see that anything is gained by irrigations in the ordinary case of empyema. I suspect that the main function they served in my father's day was to keep the lumen of the through-and-through drainage tube open, and that the fluid injected at one end of the tube almost immediately escaped by the other end, without making a very extensive journey into the empyema cavity. And I am quite sure that in some cases injudicious irrigations are productive of harm. It is quite evident, I believe, that death in two of my patients (Cases 30 and 31) some weeks after they passed from

under my care is directly attributable to sepsis arising in the wound in the thoracic wall, not in the empyema cavity, and that this sepsis was produced by irrigation, and probably aided in Case 31 by too tight closure of the wound of the second operation.

That irrigations with Dakin's hypochlorite solution, by the Carrel technique, are of no value in any cases I am not prepared to admit. But I am quite thoroughly convinced that in the vast majority of cases of empyema they are quite unnecessary, and that except in cases of very long standing, with much thickened pleura and non-expansile lung, healing will occur quite as promptly, as pleasantly and as definitively by means of large and dependent drainage. I do not think it can be denied that in many patients of the class of cases just mentioned the irrigations with Dakin's solution will eat away the inflammatory lymph deposited on the visceral pleura and that the lung will thereafter expand sooner and more completely than if such irrigations had not been employed. Nor can it be denied that it is possible to sterilize an empyema cavity by this means, at least temporarily, and then to permit the thoracic wound to close upon the sterile pneumothorax; but I also know that the same event may take place simply as the result of efficient drainage without any irrigations, at any time (Cases 14 and 35). Speaking for myself, I may say that I have never employed the Carrel-Dakin treatment for empyema, and that I should be surprised to encounter a recent case in which I thought it indicated.

The *sixth proposition*, which has to do with unhealed empyema cavities, I am sure must undergo great modification in view of advances in surgery since it was formulated. I am convinced that unhealed empyema is infrequent compared to its incidence a generation ago, largely due to the earlier recognition and more efficient treatment of the acute cases. Indeed it is probably true that if any surgeon conscientiously follows up the treatment the occurrence of an unhealed case will be extremely rare. One patient (Case 6) on whom I operated in 1909 is known to have had his sinus still unhealed nine months after operation; but among the remainder of my patients the longest period to

healing was seven months, and in not one of those who remained under my care was a second operation required. One patient (Case 31) who passed from my care two weeks after the operation, and from whom the tube was removed too early, was reoperated on later for an accumulation of pus, and eventually died of sepsis arising in the thoracic wound of the second operation. Another patient (Case 35) who was tuberculous and whose thoracic wound healed within seven weeks upon a pneumothorax, five months later had a little discharge from the sinus which healed again in three weeks; twenty-two months after my operation another empyema developed and was drained; seven months after this second operation the patient moved to Colorado, and since that time (September, 1919) he has had one slight reaccumulation which was opened and healed at the end of six weeks. He writes (March, 1920) that he is now apparently in perfect health.

I should like to say a good word for bismuth injections in the treatment of unhealed sinuses, as advocated by Ochsner. In one patient (Case 36) (the only one in whom I began to despair of seeing the sinus close spontaneously and in whom removal of the tube was followed on several occasions by rise of temperature), I had just about determined on reopening the wound (twelve weeks after operation) and injected it with 10 per cent. bismuth paste to ascertain the outlines of the cavity by skiagraphy; the next day the sinus was found healed, with the paste retained, and the wound remained healed when the patient was last seen five months later.

Unhealed empyema must be rare in Philadelphia, as I have had occasion to operate on not more than two patients.

In the *first patient*, John K., aged sixteen years, operation had been done by another surgeon April 19, 1911, for a left-sided empyema five weeks after the onset of pneumonia. On June 11 the tube was not found when the wound was dressed, and on June 17 the patient was discharged with unhealed sinus. Soon after this he came under my care in the Episcopal Hospital and was treated with bismuth injections. The sinus sometimes would close for a few days but always reopened. Finally a

roentgen-ray picture was taken and showed the tube lying in the pleural cavity (Fig. 8.)

September 15, 1911 (three months after the first operation), under ether, I resected about 6 cm. each of the 7th, 8th and 9th ribs (the 8th, which had been excised at the former operation, was of cartilaginous consistency). The drainage tube and large masses of bismuth paste were removed and a fair amount of pus was evacuated. All the lymph adherent to the visceral pleura that could be detached was removed, all the adhesions of the lung to the parietal pleura were broken through and the cavity thoroughly wiped with iodoform gauze. One long and wide strip of iodoform gauze was left in for drainage.

In two weeks the wound was practically closed and was firmly healed by October 7, 1911, twenty-two days after operation.

In the *second patient*, James K., aged fifty-one years, there was a history of some severe injury to the chest twenty-eight years previously. He had had many attacks of "pleurisy" following occasional attacks of rheumatism.

May 24, 1913. Admitted to the Episcopal Hospital, Dr. Mutschler's service. About fifteen months previously he had developed a heavy cough followed by swelling in the left thorax, diagnosed by family physician as tumor. The family physician incised this swelling and quite a large quantity of pus was removed. The sinus healed up after a long time. There had been no discharge for the past four or five months. About ten days ago he began coughing again and the sinus opened and discharged pus. Has been having night-sweats. Does not spit any blood.

On admission: Sinus in left thorax between 6th and 7th ribs, in nipple line, from which small amount of pus is oozing. Two scars of healed sinuses. Temperature 101°. Large-framed man, thorax well developed, expansion limited on left, which is dull front and back below 4th rib, with distant breath sounds and harsh, crepitant rales.

May 26, 1913. Roentgen ray 6442—heart displaced to right by pus in left pleura up to 6th rib.

May 27. Operation by Dr. Mutschler (ether): 6th left rib excised in anterior axillary line and much pus discharged (pneumococci).

May 30. Temperature normal.

FIG. 8.—Rubber tube lost in empyema cavity for three months. Bismuth injections unavailing. Sinus healed permanently three weeks after removal of tube and Estlander operation.

June 28. Still free discharge. Temperature hectic since last note, 98° to 101°. Roentgen ray 6640—heart still to right, some collapse of left lung.

July 25. Still same amount of discharge. Temperature, 98° to 100°.

August 1. Service taken over by Dr. Ashhurst. The patient walks about and does not complain of anything; general condition about same. Dressings always saturated overnight. Coughs a little.

August 8. Roentgen ray 7213 (bismuth) shows large cavity extending from 11th rib to upper thorax (Fig. 9).



FIG. 9.—Empyema cavity, *L*, injected with bismuth paste, showing outlines of calcified pleura; ten months' duration. Died ten days after Estlander operation.

August 23. Discharge no less. Temperature, 98° to 100°.

August 29. Operation; ether. (Ashhurst.)

Patient prone. Incision 12 cm. long made over sinus of previous operation (over 6th left rib in anterior axillary line), and about 10 cm. each of the 6th, 7th, 8th and 9th ribs resected, from their angles forward. This uncovered very dense parietal pleura, which was found to be lined by a calcareous deposit about 5 mm. thick, as were also the exposed surfaces of the lung and diaphragm. The rigid walled cavity extended as high as the finger could reach through the wound. The calcareous lining was peeled off the parietal pleura, the diaphragm, and the lung,

except at the apex of the cavity, where a few plates had to be left, as it was impossible to remove them without tearing the lung. The lung was found still to be bound down by dense pleura, beneath the calcareous deposit, but the condition of the patient did not warrant continuing the operation by decortication or discission of the pleura. The lung moved a little more in respiration than before the calcareous plates were removed, but it was evident that only by collapse of the soft parts could the cavity be obliterated; and though complete obliteration was not hoped for it was thought the marked reduction in size of the cavity would considerably reduce the discharge and promote the patient's comfort. Drainage was provided by iodoform gauze and a large rubber tube. The wound was closed in layers about the drainage.

August 31. Dressed, dressings soiled but not saturated, as before operation. No calcareous matter could be felt by finger introduced through wound.

September 6. Temperature fell after last dressing to normal and has not varied more than $\frac{1}{2}°$ since. Today rose to 100°. Seems irrational, no cough.

September 7. Restless, on gradual decline. Pulse weak, rapid (150). Temperature, 101°. Respiration, 34.

September 8. Died 6 A.M. Temperature having risen rapidly to 104°. No postmortem, but by opening wound calcareous matter found only around apex of cavity. Lung and diaphragm covered with gray lymph, phlegmonous in type.

It is a question in my mind whether in this latter patient the condition of his pleura did not date from his original injury twenty-eight years previously. Certainly it would be very unusual for such dense calcareous deposits to have occurred between the time of the two operations done in the Episcopal Hospital only three months apart; but the presence of a hemorrhagic pleural effusion many years ago, which remained unabsorbed, will account for the patient's repeated attacks of pleurisy as well as for the densely calcareous deposit. In this connection the appearance of the roentgen ray in Case 26 (Fig. 18) is sugges-

tive that here also a cavity containing sterile fluid may have persisted for over four years, this patient having been under treatment in another hospital for supposed empyema, which could not be located, that length of time before she came under my care with recurrence of similar symptoms.

Conclusions. From this discussion it seems to me that the propositions laid down twenty-six years ago must be modified in the following particulars:

1. Cases of pleural effusion suspected of being purulent should be punctured (with hollow needle attached to air tight syringe); and if the effusion is massive, most of it should be removed by aspiration one or two days before thoracotomy is undertaken.

2. If the fluid found on puncture is serous, or seropurulent, thoracotomy usually may be postponed, until frank pus has formed, as this delay will permit the formation of firmer adhesions and thus prevent complete collapse of the lung when the empyema is opened. Cures of such seropurulent effusions, however, have so rarely occurred without final resort to thoracotomy that attempts to cure them by injection of antiseptic fluids into the unopened pleura are usually detrimental to the patient.

3. If in a case of suspected empyema the symptoms are urgent, but pus cannot be found by puncture, exploratory thoracotomy should be undertaken in an effort to locate and drain the pus.

4. The operation of thoracotomy for empyema should provide free and dependent drainage, secured by resection of a rib, usually the 9th, 10th, or 11th in front of its angle (Fig. 7). This operation may be done with perfect satisfaction to both patient and surgeon *under local anesthesia*, and in most cases this is preferable to a general anesthetic. (I have used local anesthesia with satisfaction in 27 patients, including one baby sixteen months of age; and have employed it in every one of my last 20 patients, some of them requiring rather extensive intrathoracic manipulations. It is interesting and perhaps significant to note that only two patients in the entire series (Cases 3 and 11) developed pneumonia of the opposite lung after operation; and that both these patients had taken ether.)

5. Postoperative irrigations are unnecessary, unless after several months the lung shows no tendency to expand; when the use of Dakin's fluid may prove beneficial. In selected cases (those with small cavity) injections of bismuth paste may procure closure of the sinus.

6. If the cavity cannot be made to heal by these means the surgeon should do a major thoracotomy, combined with decortication of the lung and discission of the pleura; and in some cases resection of a number of ribs to permit the chest wall to collapse in part and meet the expanding lung.

* * *

In closing, I may be permitted to give a summary of my own cases, few in number, perhaps, but studied with such attention as was possible. Among 43 patients there have been 9 deaths, a general mortality of 21.4 per cent. Among the first 9 of these patients there were 5 deaths, 3 of which were in babies less than a year of age. But if there are included only the last 34 patients operated on since adopting the system of wide and dependent drainage,[1] there were in this number only 4 deaths, a mortality of 12 per cent. Moreover, of these 4 fatal cases:

(*a*) In the first (Case 22) the child also had extensive gangrenous stomatitis (noma) and died from this.

(*b*) In the second (Case 26) the empyema (which was encapsulated against the pericardium) was not found at operation, and the patient died eight days after operation unrelieved.

(*c*) (*d*) In the third and fourth cases (Cases 30 and 31) death occurred some weeks after the patients passed from my care, and as the result not of their empyema, but from sepsis arising in the thoracic wound and brought on by irrigations.

From which facts I conclude that the mortality of empyema, if promptly and efficiently treated need not exceed 10 per cent.

The average time required for firm healing of the thoracic wound in 24 cases in which this is known, was just over nine

[1] It is proper that I should give due credit to T. Turner Thomas, whose studies in 1913 turned my attention particularly toward the value of dependent drainage.

weeks, the shortest time being three, and the longest thirty weeks. In those patients (18 in number) who remained under my personal supervision, the average time until firm healing was just over seven weeks; the shortest time being three weeks, and the longest twelve weeks.

In 5 patients (Cases 30, 31, 36, 39 and 40), two of whom (Nos. 36 and 39) were still under my personal care at the time, there was more or less interruption to the progress of wound healing, by pocketing of pus; and in 2 of my early cases (Nos. 4 and 5) where dependent drainage was not secured at the first operation, secondary operation was required some time after they passed from my care. Final closure of the wound was secured in all cases traced (32 out of 34 patients who recovered) without an Estlander or similar operation.

* * *

Certain cases in the subjoined list deserve more than passing attention:

Cases of encapsulated empyema, with limited contact with parietal pleura—Cases 7, 8, 9, 15, 16, 21, 28.

Cases of encapsulated empyema without any contact with parietal pleura—Cases 18, 24, 25, 26, 27, 36.

Cases of two distinctly encapsulated empyemata within same pleural cavity—Cases 16, 29, 35.

Cases of hour-glass empyema—Cases 37, 38.

Cases of empyema necessitatis, Cases 6, 17 (pulsating) 21, 38.

Cases of empyema as part of a general septicemia—Cases 14 (peritonitis and abscess), 24 (streptococci in blood), 33 (jaundiced), 34 (pericarditis, endocarditis), 38 (metastatic abscess and pyemia).

Cases of encapsulated empyema rupturing through a bronchus —Cases 8, 13.

Cases of tuberculous empyema—Cases 12, 17, 35.

Case in which drainage tube fell into empyema cavity—Case 16

Case complicated by noma (gangrenous stomatitis)—Case 22.

Case complicated by independent pleural effusion on same side—Case 21.

The subjoined table gives the salient features in all the cases encountered, and, in accordance with the motto, "Ars medica tota est in observationibus," abstracts of the case histories are appended.

Case Histories

Case 1.—Empyema, right. Recovery.

John C., five years.

September 22, 1906. Admitted to the Children's Hospital, Dr. Hutchinson's service.

Ill for six weeks with pneumonia at Atlantic City; then in Children's Hospital (Dr. Charles H. Weber's service) for the last three weeks. Empyema suspected, but Dr. Weber had four dry taps. Last night pus was found (diagnosed as interlobar in position, by Dr. Weber).

September 22, 1906. Operation (Dr. Ashhurst); ether. Excised one inch right 8th rib, in midaxillary line. Pleura thickened (5 to 6 mm.); incised and incision dilated with hemostat. Pus oozed out with little force, then as child began to cry on coming out of ether (ammonia substituted for ether after opening pleura) pus was ejected with much force, creamy, pale yellow, sour. Pus appeared to extend from diaphragm up, not interlobar (only). Before operation respirations were 60, fell to 40 immediately after and to 22 to 24 after two hours. Pus gave a pure culture of pneumococci.

November 8, 1906. Tube out.

July 27, 1907. Seen at Country Branch of Children's Hospital, in excellent health; wound closed.

Case 2.—Empyema, left. Died one week (enteritis).

Joseph S., five months.

July 26, 1907. Admitted to the Children's Hospital, Dr. E. B. Hodge's service.

Had been ill three weeks with pneumonia. Dr. Hand aspirated (7–25–07) about 50 c.c. of pus (diplococcus, biscuit-shaped).

ANALYSIS OF OPERATIONS FOR EMPYEMA.

No.	Name, age and date of operation.	Side affected.	Duration of illness before operation including a preceding pneumonia.	Metapneumonic or tuberculous; and culture.	Massive or encapsulated.	Operation and anesthetic.	Result.	Sinus healed.	Remarks.
1	John C. 5 yrs. Sept. 22, 1906	R.	6 weeks +	Metapneumonic pneumococci	Massive	8th rib; ether; pus, creamy, pale yellow, sour	Recovered	Under 10 mos.	
2	Joseph S. 5 months July 26, 1907	L.	3 weeks +	Metapneumonic diplococci	Massive	8th rib; ether; pus thick, inodorous	Died	..	Death in one week from enteritis.
3	Ed. W. 11½ months July 25, 1908	L.	2 weeks +	Metapneumonic diplococci and staphylococci	Massive	8th rib; ether; 100 c.c.; thick creamy pus	Died	..	Death in two weeks from pneumonia of other lung.
4	Kath. P. 6 months July 24, 1909	L.	4 weeks +	Metapneumonic pneumococci	Massive	Intercostal incision, 7th interspace; pus, 500 c.c.; ether; rib resected one mo. later	Died	..	Death in two mos. from sepsis.
5	Jos. T. 6 years July 24, 1909	L.	5 weeks +	Metapneumonic culture (?)	Massive	8th rib; ether; pus, 100 c.c.; second rib resected one mo. later	Recovered	Over 9 mos.	
6	Elias R. 3 years July 29, 1909	L.	5 weeks +	Metapneumonic culture (?)	Massive; "necessitatis"	6th rib; ether; 500 c.c. creamy pus	Recovered	Yes	Not traced.
7	Sam S. 5 years July 29, 1909	L.	11 days	Metapneumonic mixed (colon)	Encapsulated; parietal	8th rib; ether; pus thin and turbid; colon smell	Recovered	Yes	Not traced.
8	Wm. L. 50 years Sept. 14, 1912	R.	2 months +	Metapneumonic staphylococcus, diplococcus, bacilli, etc.	Encapsulated; interlobar; discharging thru bronchus	8th and 9th ribs; eucain; 30 c.c. extremely fetid pus	Died	*	Death in two days from sepsis.
9	Minnie Y. 59 years Dec. 25, 1912	L.	19 days	Metapneumonic pneumococcus	Encapsulated parietal	11th rib; cocain; semi-solid pus	Died	*	Death in six days from bedsores, etc.
10	Mary O'B. 5 years Jan. 22, 1913	L.	2 weeks	Metapneumonic pneumococcus	Massive	9th rib; ether; 200 c.c. yellow, curdy pus	Recovered	*8 weeks	
11	James F. 7 years Feb. 14, 1913	L.	3½ weeks	Metapneumonic pneumococcus	Massive	11th rib; ether; 500 c.c. yellow, creamy and curdy pus	Recovered	3½ mos.	In good health seven years later.

12	Walter H. 15 years Aug. 26, 1913	L.	10 months	Tuberculous; smear: micrococci; culture: no growth	Massive	11th rib; ether; greenish pus	Recovered	*4 weeks	
13	Edna P. 7 years Aug. 27, 1913	L.	6 weeks	Metapneumonic diplococcus	Massive	Intercostal incision, 6th interspace; 8th and 9th ribs resected two months later; bloody pus	Recovered	4 months after intercostal incision *8 weeks after rib resection	
14	Margaret P. 12 years Nov. 1, 1914	L.	12 days	Followed peritonitis (appendicitis?); streptococcus	Massive	8th rib; gas; 150 c.c. pus; later, drainage of intraperitoneal pelvic abscess	Recovered	*10 weeks	Streptococcus grown from blood; also metastatic osteomyelitis of phalanx (staphylococci) and furunculosis
15	Hugh McI. 43 years Nov. 8, 1914	R.	4 weeks	Metapneumonic pneumococcus	Encapsulated parietal	9th rib; eucain	Recovered	Yes	In good health one year later.
16	Joseph R. 19 years Dec. 4, 1914	L.	3 weeks	Metapneumonic diplococci	Encapsulated; 2 parietal empyemata	8th rib; eucain	Recovered	?	Tube fell into cavity after operation.
17	Gerald L. 28 years Dec. 11, 1914	L.	3 weeks +	Tuberculous for seven years; streptococcus	Massive; *pulsating empyema necessitatis*	9th rib; eucain; prune-juice pus smelling of hydrogen sulphide	Recovered	?	Not traced.
18	Tony V. 2 years Nov. 23, 1915	R.	5 weeks	Metapneumonic streptococcus, staphylococcus	Encapsulated interlobar	7th rib; ether	Recovered	*10 weeks	In good health one year later.
19	Joseph F. 9 years Nov. 30, 1915	R.	17 days	Metapneumonic; mixed (colon)	Massive	9th rib; gas; 500 c.c. colon-smelling pus	Recovered	9 weeks	In good health nine months later.
20	Francis P. 11 years Dec. 3, 1915	R.	2½ weeks	Metapneumonic streptococci, diplococci, staphylococci	Massive	7th rib; ether; 200 c.c. pus; seven weeks later resection of 6th and 7th ribs; 150 c.c. thin fetid pus (streptococci only)	Recovered	5 months (3 mos. after second operation)	In good health one year later.
21	Joseph B. 34 years Dec. 10, 1915	L.	3 weeks +	Metapneumonic staphylococcus	Encapsulated; parietal *empyema necessitatis* with independent pleural effusion	11th rib; novocain; turbid fluid, 300 c.c.; intercostal incision, 7th interspace; thick yellow inodorous pus	Recovered	*7 weeks	In good health nine months later.
22	Edward S. 7 years Dec. 11, 1915	R.	3 weeks +	Metapneumonic staphylococcus	Massive	8th rib; gas	Died	*	Death one and a half days from noma of mouth.

* Indicates that the patient remained under author's care until final recovery or death.

ANALYSIS OF OPERATIONS FOR EMPYEMA—*continued.*

No.	Name, age and date of operation.	Side affected.	Duration of illness before operation including a preceding pneumonia.	Metapneumonic or tuberculous; and culture.	Massive or encapsulated.	Operation and anesthetic.	Result.	Sinus healed.	Remarks.
23	James C. 3 years Jan. 7, 1916	L.	3 weeks +	Metapneumonic pneumococcus	Massive	10th rib; ether; 250 c.c. creamy pus	Recovered	*9 weeks	Measles during convalescence; in good health 7 mos. later.
24	Philip G. 14 years Jan. 14, 1916	L.	4 weeks	Metapneumonic streptococcus	Encapsulated between lung and diaphragm	10th rib; gas; 500 c.c. pus	Recovered	7 months	Streptococcus from blood; in good health 4 yrs. later.
25	Wm. B. 30 years Jan. 14, 1916	R.	9 weeks +	Metapneumonic pneumococcus	Encapsulated interlobar	9th rib	Recovered	*3 weeks	Not traced.
26	Kate D. 38 years Aug. 5, 1916	L.	6 weeks +	Metapneumonic	Encapsulated; interlobar, against pericardium	7th and 8th ribs; novocain	Died	*	Death in eight days, unrelieved; pus not found at operation.
27	James McG. 30 years Nov. 17, 1916	L.	3 weeks	Metapneumonic; smear and culture negative	Encapsulated between lung and diaphragm	9th and 10th ribs; eucain	Recovered	*5 weeks	In good health three and a half years later.
28	Wm. B. 20 years Nov. 17, 1916	L.	4 weeks	Metapneumonic	Encapsulated; parietal and interlobar	4th and 5th ribs; eucain	Recovered	Over 4 months	In good health three and a half years later.
29	John L. 23 years Dec. 29, 1916	L.	3½ weeks	Metapneumonic pneumococcus	Encapsulated; two separate empyemata, both parietal	9th rib; eucain	Recovered	*7 weeks	In good health three years later.
30	Stanley K. 9 years Jan. 16, 1917	R.	2 weeks +	Metapneumonic; smear and culture negative	Massive	11th rib; eucain; reddish brown pus	Died		
31	Robert S. 7 years Jan. 18, 1917	L.	3 weeks +	Metapneumonic diplococcus, pneumococcus	Massive	11th rib; eucain; reddish brown pus	Died		
32	Whitman, L., 46 years Jan. 24, 1917	R.	3 weeks +	Metapneumonic diplobacillus	Massive	11th rib; eucain; 250 c.c. creamy inodorous pus	Recovered	6 weeks	In good health three years later.
33	Wm. B. 26 years Jan. 24, 1917	R.	2 weeks +	Metapneumonic pneumococcus	Massive	11th rib; eucain; 1000 c.c. curdy yellow pus	Recovered	Not traced	Desperately ill before operation (jaundiced).

34	Wm. D. 16 years Jan. 26, 1917	R.	3 weeks	Metapneumonic pneumococcus	Massive	11th rib; eucain; 500 c.c. creamy yellow pus	Recovered	*6 weeks	Desperately ill before operation (bilateral pleuritis, endocarditis and pericarditis); in good health three years later.
35	Edward H. 32 years Apr. 8, 1917	R.	10 weeks +	Tuberculous; metapneumonic diplococcus	Encapsulated; two distinct empyemata: (1) between lung and diaphragm; (2) parietal	9th rib; eucain	Recovered	*7 weeks	No lung symptoms three years later (lives in Colorado).
36	Oliver C. 21 years July 26, 1919	R.	3 weeks	Metapneumonic pneumococcus	Encapsulated between lung and diaphragm	10th rib; novocain; 150 c.c. creamy yellow pus	Recovered	*12 weeks	In good health eight months later.
37	Isadore M. 11 years Aug. 8, 1919	R.	19 days	Metapneumonic pneumococcus	Massive; "hourglass empyema"	10th rib; novocain; 1000 c.c. pus	Recovered	*3½ weeks	In good health seven months later.
38	Evelyn S. 19 years Nov. 18, 1919	R.	3 weeks	Metapneumonic streptococci	Massive; "hourglass empyema necessitatis"	9th rib; novocain; 250 c.c. yellow creamy, malodorous pus	Recovered	*8 weeks	Desperately ill before operation; metastatic abscess under L scapula during convalescence; in good health six mos. later.
39	Gertrude W. 4 years Dec. 6, 1919	R.	4 weeks	Metapneumonic diplococci and staphylococci	Massive	9th rib; novocain; 100 c.c. pus	Recovered	*6 weeks	In good health four months later.
40	Thomas W. 16 mos. Jan. 9, 1920	L.	3 weeks	Metapneumonic pneumococci	Massive	10th rib; novocain; thin serous pus	Recovered	14 weeks	In good health four months later.
41	Alice M. 29 years Feb. 20, 1920	R.	3 weeks	Metapneumonic pneumococci	Massive	11th rib; novocain; 500 c.c. creamy yellow pus	Recovered	*7½ weeks	In good health five months later.
42	Theresa D. 27 years Feb. 20, 1920	R.	17 days	Metapneumonic pneumococci	Massive	10th rib; novocain; 500 c.c. thin turbid flaky pus	Recovered	*7½ weeks	
43	James S. 34 years Apr. 9, 1920	L.	8 weeks	Metapneumonic pneumococci	Massive; "hourglass empyema"	10th rib; novocain; 1000 c.c. greenish yellow creamy pus	Recovered	9 weeks	In good health four months later.

* Indicates that the patient remained under author's care until final recovery or death.

July 26, 1907. Operation (Dr. Ashhurst); ether. Resected 2.5 cm. of 8th left rib, about 100 c.c. thick, inodorous pus. Time six minutes. Child very ill. Temperature normal after operation and did well for four or five days, then got severe enteritis, with high fever. Lungs clear, wound clean.

August 2, 1907. Died, one week after operation, from enteritis.

Case 3.—Empyema, left. Died two weeks (pneumonia of other lung).

Edward W., eleven and a half months.

July 25, 1908. Admitted to the Children's Hospital, Dr. E. B. Hodge's service.

Has been in Hospital about two weeks with pneumonia; temperature came to normal, but rose again on July 22 and July 23. Dr. Hand aspirated July 24 and got 25 c.c. pus.

Examination: No dyspnea lying down; lessened expansion, dulness, absence of breath sounds at left base. Mucous rales at apex.

July 25, 1908. Operation (Dr. Ashhurst); ether. Excised 2 cm. rib (about 8th) below angle of scapula, patient on back. About 100 c.c. thick, creamy pus, slight odor (staphylococci and few diplococci). Rubber tube.

July 28, 1908. Since operation almost no discharge of pus.

July 29, 1908. Temperature up, cyanosis, dull over lower part of upper lobe.

July 30, 1908. Dr. Hand suggested collection of pus.

July 31, 1908. Sinus explored with finger, only firm adhesions found, lung expands well. No pus by needle inserted in dull area. Bronchial breathing above empyema cavity.

August 4, 1908. Pneumonia in right lung discovered.

August 8, 1908. Died of pneumonia of right lung.

Case 4.—Empyema, left. Died two months (sepsis from pleura).

Katharine P., six months.

July 22, 1909. Admitted to the Children's Hospital, Dr. E. B. Hodge's service. Pneumonia four weeks ago. Aspirated (Dr. Ashhurst) and 100 c.c. pus (pneumococci) evacuated. Did well until July 24, when dyspnea returned.

July 24, 1909. Operation by Dr. Ashhurst (ether): Intercostal (7 to 8th) incision, left; about 500 c.c. of pus evacuated, and tube inserted.

July 27, 1909. Doing well.

August 2, 1909. Has had rapid respiration, 72 to 84; pulse, 160 to 170. Temperature 101° to 102° for last few days. Wound doing well. Eats well; bowels normal.

August 4, 1909. After taking ammonium carbonate, syrup of senega, respirations are only 60 to 70. Pulse, 140 to 150. Temperature, 99°. Still miserable.

August 14, 1909. Much improved.

August 19, 1909. No more improvement.

Later in August Dr. Hodge resected a rib to secure better drainage. In September the child was taken home; taking a milk mixture. Death toward end of September, two months after operation, perhaps from sepsis from the pleura, the wound not having healed.

Case 5.—Empyema, left. Recovery.

Joseph T., six years.

July 24, 1909. Admitted to the Children's Hospital, Dr. E. B. Hodge's service.

Had pneumonia five weeks ago. Aspirated ten days ago at home, and 1 liter of pus obtained. On admission the apex beat of heart is to right of sternum. Marked orthopnea; after aspiration of 100 c.c. no more pus would run.

Operation (Dr. Ashhurst) under ether, resection of 2 cm. of 8th rib in left anterior axillary line and evacuation of about 1 liter of pus and flocculent lymph.

July 27, 1909. Pulse still weak, no fever. Lying down for first time since operation. Bloody pus discharging.

July 29, 1909. Tube removed, only blood-stained serum discharged and smaller tube replaced.

August 3, 1909. Tube left out; nothing in sinus. Slight discharge.

September, 1909. Dr. Hodge resected another rib for better drainage. Doing well in end of month.

March 9, 1910. Readmitted and record shows only use of bismuth paste. Discharged April 23, 1910. "Discharge disappearing rapidly." Cannot be traced.

Case 6.—Empyema, left. Recovery.

Elias R., three years.

July 29, 1909. Admitted to the Children's Hospital, Dr. E. B. Hodge's service.

Pneumonia five weeks ago. Developed deformity of chest which family physician called "postpneumonic pigeon-breast." On admission had empyema necessitatis(left), apex-beat in second interspace right. Whole left thorax tense, with fluid between ribs and the skin and muscles. Aspirated by resident, large quantity of creamy pus.

July 29, 1909. Operation, ether. Resected 2 cm. of 6th or 7th rib in anterior anxillary line and evacuated over 500 c.c. of less creamy pus.

July 30, 1909. Sitting up and playing around bed.

August 4, 1909. Uneventful recovery after this date.

Case 7.—Empyema, left. Recovery.

Sam S., five years.

July 22, 1909. Admitted to the Children's Hospital, Dr. Hand's service.

Illness began July 18 with chill and fever. Has had temperature of 103° since. Pneumonia in left lung. Empyema suspected yesterday, but two punctures by Dr. Hand drew no pus. Transferred to Dr. Hodge's service July 29.

July 29, 1909. Today Dr. Ashhurst punctured twice in anterior axillary line, left, where auscultation and percussion indicated pus, but found nothing. Then punctured in 7th interspace in posterior axillary line, where was most tenderness and very slight edema, but no auscultatory signs, and drew very foul pus from considerable depth Expectoration slight but very foul, like pulmonary abscess (mixed growth).

Operation by Dr. Ashhurst (ether). Resected 3 cm. of 8th left rib in posterior axillary line, without injuring pleura; suspected pulmonary abscess, but on incising pleura quantity of

thin turbid pus (colon smell) squirted; later some coagula of lymph. Drainage tube.

July 30, 1909. Temperature normal, little discharge.

August 5, 1909. Temperature normal ever since operation.

August 25, 1909. Temperature up for one or two days, two weeks ago and again yesterday and today. Uneventful recovery thereafter.

Case 8.—Empyema, right, discharging through bronchus. Died third day (sepsis). (Pleural vomica.)

William L., fifty-two years.

July 26, 1912. Admitted to the Episcopal Hospital; under Dr. E. J. Morris's care until August 1, 1912, then on Dr. Robertson's service.

Family History. Father, grandmother and brother died of tuberculosis.

Personal History. Pertussis as child. Tobacco and beer to excess.

Present Illness. Began ten days ago as sudden sharp pain in right side, after lying on that side on grass for an evening. Pain gradually subsided after few days. Then got short of breath. Family physician gave medicine without effect. Walked to Dispensary and sent to Ward.

Examination on admission: Large full blooded, dyspneic; constant cough and expectoration. Breath very fetid. Right chest: flat below 4th rib with hyperresonance above. Left apex: impaired resonance. Rales and harsh breathing at right apex and below 4th rib. Absent breath sounds and fremitus. Expectorates 500 c.c. daily of very foul smelling pus. Temperature 99° to 100°.

July 27, 1912. Constant cough. Cannot sleep, cannot speak above a whisper. White blood cells, 16,680. No tubercle bacilli found in sputum in five separate examinations; elastic tissue absent.

August 6, 1912. Seen by Dr. Eves for aphonia: examination negative except for acute laryngitis.

August 18, 1912. Growing weaker. Temperature ranges from 99° to 102° F.

September 3, 1912. Aspiration negative on right, below angle of scapula. (Dr. Robertson.) Still septic.

September 7, 1912. Tapped by Dr. Robertson (negative) below angle of right scapula. Oxygen introduced into pleura until dyspnea was produced and entire area of dulness became

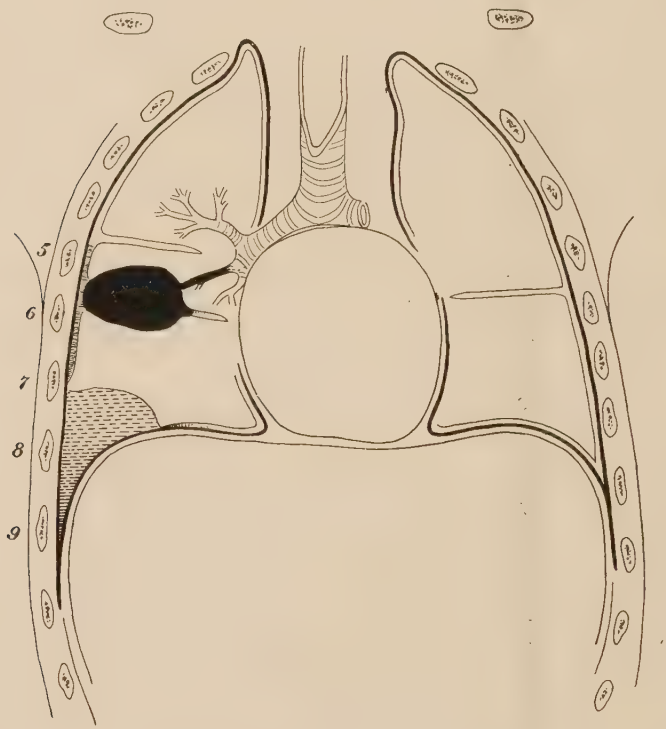

FIG. 10.—Case VIII. Interlobar empyema ruptured into a bronchus (pleural vomica). Note pleural effusion in costophrenic sinus.

tympanitic. Dyspnea soon disappeared and patient became comfortable.

September 9, 1912. Dulness as before over right chest.

September 10, 1912. Oxygen again introduced by Dr. Robertson. Patient nearly died; was unconscious for fifteen minutes; pulse 150.

September 11, 1912. Improved, dyspnea disappeared. Temperature 99° to 103° F.

September 13, 1912. Transferred to Dr. Frazier's surgical service. Seen by Dr. Ashhurst, who thought it to be an encapsulated empyema rupturing through bronchus. Patient is very dyspneic and coughs frequently until expectoration of very foul greenish material. Pulse fairly strong (92 to 96). Respiration 28 to 32. Temperature 100° and no pain. Whole right chest is flat from middle of scapula down; breath sounds weak, many crackling rales. Breath sounds amphoric below angle of scapula for distance of two ribs. Repeated punctures have located no pus.

September 14, 1912. Operation by Dr. Ashhurst (eucain 2 per cent. in intercostal nerves of 8th and 9th ribs and by infiltration also). Incision in 8th interspace posterior axillary line, patient lying on face. Excised 5 cm. of 9th rib and 6 cm. of 8th rib. Ligated both intercostals front and back. Patient complained of pain *in abdomen*. This exposed diaphragm. Bloody serum evacuated on opening pleural cavity; lung stripped easily from ribs except beneath scapula (6th to 8th ribs, in front of angles). Here it was densely adherent (culture of serous fluid; staphylococci, diplococci, bacilli). Packed remainder of pleural space. Lung densely adherent to dome of diaphragm and to posterior parietal pleura beneath scapula (Fig. 10). Burrowed with finger among these adhesions beneath scapula, and ruptured into abscess, which discharged with a gush 30 c.c. or more of same pus as is expectorated. (Aromatic ammonia to stifle fetid stench.) This cavity was beneath 6th and 7th ribs in posterior axillary line, about 7 by 5 cm., though finger could not reach upper limits. Inserted rubber tube (1.25 cm. in diameter) and iodoform gauze around tube. Time, one-half hour. Patient asked for his supper as soon as he was turned over on his back, and was given it on return to ward.

September 15, 1912. Very dyspneic, pulse very rapid and weak. Tube to lung drains large amount of greenish pus. Dressed wound.

September 16, 1912. Died 4.30 P.M.

CASE 9.—Empyema (encysted) left. Died six days (sepsis).

Minnie Y., fifty-nine years.

December 10, 1912. Admitted to Episcopal Hospital, Dr. Piersol's service. Ill for four days, with pain in left chest. Examination showed pneumonia of left lower lobe.

December 15, 1912. Temperature fell by crisis (ninth day).

December 20, 1912. Empyema suspected; dulness persists; impaired fremitus. Very ill.

December 24, 1912. Temperature suddenly rose to 104.3°. More toxic. Tapped, thick greenish pus from left pleura, base of lung. (Culture: pneumococcus.)

December 25, 1912. Transferred to Dr. Frazier's surgical service. Patient appears to be insane. Very emaciated and weak; bed-sore, etc.

Operation (Dr. Ashhurst). Cocain 2 per cent. Patient prone. Injected intercostal nerves at and below 11th rib at angle. Then waited five minutes. Skin not anesthetized yet, so infiltrated it (15 minims of 2 per cent. cocain. Same amount had been used for each of two nerves). Then entire operation (resection of 4 cm. of 11th rib) was done absolutely painlessly. After removing rib, found pleura unruptured. Opened this (as peritoneum) with scalpel and found lung lightly adherent, and showing no tendency to collapse. Packed pleural cavity off above with one strip of gauze, then burrowed in region of densest adhesions (just anterior to opening) and thick (semi-solid) pus welled up with each respiration. Inserted 1.25 cm. rubber tube (about 6 cm. inside thorax), packed it around with iodoform gauze; withdrew isolating gauze; dressed wound, and turned her on her back.

December 27, 1912. Doing well. Temperature fell to normal after operation and remained there.

December 29, 1912. Temperature, 96°.

December 30, 1912. Temperature, 103°. Lungs negative. Drains well. Bed-sore slough removed.

December 31. Died from exhaustion and sepsis from bed-sore.

CASE 10.—Empyema, left. Recovery.

Mary O'B., five years.

January 10, 1913. Admitted to the Episcopal Hospital, Dr. Piersol's service. Ill three days with pneumonia of left lower lobe. Temperature reached normal by lysis on January 17, 1913.

January 20, 1913. Temperature 101° to 104°. Aspiration in 9th left interspace gave a large amount of pus (Diplococcus, pneumococcus).

January 22, 1913. Transferred to Surgical Service. Temperature still high.

Operation (Dr. Ashhurst), ether. Patient prone. Resected 3 cm. of 9th rib, in front of its angle; gush of yellow curdy pus (about 250 c.c.). Drain:. Rubber tube.

February 18, 1913. Tube discontinued.

March 10, 1913. Out of bed.

March 21, 1913. Discharged. Wound healed.

September 28, 1916. Social Service Department reports, has moved and cannot be found.

Case 11.—Empyema, left. Recovered.

James. F., seven years.

February 10, 1913. Admitted to Episcopal Hospital, Dr. Piersol's service. Ill three weeks at home, feverish and coughing. Effusion in left lower chest. Needle gave thick, greenish pus. Culture: pure pneumococci. Temperature, 102°. Delirious.

February 12. Temperature normal. Flat all over left chest, posteriorly.

February 14. Operation by Dr. Ashhurst (ether). Patient prone. Excised 3 cm. of 11th rib at angle. Gush of pus when periosteum was torn through before fragment of rib was excised. No hemostats required. About 500 c.c. of yellow, inodorous, creamy pus, with large amounts of lymph. Lung not much bound down by adhesions and expanded well after removal of pus. Drain tube, 1 cm. lumen, inserted about 5 cm., so as to be above level of diaphragm when this rose.

February 17. Pneumonia at right apex. Delirious, very weak. Temperature since operation 99° to 102° F.

February 21. Temperature normal.

February 27. Bed-sore over sacrum.

March 11. Slowly improving.

March 21. Tube replaced.

April 3. Bed-sore healed.

April 11. Tube removed.

April 20. Tube replaced.

April 28. Tube removed. Out of bed.

May 10. Discharged. Sinus gives slight discharge.

September 13, 1916. Healed three or four weeks after leaving hospital. No deformity; rib has reformed. Impaired resonance and a little distant breath sounds. Well and hearty.

April 28, 1920. Mother reports he is in good health.

CASE 12.—Empyema, left. Recovered.

Walter H., fifteen years.

August 21, 1913. Admitted to Episcopal Hospital (Dr. Frazier's service).

Family History. No tuberculosis.

Personal History. Pneumonia at five years; well since. School-boy.

Present Illness. In October, 1912, noticed some swelling on left side, dull pain. Broke open in one month and discharged a little pus. Dressed twice daily since. Slight cough, frequent night-sweats. Very little expectoration.

Examination: Right apex, impaired resonance. Left is fair. Right apex bronchial breathing and pectoriloquy. After each five or six beats of heart a very loud friction rub is heard, evidently pericardial, and systolic in time. From 6th rib to base on left is dull front and back. Scars of two healed sinuses, anteriorly in 7th interspace. Sinus below angle of scapula discharges whitish, inodorous pus. Probe enters four inches and detects bare carious rib.

August 23. White blood cells, 18,320.

August 26. Operation (Dr. Ashhurst), eucain, 2 per cent.; 4 cm. of 10th left rib removed; great amount of greenish pus exuded (smear: few micrococci; culture: negative). Tube.

August 28. Not much pus.

September 6. Discharge less, irrigated daily.

September 8. Blows Wolfe bottles.

September 12. Better expansion on left.

September 20. No discharge. Sent home. Temperature never above 99° after operation

September 28, 1916. Three years after operation reported to have left the city.

CASE 13.—Empyema, left. Recovered.

Edna P., seven years.

June 25, 1913. Admitted to Episcopal Hospital, Dr. Mutschler's service. Had been ill for six weeks. Acute onset with meningeal symptoms. In bed since with pain in left side. Weakness and cough and yellowish expectoration. Whole left chest full of fluid.

June 27. Operation by Dr. Mutschler. Intercostal incision 6th to 7th ribs, left; large amount pus evacuated.

July 1. Improved. Temperature irregular but not high.

July 20. Only small sinus remains.

July 29. Temperature rising.

August 1. (Service transferred to Dr. Ashhurst.) Temperature 103°. Signs of fluid; two taps negative. Old sinus entirely healed.

August 2. White blood cells, 26,000.

August 5. Temperature 100° to 102°. Roentgen ray.

August 10. Coughed up some pus; sent to laboratory. Negative for tubercle bacilli; diplococcus predominated.

August 13. Sinus ruptured during night. Temperature lower.

August 19 to August 24. No improvement. Patient feels ill. Temperature up.

August 25. Better; thick yellowish expectoration. Roentgen ray after bismuth injection shows cavity extending from 4th to 11th ribs.

August 26. Temperature normal.

August 27. Operation, ether (Dr. Ashhurst). Patient prone. Excised 3 cm. of 9th and 8th ribs, near angle, opening cavity in pleura (no communication with bronchi apparent); removed bismuth; broke up some adhesions. Drain tube and iodoform gauze. Large amount of bloody pus removed.

September 18. Tube removed.

October 22. Entirely healed; out of bed.

October 27. Discharged.

September 6, 1916. Very slight scoliosis convex to left. (Left ribs were resected.) Ribs reformed. No disability. Attends State Dispensary for Tuberculosis.

February 21, 1920. Nearly seven years since operation, patient now fourteen years of age. Grandfather, living in same house, died of phthisis soon after her return home from hospital. Examination shows expansion of chest limited at both apices, but the lungs are normal. There is no increase in the slight left convex scoliosis noted three and a half years ago, and no disability.

Case 14.—Empyema, left (pleuroperitonitis). Recovered.

Margaret P., twelve years.

October 27, 1914. Admitted to the Episcopal Hospital on Dr. Fussell's service. Ambulance doctor (R. J. Sprowl) found temperature 105°, pulse 140 to 150; his diagnosis was typhoid fever. Had been ailing off and on for three weeks before onset of acute illness, but attended school daily. One week before admission had sudden violent pain in lower left abdomen. Began vomiting and has been vomiting ever since. Castor oil not effectual. Bowels not open for one week. No cough. Pains her to be moved and to take deep breath. Pains to urinate or make any motion with abdominal muscles. Examination on admission by Dr. J. W. Moore, receiving ward physician: Temperature 103°, pulse 136 to 120. Well-developed and well-nourished, but anemic. Lips red, face pale. Breathing rapid, but rather full respiration. No edema or cyanosis. Not apathetic. Teeth good. Tonsils very large and red and pharynx red. White blood cells, 30,000. Polynuclears, 75 per cent. Hemoglobin, 75 per cent. Red blood cells, 4,220,000.

Chest: Expansion good and equal on both sides. No thrills or frictions. Tactile fremitus normal everywhere. Whole lung resonant to percussion except an area the size of a quarter dollar under angle right scapula, which is dull, and an area in

right midclavicular line 4th rib (anteriorly), which seems hyperresonant, almost tympanitic. Breath sounds vesicular *all over*, including dull area, but here is heard an occasional crackling rale. No bronchophony or whispered pectoriloquy.

Heart: Negative.

Abdomen: Very rigid and tender all over, especially in epigastrium, right and left iliac fossæ. Not scaphoid nor markedly distended. Spleen and liver not palpable because of rigidity, but spleen not enlarged to percussion and liver dulness present. Abdomen resonant throughout; no dulness in flanks. Active peristalsis all over abdomen.

Rectum: No masses or areas of exquisite tenderness.

October 28. Examination by Dr. Fussell:

Patient looks ill. Complains of pain in abdomen when moved. There is a red flush on right forehead. Constantly makes outcries because she states she had pain in her stomach. Slight crusted scar on lower right lip, may or may not be herpes. Slight glandular enlargement in both axillæ and both groins. Breathing rapid and rather quick. No dulness on left side in front or laterally. Dulness on right beginning at 5th rib in mid-axilla and merging into liver dulness. No dulness on right side behind. No blowing breathing posteriorly on either side. During examination dulness in right axilla disappears. Liver dulness begins at 4th rib, parasternal line, and extends almost to edge of the ribs. Splenic dulness is apparently increased. In respiration the abdominal wall is absolutely fixed. On palpation there is no mass nor any particularly tender point. There is a great deal of abdominal tenderness in addition to the rigidity. Halfway between xiphoid and umbilicus the respiratory murmurs are curiously well heard. There is no sign of peristalsis. (Treatment just after admission is not recorded.) Rectum is ballooned out, but there is no mass.

Transferred to Dr. Frazier's service (day after admission). Temperature, 103°. Pulse, 120 to 130. Respiration, 38 to 40. White blood cells, 31,000. Eyes bright, cheeks red, rapid costal breathing. Abdomen very rigid all over, a little distended below

umbilicus. Three doctors had examined her by rectum and felt no mass. Dr. Ashhurst did not examine chest or rectum; he thought it a surgical case (peritonitis), but that child was too sick for operation. Transferred to surgical ward and enteroclysis given; *nothing* by mouth (still vomiting frequently and has been having water in medical ward, but no enteroclysis) and continued head-high posture. Also camphor and digitalis hypodermically (not given on medical ward).

October 29. Got out of bed last night and managed to get a little water (delirious). White blood cells, 23,840. Polynuclears, 92 per cent. (Nothing by mouth, continued enteroclysis. Fowler position.) Abdomen distended, tympanitic to percussion everywhere, save in right iliac fossa, where a dull area can be made out. Right side more rigid than left. Has vomited only twice. Nose bleed at 3.30 A.M.

October 30. Much weaker and more restless. Abdomen not so distended but board-like rigidity over entire abdomen. Does not vomit, has not passed any flatus; peristalsis can be heard in upper abdomen; complains of great thirst. Still nothing by mouth and enteroclysis. Temperature, 101° to 103°. Pulse, 120. Respiration, 26 to 30. Given digitalis and strychnin. No sign of localization of peritonitis.

October 31. (Saturday.) Decidedly better. Upper abdomen just a little softer. Suspicious boggy feel by rectum (first examination by Dr. Ashhurst.) Respiration still very rápid. Temperature, 99°. Pulse, 110 to 115. By noon, hot water given by mouth. By afternoon (third visit by Dr. Ashhurst this day) feels almost convalescent she says. Complained of pain "around heart" and left lower chest at A.M. visit. P.M. Temperature, 101°.

November 1. (Sunday.) Temperature, 101° (steady). Pulse, 108 to 120. Respiration, 32 to 40. Respirations still very rapid. Left cheek flushed. Alæ nasi play violently. Abdomen rather rigid, no dulness; rectal examination, negative. Chest negative anteriorly. Dr. Ashhurst determined on thorough chest examination (his first) because of failure of abdominal

abscess to appear. No evidence of subphrenic abscess (Hoover's sign). Right lung negative. Left dull from angle of scapula down, posteriorly and in axillary line, not anteriorly. Tender on pressure in intercostal spaces here. *Perhaps* slight bulging of these spaces. Breath sounds distant. *Needle* inserted in 7th interspace below angle of scapula drew pus (diplococci in chains). Dr. Fussell came in consultation; said subphrenic abscess, *no* evidence of empyema. Dr. Ashhurst maintained it was *empyema thoracis.*

Operation by Dr. Ashhurst (gas) 2.30 P.M. Resected 8th rib in anterior axillary line. 150 c.c. (streptococci) pus from pleura. Tube. Liquids by mouth. At 10 P.M. abdomen less tender, lungs edematous. Heart holding out well. ℞.—morphin and atropin. Temperature, 104°. Pulse, 120 to 140. Respiration, 40 to 48.

November 2. Profuse discharge of pus from pleura; heart displaced to right. Abdomen softer, normal bowel movement (first since enema October 29). White blood cells, 47,760. Polynuclears, 89 per cent.

November 3. Temperature falling. Continue morphin, atropin and stimulation. Three normal bowel movements (no purge).

November 4. Better, abdomen softer, no bowel movement.

November 5. Temperature gradually falling. Pulse 120 to 130. Respiration 30 to 38. Bowels open daily from now on. Examination by Dr. Fussell: Labored breathing. Heart: Right border one and a half inches to right of sternum, sounds are very rapid and feeble. Right chest anteriorly and posteriorly many rales. Left chest: pneumothorax. Abdomen is tender, especially over McBurney's point.

November 6. Examination by Dr. Ashhurst. No rigidity of abdomen, no tenderness to a reasonable degree of pressure over appendix or any other part of abdomen. To all intents and purposes the abdomen is normal. Respirations are thoracic. Fair expansion on both sides of upper chest; below nipples expansion better on right than left. No breath sounds heard anteriorly

on left; normal on right. Right chest posteriorly is normal; on left posteriorly, pneumothorax.

November 7. Herpes on lip and tongue.

November 8. Improved.

November 10. Profuse discharge from chest still.

November 14. Fluid suspected at right base, no puncture.

November 16. Tube shortened.

November 22. Tube removed. Heart in normal position. Left thumb opened for infection (pure staphylococcus).

December 5. Out of bed. Thumb badly infected. Furunculosis of back.

December 11. Convalescent for two weeks and in chair now and chest normal. Excessive thinness.

December 14. Chest healed.

December 17. Gained three pounds in last three days.

December 23. Severe cough. Examination by Dr. Piersol: Compensatory emphysema of upper and middle right lobes; slight fluid or thickened pleura at right base from 7th dorsal spine down. Consolidation or compression of upper left lobe; below effusion and air.

December 24. Feels fine. Examination by Dr. Ashhurst; dulness at right base, breath sounds distant, consolidation at left base; sounds diminished, pneumothorax. Abdomen negative.

December 25. This afternoon had attack of acute pain in abdomen; vomited once. Temperature, 100°. Abdomen tender throughout and some rigidity.

December 26. Temperature, 99° to 101°. Right lower quadrant rigid. Liquid diet.

December 30. Sequestrum removed from thumb.

December 31. Chest unchanged. Aspiration of right; no fluid.

January 3, 1915. Temperature, 99° to 101°. Pulse, 104 to 120. Respiration, 28. Vomited this A.M.

January 4. No better. Slight pneumothorax anteriorly on left; empyema scar solid.

January 5, 1915. Examination by Dr. Frazier (rectal and abdominal), who found no abscess. Resident physician (Sprowl) could not feel anything by rectum. Dr. Ashhurst examined patient again and found all abdomen below navel was rigid and tender and dull, and in rectum a distinct bulging abscess. White blood cells 26,000 for last week. Polynuclears five days ago 82 per cent., yesterday 72 per cent. *Diagnosis* Pelvic abscess from appendix, relighted by Christmas dinner.

Operation: Gas. 11.30 A.M. Incision right paramedian 5 cm., suprapubic. Transversalis fascia and peritoneum matted together and dense; at once on opening peritoneum, white, creamy pus welled out, about 50 c.c. in all. Finger inserted; felt intestines matted together by adhesions; and burrowed to Douglas's pouch. Drain: rubber tube, and iodoform gauze. No sutures. Time ten minutes. (Culture: Streptococcus.)

January 6. Temperature normal, free discharge of pus; much better.

January 10. Bloody purulent expectoration. Sitting in chair.

January 13. Tube removed from abdomen.

January 15. Weight 54½ pounds.

January 17. Slight discharge. Gaining weight.

January 23. Went home, weight 59 pounds. Sinus closed.

October 4, 1915. Scar two inches. No hernia. No disability. Appendix has never been removed.

April, 1920. Patient cannot be traced. Family report she was in good health a year ago, when she was employed as a professional dancer.

CASE 15.—Empyema right. Recovered.

Hugh McI., forty-three years.

November 7, 1914. Admitted to the Episcopal Hospital to Dr. Frazier's service.

Ailing all summer. Pneumonia four weeks ago, crisis three weeks ago, but did not get well; had fever, cough and marked expectoration. In bed all the time. Bed-sore beginning. Temperature 101° F.; right lung from middle down gives absent breath sounds and fremitus, and is flat. Aspiration gives pus in 7th interspace posteriorly (pneumococcus).

November 8. Operation: Eucain 2 per cent. Patient prone. Resection of 3 cm. of 9th right rib in posterior axillary line. The sinus of empyema runs up posteriorly to the region of the third rib, where the cavity is larger. The lung is bound down tight by adhesions (Fig. 11).

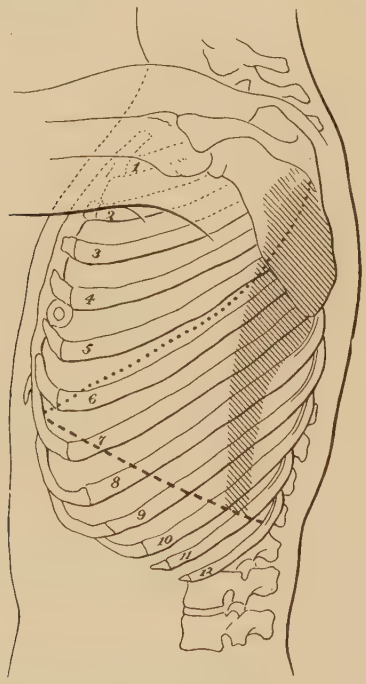

FIG. 11.—Case XV. Large, but distinctly encapsulated empyema.

November 9. Temperature normal.

November 18. Tube out.

November 23. Discharged.

September 28, 1915. Refuses to return for examination. Wife says he is in good health but has a cough.

CASE 16.—Empyema left. Recovered.

Joseph R., nineteen years.

December 3, 1914. Admitted to Dr. Frazier's service, Episcopal Hospital. Pneumonia (left) three weeks ago; crisis two

weeks ago but did not get well. Fever developed with pain in left chest and dyspnea. Cough and expectoration continued. Needle in 7th interspace shows pus. (Family physician.)

Examination on admission: Left base, absent breath sounds and fremitus; and flatness. Hoover's sign positive. White blood cells, 15,840. Temperature, 103° F.

December 4. Operation: Eucain 2 per cent. Excised 2.5 cm. of 8th left rib posteriorly. 500 c.c. of pus (diplococci).

December 8. Tube lost in wound (was sutured to skin by No. 1 chromic gut). Roentgen ray 3376*a* shows it inside chest.

December 11. Efforts yesterday failing to extract tube, Dr. Ashhurst today (gas) resected 2.5 cm. more off same rib at anterior and then at posterior end of former section, and finally found tube in spinal gutter posteriorly. *Large pus pocket* opened and drained. Tube fastened with silkworm gut and safety-pin. Temperature has been normal since operation last week.

December 14. Drainage has about stopped.

December 18. Out of bed.

December 22. Discharged.

September 28, 1916. Has removed to Wilkes-Barre, Pa.

CASE 17.—Pulsating empyema necessitatis left. Recovered.

Gerald L., twenty-eight years.

December 10, 1914. Admitted to Dr. Frazier's service, Episcopal Hospital.

Past History. Is tuberculous; has been ill off and on for seven years. In February, 1911, had left pneumonia, followed by pleural effusion (empyema), tapped, tube inserted (no rib resected). Acute illness lasted six months. Sinus ran nearly one and a half years. Recovered and resumed work about one and a half years ago (laborer).

Present Illness. Ailing for one month, very ill for one week, high fever, bad cough, pain in chest; expectoration offensive and profuse.

Examination: Extremely ill, delirious, cyanosed and dyspneic. Empyema necessitatis over second left rib and in upper axilla. Former pulsates synchronously with heart. Above middle of

scapula there is Skodaic resonance; below this flat, immobile (Hoover's sign very pronounced); breath sounds and fremitus absent. Over apex (L) breath sounds loud and blowing, almost amphoric. Right lung full of crepitant rales. White blood cells, 50,000. Polynuclears 91.3 per cent. Temperature 99°.

FIG. 12.—Case XVII. Pulsating empyema necessitatis (pyopneumothorax.)

Pulse 100 to 128. Diagnosis: Pyopneumothorax. Heart displaced 4 cm. to right of sternum. Thirty-eight ounces (well over one liter) of pus removed by aspiration in left 8th interspace posteriorly. Foul and fecal smelling. (Long pale bacillus with streptococcus predominating.) After aspiration bulging area

disappeared below clavicle, and this area was sucked in with each respiration. Given morphin for cough (Fig. 12.)

December 11. Still in poor condition but much better than on admission.

Operation: Eucain 2 per cent. Excised 3 cm. of 9th rib (L). Patient lying prone. Pleura very thick (5 mm.) and prune-juice looking pus evacuated after breaking up some adhesions. Exceedingly bad stink of hydrogen sulphide gas. Long tube inserted.

December 12. Better; marked discharge. Temperature 102°.

December 14. Temperature again normal.

December 18. Tube removed.

December 29. Went home against advice, but in very good condition; out of bed several days.

September 28, 1916. Has moved to Souderton, Pa.

Case 18.—Empyema right (encysted). Recovered.

Tony V., two years.

November 15, 1915. Admitted to Dr. Frazier's service at the Episcopal Hospital.

Three weeks ago became ill and treated at home for pneumonia; seen today by Dr. R. S. Hooker at home and diagnosed as empyema. On admission temperature 102°. Pulse, 108 to 148. Respiration, 32 to 40. White blood cells, 25,000. Poorly nourished, thin profuse nasal discharge. Pharynx unusually red. Thorax: resonance good, a few rales low in right axilla, and breath sounds are harsh around angle of both scapulæ.

November 11. Aspiration (numerous punctures) of right pleural cavity; no fluid obtained. Temperature down.

November 13. Temperature up.

November 15. Aspirated again in left axilla; no fluid obtained.

November 16. White blood cells, 36,640. Lymphocytes, 40 per cent. Polynuclears, 46 per cent. Hemoglobin, 59 per cent.

November 17. Temperature down.

November 18. Temperature up.

November 19 to 23. Temperature, 100 to 103°; irregular. Seen in consultation by Dr. W. E. Robertson, who diagnosed fluid under the 6th rib right. Roentgen ray confirms this.

November 23. Operation by Dr. Ashhurst (ether). Time ten minutes. Patient prone. Resection of 3 cm. of 7th rib near angle of scapula, pleura thick. Opened this, no pus. Finger introduced found lung lightly adherent to parietal pleura and diaphragm all over. No dense adhesions. No interlobar collection between middle and lower lobes found. Only blood. (Culture: sterile.) Drain: rubber tube (Fig. 13).

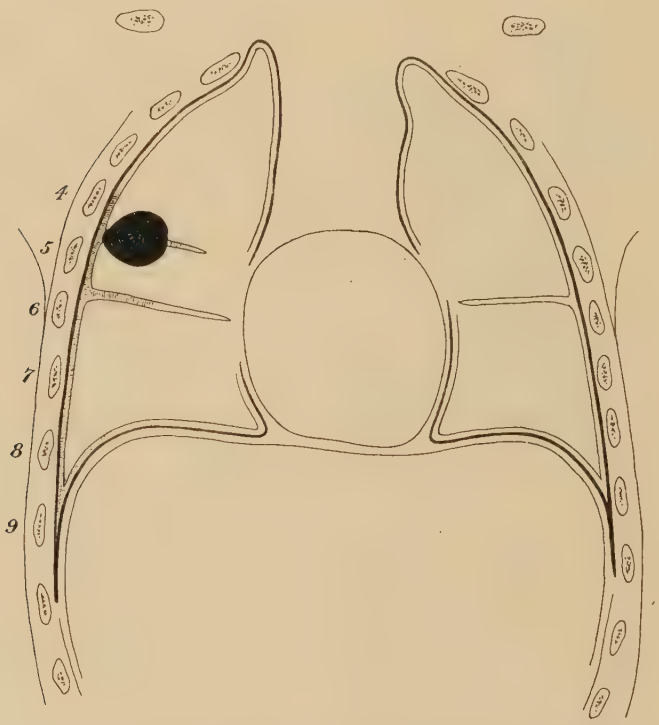

FIG. 13.—Case XVIII. Empyema encysted between upper and middle lobes of right lung; not found at operation. Later ruptured into drainage tract.

November 26. Wound doing well.

November 29. Temperature has fallen gradually to normal.

December 1. Sudden profuse discharge of pus through wound. (Culture: streptococci and staphylococci.) Evidently an encysted empyema had broken into wound. Temperature 101° F.

December 3. Considerable drainage.

December 8. Discharge scanty.

December 12. Chest still draining but scanty.

February 5, 1916. Went home. Sinus healed dry.

September 6, 1916. No deformity, lung normal, rib reformed.

CASE 19.—Empyema right. Recovered.

Joseph F., nine years.

November 17, 1915. Admitted to Dr. Stevens's service (P. E. H.).

About four days ago became sick, attributed to eating some cabbage two days before. Pain in abdomen and then vomited; pain was continuous. This morning pain seemed localized to upper right abdomen and patient then began to show rapid and shallow respirations and to dart his tongue in and out. Has eaten very little since illness began, but has not been constipated.

On admission heart not enlarged; no murmurs. Lungs anteriorly resonant throughout; breath sounds normal posteriorly; dulness and absent breath sounds over right lower lobe up to angle of scapula. Diminished resonance over left lower lobe (Grocco's sign). Few moist rales above area of dulness on right. Liver not enlarged; great tenderness and much rigidity in right upper quadrant; no marked tenderness in right iliac fossa.

November 18. White blood cells 25,200.

November 27. Diagnosis of empyema made and transferred to surgical service. Temperature has been 102° to 103° ever since admission, growing more irregular (99° to 104°) since November 23.

November 28. 500 c.c. of colon smelling pus removed by aspiration. Dyspnea much relieved. Culture of pleural fluid: mixed growth.

November 30. Operation by Dr. Ashhurst (gas). Patient supine, right chest projecting over edge of table. Resected 4 cm. of rib below angle of scapula, evacuating nearly 500 c.c. of colon pus; undoubtedly *not* subphrenic but in pleural cavity. No perforation of diaphragm felt. Drainage tube. Temperature fell at once.

December 3. Draining freely.

December 12. Drainage much less.

December 22. Out of bed, temperature still down.

January 3, 1916. Went home. Small tube still in sinus and some discharge.

August 29, 1916. Examination in dispensary. Very slight scoliosis; sinus healed by February 1, 1916. Lung sounds normal.

CASE 20.—Empyema, recurrent (right). Recovered.

Francis P., eleven years.

October 13, 1915. Admitted to Dr. Deaver's service (P. E. H.).

Two and a half weeks ago developed pneumonia, for past five days excessive cough and profuse expectoration. On admission temperature, 101°. Pulse, 112. Respiration, 36. Respiration shallow. Right chest more prominent and motionless on breathing. Flatness over whole right chest, feeble breath sounds, tubular on deep breathing. Left chest hyperresonant, few rales. Heart displaced to left apex, in 5th interspace, anterior axillary line. By aspiration, 5 c.c. foul greenish pus; staphylococci, diplococci and streptococci.

October 14. Operation (Dr. Deaver). Ether. Resected 2.5 cm. of 7th rib left mid-axillary line. 200 c.c. of pus. Rubber tube.

October 24. Still profuse discharge. Temperature, 99° to 103°.

October 29. White blood cells, 14,640. Lymphocytes, 44 per cent.

November 1. Transferred to Dr. Frazier's service. Dressings still require changing twice daily; tube still in. Temperature, 99° to 101°.

November 8. Dressed once daily.

November 17. Drainage less.

November 26. Temperature up.

November 29. Temperature still up.

December 3. Second operation (Dr. Ashhurst): ether. Old sinus excised by incision in long axis of patient's body. Excised 3 cm. of rib next above and 3 cm. more off anterior end of that

formerly excised (almost closed). Burrowed between adherent lung and thoracic wall posteriorly, gush of fetid thin pus. (Culture: streptococcus.) About 150 c.c. Rubber tube drain.

December 5. Foul discharge (Bacillus pyocyaneus).

December 12. Improved.

December 13. Seen by Dr. Stevens, who diagnosed pus in extreme lower part of right pleural cavity. Circulation not very good.

January 14, 1916. Sinus is being exposed to sun daily.

January 24. Temperature much lower, drainage less.

February 1. Discharge very slight. Breath sounds good.

February 3. Discharged from hospital.

September 13, 1916. Robust and rosy. No deformity. Sinus healed solidly since March. Rib reformed. Thickened pleura, but lung normal. (Impaired resonance and fremitus and distant breath sounds.)

Case 21.—Empyema left. Encapsulated, with separate pleural effusion. Recovered.

Joseph B., thirty-four years.

December 8, 1915. Admitted to Dr. Piersol's service (Episcopal Hospital).

Present Illness. Three weeks ago pain in left chest and cough. On admission temperature 100°. Pulse, 92. Respiration, 20 to 24. White blood cells, 22,000. Polynuclears, 89 per cent. Pain in lower left chest; slight cough. Not toxic. Not dyspneic. Bulging of left anterolateral chest wall; dull red, extremely tender and resistant, from anterior axillary line into axilla. Respiratory excursions limited over left lower thorax; vocal fremitus absent, anteriorly below level of nipple and in left axilla below this level; and posteriorly below angle of scapula. Skodaic resonance over upper left lung. Traube's semilunar space seems obliterated. Flatness over left chest below nipple, also absent vocal resonance, and breath sounds inaudible.

Right lung: rough puerile breathing throughout and dry rales.

Left chest tapped posteriorly, turbid straw-colored fluid, not true pus. (Laboratory report: Gelatinous, 320 cells per c.mm.;

80 per cent. polynuclears; 20 per cent. lymphocytes.) Blood Wassermann negative.

December 9. Seen inconsultation by Dr. Ashhurst. Evidently an extrathoracic abscess over left anterolateral chest and inflammatory exudate in pleura. Transferred to surgical service.

Operation by Dr. Ashhurst (novocain $\frac{1}{4}$ per cent.).

(*a*) Resected two inches of left 11th rib posteriorly; pleura opened; profuse discharge of slightly turbid fluid. No odor. Diaphragm comes up against wound in expiration and fluid only discharges when diaphragm is pushed away. Finger introduced finds no adhesions where diaphragm comes against ribs. Lung not felt. About 300 to 350 c.c. of turbid fluid evacuated and more drains while dressing wound. Tube inserted up four inches and stream of turbid serum escaped through it. Tube sutured to skin and ends of skin wound closed. (Culture of serum: negative.)

(*b*) Patient on back. Novocain. Incision over subcutaneous (left) phlegmon; thick yellow inodorous pus (culture: Staphylococcus). This pus had spread over area 8 cm. in diameter superficial to ribs and discharged between 7th and 8th ribs through orifice admitting little finger, into walled-off cavity about 8 cm. in diameter; encapsulated empyema necessitatis. Iodoform gauze drain. (Query: Is free pleural fluid tuberculous? Presumably it is analogous to that in pleura in subphrenic abscess and to that in knee in osteomyelitis of tibia.)

December 10. Temperature 98° to 103° F.

December 15. Temperature steady 98° to $99\frac{2}{5}$°.

December 25. Tube out from posterior wound.

December 29. Out of bed.

January 7, 1916. No drainage. Went home at own request.

September 20, 1916. Examination: Returned to work two months after leaving hospital. No disability since. Both wounds solidly healed, lung normal on examination.

Case 22.—Empyema, right; necrosis of mandible (from noma). Died two days (noma).

Edward S., seven years.

December 11, 1915. Admitted to Dr. Frazier's service (P. E. H.).

Pneumonia at home for three weeks. December 7th refused to eat because of sore mouth, and for four days before admission was pulling out loose molar teeth with his fingers; had very foul breath. Entire alveolus of lower jaw (right and left), except under the three front teeth, is necrotic, and the noma extends on to cheeks. Right lung: dull except over extreme apex, breathing tubular and fairly loud where dull, and fremitus increased. Left lung: numerous rales and tubular breathing at base.

1 P.M. Red blood cells, 2,800,000. Hemoglobin, 35 per cent. White blood cells, 15,800. Temperature, $101\frac{2}{5}°$. Condition very poor. Aspiration right chest, 10 c.c.; thick yellowish pus.

2 P.M. Child desperately ill from sepsis.

5 P.M. Operation by Dr. Ashhurst (gas). Resection of 3 cm. of 8th right rib in posterior axillary line; patient on back. Pleura not injured. On opening it (rather thick) a squirt of thick creamy yellow pus, no odor. (Culture: mixed growth.) About 300 c.c. evacuated. Cavity extends three ribs lower to costophrenic space and up as far as finger can reach toward apex. Respirations very bad. (Inhalations of ammonia.) Rubber tube drain. Then fuming nitric acid to mouth, and alveolus of mandible excised.

December 13, 1915. Died 1 A.M.

CASE 23.— Empyema left. Recovered.

James C., three years.

January 4, 1916. Admitted to the Episcopal Hospital, Dr. Ashhurst's service. Three weeks ago became ill with cough, high temperature and pain in left side. On admission: Respiration rapid, expansion absent on left. Fremitus is diminished and breath sounds almost absent; entire left chest is dull on percussion. Apex-beat in midline. White blood cells, 16,640. Polynuclears, 71 per cent. 500 c.c. pus drawn by aspirator. No dyspnea before or after. Report from laboratory January 5: Pneumococcus.

January 7, 1916. Operation by Dr. Ashhurst (ether). Patient

prone, resected 10th left rib in posterior axillary line. 250 c.c. of creamy pus evacuated; no masses of lymph. Loosened lung from diaphragm and from spinal gutter, whereupon it expanded 50 per cent.

January 17. Drainage much less.

January 22. Temperature up, slight cough.

January 26. Developed measles and sent to Philadelphia General Hospital.

February 3. Returned from Philadelphia Hospital. Temperature, 100 to 101°.

February 6. Temperature, 104°. Draining freely.

February 15. Temperature falling.

February 26. Tube removed.

March 1. Tube replaced.

March 6. Tube removed. No drainage.

March 10. Discharged. Sinus healed.

September 6, 1916. No scoliosis, ribs reformed, perfect result.

CASE 24.—Empyema, encysted, left. Recovered.

Philip G., fourteen years.

December 27, 1915. Admitted to Dr. Piersol's service at the Episcopal Hospital.

Two weeks ago developed chill, headache, vomited several times, and had generalized slight pain. After few days felt better and went out. Then right ear began to ache; and two days ago developed cough, and became constipated. Has now coryza, cough, slight dyspnea and is constipated. No appetite since illness began.

On admission: fairly well built, slender, not emaciated, no adenopathy. Heart is not enlarged nor displaced, apex-beat in usual location, no murmurs, sounds of fair quality. Lungs are negative, good breath sounds, good resonance throughout. Abdomen negative. White blood cells, 11,040.

December 30. Marked diminution in breath sounds over left base posteriorly, few sonorous rales in lower left axilla. Sputum negative for tubercle bacilli.

January 2, 1916. Widal negative.

January 4. Marked bronchial breathing over right apex posteriorly.

January 6. Blood culture: short chain streptococcus. Malaria negative. White blood cells, 19,960.

January 12. Dulness on percussion and great tenderness at left base posteriorly. Nothing obtained on exploratory puncture.

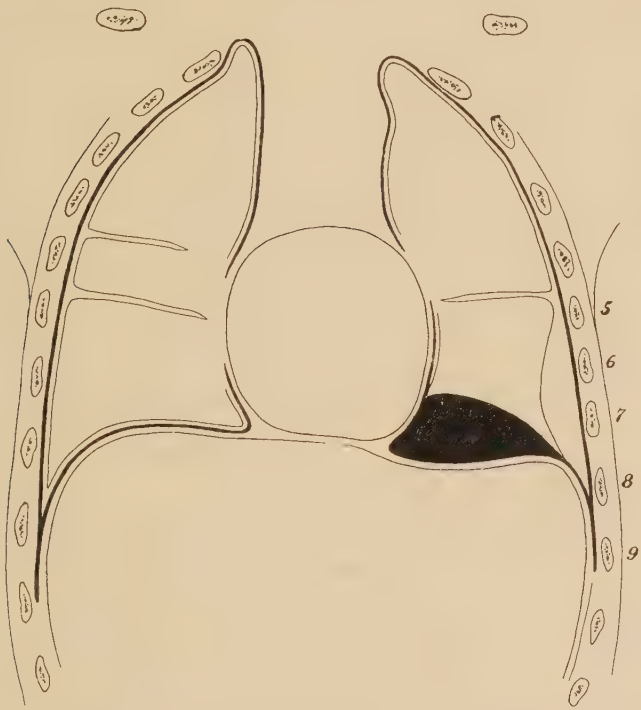

FIG. 14.—Case XXIV. Empyema encysted between left lung and diaphragm. Cases XXVII and XXXVI were quite similar, but on the right side.

January 13. Examined by Dr. Ashhurst in consultation: Has been in medical ward over two weeks with septic temperature (100° to 104°) and chills. Patient is extremely emaciated and anemic. Left lung dull at base, all signs of empyema but needle found no pus. Very tender in left costovertebral angle.

Excursion of costal margin from midline (Hoover's test) not increased, no more tender in left than in right hypochondrium.

Roentgen ray (only properly interpreted after operation) shows dense shadow above left diaphragm, upper level horizontal (not domed) and higher than diaphragm on right. A diagnosis was made of encysted empyema and exploratory operation advised.

January 14. Operation by Dr. Ashhurst. Stovain locally for resection of rib; gas for intrathoracic explorations. Patient prone. Excised 5 cm. of 10th rib near angle. Then incised pleura. Lung did not collapse. Diaphragm exposed, soft; spleen easily palpated through diaphragm, no sign of subphrenic abscess, and on retracting upper ribs (now general anesthetic) lung was seen to be plastered on to diaphragm. Extended incision up parallel to spine, excised 6 cm. more of rib at vertebral end. Dissected carefully with finger, raising lung from diaphragm; a flood of pus (500 c.c.) (culture: streptococci) from between lung and diaphragm. Lung now collapsed. Drain, rubber tube and iodoform gauze between lung and diaphragm. Ends of incision (12.5 cm.) closed with silkworm gut (Fig. 14).

January 15. Given enteroclysis and liquids by mouth. Looks better, quiet, comfortable, but very weak and thin.

January 17. Temperature, 98° to 100° ever since operation. Eating better. Looks better.

January 22. Tube shortened.

January 25. Tube removed. Rapidly improving.

January 31. Up in chair.

February 14. Able to walk.

February 26. Sent home.

August 9, 1916. In dispensary in good general health, sinus in wound just admits probe; has been dressed three times weekly by family physician since leaving hospital; tube was retained until last week, since when gauze has been employed. It was recommended that the packing be discontinued.

February 29, 1920. Sinus closed permanently a week after the gauze packing was discontinued. The only symptom he complains of now is a pricking in the scar at times on exertion.

He works as meat-chopper, lifting heavy portions of the carcasses without disability. There is no scoliosis and no deformity except the very much depressed scar. The lungs are normal, but the ribs below the scar do not move in forced respiration as do those on the other side.

CASE 25.—Empyema, encysted, right. Recovered.

William B., thirty years.

December 22, 1915. Admitted to the Episcopal Hospital, Dr. Piersol's service.

Six weeks ago developed pain in back and slight dyspnea; began to cough, with slight mucopurulent expectoration. Yesterday pain in right side at costal margin, cough, some dyspnea, rapidly becoming worse. On admission: temperature, 103°. Pulse, 104 to 108. Respiration, 32. White blood cells, 10,000. Polynuclears, 91 per cent. Well developed, dyspneic, alæ of nose moving in each respiration. Lungs: Impairment of resonance over right side, most marked in middle and lower lobes; tactile and vocal fremitus decreased and bronchial breathing with moist rales over middle and lower lobes. Few sonorous and crepitant rales over right upper lobe. Left lung negative. Heart normal. Liver enlarged 5 cm. below costal margin.

December 26. Temperature fell by lysis to 100°.

December 30. General condition improved. Temperature, 100 to 103°. Marked bronchial breathing over middle of right lung posteriorly.

January 3 to 14, 1916. Temperature, 99° to 101° to 102°, irregular.

January 13. Seen by Dr. Ashhurst in consultation. In medical ward (Piersol) some weeks with sepsis following pneumonia ("unresolved"). Examination: Right chest dull (flat) from angle of scapula down, fremitus normal, breath sounds distant. A diagnosis of empyema was made from history and condition of "unresolved pneumonia." Medical attendants could not locate pus. Needle in 8th interspace drew only blood.

January 14. Transferred to surgical ward. Dulness over middle and lower lobes right. Right base, however, transmits

vocal fremitus, although voice and breath sounds are diminished. Roentgen ray shows haziness of upper and middle lobes. Operation by Dr. Ashhurst (novocain $\frac{1}{4}$ per cent.). Patient prone. Incision 10 cm. over 9th rib, excised 8 cm. Diaphragm and lightly adherent lung present on opening pleura. Separated

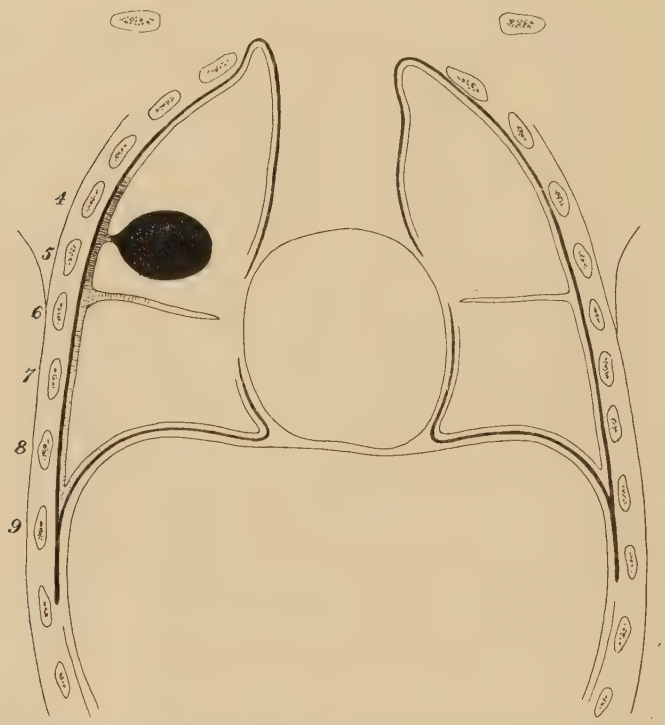

FIG. 15.—Case XXV. Empyema encapsulated between upper and middle lobes of right lung. Evacuated by thoracotomy. Compare Fig. 13 (Case XVIII).

lung from diaphragm by finger as far as could reach; no pus. Surface of diaphragm rather sensitive; lung insensitive. Then burrowed between middle and lower lobes; no pus; entirely insensitive. Then burrowed up along parietal pleura and found very dense adhesions up along 5th to 6th ribs, finally broke

through, when just about to abandon operation and got a flood (perhaps 250 c.c.) of blood-stained pus. (Culture: pneumococcus). Evidently had been interlobar (upper and middle lobes) and had worked out to parietal pleura. Parietal pleura rather sensitive. Slight coughing on evacuation of pus and partial collapse of lung. Drain: rubber tube up along parietal pleura for four inches (Fig. 15).

January 15. Looks convalescent.

January 16. Drains freely.

January 20. Tube removed.

January 23. Temperature normal. Out of bed. Sputum negative for tubercle bacilli.

January 31. Convalescent.

February 3. No discharge. Small granulating wound. Sent home.

August 9, 1916. Cannot be traced.

CASE 26.—Interlobar empyema; left (against pericardium). Died.

Katherine D., thirty-eight years.

August 3, 1916. Admitted to Dr. Ashhurst's service (P. E. II.).

Previous History. Four and a half years ago had attack of pneumonia and pleurisy (left sided) and was in another hospital five months; had septic temperature and chills. Was aspirated but no pus could be obtained.

Present Illness. Has had no trouble since until six weeks ago, when she had pain in left side for two days, severe pain for three-quarters of an hour, followed by chill. July 28 had temperature 103°, pulse 120, and sent for Dr. Shannon. Has had chills. August 1 went to bed complaining of weakness and fever and pain on left side. Last night (August 2 and 3) had pain in right shoulder, relieved by hot-water compresses. Has had slight cough but not much expectoration. Coughed more before taking to her bed.

On admittance: well nourished, no evidence of acute suffering. Breath foul. Temperature 101° to 105°. Pulse 120 to 150. Respiration 32 to 40. White blood cells 21,000. Chest:

Posteriorly inspection and palpation negative except for slight restriction of expansion and decreased fremitus at base of left lung. Percussion note is impaired from 7th interspace in mid-axillary line to vertebral column and extending to base of left lung. Auscultation shows decreased breath sounds over this area. Right lung negative; breath sounds normal. Heart: Rapid; no murmurs; outline normal. Abdomen negative. Puncture in 7th interspace, anterior axillary line (Record syringe) gave no fluid. After admittance had chill.

August 4. Another chill today. Temperature 101° to 104°. Roentgen-ray apparatus out of order and no roentgenological examination could be made.

August 5, 1916. Operation by Dr. Ashhurst (novocain $\frac{1}{4}$ per cent.). Patient prone. Incision 10 cm. over left 8th rib, excised 8 cm. Opened pleura, lung lightly adherent throughout but freely movable. Lung densely adherent at periphery to diaphragm. Packed off above. Dissected lung from diaphragm. No pus. Felt inner border of spleen through diaphragm: no subphrenic abscess. Packed over diaphragm, removed upper packing and separated lung from parietal pleura. Then extended skin incision, excised 3 cm. more of 8th rib and 10 cm. of 7th; dissected with two forceps in interlobar space for 5 or 6 cm. but found only dark blood. (Culture: Sterile.) Iodoform gauze stuffed in this hole and wound closed in layers. (Hoped pus would break into wound as in Case XVIII, Fig. 16.)

August 7. Examination by Dr. Hooker. On left side down to angle of scapula there are normal breath sounds, resonance and fremitus. Unable to examine below on account of dressing. Heart, second aortic accentuated, no murmurs. Blood culture negative. One chill today. Temperature 98.4° to 104°.

August 9. Examination by Dr. Hooker: Heart, second aortic accentuated, roughening at mitral valve, presystolic. Entire right lung shows increased vocal resonance, many crepitant rales, impaired note on percussion, typical pneumonia (hypostatic in origin). Left lung same as last examination. Drainage removed and wound clean.

August 10. Expression is anxious, apathetic, listless, but rather restless. Heart sounds distant. Some evidence of pus on dressings, not present yesterday. Neck held very rigid, moves extremities when attempts are made to flex neck. White blood cells 19,000. Polynuclears 79 per cent. Hemoglobin,

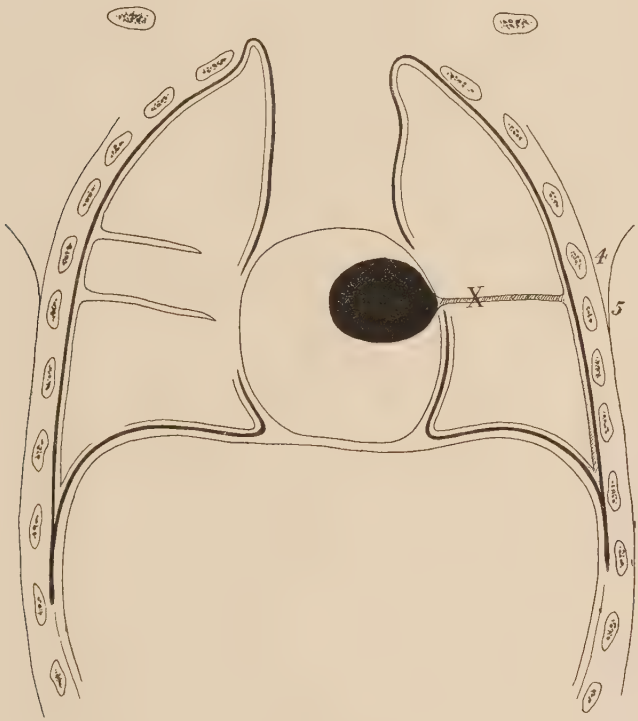

FIG 16.—Case XXVI. Empyema encapsulated between fissure of left lung and pericardium. *X* indicates the point reached at operation.

55 per cent. Temperature does not fall below 101° any more. Roentgen ray shows shadow of abscess to left of midline of thorax, under 6th and 7th ribs (Fig. 18).

August 13. Died of sepsis. Had been moribund for last three days.

Wound explored after death by Dr. H. S. Spruance (ward

surgeon) after removal of two more ribs. He found gauze pack had been correctly placed in interlobar space, and by separating

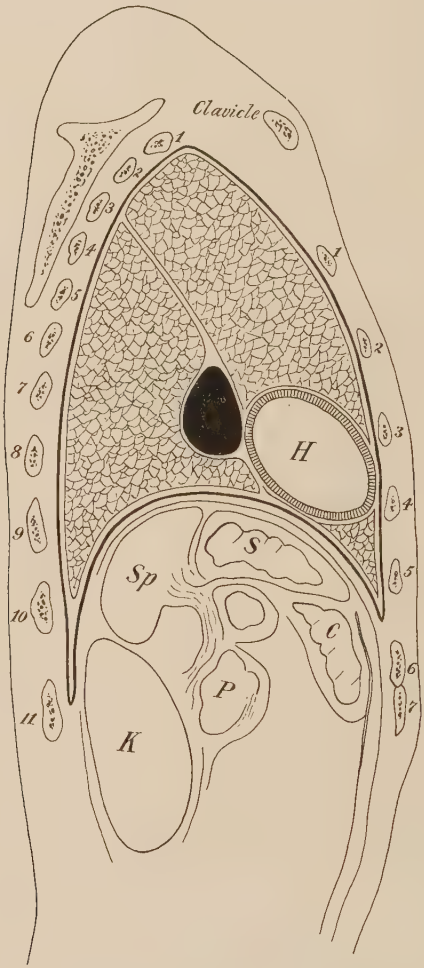

FIG. 17.—Case XXVI. Diagram of sagittal section through middle of left clavicle, indicating site at which pus was found at autopsy.

lobes further (about 2.5 cm.) through dense adhesions he came on abscess (100 c.c.) in interlobar space and against pericardium.

Pericardium when opened was found to contain many recent fibrinous adhesions but no pus (Figs. 16 and 17).

CASE 27.—Empyema left, encysted above diaphragm. Recovered.

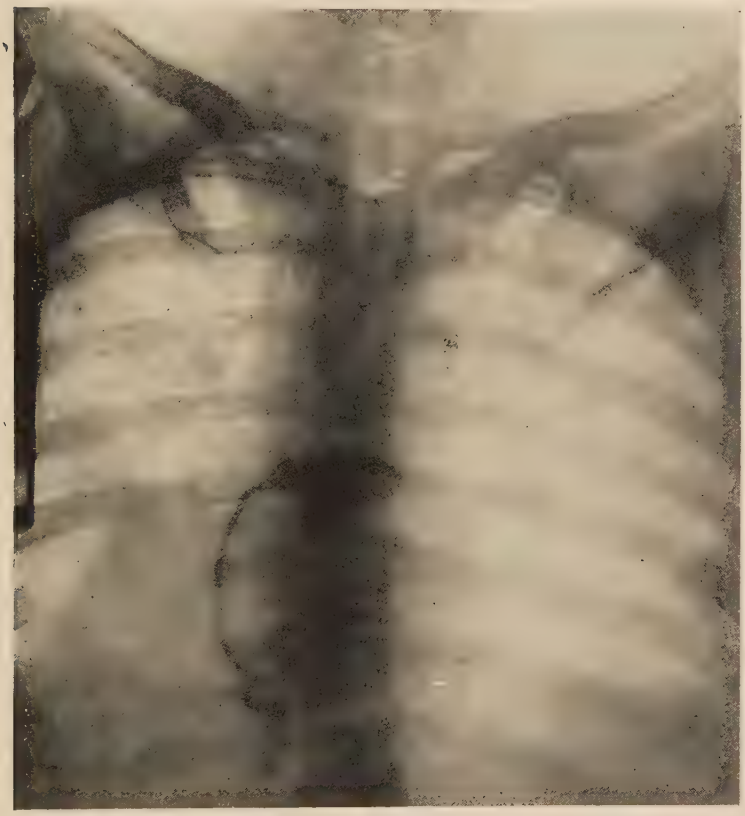

FIG. 18.—Case XXVI. Encysted empyema three days after operation at which no pus was found. Note distinct outlines of abscess cavity overlying shadows of sixth, seventh and eighth thoracic vertebræ, mostly to left of midline. (See Figs. 16 and 17.)

James McG., thirty years.

October 30, 1916. Admitted to the Episcopal Hospital, Dr. Robertson's service.

Present illness began October 19 with coryza. October 28 had chill and began expectorating; continuous pain in left chest. On admittance signs of pneumonia at base of left lung.

November 5. Temperature falling by lysis.

November 11. Temperature has not reached normal. Puncture of chest negative.

November 12. Puncture again negative.

November 16. Third puncture reaches pus in 8th interspace, 40 c.c. of pus withdrawn. Smear and culture of fluid is negative.

November 17. Transferred to surgical ward (Dr. Ashhurst). Temperature 99° to 103° for the last week.

Operation by Dr. Ashhurst (eucain 1 per cent.). Excised 5 cm. of 10th rib; lung does not collapse, lightly adherent to costal pleura and densely to diaphragm. Separated costal adhesions, no pus within reach of opening. Separated lung from diaphragm as far as possible, no pus, but adhesions at limit of fingers were more dense. Excised 5 cm. of 9th rib, and after gauze pack above, dug lung away from diaphragm to dome, when about 60 c.c. of pus discharged. Drain: Rubber tube wrapped in iodoform gauze. (See Fig. 14.)

November 18. Temperature still up.

November 22. Still draining freely. Temperature, 100° to 103°.

December 1. Tube removed. Out of bed.

December 8. For continuing temperature and history of syphilis is given neosalvarsan.

December 12. Temperature normal.

December 18. No drainage; incision closing. Sent home.

January 16, 1917. Seen by Dr. Spruance, ward surgeon. Healed firmly for about one month In perfect health.

February 29, 1920. Examination: Is police officer. In perfect health. Lungs normal. On palpation ribs seem to have reformed.

Case 28.—Empyema left, encysted, upper lobe. Recovered.

William B., twenty years.

October 18, 1916. Admitted to the Episcopal Hospital, Dr. Robertson's service.

Blind since illness with pneumonia at five years of age. Onset of present illness, October 16, with chilliness, during evening; awoke during night with pain in left chest. On admission: pneumonia over upper left lobe.

October 23. Temperature falling by lysis.

November 4. Temperature has not reached normal. Signs of fluid. Puncture below angle of scapula negative.

November 16. Signs of fluid still present, now confined to upper lobe left. Puncture between angle of scapula and spine gives 30 c.c. pus. Sent to laboratory. Previous punctures all over left chest have been negative.

November 17. Seen by Dr. Ashhurst in consultation. Has been in ward over four weeks, with continued temperature following typical pneumonia (left upper lobe), which declined by lysis over three weeks ago. *Repeated* punctures negative until yesterday pus was found (30 c.c. easily drawn) in fourth interspace at spine of scapula. Transferred to Surgical Srevice (Dr. Ashhurst).

Operation by Dr. Ashhurst (eucain, 1 per cent.). (Patient blind since five years and neurotic.) Excised 4 cm. of fourth and fifth left ribs between scapula and spine, flood of curdy pus and great handfuls of coagulated lymph. Cavity extends to 1st rib and down only to 6th or 7th in midaxillary line, evidently encapsulated over interlobar fissure. Drain: large rubber tube and iodoform gauze (Fig. 19).

November 18. Temperature falling, profuse drainage.

December 27. Up and about ward part of day.

December 30. Fifty million autogenous vaccines, given with idea of hastening closure of cavity.

January 8, 1917. One hundred million vaccines given.

January 16. Still in ward, not much discharge. Temperature normal for one week, until today, sudden rise.

January 26. Temperature about normal. Scarcely any discharge. Up all day.

January 27. Sent home. Scarcely any discharge.

February 21, 1920. Three years after leaving hospital, examination shows him fat and healthy. The sinus did not heal entirely for nearly ten weeks after his discharge (over four months after the operation). Examination shows the lungs normal. He has full use of his left shoulder, in spite of section of trapezius

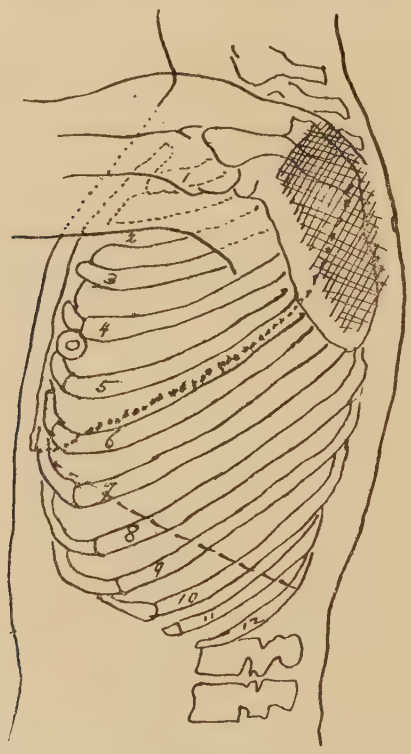

FIG. 19.—Case XXVIII. Empyema encapsulated over posterior end of left interlobar fissure.

and rhomboid muscles at time of operation. As far as can be felt the ribs have reformed. His only complaint is of a pricking feeling in the scar when he puts his hand to small of back (Fig. 20).

CASE 29.—Empyema left (two distinct encysted empyemas). Recovered.

Johan L., twenty-three years (Episcopal Hospital).

December 28, 1916. Admitted to the surgical from medical ward with postpneumonic empyema. Temperature, 102°.

Originally admitted to Dr. Deaver's service October 6, 1916, with diagnosis of syphilis, having contracted mixed chancre about one month previously, followed in two weeks by suppurative left inguinal adenitis, there being unhealed sinuses here on admission.

FIG. 20.—Case XXVIII. Resection of fourth and fifth ribs. Three years and a half after operation.

November 6. Transferred to medical ward (Dr. A. A. Stevens) for constitutional treatment for syphilis, local lesions being under control.

December 4. Developed pneumonia at base of left lung.

December 15. Temperature falling by lysis.

December 18. Temperature has not reached normal. Signs

of fluid. 100 c.c. of cloudy fluid at second puncture, at angle of scapula. (Culture: Pneumococcus.)

December 21. Flatness extends almost to spine of scapula; heart displaced 2.5 cm. toward right.

December 23. On puncture a small amount of pus recovered from depth at left scapular angle. (Culture: Diplococci.)

December 25. No improvement.

December 27. Temperature slightly higher (101° to 103° since December 24).

December 28. Transferred to surgical ward (Dr. Ashhurst) with diagnosis of empyema.

December 29. In medical ward many weeks with pneumonia, after his temperature reached normal, then rose again and for couple of weeks has been high and irregular. Five recent punctures negative where signs indicated fluid. Yesterday puncture in eighth interspace below angle of scapula drew 40 c.c. pus (pneumococcus).

Operation. Eucain, 1 per cent. Patient prone. Resected 5 cm. of eighth or ninth left rib and pus oozed before it was removed; pleura nevertheless thick (2 mm.); pus thick, creamy, many curds. Cavity about 8 to 10 cm. in diameter on diaphragm and against costal pleura. Burrowing in adhesions opened *another pocket of pus* above and against ribs. Cavity extended upward toward interlobar region. Lower lobe densely adherent to diaphragm at one point; loose all around. This piece of lung was dissected loose from diaphragm. Considerable complaint and coughing when costal pleura was rubbed in burrowings, but lung and diaphragm insensitive. Drain: Rubber tube and iodoform gauze. No ligatures. No sutures.

January 15, 1917. Drainage lessening.

February 2, 1917. No discharge. Temperature normal. Wound granulating. Up and about ward.

February 9, 1917. Discharged.

February 1920. The Swedish Consul at Philadelphia reports that this patient was last seen by him about one year ago, apparently in good health.

CASE 30.—Empyema, left. Died after five weeks (sepsis from thoracic wound).

Robert S., seven years.

January 17, 1917. Admitted to the Episcopal Hospital (Dr. Ashhurst's service).

Had had pains in left side and stomach for a week or ten days; January 5, took to his bed; vomited, had cough; chills and high fever. Treated at home for twelve days for bronchopneumonia. Family physician diagnosed empyema following pneumonia.

January 17. On admission: An anemic, poorly nourished boy. Has incomplete cleft of palate; had operation for hare-lip as infant. Expansion of left chest limited. Palpation negative; dulness and distant breath sounds. *Puncture negative.*

January 18. Operation (Ashhurst). Eucain, 1 per cent. Patient prone. Resected 4 cm. left eleventh rib, posteriorly. Opened pleura, flood of reddish-brown pus. (Culture: Diplococci, pneumococci.) Tube passed upward four inches and held in by silkworm-gut suture. Lung could not be felt. Time fifteen minutes.

January 23. Temperature normal until today. Tube removed. Out of bed.

January 25. Draining slightly. Temperature normal to 100° since removal of tube.

January 26. Up in chair all day; no discharge.

January 27. Wound healing well.

January 31. Temperature rose to 104° suddenly. Transferred to Dr. Mutschler's service.

February 2. Vomits, no drainage. Temperature 100° to 103°.

February 3. Wound explored with hemostat and several ounces of pus obtained. Tube replaced. Temperature fell to normal.

February 5. Draining well.

February 7. In good general condition. Temperature normal. Slight drainage of purulent fluid from tube. Cavity irrigated with normal saline. This causes some pain. Fluid comes back clear. Temperature rose to $100\frac{3}{5}°$ (Figs. 21 and 22).

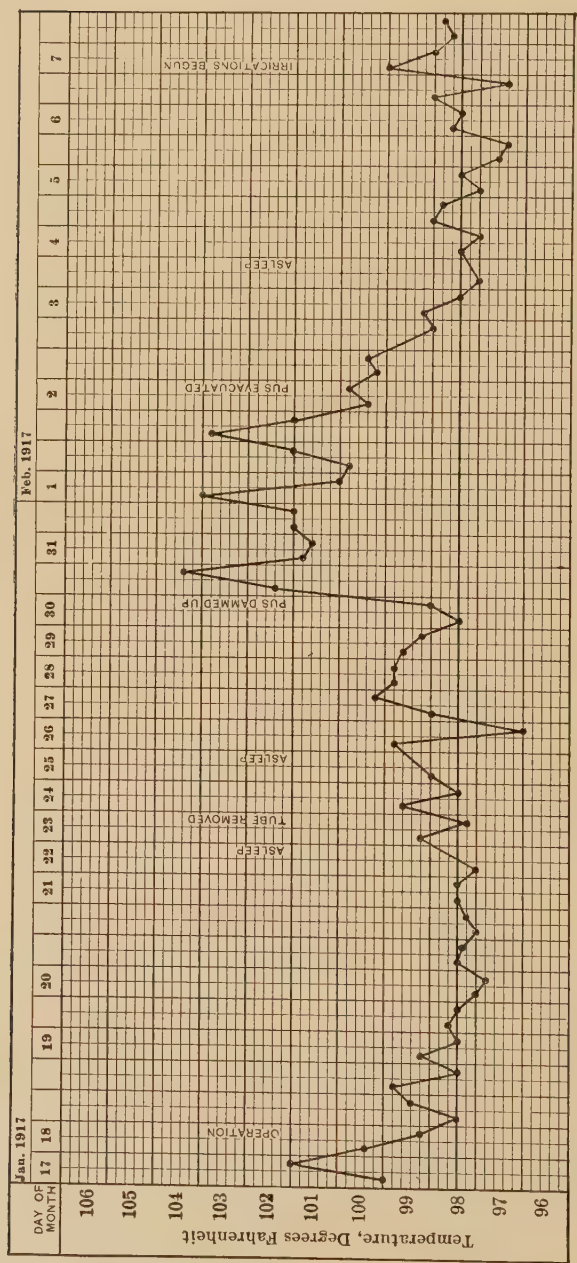

FIG. 21.—Temperature chart of Case XXX, continued as Fig. 22.

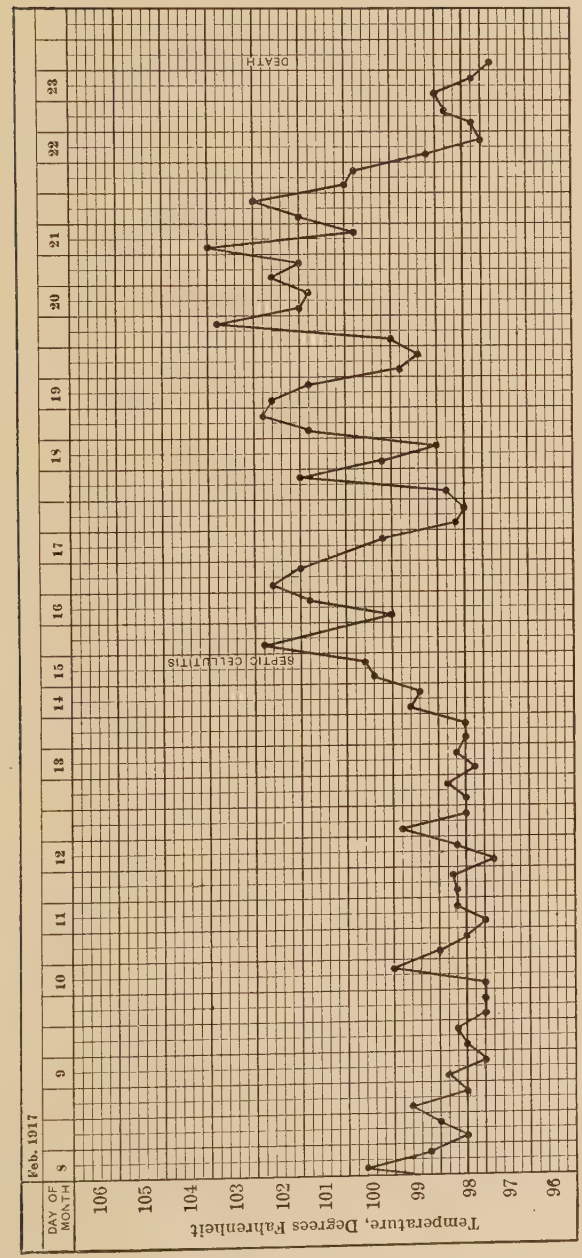

FIG. 22.—Temperature chart of Case XXX. Death from septic cellulitis of thoracic wall. (Continued from Fig. 21.)

February 9. Appetite excellent, only slight discharge but child is fretful and nervous. Daily irrigations.

February 12. Temperature, 98° to 100°.

February 15. Temperature rose suddenly to 103° and continued hectic, 100° to 104°, until death, February 23. Daily irrigations.

February 18. Septic temperature, with sweats. No chills. Vomited. Unproductive cough. Small area of cellulitis around drainage tract, with extreme tenderness. Chest negative but no pus draining. Pulse-rate now 120 to 140, formerly 80. Respiration 28 to 32, formerly 20. Slightly impaired percussion note over left chest posteriorly; two punctures negative. Irrigations continued.

February 20. No drainage. Unable to sit up without support; will not eat. Vomits at intervals. A maculopapular rash like measles over trunk and extremities. Throat, negative. Irrigations continued.

February 21. Sweats, paroxysms of vomiting without other abdominal signs or symptoms, anorexia and increasing weakness continue.

February 22. Irrigated. Tract is open but there is no drainage. Marked abdominal distention but no pain or rigidity. Rash still present. Temperature falling.

February 23. Died with acute dilatation of heart 11.30 A.M. Temperature subnormal. Cause of death: Sepsis from wound of thoracic wall.

CASE 31.—Empyema right. Died (sepsis from thoracic wound).

Stanley K., nine years.

January 15, 1917. Admitted to the Episcopal Hospital, Dr. Ashhurst's service. Present illness began on December 24, 1916, with chill, fever, vomiting and jaundice. Four days later pain in right side, radiating to shoulder, and to left chest, finally localized to right costal margin. Short of breath and breathing pained him. Was treated for lobar pneumonia. Two days before admission mother noticed right chest was swollen; called doctor's attention to it and he found pus on puncture.

On admission, right lower chest had interspaces obliterated, flat, absent breath sounds, apparently massive empyema. Two punctures in axilla negative, but pus found below angle of scapula (Dr. Spruance, ward surgeon); 200 c.c. pus removed by puncture. Smear and culture negative. Polynuclears, 55 per cent. Lymphocytes, 45 per cent. Temperature, $101\frac{3}{5}°$ F. Pulse, 160. Respiration, 48.

January 16. Operation (Ashhurst) (eucain, 1 per cent.). Patient prone. Resected 4 cm. of 11th right rib. Pleura pened just above its reflection on to diaphragm. No pus found here. Inserted finger and in adhesions above 10th rib, close to spine, got a gush of pus. (Culture: Negative.) Pus reddish-brown, no curds. Cavity runs up spinal gutter as far and as wide as finger can reach. Inserted rubber tube upward 10 cm. and more pus then spurted when he coughed (1 liter in all).

January 21. Draining considerably.

January 22. Tube removed.

January 25. Still draining. Out of bed on house diet. Temperature, 99° to 100°.

January 26 to 31. Temperature, 99° to 103°. Pus probably dammed up.

January 31. Transferred to Dr. Mutschler's service.

February 1, 1917. Wound closed. Temperature irregular.

February 1 to 5. Temperature, 98° to 103° F.

February 7. Operation wound granulating, no discharge. On deep inspiration (which brings on coughing) there is limitation of expansion on right side above. Tactile fremitus absent and breath sounds distant in right scapular region. At right base many moist bubbling rales. Percussion note hyperresonant except in scapular region, where it is flat.

February 6 to 8. Temperature, 99° to 102°.

February 8. Finger inserted in old sinus (no anesthetic); base of lung felt to crepitate and expand with inspiration. Adhesions bound an area from 9th rib above, in front by posterior axillary line, below by diaphragm. These adhesions cannot be broken by gentle pressure and more is not attempted because of fear of pleural reflex. Temperature fell from 102° to 99°.

February 10. Dyspnea increasing. Drenching sweats twice daily. Well-defined area of flatness extending from scapular spine to its angle and as far forward as mid-axilla. Puncture in 6th interspace at angle of scapula and creamy purulent fluid is withdrawn about the consistency of molasses in March. A second futile attempt is made to drain this encysted collection of pus through the old incision.

February 9 to 12. Temperature, 99° to 101° F.

February 12. General condition excellent.

February 13. Operation (Mutschler) (ether); 3 cm. of 7th right rib resected in midscapular line and 2 ounces (60 c.c.) of creamy, purulent, viscid fluid evacuated. Pleural cavity is then irrigated with sterile water until latter comes away clear. Rubber tube inserted 6 cm., stitched to skin by silkworm gut. Incision is then closed with interrupted silkworm-gut sutures and dressings applied. On return to ward was able to breathe comfortably in recumbent position.

February 14. Dressings soaked with purulent blood stained discharge. Old tract has definitely closed. Pleural cavity is irrigated with warm normal saline solution, injected through rubber drain tube and again withdrawn.

February 15. Dressings and irrigation repeated. Unable to sit up without excruciating pain in right scapular region. The wound is draining well, but temperature continues elevated (100° to 103°).

February 17. Drainage less. Well-defined area of induration, redness, tenderness, swelling and edema around drainage tube. Irrigation is followed by a fit of coughing and fluid expelled is seen to contain small pieces of coagulated exudate.

February 17 to 20. Temperature, 100° to 104°, and so on until death, February 25.

February 19. Pulse feeble, rapid but regular. Vomited. Takes liquids sparingly, no food. Macular rash, coppery in color, over limbs and trunk. Is evidently exceedingly toxic; wound drains little. Rubber tube removed, irrigation performed. Percussion note is resonant to level of 9th rib; below

this there is flatness, with distant breath sounds. Puncture in 9th interspace causes no pain; clear, colorless fluid, evidently residue of irrigating fluid, is withdrawn; contains small fragments of floating exudate.

February 20. Obviously very ill. No appetite, listless all day long. Area of cellulitis around tube is larger. Movement are painful, as if they involve the muscles in this area. Sutures removed.

February 24. Vomited large quantity of greenish material. Dyspneic, toxic, dull and drowsy. Toward evening cyanotic.

February 25. Died 3.30 A.M. Cause of death: Sepsis from wound in thoracic wall.

Case 32.—Empyema right. Recovered.

Whitman L., forty-six years.

January 3, 1917. Admitted to the Episcopal Hospital (Dr. Stevens's service). Has had a cough for years. Last evening was taken with chills and sweats, vomiting and severe headache. This morning had general pains and pain on inspiration in right chest. Typical pneumonia at right base.

January 12. Signs of fluid at right base. Temperature has never reached normal (99° to 101°).

January 14. Developed bilateral suppurative otitis media Paracentesis of right chest negative.

January 17. Temperature rising (101° to 103°). Still signs of fluid at right base. Is not septic.

January 22. Signs of fluid at right base; puncture gave pus (culture and smear: Diplobacillus).

January 23. Puncture draws 250 c.c. creamy pus.

January 24. Transferred to surgical service (Dr. Ashhurst).

Operation by Dr. Ashhurst (eucain, 1 per cent.). Patient prone. Resected 4 cm. of eleventh rib; found very much thickened pleura, cut through it and exposed fibers of diaphragm. Then cut higher in pleura (costophrenic sinus) and opened pleural cavity, whence over 500 c.c. of pus was discharged; creamy, inodorous. (Culture: Diplococcus and pneumococcus(?)). Diaphragm not sensitive, costal pleura very sensitive. Cavity

extends up and back beyond reach of finger. Drain: Large rubber tube up for 10 to 12 cm.

January 26. Drainage almost stopped. Sat up in chair a while.

January 31. Still draining profusely. Temperature normal ever since operation.

February 10. Less drainage. Learning to walk.

February 12, 1917. Tube removed.

February 17, 1917. Went home.

February 29, 1920. Wound healed firmly four weeks after leaving hospital. No disability. Lungs normal.

CASE 33.—Empyema, right. Recovered.

John B., twenty-six years.

January 10, 1917. Admitted to the Episcopal Hospital, Dr. Stevens's service. Illness began January 4 with chill and sweat, and pain in right side; has had sweat almost every night. On admission: Exceedingly toxic and sick, entire body deeply jaundiced. Cyanosis of finger-tips. Pneumonia at base right lung.

January 12. Has been markedly delirious. Strapped to bed. Temperature low, never up to 101°, evidently poor reaction.

January 16. Rational. Jaundice subsiding.

January 23. Signs of fluid at right base (apical pneumonia). Puncture gives pus. Temperature 101° to 103° since January 21.

January 24. Transferred to surgical ward (Dr. Ashhurst).

Operation by Dr. Ashhurst (eucain, 1 per cent.). Pátient prone. Resected 4 cm. of 11th rib; pleura thickened, pus gushed on opening it. Finger introduced, found opening at lowest limit of cavity, which extended up and back beyond reach of finger, limited in front and above by attachments of diaphragm. About 1 liter of curdy yellow pus evacuated (Culture: Pneumococcus), and continues to drain profusely when tube is inserted, up 10 to 12 cm. along spine.

January 26. Drainage almost stopped. Sat up in chair a while.

January 31. Still draining profusely.

February 6. Sits up each day. Temperature, 98° to 102°.

February 12. Tube removed, temperature having reached normal.

February 18. Discharged. Temperature normal since last note. Wound nearly healed. Patient not traced.

CASE 34.—Empyema, right. Recovered.

William D., sixteen years.

January 9, 1917. Admitted to the Episcopal Hospital, Dr. Stevens's service. Chief complaint: pain in right chest worse on coughing and on deep inspiration. Temperature, 103°. Onset January 5, with chill and sweat; cough; blood-stained sputa; headache and weakness. Excessively ill with typical lobar pneumonia, right middle lobe.

January 11. Type II pneumococcus reported in sputum.

January 12. Pericardial friction sounds. Very toxic. Abdomen markedly distended. Temperature fell by crisis to 99°.

January 16. Temperature has gradually risen again to 103° F. Pneumonia at *left* base.

January 21. Still very ill. Temperature irregular, 100° to 103°. Sweats at night. Signs suggestive of fluid at right base. Consolidation at left base.

January 25. 250 c.c. pus drawn by puncture in ninth interspace, posterior, right side.

January 26. Transferred to surgical service (Dr. Ashhurst). Temperature fell to normal after puncture. Is blue, thin, anemic. Right chest (lower) is flat, distant breath sounds, somewhat diminished fremitus.

Operation by Dr. Ashhurst (eucain, 1 per cent., 10 c.c. only). Patient prone. Resected 4 cm. of eleventh right rib; pus oozed before rib was resected. About 500 c.c. creamy yellow pus evacuated. Culture: Diplococcus (pneumococcus). Finger introduced, felt no lung or adhesions. Opening was at bottom of costophrenic sinus. Large rubber tube passed up 8 to 10 cm. and held to upper skin margin by silkworm gut suture. Time ten minutes.

January 27. Temperature normal.

January 31. Temperature irregular, 98° to 102°.

February 3. Still draining freely.

February 6. Out of bed daily. Temperature still irregular.

February 12. Smaller tube inserted.

February 18. Temperature normal. Free drainage. Learning to walk.

February 19. Tube removed.

February 21. Wound closes between daily dressings, damming up a few drops of pus.

February 22. Small tube reinserted. Went home.

February 21, 1920. Three years after operation. Scar has remained healed since discharge from hospital. Then weight was 87 pounds. In four weeks it reached 114 pounds and is now steady at 120 pounds. Went to State Sanitorium for Tuberculosis on discharge and remained there for nearly a year. Lungs are normal on examination, except slightly distant breath sounds over right chest posteriorly. Chest expands normally. Well-developed chest. No deformity. Rib has reformed. Some evidence of old endocarditis audible and gets out of breath easily, but able to do a man's work.

CASE 35.—Empyema, right (two distinct encysted empyemas). Recovered.

Edward H., thirty-two years.

April 7, 1917. Admitted to the Episcopal Hospital, Dr. Ashhurst's service. Referred by Dr. H. R. M. Landis.

Taken ill ten weeks ago. Diagnosis: Pneumonia, right. Sent to a hospital and after about seven weeks, as he did not get well, they said he was tuberculous (called it "unresolved pneumonia") and sent him to White Haven, Pa. Seen there March 17, 1917 (three weeks ago) by Dr. Landis, who drew off a quantity of *sterile* pus, and referred him to Dr. Ashhurst.

Examination: Emaciated, free expectoration of mucopus (not fetid). Right chest dull over lower lobe and signs of fluid. Needle drew from 8th interspace in posterior axillary line, 350 c.c. of pus (92 per cent. polynuclears. Smear: Negative).

April 8. Operation by Dr. Ashhurst (eucain, 1 per cent.).

Resected 5 cm. of 9th right rib (patient prone). The pleura much thickened (2 to 3 mm.). (Spurting intercostal artery tied by suture, caused much pain, checked by eucain injection.) On opening pleura pus escaped from *thoroughly walled-off abscess between diaphragm and lung.* Diaphragm felt normal, soft, depressible; and smooth liver palpable beneath it. The upper margin of cavity was formed by lung, densely adherent at periphery to costal pleura, just above 9th rib. Diaphragm rose to 10th rib. Supraphrenic abscess extended four inches toward dome of diaphragm. With much difficulty, but *without causing any pain*, adhesions of lung to costal pleura were broken through by the fingers, first far posteriorly, and then the lung was peeled off the costal pleura all the way front (here it was painful, under anterior costal margin, 8th, 7th and 6th ribs).

It was noted that the needle puncture which drew pus in the 8th interspace was above the level where the lung was adherent to the chest wall. *On detaching the lung a perfect flood of pus (over 500 c.c.) came from above, from between lung and ribs;* this cavity extended up as far as finger could reach. (Culture: Diplococcus.) (Fig. 23.)

Drain: Rubber tube between lung and diaphragm and another (2 cm. lumen) between lung and costal pleura, running up toward apex 15 cm. Iodoform gauze stuffed in wound between these two tubes to hold margin of consolidated lung away from wound and convert the two abscess cavities into one. Wound not sutured (12.5 cm. incision). Time, thirty minutes.

May 27. Uneventful convalescence. Wound has been merely moist for last two weeks.

June 3. Went home. Wound now closed for a week with normal temperature, though up to then small tube entered 15 cm. easily. Weight, 150 pounds; gain of 23 pounds in eight weeks since operaton. Breath sounds normal. No symptoms. Right chest moderately contracted in front.

July 6. Reports he will return to work in one week.

November 1917. Sinus discharged but healed in three weeks.

February, 1919. Empyema formed again and another opera-

tion, 5 cm. above former operation, done by Dr. Schell at Northwestern General Hospital. Recovered. Weight, 170 pounds.

September, 1919. Moved to Denver. Since then one reaccumulation was opened; healed in six weeks.

March, 1920. Weight, 170 pounds. Excellent health, no symptoms of tuberculosis; working every day.

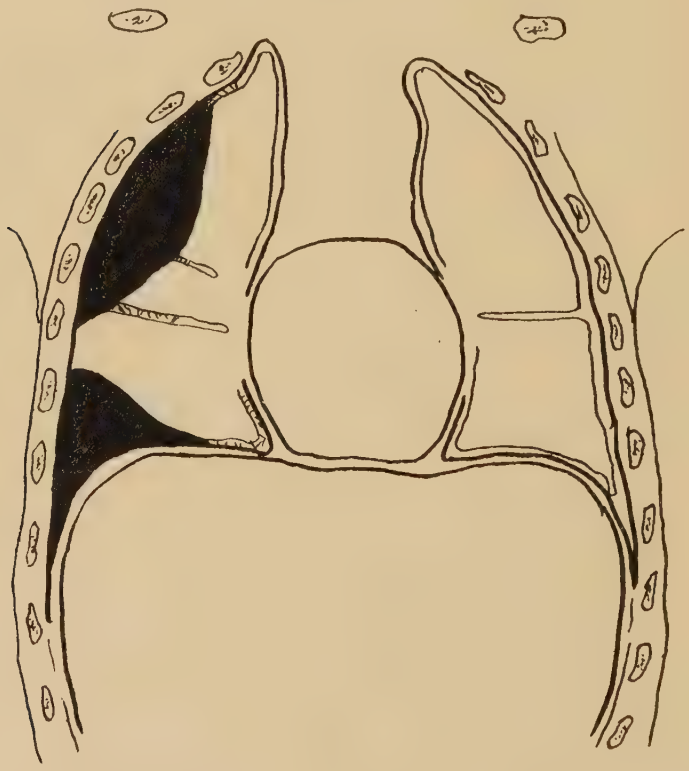

Fig. 23.—Case XXXV. Two distinct encapsulated empyemata.

Case 36.—Empyema, right; encapsulated. Recovered.

Oliver C., twenty-one years.

July 9, 1919. Admitted to the Episcopal Hospital, Dr. Robertson's service. Ill since July 7; typical pneumonia. Chief complaint is pain in right chest and shortness of breath. On

awakening in morning had chill, became feverish and dyspneic and developed pain in right chest on inspiration. On admission: Signs of pleuropneumonia at right base. Temperature, 100° to 102°. Thought to have fluid, but puncture negative.

July 12. Puncture in posterior axillary line is negative.

July 14. Consolidation also of left base.

July 15. Pleuropericardial friction sounds on left.

July 24. Temperature continues 99° to 103°.

July 25. Temperature declined by lysis, yesterday shot up again to 103°. Needle in 9th interspace in scapular line drew 350 c.c. pus. (Culture: Pneumococci.) Transferred to surgical service (Dr. Ashhurst) July 26.

Operation by Dr. Ashhurst (novocain, $\frac{1}{4}$ per cent.). Excision of 5 cm. of 10th rib. Costal pleura normal but adhesions of lung to costal pleura above and in front of opening, and lung adherent to diaphragm. Could not be separated by fingers. Packed. Lung cut loose from diaphragm by scissors. 150 c.c. pus, yellow, creamy. Tube and gauze wick. A few whiffs of ether toward end. Diaphragm felt normal for 5 cm. from ribs, then felt hard; this part was adherent to lung.

August 3. Temperature has reached normal. Little discharge.

August 13. Tube removed. Has been up in chair several days and rapidly getting fat.

August 14. Temperature shot up to 103° Tube replaced.

August 18. Last night and night before had chills. Resident's attempts to get tube in far enough apparently ineffectual. Therefore today, under gas, Dr. Ashhurst put finger into sinus and found lung again adherent to diaphragm, and tore it loose, giving exit to bloody pus; and put tube again deep in wound, almost to dome of diaphragm. (See Fig. 14.)

August 25. Temperature has gradually reached normal. No discharge.

September 5. Tube removed. No discharge.

September 6. Temperature shot up to 103°. Tube replaced.

September 8. Temperature normal.

September 14. Tube removed.

September 15. Temperature shot up to 102°. Tube replaced.

September 17. Temperature normal. No discharge.

September 20 Out of bed.

September 27. Temperature stays normal, but sinus does not heal, though there is practically no discharge. Tube retained.

October 10. Tube shortened.

October 15. Tube removed and gauze wick inserted

October 21. Bismuth paste injected to determine size of empyema cavity. Roentgen ray shows sinus extends up to 5th rib anteriorly. (Roentgen ray 1224 D.)

October 25. No discharge from wound since injection of bismuth.

October 30. Wound is firmly healed. Went home.

November 17 Returns on visit. Still healed. No symptoms.

February 29, 1920. Weight 170 pounds (127 pounds on leaving hospital). Went to work the day after discharge from ward, and has been at work ever since. No disability. Lung normal except distant breath sounds at right base posteriorly. The rib has not yet reformed.

Case 37.—Empyema, right (massive). Recovered.

Isador M., eleven years.

August 4, 1919. Admitted to the Episcopal Hopsital, Dr. Robertson's service.

Onset July 31. On admission very ill, lobar pneumonia at right apex.

August 6. Puncture at angle of scapula gives 12 c.c. turbid fluid.

August 8. Puncture in axilla through 4th interspace and at angle of scapula in 8th interspace; 3 c.c. of slightly turbid pus obtained from each. Patient is better.

August 9. Puncture just lateral to angle of scapula gave 500 c.c. thick green pus. Much better after evacuation.

August 12. Puncture gives 350 c.c. of green pus. Temperature declining by lysis. Smear shows diplococci of pneumococcus type.

August 14. Temperature 98° to 102°.

August 16. Puncture gives 250 c.c. of pus. Very thick and green; 20 c.c. of formalin in glycerin injected. Temperature fell from 103° to 99°.

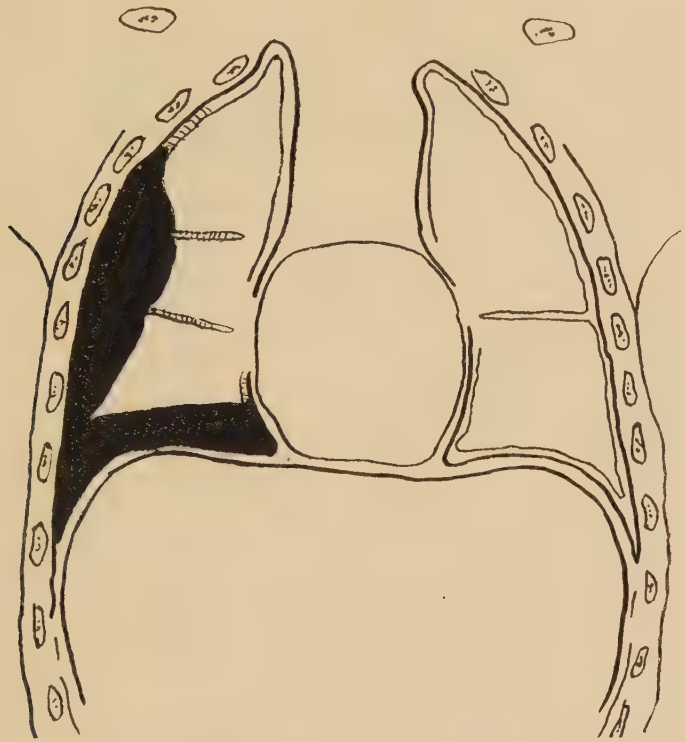

FIG. 24.—Case XXXVII. Massive hour-glass empyema. Case XLIII was quite similar.

August 18. No change. Examination by Dr. Ashhurst. Skodaic resonance over right apex anteriorly; interspaces on right side of chest obliterated. Dull in anxilla and posterior to line of nipple, and posteriorly dull below the 4th interspace except close to vertebral column. Breath sounds distant. Diagnosis: Postpneumonic empyema. Duration ten days. Transferred to surgical service (Dr. Ashhurst).

Operation by Dr. Ashhurst (novocain, ¼ per cent.). Resection of 4 cm. of 10th right rib posteriorly. One liter of pus (Culture: Pneumococci) evacuated on opening pleura. The cavity extended from diaphragm as high as finger could reach and also between diaphragm and lung (Fig. 24). Diaphragm was covered with thick, gray slough, and the lower lobe of the lung stood out surrounded by pus on both phrenic and costal surfaces.

August 22. Free drainage. Doing very well.

September 1. Wound closing. Less discharge.

September 9. Tube removed.

September 13. Incision healed. Sent home.

March 21, 1920. Seven months after operation. Has gained 14 pounds in weight since leaving the hospital—present weight 83 pounds. Lungs are normal. Rib appears to have reformed.

Case 38.—Empyema, right. Recovered.

Evelyn S., nineteen years.

November 16, 1919. Admitted to the Episcopal Hospital, Dr. Ashhurst's service. Sent from Philadelphia Hospital for Contagious Diseases, where she was taken October 31 for suspected diphtheria. October 29. Onset with sore-throat and headache. October 31. Taken to Hospital for Contagious Diseases. November 5. Pain in right side. Dulness. November 13. Evidences of fluid in right chest. Puncture drew 20 c.c. yellowish purulent fluid (sterile). Throat has given nine negative cultures, never a positive culture.

On admission, chief complaint is pain in both arms and back. There is a subpectoral abscess below right clavicle. Patient emaciated and very septic. Temperature, 103° F. (Fig. 25.)

November 17. Seen by Dr. Fussell, who advised aspiration over right base, where signs were suggestive of fluid.

November 18. Dulness and distant breath sounds over lower posterior chest. Puncture draws pus. Diagnosis: Right empyema.

Operation by Dr. Ashhurst (novocain, ¼ per cent.). Resection of 3 cm. of 9th rib, below angle of scapula. Pleura thickened. 250 c.c. of greenish yellow, creamy, malodorous pus evacuated

(same as by aspiration). (Culture: no growth. Smear: organisms like streptococci but smaller.) Cavity extends backward to spine and upward beyond reach of finger. Rubber tube sutured in wound. Right subpectoral abscess to be treated

FIG. 25.—Case XXXVIII. Massive empyema necessitatis, pointing beneath right pectoral muscles. With metastatic abscess between left scapula and chest wall.

later. Diaphragm came just to level of rib resection and felt flat across top to spine; whole cavity appears rigid and may require secondary operation for closure. Still very ill.

November 19. Had a chill.

November 20. Improving, free drainage of pus.

November 22. More drainage than usual from tube. Subpectoral abscess much smaller. Still very annoying cough.

November 25. *Second operation.* Large abscess from beneath left scapula drained under local anesthesia. (Smear: Diplococci and staphylococci.) First sign of this abscess developed seventy-two hours previously. Still very ill.

November 30. The subpectoral abscess has refilled.

Third operation: 100 c.c. of pus from beneath right pectoralis major drained under local anesthesia. (Smear: Diplococcus and bacillus. Culture: no growth.)

December 1. Better. Still coughing. Incision in left back almost healed.

December 20. Out of bed in wheel chair.

January 9, 1920. Tonsils removed under local anesthesia.

January 28. All incisions now firmly healed, the last to close was that of subpectoral abscess. Empyema incision has been healed for two weeks. Went home today.

March 21, 1920. Four months after operation, incision has remained closed. Is round shouldered, with slight scoliosis convex to the left. Gets tired easily.

Case 39.—Empyema, right. Recovered.

Gertrude W., four years.

December 5, 1919. Admitted to the Episcopal Hospital, Dr. Ashhurst's service.

Had whooping-cough and influenza in fall of 1919. Four weeks ago she began vomiting; physician made a diagnosis of congestion of lungs. Later he diagnosed pleurisy.

On admission: Anemic, run-down child, with respiratory embarrassment. Respiratory movements almost absent on right. There is markedly diminished tactile and vocal fremitus of whole chest, anteriorly and posteriorly. Percussion shows flatness over entire right chest. Puncture draws 75 c.c. of thick greenish pus.

December 6. Operation (Dr. Moore, ward surgeon). Novocain, 1 per cent. Resection of 3 cm. of right 9th rib below angle

of scapula. 100 c.c. pus evacuated. (Smear: Diplococci and staphylococci. Culture: Mixed.)

December 24. Rise in temperature. Longer tube inserted.

December 27. Temperature down.

December 29. Tube removed.

January 7, 1920. Rise of temperature for past three days; 30 c.c. pus evacuated by forceps in sinus. Tubereplaced.

January 13. Temperature normal since replacing tube. Tube removed today.

January 22. Out of bed for four days. Sent home with incision healed.

April 11. In good health. Lungs normal. Four weeks after leaving hospital a little pus discharged from sinus on removing scab. Healed in three or four days.

Case 40.—Empyema, left. Recovered.

Thomas W., sixteen months.

December 31, 1919. Admitted to the Episcopal Hospital, Dr. Carson's service.

Eleven days ago child developed fever and cough; physician called who diagnosed pneumonia. After convalescence fever recurred and physician suspected empyema. On admission there is limited expansion of left chest, no fremitus on palpation and dulness over entire chest continuous with heart dulness. Hyperresonance over right lung. Heart displaced 2 cm. to right. Very slight change in breath sounds on left side; on the right side breath sounds are clear and distinct. Has a cough.

Puncture of left pleura gives 100 c.c. turbid straw-colored fluid, no odor (smear and culture show diplococci).

January 2, 1920. Not sleeping well; dyspneic. Pulse not so good. Puncture gives 250 c.c. turbid odorless greenish straw-colored fluid; some relief of dyspnea.

January 4. Slightly better. Fluid collecting again.

January 7. Puncture gives 150 c.c. greenish-yellow turbid fluid, no odor. Gradually improving.

January 8. Restless and dyspneic. Very irritable. Seen by Dr. Ashhurst in consultation and transferred to his surgical service.

January 9. Operation by Dr. Ashhurst (novocain, $\frac{1}{4}$ per cent.). Resection of 2 cm. of 10th left rib, midscapular line. Pleura 2.5 mm. thick. Thin, serous pus evacuated. Cavity extends as far as finger can reach. Tube drainage.

January 12. Temperature normal since yesterday.

January 14. Tube removed. No pus has drained since operation

January 29. Temperature rose to 104° yesterday, after being nearly normal since last note; 10 c.c. of pus evacuated from sinus by inserting forceps. Then temperature fell to normal. Tube replaced.

January 31. Transferred to Dr. Neilson's service.

February 19. Temperature has been normal for four days, after another flare-up, relieved by evacuating a little pus.

February 25 to March 9. Temperature, 100° to 102° F.

March 9. Not doing well. Septic temperature. Nothing definite in chest findings, but roentgen-ray examination indicates presence of pus. Under ether anesthesia Dr. Hawfield (chief resident physician) ran finger into sinus but found no pus. Tube left in sinus.

March 12. Free discharge of pus.

March 20. Temperature normal for past week.

March 26. Sent home, with tube still in sinus.

April 2. Tube out. Tiny sinus.

April 16. Wound healed. In perfect health.

Case 41.—Empyema right. Recovered.

Alice M., twenty-nine years.

February 6, 1920. Admitted to the Episcopal Hospital (service of Dr. J. B. Carson).

Chief complaint: pleurisy pains. Eight days ago was taken suddenly with chill and feverishness. Some cough. Three days ago severe pain in right chest; constant since that time.

On admission: Consolidation, base right lung with Skodaic resonance above.

February 8. Puncture of right chest gives 250 c.c. serous fluid. (Smear shows a streptodiplococcus probably pneumococcus; culture is contaminated.)

February 10. Condition fair. Temperature falling by lysis.

February 18. Temperature since February 12 has been rising gradually and since 14th has been 100° to 103°. Transferred to surgical service of Dr. Mutschler.

February 20. Operation (Dr. Ashhurst). Novocain, $\frac{1}{4}$ per cent. Patient prone. Resection of 4 cm. of 11th right rib. Nearly 500 c.c. of creamy yellow pus evacuated upon opening pleura, which was 2 or 3 mm. thick. (Culture: Pure pneumococci.) Finger introduced palpates no lung as high as it can reach. Opening is at level of diaphragm, which is flat, not domed as normally. Large tube drainage.

March 5. Tube replaced by smaller one. Very little discharge; up and about ward. Temperature has slowly fallen to normal.

March 10. Up and about ward. Very little discharge.

March 30. Tube removed

April 12. Wound healed.

April 15. Went home.

June, 1920. In good health.

CASE 42. Empyema, right. Recovered.

Theresa D., twenty-seven years.

February 7, 1920. Admitted to the Episcopal Hospital, Dr. J. B. Carson's service. Chief complaint: cough, backache and pain in the chest. Husband has pneumonia and three children have influenza. Patient has been sick in bed four days. Has a nursing baby.

Examination: Limitation of expansion and impaired resonance over *left* chest.

February 11. Improved.

February 14. Not so well.

February 15. Consolidation at *right* base.

February 18. Signs of fluid at right base. Two punctures negative; third puncture found sero-pus. (Culture: Pneumococci.) Transferred to surgical service of Dr. Mutschler.

February 20. Examination by Dr. Ashhurst. Entire right

chest posteriorly is flat from spine of scapula down to base, and breath sounds are distant.

Operation by Dr. Ashhurst (novocain, $\frac{1}{4}$ per cent.). Patient prone. Resection of 4 cm. of 10th right rib near its angle. Pleura slightly thickened. Upon opening it, thin turbid pus discharges, with some flakes of lymph, nearly 500 c.c. Finger introduced feels expanding lung, not bound down by adhesions. Large tube drain

March 5. Tube replaced by smaller and shorter. Temperature normal ever since operation.

March 19. Up and about ward. Very little discharge.

April 2. Tube removed.

April 12. Wound healed.

April 15. Went home.

Case 43.—Empyema, left.

James S., thirty-four years.

April 7, 1920. Admitted to the Episcopal Hospital, Dr. Hopkins's service. Onset February 6 with influenza, followed by pneumonia with crisis in eight days. Did not get well. Thought by family physician to have tuberculosis. Two aspirations at home four weeks ago in posterior axillary line left side were negative.

April 8. Aspiration showed thick creamy pus. Aspirated in 7th interspace, posterior axillary line. Transferred to surgical service (Dr. Ashhurst). Emaciated, septic adult, with beginning bed-sore over sacrum. Has constant cough.

April 9. Operation (Dr. Ashhurst). Novocain. Resection of 4 cm. of 10th rib in scapular line. Pleura thickened. Pus spurted 2 meters on opening pleura, creamy, greenish-yellow pus. About 2 liters removed. Exudate surrounding lung on costal and diaphragmatic surfaces (Fig. 24). Tube inserted and anchored with silkworm gut.

April 10. Coughed very little.

April 19. Tube removed and replaced by smaller. Very little discharge at any time since operation. Uninterrupted convalescence.

April 21. Out of bed.
May 12. Tube removed.
May 15. Went home.
June 14. Wound healed.

August, 1920. Four months after operation: In perfect health lung normal. Weight 170 pounds.

OPERATION FOR EMPYEMA IN YOUNG ADULTS

By FRANK E. BUNTS, M.D.
CLEVELAND, OHIO

The great prevalence of pneumonia in many of the United States cantonments and the resulting incidence of empyema, reaching as high as 10 per cent. in the base hospital to which I was assigned, brought to the surgical service about 175 cases for operation. I am not able at present to give the exact data, but certain clinical facts connected with this series of cases seem to be of special interest.

All cases naturally occurred in young adults of army registration age, and while this may have no bearing upon the results, yet it must be granted that they should, by the mere fact of their youth and of their having been admitted to service after elaborate physical examinations, be presumed to be better risks than the average case in civil practice, and, to avoid the possibility of inherent differences in the varied cases found in civil practice, I have designated them in a group as young adults.

1. Classification. In concurrence with the chief of the medical service, patients with fluid in the chest were divided into three classes:

(*a*) Those with clear fluid and no microörganisms present.

(*b*) Those with slightly turbid fluid and various bacteria—staphylococcus, colon bacillus or streptococcus hemolyticus—present.

(*c*) Those with frank yellow pus and with bacteria present.

2. Recognition, Diagnosis. Physical examination often failed to reveal the location of the accumulated fluid, though its

presence was practically certain. The use of the aspirating needle was freely resorted to and a considerable number of punctures were frequently made without successfully locating the fluid. This was due, to a considerable extent, to the fact that many of the accumulations were encapsuled, and particularly to the frequency of interlobar collections of pus.

To obviate the frequent and not always innocuous punctures, early use of the roentgen-ray examination was made in cases able to endure such examination. This greatly simplified and rendered comparatively easy the detection of the location of the empyema, and when stereoscopic plates could be made, immensely facilitated operative procedures.

3. Treatment. Class (*a*). These were aspirated by the physician in charge, or upon request, by one of the surgical staff, but were not transferred to the surgical service.

Class (*b*). These were transferred to the surgical service, aspirated under local or primary ether anesthesia and injected with a small amount of glycerin and formalin (2 per cent. solution). These were watched carefully from day to day and a failure to show improvement or an increase in the severity of their symptoms was followed by immediate operation. In the neighborhood of 16 cases were treated in this manner, of which 6 or 7 recovered without operation. Inasmuch as an occasional case under this classification recovered in which aspiration without the injection of formalin was carried out, it is impossible to say that the latter was a curative agent in the others. All that can be said is that a number got well under its use and that it did not seem to do any harm in any instance.

Class (*c*). These were all operated upon within twelve hours after their detection, except, and this I believe to be of importance, *those cases in which the high fever and physical signs showed the pneumonia to be still active or invading the opposite side.* In these the fluid was aspirated, sometimes repeatedly, until the pneumonic symptoms abated, and then operation was proceeded with. It was a self-evident fact in these cases that the empyema was not the determining factor in the critical condition in which

these patients found themselves, and a radical operation, or indeed any operation other than aspiration, would materially lessen their chance of recovery. This we found to be true from serious clinical experience.

Anesthetic. I have read and heard much discussion regarding the proper anesthetic to be used in these cases, some saying that only local anesthesia should be used, and almost all condemning the use of ether. In a few of the very worst cases when it seemed from the greatly debilitated condition of the patient that no general anesthetic would be tolerated I used local anesthesia alone, but in all the others primary ether anesthesia was used, and I believe without any ill effects whatever, the patient being wide awake at the end of the operation. I have not seen severe coughing or respiratory embarrassment result from the proper administration of ether, and the temporary and transient loss of consciousness, I believe to be an act of mercy to the patient.

Method of Operating. Local anesthesia over the area of the rib to be resected, followed by light primary anesthesia and rapid incision and excision of bone, insertion of a long three-quarter-inch rubber drainage tube which was sutured into the wound, tight suturing of the wound about it and a clamp to the tube to prevent escape of fluid.

Subsequent Treament. The patient was put in a semirecumbent position or the head of the bed elevated by blocks, and the tube end inserted into a drainage bottle attached to the side of the bed, and containing some antiseptic fluid. The clamp on the tube was opened up for a few moments every half-hour, allowing a small amount of fluid to escape until the chest cavity was evacuated and danger of sudden respiratory or circulatory changes eliminated. The clamp was then removed entirely and drainage allowed to continue. At the end of a week or ten days, rarely earlier, the cavity was washed out twice daily with varying solutions, such as iodin, sterile water, normal saline, boracic acid, formalin and glycerin, and at two-hour intervals, when the Carrel-Dakin method was used. The

large number of cases operated upon gave excellent opportunity to try out a series with each method. In from one to two weeks, when the discharge had greatly diminished, the large tube was removed and progressively smaller short tubes inserted.

Blowing into a bottle was insisted upon in every case, but not until the *unaffected side had been carefully strapped with adhesive plaster in a manner similar to that used in fractured ribs*, the object being to prevent emphysema of the well lung, if possible, and to hasten the expansion of the collapsed lung.

As soon as the patient was able to be up, light setting-up drills and breathing exercises were instituted. Beds were moved out of the wards on to the porches, foods were administered as frequently and in as great quantity as the patient could take them. Heroin, and occasionally morphin, were given during the first two or three days for pain or cough, threatened edema of the lungs was combated with digitalis, atropin and oxygen, and in the latter stages, iron, usually in the form of the syrup of the iodide, was given.

4. Results. There was a mortality of approximately 13 per cent. This included every case operated upon, regardless of postmortem findings. No deaths occurred immediately after operation, two days to three weeks being the subsequent range of life, when death followed operation, depending upon complications resulting.

New accumulations of pus, usually interlobar, were sought for and found by the use of the roentgen ray before using the needle in those cases which did not clear up under treatment, and secondary operations were sometimes necessary for their evacuation.

No case required extensive rib resection (Estlander operation), decortication or other procedure for obliterating the chest cavity. Two-thirds of all the recovery cases were either in France with their regiments or temporarily in a convalescent hospital with the wounds healed, and at the time of my detachment from the base hospital there were none who were not in a condition which would not admit of their early discharge

to duty or to a convalescent hospital without further operation upon the chest.

Complications. Infective arthritis occurred in a small number of cases. Pneumonia on the opposite side and occasionally empyema on the opposite side made serious and in one or two instances fatal complications. Endocarditis and myocarditis were rare occurrences.

Autopsies. Until countermanded, autopsies were held on all deaths following empyema. The results of these examinations were most illuminating and valuable. *In not one case could we ascribe the death to empyema.* It was invariably found that the drainage, so far as the part attacked was concerned, was satisfactory, but the cause of the death was a pyemia rather than an empyema; broken-down and suppurating bronchial and mediastinal glands, pus in the pericardium, pultaceous areas in the spleen, abscesses in the liver, multiple abscess in the lungs and free pus in the peritoneal cavity gave evidence of the general rather than the local character of the condition. I was informed by a chief of service in one of the cantonments that these cases were not classified as death from empyema but rather from pyemia. If this be a proper disposition of them then the mortality from simple cases of empyema was practically *nil* in the series of cases to which this paper refers.

Remarks upon Operations and Treatment. The results of autopsy findings must be carefully considered before advocating any special line of treatment or operation. Following the great number of operations throughout the United States for empyema, a great array of opinions and operations was advocated, and many claims for excellency presented which can scarcely be admitted, in view of the fact that except under the most unfavorable circumstances, and in the hands of the most inexperienced operators and of totally inadequate technic, death does not occur by reason of the method of operative procedure but by reason of the inherent character of the pyemia or septicemia present, which precludes the possibility of efficient surgical intervention. This being the case I do not present the method

of operation outlined in this case as being superior to others, but in view of its low mortality, of the comfort of the patient, of its excellent permanent results and of the cleanliness and absence of disagreeable odor in a ward full of these usually offensive smelling cases, I believe it to be worthy of consideration as a good method of operation.

THE ETIOLOGY OF CHRONIC EMPYEMA

By WALTON MARTIN, M.D.
NEW YORK

I HAVE gathered the impression from studying my own cases of chronic empyema and from talking with other surgeons, that chronic empyema is a very uncommon outcome of pyogenic infection of the pleura when the operation for drainage is performed and the after-care supervised by an experienced surgeon. I have talked over this question with men holding most divergent ideas regarding the treatment of acute empyema, and, if they are interested in the subject, they invariably tell me that with their method they never see chronic suppurative pleurisy develop.

This has suggested to me that in a large percentage of these cases the causative factor lies in the treatment of the acute condition. That is, in only a small percentage of cases are there present from the beginning conditions which will invariably lead to chronic empyema. The first thought, on seeing a large, unyielding cavity develop in the pleura following the drainage of an acute empyema, is that since the lung collapsed when the chest was opened it has remained collapsed because an open pneumothorax has been established; positive atmospheric pressure pressed the lung in, therefore, negative pressure must be established and maintained. Every recrudescence of the empyema question is regularly followed by a great many devices for so-called bloodless thoracostomy. Of course, the problem cannot be solved in this way alone. Statistics show, in fact, that more chronic empyemata result from continuous puncture

aspiration drainage than from any other form of treatment except repeated aspiration.[1]

I have thought, therefore, it might be of interest and profit to discuss other etiological factors, drawing my conclusions from a series of twenty-one cases on which I found it necessary either to do an extensive thoracoplasty or decortication.

The very definition of the condition is a debatable point. Is the persistence of pleural suppuration for two months, four months or six months indispensable? Is the ease with which it can be cured or the readiness with which the cavity can be disinfected the essential? One usually means, I think, by chronic empyema a persistent collection of pus in the pleural cavity with little or no tendency to heal; that is, an empyema in which, after the evacuation of the pus, the lung does not expand again and an infected cavity remains. These unfavorable anatomical conditions of the lung, pleura and thoracic wall are reached much faster in some cases than in others, so that a definite time limit cannot be given, nor is there a definite pathological picture. There is obviously a gradual transition, with many intermediate forms, between the acute and chronic condition, but the essential feature is an infected cavity with rigid walls. If a collection of pus is not opened for several months or remains untreated until it bursts through the chest wall or lung the pulmonary and visceral pleura, in response to the repeated bacterial irritation, become thickened and unyielding. The lung, compressed by the new-formed granulation tissue, is firmly held in a more or less collapsed condition. The pleura is converted into a thick layer of organized connective tissue. The deeper layers, those in contact with the lung, after a varying time become so well organized that they will not disappear even after the bacterial irritation ceases by giving free exit to the pus. This pleural response to irritation is probably dependent on the type and virulence of the bacteria and the special individual resistance of the pleura. However, there is a direct time relation between the duration of the infective process and these changes in the pulmonary and parietal

pleura, and, although there is a great variation in this time relation, yet it holds true that the ability of the lungs to expand has a direct relation with the interval between the onset of the empyema and the free evacuation of pus. If the pus be retained, for example, until it bursts through the chest wall a chronic empyema invariably results.

The thickening of the pleura in response to bacterial irritation and the binding down of the compressed lung, so that when the chest is opened the lung no longer expands, is the pathological picture of chronic empyema. The inner surface of the suppurating pleural cavity is irregular and covered with pus and detritus. Its outer surface is made up of fibrillar connective tissue. It is not materially different from the walls of an abscess elsewhere in the body and obeys the same laws, so that the thickness and rigidity of the wall bears not only a definite relation to the duration of the infection but to the amount of pressure or tension of the exudate set up by the bacterial irritation. Every time there is an increase in tissue tension about a nidus of pyogenic infection there is a local response manifested by an increase in the surrounding newformed tissue walling it in. If the infected pleural cavity be opened and free passage be given to the exudate there will be found a direct relation between the adequacy of the drainage and the reaction and consequent thickening of the pleura. If intermittent or inadequate drainage be established the infection will not terminate, the pleura will continue to react to the bacterial irritation and the granulation tissue forming the wall of the pleural cavity will become better and better organized. Now the conditions in the thorax are such that insufficient drainage is very liable to occur. Aside from the position of the original incision, whether a rib be resected or there be an intercostal incision, whether large drainage tubes be introduced or an attempt be made to make an airtight joint about a tube, there is a marked tendency, as soon as wound healing begins, to close the drainage tract. The shifting planes of the thoracic wall and the crowding together of the ribs tend very quickly to break the continuity of the drainage

path. The soft parts heal about the tube, and, although the track may be patent, yet it is often sufficiently compressed to interfere with the absolutely free exit of the pus which is essential to lung expansion.

In Case XIX the patient presents an example of chronic empyema resulting from inadequate drainage. One month after the first aspiration an inch of rib was resected and a drainage tube inserted. At the end of five months he still had a small tube in the chest, the soft parts were contracted closely about the tube, the rib had regenerated, forming a bone ring about the orifice in the soft parts. Every few days he had a rise of temperature; he had lost his appetite; he was anemic; the muscles of his arm and side were atrophic; his chest contracted. In short, he presented the usual picture of chronic suppurative pleurisy. The retention of pus and the imperfect drainage could readily be demonstrated by injections of a weak solution of methylene blue. Notwithstanding coughing and straining, greenish pus was still pouring out of the wound three days later and the urine was stained for several days, showing the absorption even through a thickened pleura. I know of nothing more surprising than to see a patient four or five weeks after an operation for empyema, with a small drainage tube still in the chest, with the soft parts healed firmly about it, with abundant discharge of pus, but with an afternoon temperature, a rapid pulse and no appetite, change after reoperating and resecting a portion of a rib and establishing free drainage. The temperature becomes normal, the appetite returns, the lung often expands in a surprisingly short period. A similar but slower result followed free drainage and sterilization of the cavity in this patient.

There is yet another outcome of a focus of infection, uncommon to be sure, but of great interest. The exudate does not break through the surrounding wall nor is an external passage provided for it. The circumscribing wall becomes very greatly thickened, the virulence of the bacteria becomes more and more attenuated; finally a static condition is reached and the lesion is no longer active. It remains for months and years latent.

A most interesting problem is here presented regarding the life-history and metabolism of non-sporebearing pyogenic bacteria in one of these chronic abscesses. The examples of this condition that we are familiar with are the chronic pyogenic bone abscesses. From trauma or some obscure cause the delicate balance between the living cells of the abscess wall and the microörganisms may be at any time upset and the bacteria again begin to grow; tissue tension is again present, with its local and constitutional signs months and years even after the original infection. There are records of circumscribed collections of pus in the pleural cavity that have apparently been there for years and that were discovered accidentally at autopsy. Brin[2] reported the autopsy of a woman, aged sixty-four years, operated on for stenosis of the common duct. The woman died on the fifth day. In the left pleural cavity there was an abscess filled with thick yellowish pus and broken-down material. It was situated between the diaphragm and the under surface of the lung. The surrounding pleura was $1\frac{1}{2}$ cm. thick and the costal pleura calcareous. There was no communication with a bronchus. There was no record in the history of the patient of an illness other than that of the biliary colic.

A far commoner condition is the latent collection of pus following operation for acute empyema. A patient has an acute empyema; the pleural cavity is opened and drained. After a time the temperature is normal, the discharge diminishes or almost ceases, the drains are removed and the external wound heals. The patient is discharged from a hospital service. He, however, after his return home never feels really well. His appetite is poor; from time to time he feels feverish; he has a slight cough. The physical signs over the affected side do not return to normal; the roentgen ray may be indistinct and may only show great thickening of the pleura. One of my patients (Case XVII) with this condition was sent to Loomis Sanitarium for tuberculosis. He had had pneumonia and an operation for empyema six months previous at his own home. He remained at the Sanitarium for four months, although no tubercle bacilli

were found in the sputum. He then began to run a high temperature. An exploring needle was inserted into his chest near the old empyema scar and pus withdrawn. At operation there was a very large rigid-walled cavity involving the whole right pleura. In another (Case XI), a young Italian girl, there was an operation for empyema in December, 1913. After several months the sinus closed. She returned home, but never regained her health. She was readmitted two years later with a high temperature. An exploring needle inserted near the old scar withdrew pus. At operation there was a large empyema cavity, the lung was compressed against the vertebral column, the parietal and visceral pleura were enormously thickened.

Foreign bodies, usually drainage tubes, have been frequently found in the pleural cavity. It is usually taken for granted that they are responsible for the chronic suppurative pleurisy which always accompanies their presence. I have operated on two patients with this condition (Cases III and IV). In one of them, a man, aged thirty-eight years, two tubes were removed. He had had a persistent sinus and chronic empyema for four years. The patient usually leaves a hospital with a draining sinus and a drainage tube in place. At one of his dressings no tube is found. From the fact that the sinus is narrow and that he has no realization of the cavern within, the doctor dressing the patient when the tube is lost assumes that the tube has fallen out, not in. He usually inserts a new tube. In other words, drainage tubes readily fall into chronic empyema cavities rather than cause them. Their presence there is an added factor, of course, in causing the persistence of the suppuration.

In nearly every series of chronic empyemata reported a certain number are caused by tuberculosis. A distinction should be made between tuberculosis of the pleura, secondary tuberculosis developing in a patient suffering from chronic suppurative pleurisy and suppurative pleurisy occurring in a patient suffering from tuberculosis. In my series there were three cases of tuberculous pleurisy. In Cases XII and XVIII microscopic examination of the excised pleura showed tuberculosis. In all three there was an associated pyogenic infection.

In 12 recurrences following acute empyema at the site of the primary operation, Stevens[3] found the Streptococcus hemolyticus (the organism that caused the original infection) in 11; 1 was sterile. In 9 recurrences distant from the sinus, including undiscovered pus pockets from multilocular empyema, 4 were due to the streptococcus, 3 were sterile and 2 contained staphylococcus. But the effort to base the prognosis and treatment on the type of infection made by Netter[4] has not proved satisfactory. The infection is frequently mixed and there are extraordinary differences in virulence in different epidemics in both the pneumococcus and the streptococcus. The staphylococcus is rarely found unassociated with one of the other pyogenic microörganisms. Its presence in pure culture led Netter on two occasions to predict tuberculosis and in each instance his prediction proved true. The tendency of both the streptococcus and staphylococcus to persist in the tissue and the phenomena of reinfection and secondary infection with these organisms is significant. In making routine bacteriological examinations of granulating wounds one is struck with the ease with which reinfection takes place from some cause often difficult to discover: a piece of necrotic tissue, a minute foreign body or a small pocket with retained exudate. The wound surface which has been almost free from bacteria is suddenly swarming with them again. When the same type of bacteria start to grow luxuriantly we speak of reinfection; when a new organism is added we speak of secondary infection. We are all familiar with the effect of secondary infection in tuberculosis. Kiener[5] reports two interesting observations of secondary infection following empyema: one, a staphylococcus infection, was grafted on a streptococcus; in another a staphylococcus was added to a tuberculous infection. In the subsequent persistent infection the staphylococcus was the prevailing organism.

In Cases II, VIII and XI, I have been able to follow, to a certain extent, the sequence of events in the development of the chronic empyema. In Case II, for example, at operation the lung was found compressed against the vertebral column; the

cavity was very large, involving the whole chest. It was partially filled with foul smelling pus; the pleura was greatly thickened. The patient was eighteen years old. He had been in good health before the onset of the acute empyema, three years before. The diagnosis of pus in the chest had been made early and an operation performed and the drainage tube inserted. After ten days this tube was replaced by another connected to a rubber suction bag and an effort had been made to make an airtight joint between the thoracic wall and the drainage tube by iodoform packing, perforated rubber dam and adhesive plaster. After several weeks the patient was allowed up and permitted to walk. The drainage tube was still in the chest and the suction bag still attached. He was operated on in May. In July he still had a tube in the chest. During this month the tube was removed and the external wound closed. He went home but continued in poor health. He returned to the hospital nine months later for cough and persistent temperature. The chest was opened, a piece of rib was resected and a drainage tube inserted. The pus evacuated was brownish and very foul-smelling. Again the suction bag was applied. There was the same sequence of events; he returned home, the wound again closed but he never regained his health, although he was not actually sick. He had slight fever, persistent cough and shortness of breath. In the patient referred to the exudate at the second operation was foul-smelling. The original pyogenic infection had become secondarily infected by putrefactive organisms.

This question of secondary infection and reinfection and its relation to chronic empyema has been little studied. Of course, it presents unusual difficulties. Secondary surface contamination is almost certainly present in every granulation wound or cavity lined with granulations that communicates with the external air. This by no means necessarily denotes secondary infection. Forty years ago incision and drainage of the chest was unsatisfactory. It was soon generally recognized that the patients were reinfected after the operation. When both the

operation and the after-treatment were carried out under antiseptic precautions there was an astonishing improvement in results. The study of the statistics between 1875 and 1895 is very instructive.[6] I believe these cases I have referred to are examples of chronic empyema resulting from repeated reinfection of the pleura and intermittent drainage. A drainage tube is a foreign body. When a tube is retained in any wound until healing takes place it is soon compressed by contracting healing tissue. The pressure is finally sufficient to interfere with the nutrition of the granulations in contact with the tube; surface necrosis results. A condition of repair and interference with repair is established. The trauma is added to by the movement of the tube in the drainage tract; the greater the activity of the patient the more this displacement of the tube is likely to occur. By these repeated injuries of the granulations the protecting lining wall of round cells is broken again and again. Surface organisms, usually the staphylococcus or streptococcus penetrate the tissue and infection, not contamination, is established. If the tube be long the walls of the drainage tract are made up not only of thoracic wall but the pleura. The exudate, made up of leukocytes and microörganisms, oozes between the tube and the granulating wall embracing the tube. Some of it trickles into the space still present in the pleura, is shut off by the granulations and imprisoned. There is a renewed intrapleural exudate sufficient to hinder expansion of the lung. When the tension of the exudate becomes sufficient it again escapes externally. One of the most admirable principles of the Carrel treatment is the scrupulous avoidance of secondary infection and damage to the granulations, and it seems to me, as soon as the healing wound has contracted so tightly about a drainage tube that it is inserted with difficulty, it is better to remove the tube or reoperate.

The influence of the anatomical arrangements of the adhesions between the pulmonary and parietal pleura at the time of the original infection has been suggested by Homans[7] as an etiological factor of importance in determining the tendency to chronicity.

If the lower margin of the lung be held down by adhesions to the diaphragm he believes that the prognosis is favorable; the lung will expand readily after drainage. If, on the other hand, the lung is collapsed and adherent and the lower margin is not in contact with the diaphragm the prognosis is bad; chronic empyema is likely to occur. He shows a silhouette taken from a roentgen-ray plate in one case of chronic empyema which represents a type seen in chronic suppurative pleurisy when there has been a large collection of pus in the chest. The lung is usually either compressed so that there is only a narrow band of lung tissue in contact with the vertebral column or, as in his illustration, drawn upward away from the diaphragm. The roentgen-ray photographs in Cases VIII and XVIII are very like his diagram. Obviously a small sacculated empyema favorably situated for drainage offers a good prognosis. Also, obviously, a chronic empyema involving the entire pleural cavity, with lung completely collapsed, presents a more difficult problem than a circumscribed chronic empyema. His theory seems to me, however, to attribute a permanency to the original plastic adhesions, as if they were unmodified by the duration, character and treatment of the infection, unaltered by protophytic ferment and proteolytic antiseptic solutions, uninfluenced by the mechanical factors of intra- and extrapulmonary pressure. A similar theory applied to the permanency of the original plastic adhesions about a focus of infection in the peritoneum would lead to conclusions at variance with common experience.

The shape of the empyema cavity has a significance in determining the readiness with which it can be drained and cured. If it is irregular, with secondary pockets or diverticuli, or presents a considerable cavity connected with the main cavity by a narrow channel, all the phenomena of intermittent drainage or incomplete drainage may be produced by the shutting off of a loculus or by the more or less complete blocking of a channel; drainage of the main pocket will evidently be inefficient. Multilocular empyemata and lung abscesses are frequent autopsy findings. In fact, the mortality in acute empyema seems to be

largely due either to the fact that the empyema is only one of the localizations of a general infection which may lead to death with lesions in the lungs, pericardium and meninges or to undrained, circumscribed collections of pus. For example, in the necropsy findings reported in 16 fatal cases at Camp Sheridan, Ohio, 14 had one or more undrained collections of pus. In a fifteenth there was a miliary tuberculosis. In Case II, for example, an abscess was found in the left chest above the fourth rib containing 200 c.c. of pus. The pleural cavity below that point had been drained. There was a second pus pocket between the upper and lower lobe.[8] If death does not occur and the pus from one of these secondary foci finds its way into the main cavity we have produced an irregular cavity imperfectly drained. In some of these cases a secondary opening occurs spontaneously through the lung, either a lung abscess breaking into the pleural or a loculated collection of pus finding its way through the lung and draining through a bronchus. Chronic empyema results when the microörganisms are attenuated and there is inadequate and intermittent drainage. Obviously, the virulence of the infection or the complete absence of drainage leads either to the death of the patient or the recognition and early treatment of the condition.

In Cases I, IV, V, VI, VII, IX, X and XVI the large empyema cavity was draining both through the chest and through the lung. In Case IV there was an abscess in the upper lobe that communicated with a bronchus and with the pleura, so that there was a dumbbell-shaped cavity draining at each end. In Case XVI there was a similar condition, but the abscess was in the lower lobe. In these cases the large opening into a bronchus is an etiological factor in the persistence of the suppuration process. At times there is free drainage through the bronchus, at times it is blocked and the pus from the infected area in the lung backs up and empties into the pleural cavity. We have again produced the phenomena caused by the intermittent collection of an exudate under tension about a focus of infection.

We have evidence from autopsy findings that the lung may

expand almost completely as early as the eighth day after the evacuation of a very large purulent exudate followed by simple drainage with tubes.[9] It was long ago pointed out by Schede[10] that a closed uninfected pneumothorax rapidly disappeared. During the war Bastinelli[11] found satisfactory restoration of lung expansion after an artificial pneumothorax which had been established and maintained for from twelve to fifteen days. Since we have made routine roentgen-ray examinations I think many of us have been surprised when evidences of infection are no longer present, as shown by the mucoid nature of the wound secretion or by negative bacterial findings, to see that the lung expands satisfactorily if the outer wound is allowed to close, even in the presence of a considerable pneumothorax. When expansion has taken place and the infection has ceased, roentgen-ray examination shows that the thickened pleura gradually returns to a layer so thin that it is no longer opaque to the roentgen ray even when there has been long-continued infection and the pleura has been seen to be much thickened at operation. (Case II.)

I believe that chronic suppurative pleurisy, excepting when there are complicating conditions in the lung or an underlying tuberculous infection, should not occur. I feel sure that in the majority of cases there has been a failure to appreciate the fundamental principle involved in treating an infected cavity; that an absolutely free external passage for the exudate must be provided as long as infection is present; that scrupulous cleanliness must be observed in the after-care; that one must be always on the lookout for the possibility of secondary loculi and foci of infection and shut-off portions of the drainage tract; that in a freely drained cavity surface contamination does not lead necessarily to reinfection, but that in a poorly drained cavity reinfection and secondary infection are very liable to occur. I believe that surgeons with very different ways of operating and very diverging ideas regarding after-care get equally good results provided these essentials are borne in mind. I believe that the entrance of air through the thoracic wound to an undesirable degree can be assured by very simple means; that

although the danger of early operation in streptococcus infection while pneumonia is still present has been recently generally recognized,[12] this by no means implies the desirability of a long delay and treatment by aspiration after the pneumonic process is over and the exudate is purulent or seropurulent in character. I think no case should be allowed to leave a hospital with a drainage tube in the chest; that all patients with a closed, even if apparently sterile, pneumothorax should be kept under close observation until it disappears. I think that there should be a more general recognition that not only high temperature and obvious signs of infection indicate a pent-up collection of pus, but that a slight afternoon temperature, a rapid pulse, loss of appetite, vague discomfort in the chest—in short, a failure to return to vigorous health—are very suggestive of a hibernating pleural abscess. Finally, that in the treatment of acute empyema will generally be found the etiological factors of the chronic condition.

In one-half of the cases of chronic empyema in my series there was no complicating lesion of the lung, no infection with tubercle bacilli, no complexity of the original cavity.

Case I.—R. S., aged forty-three years, January, 1910. Tuberculosis of lung; chronic empyema; rupture through bronchus. Operation: Two stages; thoracoplasty; portions of 3d, 4th, 5th, 6th, 7th and 8th ribs and parietal pleura resected. Calcareous plates on pleura. Lung completely collapsed. Died two months later; emaciated; still had persistent sinus.

Case II.—C. B., aged eighteen years, August, 1911. Chronic empyema, with very large cavity; lung completely collapsed. Time elapsed since operation for acute empyema, three years. Operation: Extensive thoracoplasty; two stages; portions of 3d, 4th, 5th, 6th, 7th, 8th and 9th ribs resected, with adjoining parietal pleura; partial decortication of lung. Result: Cured. Roentgen-ray examination May, 1920 (Fig. 1), nine years after operation. Gain in weight about thirty pounds. Original illness: Metapneumonic empyema. First operation: Thoracot-

omy, with aspiration drainage. Second operation: Thoracotomy, with rib resection; aspiration drainage with rubber bag.

Fig. 1.—Case II

Case III.—J. S., aged thirty-three years, March, 1911. Chronic empyema. Moderate-sized cavity. Time elapsed since operation for acute empyema, five years. Two drainage tubes found in pleural cavity. Operation: Partial thoracoplasty;

portions of 5th, 6th, 7th and 8th ribs and parietal pleura resected. Tubes removed. Result: Cured. Gain in weight forty pounds. Original illness: Empyema following pneumonia. Rib resection, with tube drainage.

Case IV.—P. H., aged thirty-eight years, April, 1911. Chronic empyema; communication with bronchus; very large cavity. Time elapsed since operation for acute empyema, seven years. Old drainage tube found in pleural cavity. Operation: Partial resection of 2d to 8th ribs, with parietal pleura. Result: Health improved, able to work as hod-carrier, but coughed up pus from time to time. Died two years later of meningitis (pneumococcus?).

Case V.—J. K., aged seventeen years, October, 1912. Chronic empyema; bronchial fistula; small cavity, the size of an orange, communicated with bronchus. Time elapsed since rib resection for acute empyema, five months. Operation: Thoracoplasty. Result: Cured.

Case VI.—H. W., aged eighteen years, September, 1913. Chronic empyema; lung abscess; bronchial fistula. Time elapsed since operation for acute empyema, fourteen months. Cavity small. Operation: Partial thoracoplasty. Result: Improved. Still has small lung abscess draining through bronchus. Is able to work as clerk.

Case VII.—B. S., aged thirty years, February, 1913. Chronic empyema; lung abscess; bronchial fistula. Duration, two years. First operation: Thoracoplasty. Result: Improved. Second operation: Resection of portions of lung with fistula. Died shortly after operation.

Case VIII.—C. U., aged thirteen years, October, 1913. Chronic empyema; very large cavity. Time elapsed since operation for acute empyema, two years. Operation: Extensive rib resection; portions of 3d, 4th, 5th, 6th, 7th, 8th and 9th ribs, with parietal pleura removed. Result: Cured. Roentgen ray April, 1920 (Figs. 2 and 3) seven years after operation. Has learned trade of carpenter.

CASE IX.—W. N., aged forty-four years, October, 1914. Chronic empyema; bronchial fistula; large cavity. Operation:

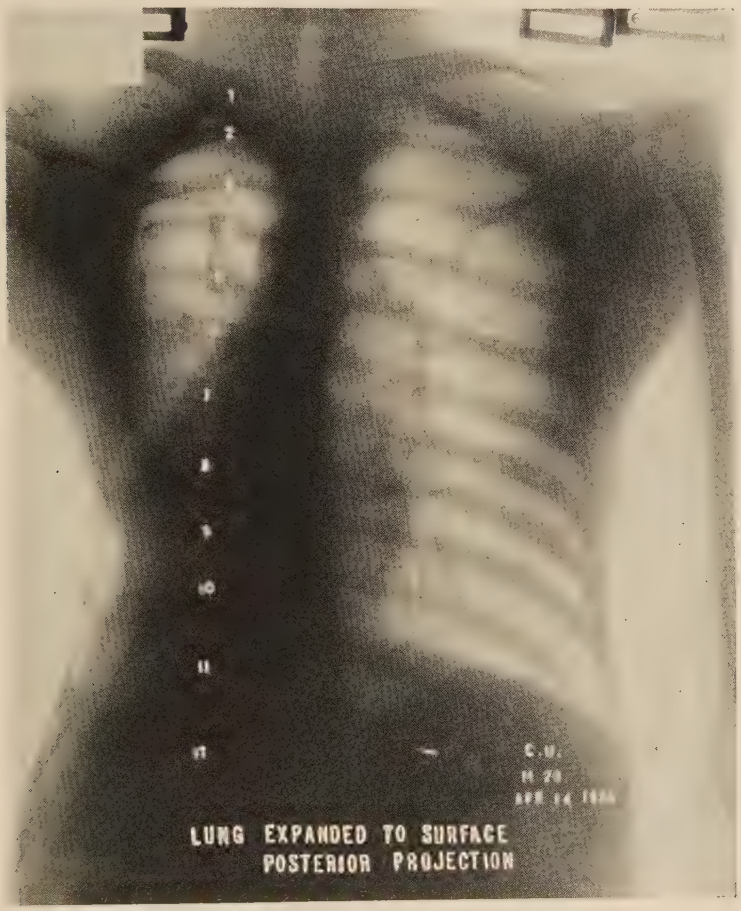

FIG. 2.—Case VIII. Seven years after extensive thoracoplasty for chronic empyema.

Thoracoplasty; resection of portions of 4th, 5th, 6th and 7th ribs and parietal pleura. Result: Improved. Still coughs, has never been able to work.

Case X.—M. G., aged thirty-five years, June, 1915. Chronic empyema; bronchial fistula; moderate-sized cavity. Operation:

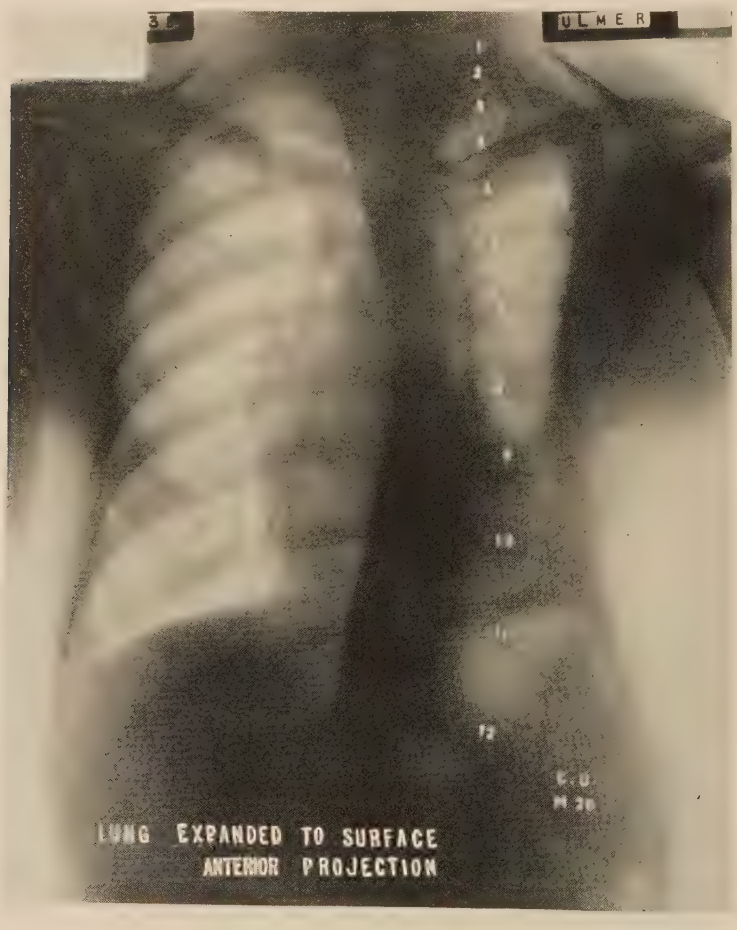

Fig. 3.—Case VIII. Seven years after extensive thoracoplasty for chronic empyema.

Thoracoplasty; portions of 6th, 7th and 8th ribs resected. Result: Improved. Late result unknown.

Case XI.—M. G., aged fourteen years, August, 1915. Chronic empyema; large cavity. Time elapsed since operation for acute

empyema, thirteen months. Operation: Resection of portions of 7th, 8th and 9th ribs, with parietal pleura and a small strip

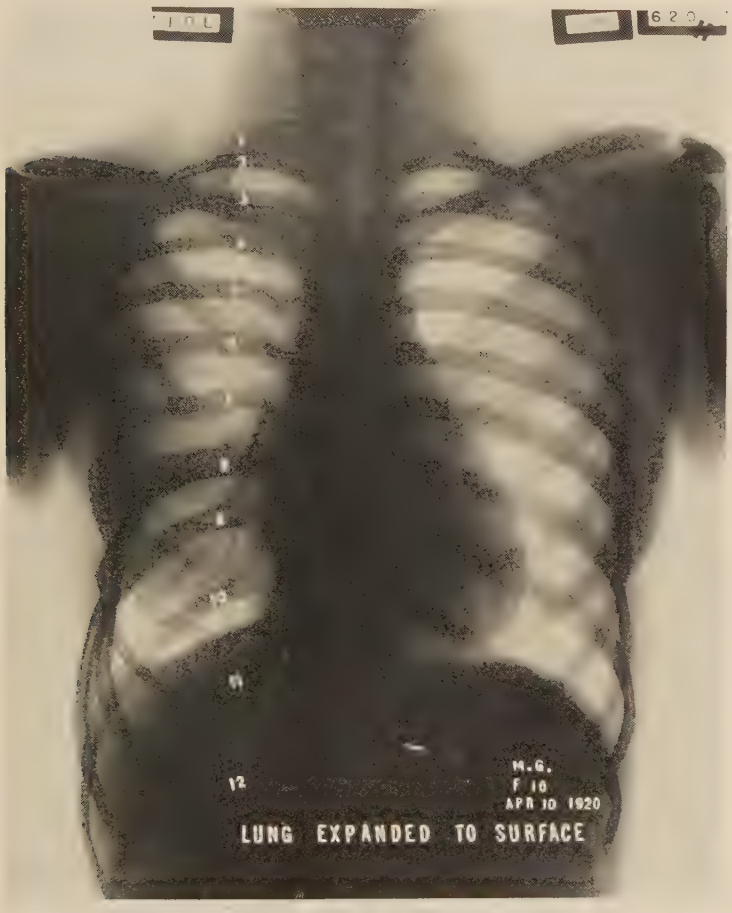

FIG. 4.—Case XI. Five years after thoracoplasty for chronic empyema.

of pulmonary pleura. Result: Cured. Roentgen ray April, 1920, five years after operation (Fig. 4).

CASE XII.—C. N., aged thirty-eight years, February, 1916. Chronic empyema; large cavity; tuberculosis of pleura; osteo-

myelitis of ribs and body of vertebra. Operation: Multiple rib resection; removal of parietal pleura; sequestrum removed

FIG. 5.—Case XVII. Three years after extensive thoracoplasty.

from body of vertebra (Dr. N. Green). Result: Cured. In December, 1919, roentgen ray showed no cavity. Patient in good health; works as clerk in sanitarium.

CASE XIII.—J. G., aged thirty-four years, January, 1916. Chronic empyema; moderate cavity. Time elapsed since

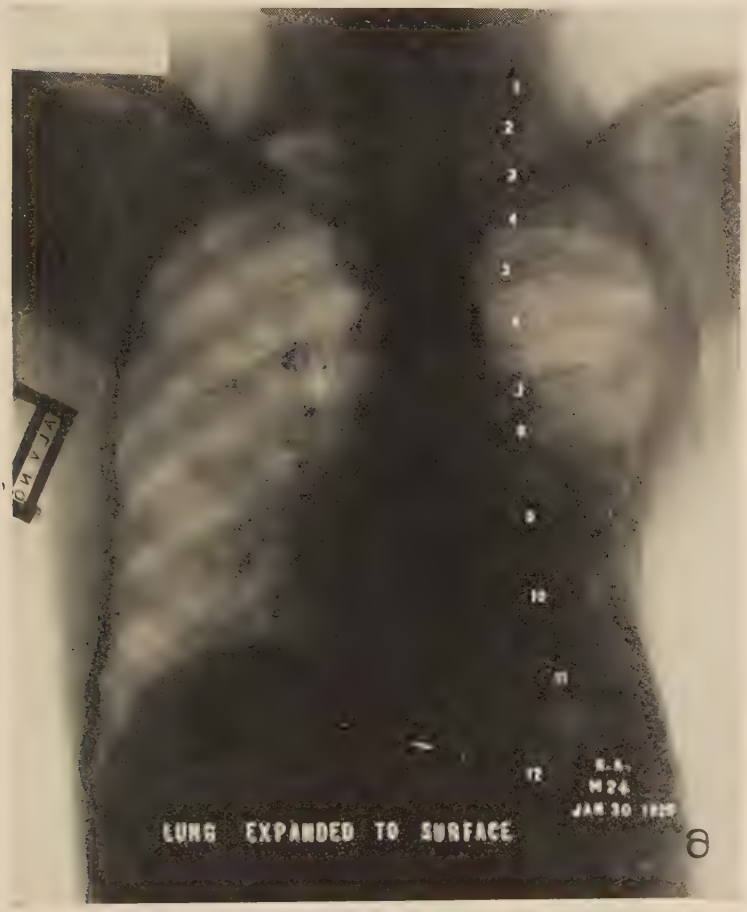

FIG. 6.—Case XVIII. Three years after operation for chronic tuberculous empyema, with extensive tuberculosis of ribs.

operation for acute empyema, eight months. Operation. Resection of 7th, 8th, 9th and 10th ribs, with parietal pleura: Result: Cured. Patient not seen since 1916.

Case XIV.—F. L. F., aged twenty-eight years, September, 1918. Chronic empyema; large cavity. Resection of 6th, 7th, 8th and 9th ribs, with parietal pleura. Result: Cured.

Case XV.—J. S., March, 1917. Chronic empyema; small cavity. Time elapsed since operation for acute empyema, four months. Operation: Resection of portions of 6th and 7th ribs and parietal pleura. Result: Cured.

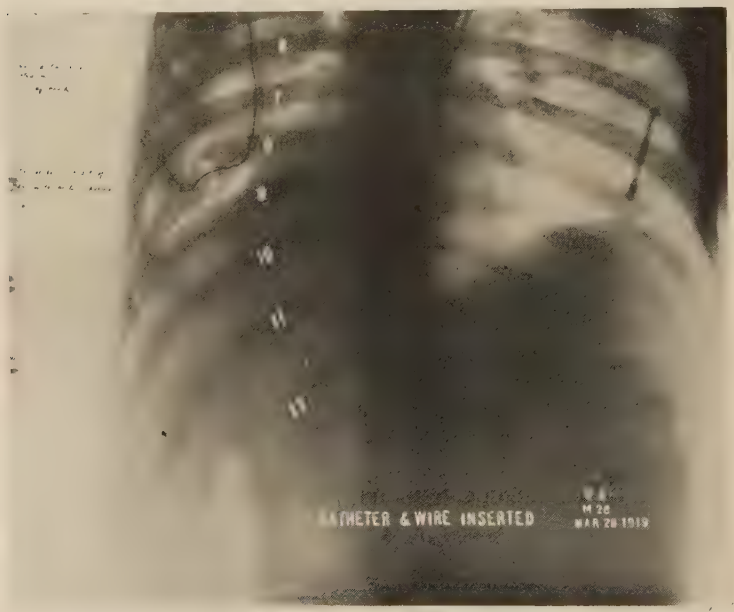

Fig. 7.—Case XIX. Before operation. Wired catheter passed through sinus into pleural cavity. Ring of bone the site of resection of rib for acute empyema. Posterior position.

Case XVI.—A. R., Aged forty-five years, February, 1916. Chronic empyema; lung abscess; bronchial fistula. Duration of illness, one year. Operation: Partial resection of 7th, 8th and 9th ribs; drainage of abscess. Result: Improved. Died two years later of chronic nephritis.

Case XVII.—W. R., aged nineteen years, May, 1917. Chronic empyema; very large cavity. Time elapsed since operation for

acute empyema, eighteen months. Operation: Extensive thoracoplasty; partial resection of 3d, 4th, 5th, 6th, 7th, 8th and 9th

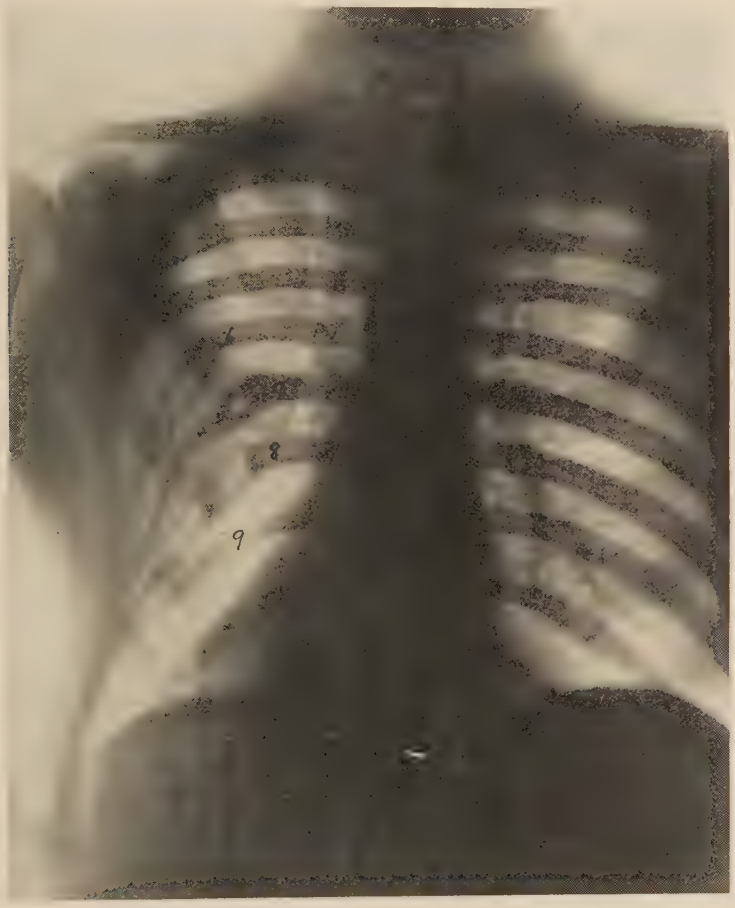

FIG. 8.—Case XIX. April, 1920. One year after operation. Regeneration of ribs. Lung expanded to full extent. Excursion of diaphragm normal.

ribs, with parietal pleura. Incision of pulmonary pleura. Result: Cured. Roentgen ray (Fig. 5) three years after operation.

CASE XVIII.—R. A., aged twenty-one years, May, 1917. Chronic empyema; tuberculosis of pleura; extensive tuberculosis

of rib and chest wall. Operation: Three stages. Resection of portions of 2d, 3d, 4th, 5th, 6th, 7th, 8th and 9th ribs, with

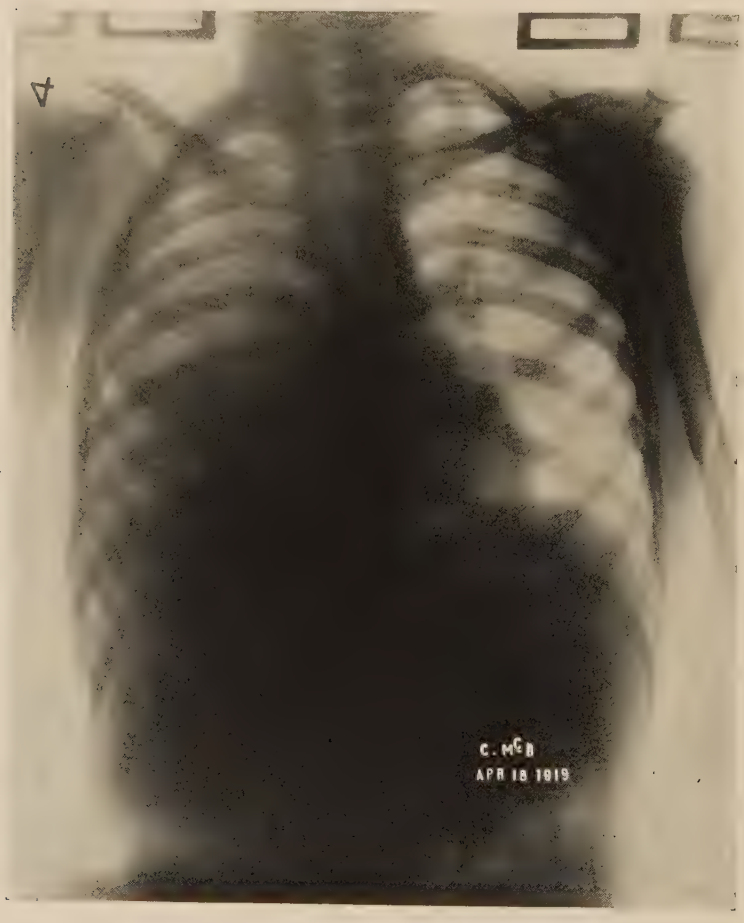

FIG. 9.—Taken before operation. Dense shadow on right side.

the parietal pleura; partial decortication of lung. Result: Cured. Roentgen ray (Fig. 6) three years after operation.

CASE XIX.—J. G. W., aged twenty-eight years, March, 1919. Chronic empyema; medium-sized cavity. Time elapsed since

operation for acute empyema, five months. Operation: Portions of 6th, 7th and 8th ribs removed. Carrel-Dakin irrigation.

FIG. 10.—Eleven months later, nine months after operation. Lung fully expanded. Pleura no longer casts shadow.

Wound closed when smears showed one organism to ten fields. Result: Cured (Figs. 7 and 8).

CASE XX.—C. McB., aged twelve years, June, 1919. Chronic empyema; medium-sized cavity. Time elapsed since operation

for acute empyema, five months. Operation: Partial resection of 6th and 7th ribs and parietal pleura. Pleura much thick-

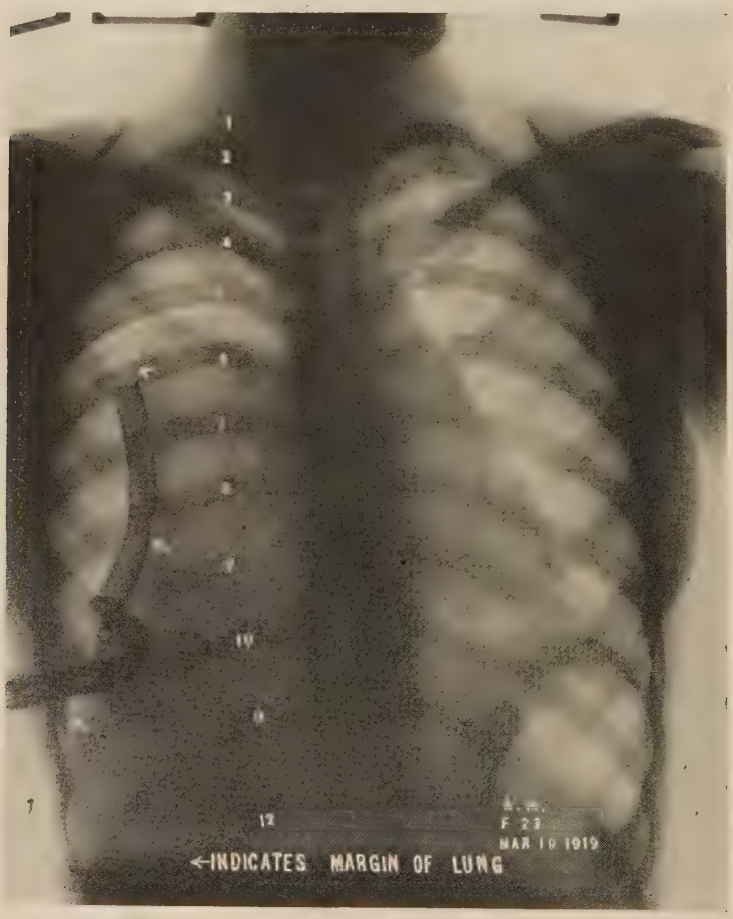

FIG. 11.—Drainage tube in place. Nine days after operation for acute empyema.

ened. Result: Cured. Fig. 9, taken before operation; Fig. 10, eleven months later. Nine months after operation lung fully expanded.

CASE XXI.—A. M., aged twenty-two years, March, 1920. Chronic empyema; long shallow cavity. Time elapsed since operation for acute empyema, one year. Operation: Thoraco-

FIG. 12.—One year later, two days before thoracoplasty. Long narrow cavity.

plasty; resection of portions of 7th, 8th and 9th ribs, with parietal pleura. Result: Cured. Nine days after operation for acute empyema (Fig. 11). Fig. 12, *x*-ray photograph one year later,

showing long narrow cavity. Roentgen ray June, 1920, shows lung expanded to surface.

References

1. Cestan, E.: Thérapeutique des Empyèmes, Paris, 1898.

2. Brin: Pleurésie Purulente Enkystée de la Base avec Calcification de la Pleure Costale Gauche, Latence Absolue Pendant Toute la Vie, Soc. Anat. de Paris, October, 1897.

3. Stevens, Franklin: Recurrences after Operation for Empyema, Jour. Am. Med. Assn., 1919, lxxiii, 812.

4. Netter: Utilité des Recherches Bacteriologique pour le Prognostic et le Traitement des Pleurésies Purulentes, Soc. Méd. des Hôp., 1890, 441.

5. Kiener: Des Pleurésies Fibrino-purulent es etdes Pleurésies Purulentes Proprement, leur Marche Naturelle Dites et leurs Indications Thérapeutiques, Revue de Médecine, 1890, xi, 881.

6. Bouveret: Empyema, Paris, 1889.

7. Homans, John: Prognosis and Treatment of Empyema, Annals of Surgery, 1918, lxvii, 697.

8. Dodge, W. T.: Empyema at Base Hospital (Camp Sherman), Autopsies, Jour. Am. Med. Assn., 1919, lxxii, 1808.

9. Herz: Zur Behandlung Jauchiger Empyeme, Centralbl. f. klin. Med., 1892, No. 41, i.

10. Schede, M.: Die Behandlung der Empyeme, Verhandlungen des 9 Kongresses f. inner. Med., 1890.

11. Bastinelli, R.: Artificial Pneumothorax in Chest Wounds, Surg., Gynec. and Obst., 1918, xxviii, 5.

12. Graham and Bell: Open Pneumothorax: Its Relation to the Treatment of Empyema, Am. Jour. Med. Sc., 1918, clvi, 839.

THE MORELLI METHOD OF ASPIRATION DRAINAGE FOR ACUTE EMPYEMA

By LINCOLN DAVIS, M.D.
BOSTON, MASS.

For many years surgeons operating for acute empyema have striven to obtain air-tight suction drainage of the chest, recognizing its importance and value in securing early reëxpansion of the lung, and hence in bringing about prompt functional cure.

It is quite generally recognized that a very important factor is the institution of suction drainage at a time when expansion of the lung is still possible, that is, before the retracted lung has become bound down by tough, organized, fibrinous exudate.

There have been many ingenious and useful devices for securing aspiration drainage which have given more or less satisfactory results in the hands of their originators, but no one method has been very generally adopted. Bülau,[1] at the Medical Congress of Vienna in 1890, advocated air-tight drainage of acute empyema by means of a catheter introduced through the cannula of a large trocar which is inserted through an intercostal space. The cannula is then withdrawn, leaving the catheter held tightly in place by the closely fitting soft tissues. The catheter is connected with a rubber tube which in turn is immersed in a bottle containing an antiseptic solution. This bottle being placed at a lower level than the chest, allows of siphon drainage. This method, with various modifications for retaining the catheter and rendering its fit air-tight, together with the addition of irrigation, has been used up to the present time, and lately has

[1] Ztschr. f. klin. Med., 1890, xviii, 31.

received added prestige from its successful and wide application in the epidemics of empyema following influenza, by Whittemore and others. It is a simple and extremely useful method. There are, however, certain disadvantages. (1) The caliber of the catheter being necessarily restricted it is liable to become clogged. This may be obviated to a certain extent by systematic irrigation. (2) It is extremely difficult to maintain a hermetically air-tight joint for more than a few days at the most, after this time leakage occurs about the catheter, and it is then practically impossible to restore the original air-tight condition. (3) Any adjustment or changing of the catheter is very difficult. (4) If the lung is not readily dilatable all the pus cannot be drained from the pleural cavity by this method so long as the apparatus remains air-tight.

Forlanini,[1] of Pavia, pointed out the latter defect in the method and advocated, in 1890, preliminary thoracentesis, with the introduction of air into the pleural cavity simultaneously with the evacuation of the pus, followed later by the institution of suction drainage by the method of Bülau. Forlanini insistently urged the advantages of producing artificial pneumothorax in empyema, not only in permitting complete evacuation of the effusion in cases in which the lung is bound down and the chest walls rigid, but in doing so without change of intrapleural pressure and without arousing the so-called pleural reflexes of pain, cough, dyspnea, etc. He also advocated inhalations of compressed air in the after-treatment to aid in reëxpansion of the lung.

R. W. Parker,[2] of London, had previously, in 1882, advocated pneumothorax in the treatment of empyema, but his suggestion seems to have found little favor at that time.

Eugenio Morelli,[3] a pupil and assistant of Forlanini, who had worked for many years with the latter in the development of his therapeutic pneumothorax in phthisis, recognized the applica-

[1] Policlinico, 1890, Nos. 10, 11, 12, 13.
[2] Lancet, 1882, p. 689.
[3] La Cura delle Ferite Toraco-polmonari, Bologna, 1918.

bility of artificial pneumothorax in the treatment of wounds of the lung during the war and devised an ingenious apparatus for the treatment of war wounds complicated by empyema, which



Fig. 1.—Pneumatic jacketed drainage tubes; three sizes.

has a useful application to the empyema of civil life. Having had occasion to observe Morelli's marked success with the empyema of war wounds, and subsequently having applied the method

myself in a small number of cases of civil empyema with very satisfactory results, I feel that the method is worthy of consideration in a symposium on empyema.

Morelli has devised a pneumatic jacketed drainage tube (Fig. 1), which by inflation of the dumb-bell-shaped soft-rubber jacket closes the thoracotomy wound hermetically tight. This will remain tight for many days, is easily kept in place and can readily be readjusted if for any reason the drainage is not satisfactory.

FIG. 2.—Metallic spider for holding drainage tube in place.

It is held firmly in place by means of a spider (Fig. 2) made of thin malleable metal which fits over the pneumatic sac, the feet of the spider being adjusted to the chest wall. The drainage tube is passed through a central opening in the spider, which is of slightly smaller caliber than the latter. The whole is covered with a layer of gauze and fastened by strips of adhesive. These drainage tubes were incidentally pictured in an article by Lieutenant-Colonel Bastianelli on "Artificial Pneumothorax in

Chest Wounds," in *Surgery, Gynecology and Obstetrics* for January, 1919, p. 5. The technic of the method is as follows: The diagnosis of empyema having been made, a preliminary thoracentesis is performed and the purulent exudate is withdrawn and replaced with an equal quantity of air by means of the apparatus depicted in (Fig. 3).

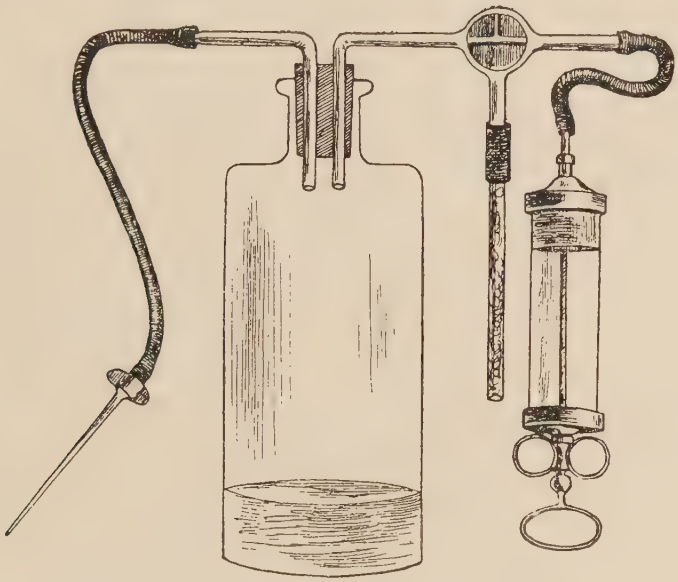

FIG. 3.—Thoracentesis apparatus.

This consists of a bottle, of the capacity of a liter, closed by a rubber stopper which is perforated by two glass tubes, one of which is connected by rubber tubing to the thoracentesis needle, and the other with a 3-way cock, which is in turn connected with a filter, consisting merely of a glass tube filled with sterile cotton, and finally a syringe of at least 100 c.c. capacity with a perfectly fitting piston.

The apparatus is operated as follows: Having been sterilized and the joints made tight, the large thoracentesis needle is introduced into the chest, and the connection between the bottle and the syringe being open a suction stroke is made with the

piston of the syringe; this produces a rarefaction of the air contained in the bottle, and results in the flow of the fluid in the chest into the bottle to replace the displaced air. When the flow of the fluid begins to subside a reverse stroke is made with the piston of the syringe forcing the air in it back again into the bottle, whence, finding its place taken by the fluid, it will be obliged to pass on into the pleural cavity, where it will be distinctly heard gurgling through the pleural effusion as it rises to its upper surface. When the gurgling ceases a new aspiration is made with the syringe, followed by a new insufflation of air into the pleural cavity, and so on, until all the fluid has been evacuated from the chest or the bottle is completely filled with fluid, all the air which it previously contained having entered the pleural cavity. When one bottle is full another may be substituted and the process repeated. The 3-way cock and filter come into play when it is desired to put in a greater quantity of air than the amount of fluid extracted, or *vice versa*. With this method, if the air is warmed to body temperature, there is absolutely no change in the intrapleural pressure, and no modification of the cardiac condition results. There is no danger of edema of the lung nor sudden rupture of pleural adhesions, no sense of constriction nor other pain, no cough nor stimulation of the pleural reflexes: in fact, no untoward disturbances of any kind.

Morelli strenuously advocates this method of thoracentesis for all pleural transudates and exudates of whatever nature, claiming, with much logic, in addition to the advantages already enumerated, the much lesser likelihood of a reaccumulation of fluid than when aspiration is done by the ordinary method which greatly increases the negative pressure of the pleural cavity.

Having replaced the pus of the empyema with an equal amount of air, on the following day a thoracotomy with resection of a square piece of rib is done under local anesthesia, and the previously described pneumatic drainage tube inserted and connected with the apparatus in (Fig. 4), consisting of a wooden stand upon which are set three bottles. The upper bottle is for the purpose of irrigation. The middle bottle placed at about

the level of the bed is connected directly with the drainage tube and is partly filled with an antiseptic solution; it is connected by

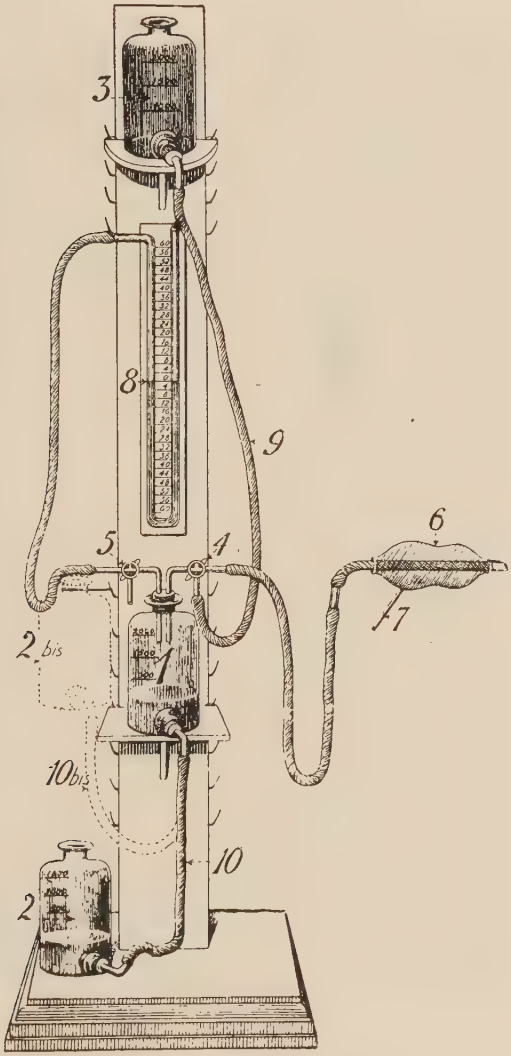

FIG. 4.—Empyema apparatus.

a tube at its bottom with a third bottle set at a lower level and aspiration drainage is exerted by the difference in level of the

fluid in the two bottles. In the case of a recent war wound of the lung complicated by empyema, Morelli maintains at first drain-

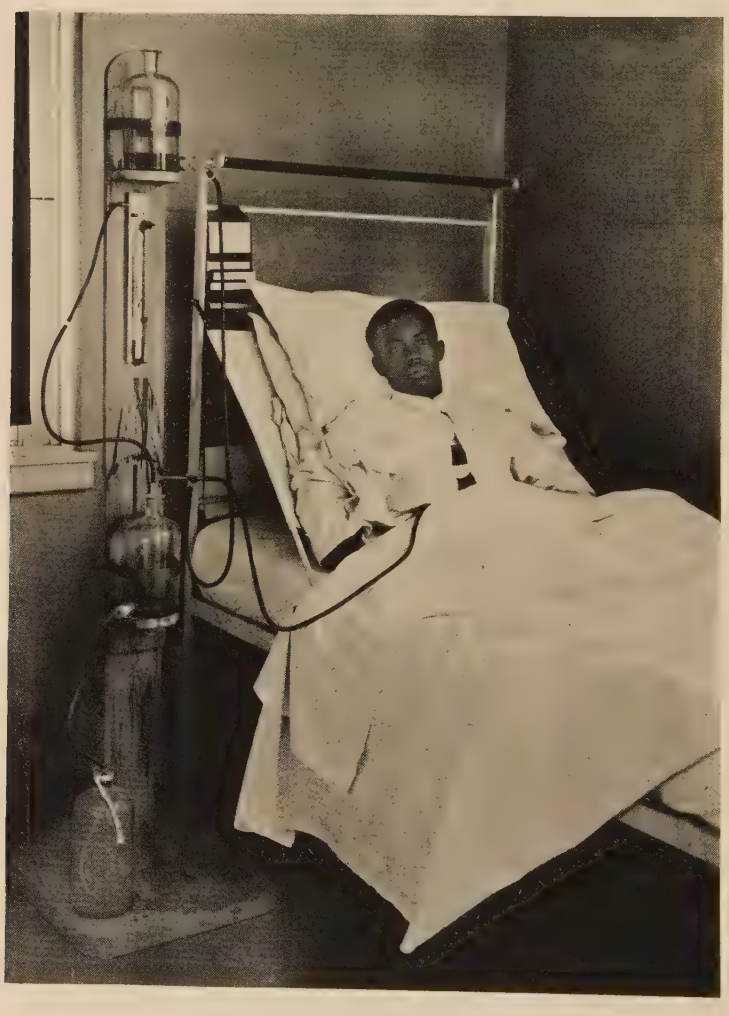

FIG. 5.—Apparatus set up.

age with positive pressure in the pleural cavity by raising bottle (2) to the position of (2 bis) in the cut above the level of bottle

(1). For ordinary cases of civil empyema this is not necessary and negative pressure is exerted at once by lowering bottle (2) to a point corresponding to the amount of negative pressure desired. A manometer is connected with bottle (1) by a 3-way cock at (5), which registers the negative pressure in bottle (1) as well as in the pleural cavity. There is a 3-way cock also at (4), which allows of irrigation, which is useful in clearing the tubes of coagula of fibrin or inspissated pus.

This apparatus, which seems somewhat complicated, works very well in practice. It can be seen at a glance whether or not the drainage is working, and irrigation may be carried on with great ease and perfect cleanliness. For practical purposes the whole thing may be greatly simplified by merely connecting the pneumatic jacketed drainage tube with two bottles containing liquid at different levels, one standing on a chair and one on the floor, cutting out 3-way cocks, manometer and irrigation bottle, which are unessential accessories.

The advantages of this method are that not only can large fibrinous clots be removed directly at the time of operation, but a drainage tube of larger caliber than the trocar method permits of can be used, so that subsequent obstruction of the drainage is less likely. Furthermore, air-tight drainage can be maintained for a longer period of time, as the pneumatic jacket of the tube adjusts itself to the wound and does not tend to work loose; it causes no necrosis of the tissues, but bright granulations spring up along the tract of the wound, which heals promptly when the tube is removed. It is at all times surprisingly comfortable. It is especially adapted to cases in which there are fibrinous clots which so often clog the tubes of small caliber, and in cases in which through delay in operating tough adhesions have formed, which will require somewhat prolonged aspiration for the complete reëxpansion of the lung.

If it is inconvenient, as is often the case, to do a preliminary thoracentesis with induction of artificial pneumothorax, in my opinion the same benefits may be obtained, with practically negligible risk, while performing the operation at one sitting.

It is only necessary to exercise care in allowing the pus to escape very slowly from the thoracotomy wound by making at first a small opening in the pleura, which can be controlled by digital pressure, preventing at the same time the rapid and tumultuous entry of air, which is as much to be avoided as is the forced expulsion of pus.

For cases in children, or in recent cases in which the effusion is thin and of a turbid serous nature, the trocar and catheter method is quick, simple and entirely adequate, the importance, however, of replacing the withdrawn purulent exudate with air, so as to allow of the complete evacuation of the former, as insisted upon by Forlanini and Morelli, should be borne in mind. This can be accomplished by means of the thoracentesis apparatus of bottle and syringe of (Fig. 3), which should be connected with the catheter as soon as the latter is introduced into the chest, and negative pressure instituted later by means of the two-bottle method. If the lung is fully dilatable no harm is done by introducing the air, which will readily be sucked out again by the apparatus. Simple siphon drainage, however, will not suffice for this, as the siphonage will be broken by the column of air in the tube, which will not affect, on the contrary, the two-bottle method.

The value of irrigation with Dakin's solution or other antiseptic in empyema is emphasized by Morelli, and is now generally recognized. Apart from its antiseptic value it is of special importance in all cases of air-tight suction drainage in keeping the tubes free from plugging. Care must be taken to introduce only small amounts of fluid at a time and to make sure that as much returns from the chest as is put in.

The features of the Forlanini-Morelli method in the treatment of empyema are in brief: the systematic induction of pneumothorax, continuous aspiration drainage combined with irrigation and an air-tight pneumatic jacketed drainage tube of great value in appropriate cases.

EMPYEMA: A SYLLABUS OF OPERATIVE TREATMENT

By HOWARD LILIENTHAL, M.D.
NEW YORK

This is an attempt to standardize the selection of operative methods in the surgery of empyema of the thorax.

It is presented here for discussion and criticism. It consists of:

1. A classification of the conditions demanding operation.
2. A list of procedures, with a brief description of each.
3. A synoptic table showing the types of the disease paired with their appropriate operations.

In such a presentation as this there can be given no complete plan for carrying any save the simplest cases to their conclusion; but complications such, for example, as the discovery of an unsuspected sacculation may put the case in another class which can be treated according to the table. It is also recognized that there can be no absolute rule for the treatment of any given case because the conditions are never twice exactly alike, but this does not forbid our attempt to construct a model.

Bacteriology is not considered because it has nothing to do with our subject. It is merely of prognostic importance.

Every case is assumed to have been roentgenologically studied in acute intrathoracic tension, when the therapeutic aspiration is urgent even without the roentgen ray.

Anesthesia in minor operations should be local even with rib resection. Intrapharyngeal differential pressure by ether vapor or nitrous oxide and oxygen is preferable for the more serious procedures.

The Carrel-Dakin method is recommended as a most valuable postoperative aid, but it should not be employed when the instillation of even small quantities of the fluid, with a wide opening for its escape from the thorax, is followed by a severe coughing. Also in children and in a few susceptible adults the long-continued application of this treatment seems to cause a general deterioration. Such patients improve on discontinuing this remedy.

Empyema can best be treated in a hospital.

CLASSIFICATION OF CONDITIONS DEMANDING OPERATION

(Tuberculosis, syphilis, actinomycosis, etc., are not included)

EMPYEMA

ACUTE	A. Seropurulent effusion B. Frankly purulent exudate	(*a*) General or large. (*b*) Sacculated, single or multiple. (*c*) With purulent expectoration (hidden lung abscess or empyema emptying through a bronchus). (*d*) With lung abscess (intrinsic). (*e*) With lung abscess (bronchiectatic) (*f*) From extrapleural sources other than lung, by direct extension. (*g*) With tension pneumothorax. (*h*) Traumatic.
CHRONIC		(*a*) With closed thorax. (*b*) With pleurobronchial fistula and closed thorax. (*c*) With open thorax (fistula). (*d*) With pleurobronchial fistula and open thorax. (*e*) With fibrosis and permanent contraction of lung.

A LIST OF PROCEDURES, WITH A BRIEF DESCRIPTION OF EACH

Procedure No. 1.[1] Diagnostic aspiration. Only a few cubic centimeters to be removed. Syringe to be detached and needle to be withdrawn while 2 per cent. lysol is slowly injected through it into the puncture tract to prevent infection and phlegmon of the chest wall (5 to 15 c.c. may be injected).

Procedure No. 2. Therapeutic aspiration.[1] Use fine trocar and cannula with rubber tube attached so as to empty the chest by patient's expulsive efforts and by gravity. No forcible suction to be employed. Air permitted to replace the fluid removed or if desired the air may be expelled from the chest by the patient's straining with closed glottis or even by his normal respirations, the tube being pinched during *inspiration* until no more bubbles appear on straining or on *expiration* from end of tube held under water. The cannula is then quickly withdrawn. (Roentgen ray will demonstrate the efficacy of this method of getting air out of the thorax.)

Procedure No. 3. Minor intercostal thoracotomy and tube drainage (with or without airtight closure).

Procedure No. 4. Resection of rib with its periosteum. Tube drainage.[2]

Procedure No. 5. Major intercostal thoractomy with rib retraction (rib spreader) and full exploration of chest cavity with mobilization of lung[3] if desirable.

Procedure No. 6. Non-collapsing major thoracoplasty, with costotomy but no resection of ribs. Mobilization of lung.[4]

Procedure No. 7. Various forms of collapsing thoracoplasty (Schede, Estlander, Wilms, etc.).

SYNOPTIC TABLE, SHOWING THE TYPES OF THE DISEASE PAIRED WITH THEIR APPROPRIATE OPERATIONS

Condition.	Operation.
Acute Seropurulent Effusion:	
1. General or large.	Procedure No. 2. Repeat if necessary until frank pus is present or no more fluid accumulates.
2. Sacculated, single or multiple.	Procedure No. 2 applied to larger cavities. Repeat if necessary until pus is present or no more fluid accumulates.
3. With purulent expectoration, hidden lung abscess or empyema emptying through a bronchus.	Procedure No. 2. Repeat until pus is present (or no more fluid accumulates) then Procedure No. 5.

---

[1] Lilienthal, Brickner and Kellogg: Thoracic Injuries. Report of Cases Treated by Surgical Team 39, etc., Jour. Am. Med. Assn., March 22, 1919, vol. lxxii.

[2] Lilienthal, Howard: Thoracic Fistula and Chronic Empyema, Ann. Surg., July, 1919.

[3] Lilienthal, Howard: Empyema, Ann. Surg., September, 1915.

[4] Lilienthal, Howard: Thoracic Fistula and Chronic Empyema, Ann. Surg., July, 1919.

SYNOPTIC TABLE, SHOWING THE TYPES OF THE DISEASE PAIRED WITH THEIR APPROPRIATE OPERATIONS—*continued*

Condition.	Operation.
4. With lung abscess (intrinsic).	Procedure No. 4. This is preliminary as a rule but it may prove curative.
5. With lung abscess (bronchiectatic).	Procedure No. 5 with a view to dealing later on or at the same time with pulmonary condition (lobectomy).
6. From extrapleural sources other than lung by direct extension.	Procedure No. 4. Generous resection and dealing at once with the cause (*e. g.*, subphrenic abscess).
7. With tension pneumothorax.	Procedure No. 2 followed by Procedure No 3.
8. Traumatic.	Procedure No. 2 followed by Procedure No. 3 or 5 according to extent of trauma.
Acute Frankly Purulent Effusion:	
1. General or large.	Procedure No. 3 followed if course is unsatisfactory by Procedure No. 5 (fluoroscopic study important).
2. Sacculated, single or multiple.	If single, Procedure No. 4. If multiple, Procedure No. 5.
3. With purulent expectoration (hidden lung abscess or empyema emptying through a bronchus).	Procedure No. 4.
4. With lung abscess (intrinsic).	Procedure No. 4. Generous resection with simultaneous or deferred drainage of abscess.
5. With lung abscess (bronchiectatic).	Procedure No. 5. Possibly as first stage of lobectomy.
6. From extrapleural sources other than the lung by direct extension.	Procedure No. 4, with immediate attention to cause.
7. With tension pneumothorax.	Procedure No. 2, later No. 3 or No. 5 according to roentgen ray.
8. Traumatic.	Procedure No. 4 (revision probably necessary).

SYNOPTIC TABLE, SHOWING THE TYPES OF THE DISEASE PAIRED WITH THEIR APPROPRIATE OPERATIONS—*continued*

CHRONIC EMPYEMA

CONDITION.	OPERATION.
1. With closed thorax (simple).	Procedure No. 5.
2. With pleurobronchial fistula and closed thorax (roentgen ray diagnosis pyopneumothorax).	Procedure No. 3, later No. 5.
3. With open thorax (fistula).	Procedure No. 6.
4. With pleurobronchial fistula and open thorax (thoracic fistula).	Procedure No. 6.
5. With fibrosis and permanent contraction of lung. (Demonstration at operation by impossibility of inflating lung with intrapharyngeal pressure after "decortication," and after weeks of further effort by blowing and coughing exercises.)	Procedure No. 7.

POSTSCRIPT.—The use of Beck's paste or of 5 to 10 per cent. iodoform in vaselin is recommended in certain narrow cavities which have previously been rendered bacteria-free or nearly so. This form of treatment is often successful even when there is an open bronchus at the end of the tract.

OBSERVATIONS ON THE TREATMENT OF CHRONIC EMPYEMA

By GEORGE J. HEUER
BALTIMORE, MD.

In 1913 a patient who had been treated for pulmonary tuberculosis by artificial pneumothorax came to us with a tuberculous empyema. We resected a rib and drained an empyema cavity containing over 1000 c.c. of thick, greenish pus in which were myriads of tubercle bacilli. The lung, due to its long period of collapse, was incapable of expansion and the patient's condition did not permit a thoracoplastic operation. Under the circumstances we tried repeated injections of Beck's bismuth paste, and although it required several months to accomplish it, we were astonished at the result. The tubercle bacilli disappeared from the discharge, the discharge itself became a clear straw-colored sterile fluid and the sinus tract spontaneously closed. The intrapleural cavity never became obliterated, yet the patient went about not at all inconvenienced by its presence. So far as we can gather this is the first case in which the complete sterilization of a chronic empyema cavity followed the prolonged use of antiseptic substances. It demonstrated to us that it was possible to sterilize empyema cavities and that sterile intrapleural cavities need not be surgically obliterated but were quite compatible with good health.

Since that time we have been deeply interested in the treatment of chronic empyema. Our experience soon showed that we, at least, were not able within a reasonable time to sterilize all empyema cavities by the injection of bismuth paste, and,

guided largely by animal experimentation, we have therefore sought for other methods which would cure chronic empyema and still avoid the mortality and the mutilation of thoracoplastic procedures such as the Estlander and Schede operations. Our observations on the treatment of chronic empyema before and

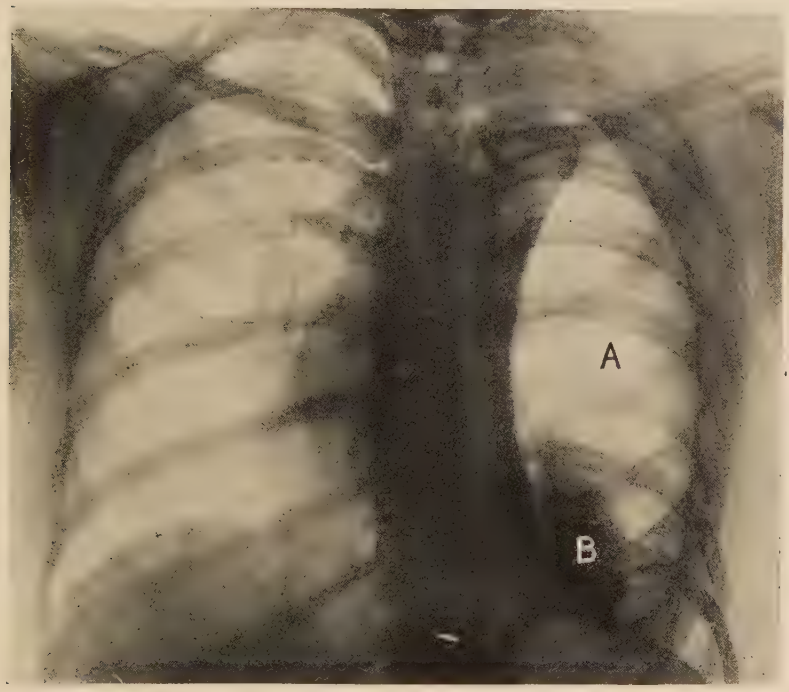

FIG. 1.—A tuberculous empyemic cavity sterilized by bismuth paste. *A*, empyemic cavity; *B*, a small mass of bismuth paste remaining in the cavity at the time of the closure of the sinus.

since the discovery of the Carrel-Dakin method of treating infected wounds concern the description of and the results obtained by these methods.

1. BISMUTH STERILIZATION OF EMPYEMA CAVITIES. In addition to the brilliant case described in our introductory remarks we have attempted the sterilization of chronic cavities with

bismuth paste in 6 cases. In 5 of them preliminary rib resection to establish a satisfactory sinus was necessary. The method is now well known and we need not pause over it. We should, however, like to add our experience to that of others who have had favorable results. In one patient with a large tuberculous empyema cavity similar to the one described we failed to completely sterilize the cavity during the period (two months) he was under our care, yet there was marked improvement, as indicated by the fall in the temperature and the gain in weight. In the smaller empyema cavities, however, and especially in the long tubular intrapleural sinus tracts of tuberculous origin, we have been quite uniformly successful, and we have 5 cases at present which have been healed over long periods. Our total results therefore in 7 cases are 6 successes and 1 failure. For the non-tuberculous cavities we have now, I believe, better methods of treatment; but if it is fair to judge from a small experience the tuberculous cavities respond more quickly to bismuth paste than to Dakin's solution.

2. Substitution of a Sterile Extrapleural Cavity for a Septic Intrapleural Cavity by Stripping the Parietal Pleura. It seemed possible from experiments on animals that an intrapleural cavity might be collapsed by stripping the parietal pleura according to the method of Tuffier and bringing it against the visceral pleura. A sterile extrapleural cavity would be the result, and thiis might be maintained by the injection of air or nitrogen. The operation was carried out away from the sinus tract and in a relatively aseptic field. A necessary requirement was that the sinus be at the lowermost point of the cavity. After the resection of 10 to 12 cm. of a single rib it was possible to strip the parietal pleura over a wide area. The procedure proved to be feasible if the parietal pleura were not too greatly thickened. In the presence of a rigid, board-like pleura, however, the result was that when mobilized it stretched across the thoracic cavity as a cord subtends an arc and could not be brought into contact with the visceral pleura. In 2 cases of this kind we were able to reduce

the size of the cavities by one-half and three-fourths but failed to completely obliterate them. In one case (reported to me by Dr. Cave, who at the time had assisted me with animal experiments) the procedure was successful. In view of the probable

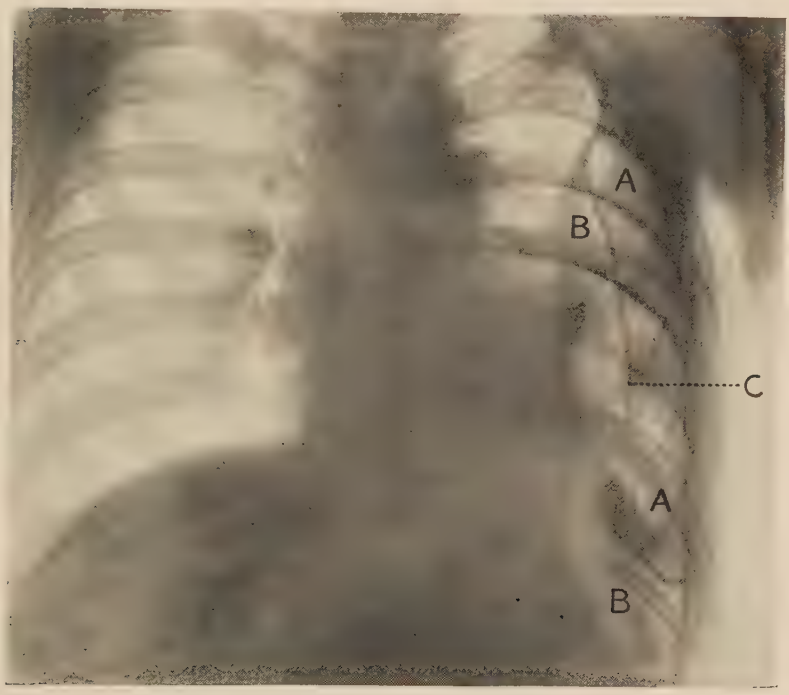

FIG. 2.—A tuberculous empyemic cavity in which an attempt was made to substitute a sterile extrapleural cavity for a septic intrapleural cavity by stripping the parietal pleura. (See text, Method 2.) The result, due to the thickness and rigidity of the parietal pleura, was a partial and not a total obliteration of the intrapleural cavity. *A*, extrapleural cavity; *B*, intrapleural cavity; *C*, the mobilized parietal pleura. (*X*-ray taken about ten days after operation.)

failure of this method in many cases it was abandoned. But our experience was productive in that it taught us that the parietal pleura over chronic empyema cavities may be stripped away from the chest wall, that we had therefore a method of

exposing the entire cavity through the resection of a single rib, that the presence of the thickened parietal pleura probably hindered the expansion of the lung and that its excision might therefore possibly permit the expansion of the lung. It led to two of the following procedures, (3) and (5).

3. Excision of the Mobilized Parietal Pleura over the Empyema Cavity. Irrigation of the Extrapleural Cavity with Dakin's Solution. Secondary Closure. It appeared from our previous observations that the thickened parietal pleura about an empyema cavity hindered the obliteration of the cavity. By stripping the parietal pleura away from the thoracic wall well beyond the limits of the empyema cavity and excising it along the line where it joins the visceral pleura it seemed to us that the cavity might more readily be obliterated. The result is an extrapleural cavity, presenting upon the mesial wall of which is an area of visceral pleura. The procedure, moreover, removes at least half of the infected pleural surface and allows the formation of granulation tissue from the thoracic wall. It is easier, I believe, than the Fowler or Delorme operation. The Dakinization of the extrapleural cavity seemed necessary because of the presence of infection. In practice the operation has been carried out as follows: After stereoscopic roentgen rays of bismuth injections of the cavity have been made to determine the size and position of the cavity the sinus tract is carbolized, encircled by an incision and dissected down to the pleura. Ten to 12 cm. of a single rib are excised and the parietal pleura stripped away from the chest wall well beyond the limits of the cavity. With as careful an observance of aseptic technic as possible the parietal pleura is incised, the granulation tissue removed from the cavity and its entire inner surface carbolized. The parietal pleura is then excised. The wound is closed except for an opening large enough to permit the two tubes of our Dakin irrigating apparatus. This procedure has been carried out in 4 cases; in 2 cases as a primary procedure and in 2 cases as a secondary operation following the failure of other methods. In all the cases the method was

successful. The cavities varied in size from 100 to 200 c.c. in volume, were elliptical rather than spherical in shape, were of long standing (one to four years) and were surrounded by a markedly thickened pleura. Sterilization of the cavities and closure of the sinus tracts were effected in 1 case in thirteen

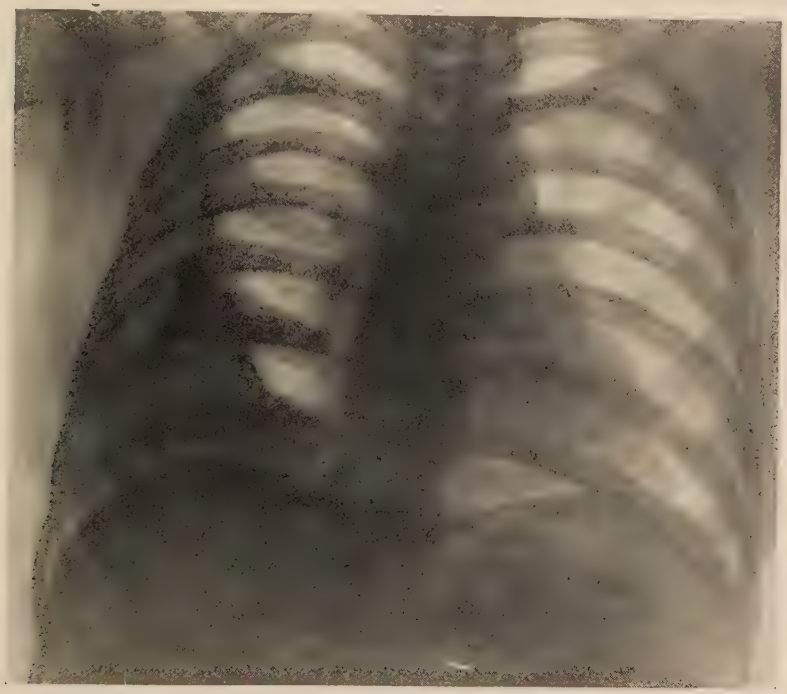

FIG. 3.—A chronic empyemic cavity treated by mobilization and excision of the parietal pleura, followed by irrigations of the extrapleural cavity with Dakin's solution. (See text, Method 3.) The small dense shadow is the remains of the bismuth paste injected to determine the form and position of the cavity. (*X*-ray taken before operation.)

days, in 1 case in twenty-one days, in 1 case in forty days and in 1 case in sixty-seven days. We have examined personally or have letters from all these cases. In none have the wounds reopened. The patients have now been well for from six months to one and half years. We have a series of pre- and postopera-

tive roentgen rays in 3 of the cases. Although we cannot state accurately how soon after sterilization the cavities were obliterated, we know that all were obliterated rather promptly—almost surely within a month. In the later roentgen rays of these cases the shadows indicating the thickened pleura have almost entirely disappeared.

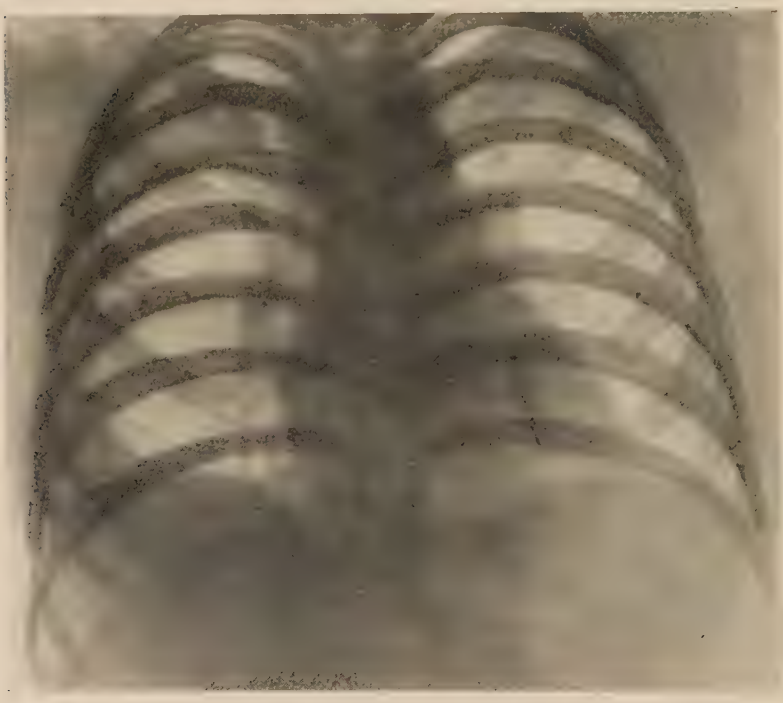

FIG. 4.—The end-result in the case shown in Fig. 3. (*X*-ray taken ten months after operation.) The cavity is obliterated. There is only a slight haziness to indicate what was found at operation to be a greatly thickened pleura.

4. PRELIMINARY CORRECTION OF THE SINUS TRACT AND CAVITY IF NECESSARY. STERILIZATION OF THE CAVITY WITH DAKIN'S SOLUTION. SECONDARY SUTURE OR SPONTANEOUS CLOSURE OF THE SINUS TRACT. In the cases in which bismuth

roentgen rays showed a sinus leading directly into a single cavity the tubes of our irrigating apparatus were introduced into the cavity without preliminary operative procedures and the sterilization of the cavity attempted. In the cases in which a long or tortuous tract led into the cavity so that mechanical conditions for subsequent sterilization were unsatisfactory a preliminary operation, with excision of the sinus tract or the establishment of a new opening into the cavity at a point of election, was performed. This method has been carried out in 10 cases. In 1 case no preliminary operation was necessary. In 1 case the cavity was opened widely and the large open wound—the bottom of which was formed by the cavity—subsequently closed by secondary suture. In 8 cases the sinus was excised and either enlarged or closed and a new sinus established. In 2 of these 8 cases rather extensive rib resections (in 1 case segments of two ribs and in 1 case of four ribs) were performed. In these cases in which the cavities were under the scapula the rib resections may have hastened the obliteration of the cavities, but could not have influenced the sterilization of the cavities. The results in the 10 cases are as follows: One case insisted on going home three weeks after irrigations of the cavity were begun. At the time of his discharge the bacterial count was very low but the cavity was neither sterile nor closed. This patient has not been heard from. (Kendricks.) One case (the only instance in this series of tuberculous empyema secondarily infected with a hemolytic streptococcus) was discharged two and a half months after the beginning of the Dakin solution irrigations. The bacterial count was rapidly reduced from infinity to 1 or 2 organisms per microscopic field; but for a month we were unable to do better than this and feared to close the sinus because of the presence of a hemolytic streptococcus. A letter from this patient states that his general health is good but that the sinus is still draining. In 1 case the cavity was bacteriologically sterile and closed in one month after beginning Dakin irrigations, but reopened two weeks later. A secondary operation with stripping and excision of the parietal

pleura cured this patient. In one case sterilization and closure were accomplished in three weeks. The wound, however, reopened and discharged, then closed spontaneously and has remained closed for one and half years. In the remaining 6 cases sterilization and closure were accomplished in fourteen days, twenty days, twenty-three days, thirty days, sixty days

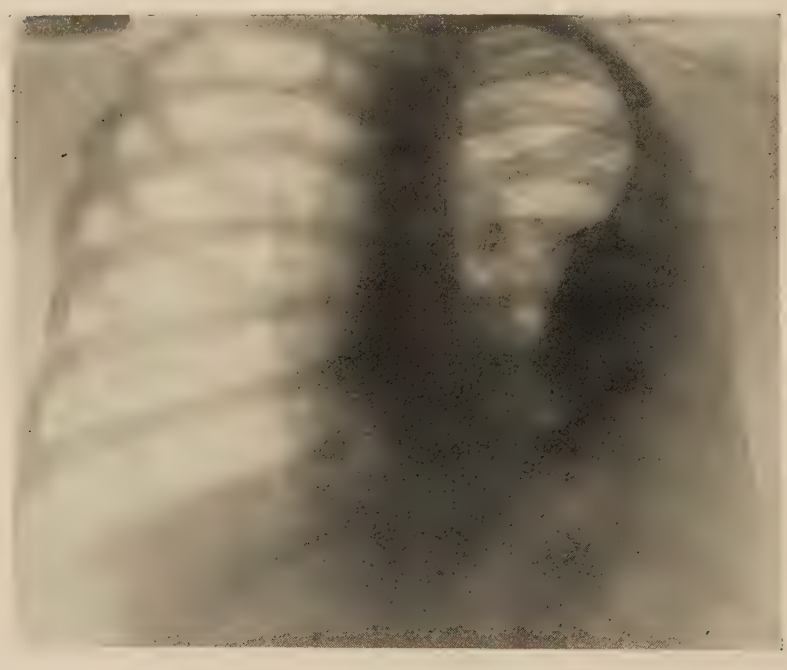

FIG. 5.—A chronic empyemic cavity treated simply by irrigations with Dakin's solution. (See text, Method 4.)

and seventy days. By personal examinations or letter we know that in none of these cases has the wound reopened and that they have been well for from seven months to three years. Exclusive of the three cases in which sterilization was not accomplished we know from roentgen-ray studies that the cavities were not obliterated at the time of closure of the sinus tracts; in other words, that we closed or allowed to close a

sinus over an intrapleural cavity. We know from subsequent roentgen-ray examinations of 4 patients who have since returned for examination that the cavities—even though surrounded by a markedly thickened pleura—have spontaneously been obliterated and that the thickening of the pleura has largely disappeared. Our total results, therefore, in these 10 cases have been 6 com-

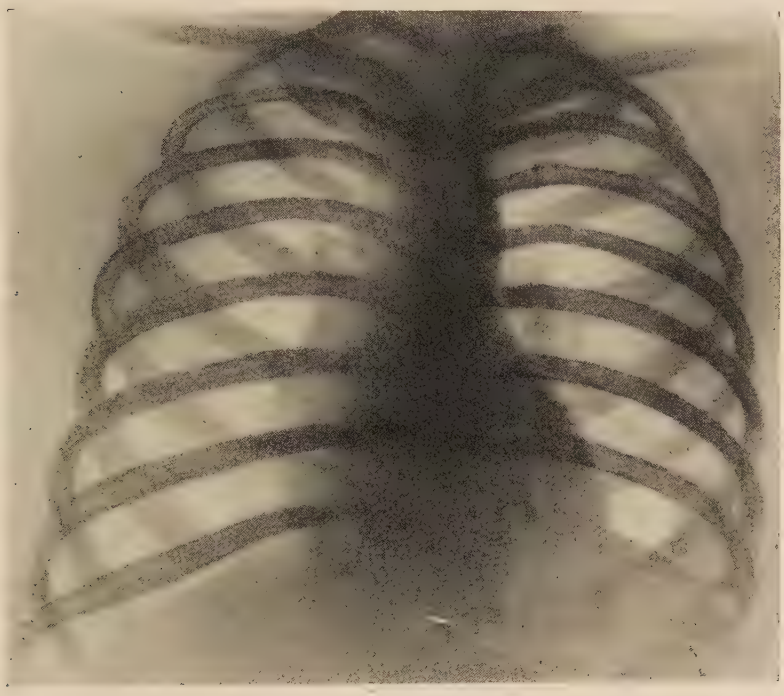

FIG. 6.—The result in the case shown in Fig. 5. (*X*-ray taken twelve months after beginning treatment.) The cavity is obliterated. The shadow cast by the thickened pleura has practically entirely disappeared.

plete successes and 4 failures. In 1 of the 4 failures the sinus, which reopened two weeks after its primary closure, closed spontaneously and has since remained closed. In another case included as a failure in this group a subsequent operation resulted in the closure of the sinus and a complete cure. In only 2

cases, therefore, did we fail in the closure of the cavities before the patients left the hospital.

5. Immediate Sterilization of Chronic Empyema Cavities with Pure Carbolic Acid. Closure without Drainage. Our experience with the progressive sterilization of empyema cavities led us to attempt the immediate sterilization and complete closure of chronic empyema cavities at the time of operation. This procedure has been attempted only in small (up to 200 c.c. in volume) and favorably situated cavities. The operation has been carried out as follows: The sinus tract is carbolized, surrounded by an incision, tied off and recarbolized. With a new set of instruments the sinus tract is followed down to the pleura, care being exercised not to open it. Ten to 12 cm. of a single rib are resected and the parietal pleura stripped from the chest wall beyond the limits of the cavity. With the wound held widely opened with a rib spreader and with the greatest care not to contaminate the field the parietal pleura is incised from one end of the cavity to the other (at the same time excising the sinus tract) and the cavity—previously cleansed by Dakin irrigations—opened widely. Holding up the edges of the incised parietal pleura the granulation tissue lining the cavity is wiped out and then the cavity is carbolized throughout with pure carbolic acid. The excess of acid is wiped out with alcohol and salt sponges. The parietal pleura has been treated in various ways; it has been allowed to simply fall into the cavity; it has been sutured to the visceral pleura so as to bring the two layers of the pleura accurately into apposition, or it has been excised. The extrapleural cavity is wiped dry. The wound is closed without drainage. This operation has been carried out in 3 cases. I have a distinct recollection of 2 other cases operated upon by this method with successful results before I went abroad, but in looking over our hospital records I am unable to find them. In 2 of the 3 cases the wound healed by primary intention and remained healed. In 1 case the wound healed per primum but on the fifth day after operation an area of induration appeared in the subcutaneous tissues

along the healed incision. Before the incision was opened cultures from the fluid in the cavity showed that the cavity was sterile. With the opening of the incision the cavity became secondarily infected but was sterilized with Dakin's solution and later closed by secondary suture. By personal examination we know the end-results in these 3 cases. In the 2 cases in

FIG. 7.—A chronic empyemic cavity treated by immediate sterilization and closure without drainage. (See text, Method 5.)

which the wounds healed by primary intention the wounds have remained healed and the patients are well three and half years and four years after operation. In the case which developed a secondary infection the wound has remained healed since the secondary closure of the cavity. We know the fate of the cavities in these 3 cases. In 1 case the cavity after

operation became filled with blood, as proved by aspiration, but later was completely obliterated; in 1 case, if we properly interpret the clear space in the roentgen rays, the cavity did not fill with fluid but remained an air space until its obliteration; in 1 the cavity remained filled with a blood-tinged serous fluid until its obliteration.

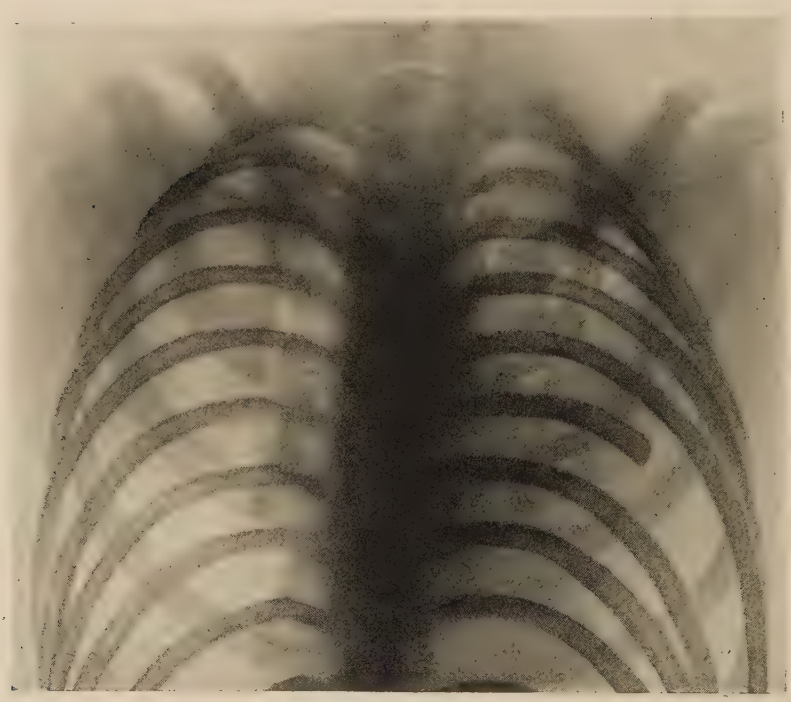

FIG. 8.—The end-result in the case shown in Fig. 7. (*X*-ray taken one month after operation.) The defect in the rib shows the extent of the rib resection in this case. The cavity is obliterated. The shadow cast by the thickened pleura has entirely disappeared.

To summarize our observations, we may say that 24 patients with long-standing chronic empyema have been treated by one or another—in a few instances by two—of the methods described. There has been no operative mortality. Through the efforts of Miss Spicer, my secretary, and Miss McEvoy, my social

service aide, I have, with one exception, either examined personally or have received letters from all these patients. Twenty patients were discharged from the hospital with their wounds healed. In 19 of these patients the wounds have remained healed and 18 patients are well from seven months to four years after their discharge from the hospital. One patient died

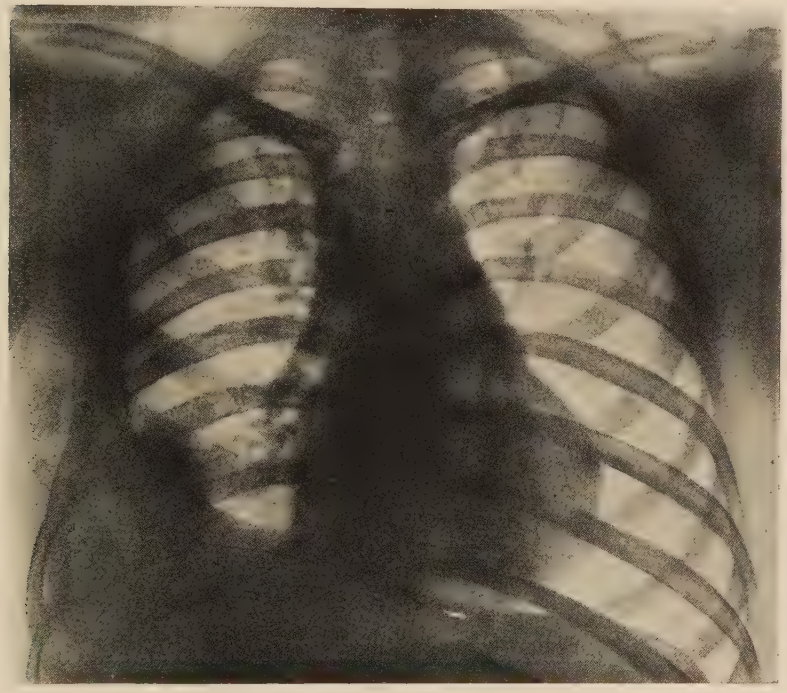

FIG. 9.—A chronic empyemic cavity treated by immediate sterilization and closure without drainage. (See text, Method 5.)

of pulmonary tuberculosis two years after his discharge from the hospital; in 1 patient the sterile cavity became reinfected by the rupture into it of a tuberculous focus, and death occurred, following an extensive thoracoplastic operation, three years after the sterilization of the cavity. Four patients were discharged from the hospital with the cavities infected and draining. Two

of these patients are in tuberculosis sanitoria with their cavities still draining; 1 patient has since died of pulmonary tuberculosis. One patient discharged against our wishes three weeks after his admission has not been heard from. With the exception of this last patient, whom undoubtedly we could have cured had

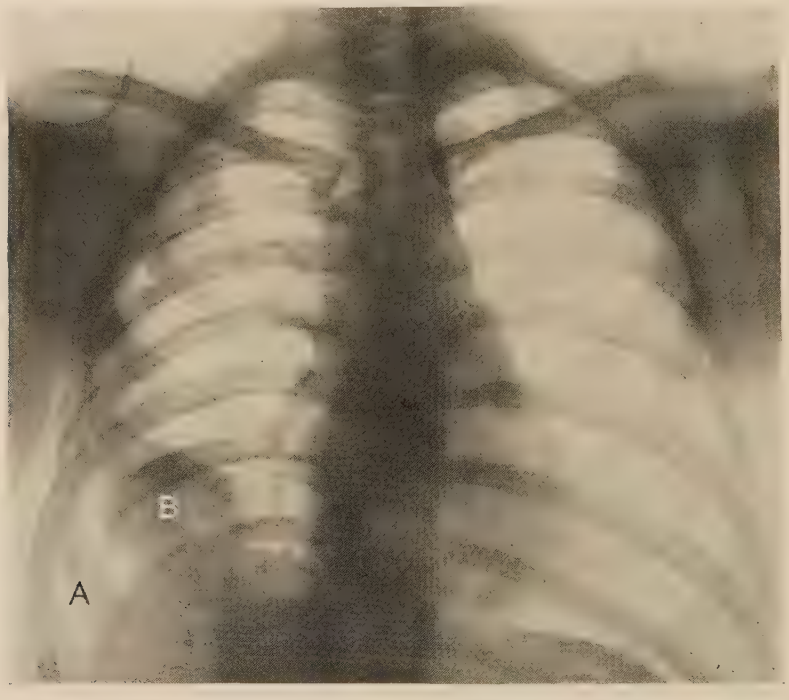

FIG. 10.—The result in the case shown in Fig. 9, three weeks after operation. The extrapleural cavity is not yet obliterated but is represented by the clear space, *A*. An area of thickened pleura is shown at *B*.

he remained in the hospital, our only failures occurred in patients with active pulmonary tuberculosis in whom a tuberculous empyema followed prolonged artificial pneumothorax treatment.

Not less interesting than the facts that empyema cavities of long-standing can be sterilized and that subsequent to sterilization and closure of the sinus tracts they are spontaneously

obliterated—and by expansion of the lung rather than by retraction of the thorax—is the fact that eventually there is almost a complete restoration to the normal. The late roentgen rays in our series show that the markedly thickened pleura, certified at operation, practically entirely disappears. In 4 cases we have indeed aided in this restoration to the normal by excising the thickened parietal pleura; but in cases in which such excision has not been done the thickened pleura has nevertheless disappeared. (See lantern slides and photographs.)

In conclusion, we may add some observations on the complications following the irrigation of empyema cavities with Dakin's solution. *Hemorrhage* from the cavity has occurred in 3 cases in the above series. It was not excessive nor alarming and spontaneously ceased as soon as the irrigations were discontinued. It invariably occurred late in the process of sterilization—at a time when the organism count was 5 per microscopic field or lower. It has not yet, in our experience, been a serious factor in the treatment of empyema cavities by Dakin irrigations. In 2 cases the irrigations were discontinued for from twenty-four to forty-eight hours, then recommenced and without a repetition of the bleeding. In 1 case recurring slight hemorrhages caused us to discontinue the irrigations and a single injection of bismuth paste was followed by closure of the sinus. *Bronchial fistulæ* have developed in the course of the irrigations with Dakin's solution in 2 cases. In 1 case there was a history of a previous bronchial fistula which had apparently been closed for three months. In the other case there was no history to indicate that a bronchial fistula had previously been present. This complication has in our experience prevented, for a time at least, the continuation of the irrigations because of paroxysms of coughing, the taste of the solution and the fear of strangulation. In the 2 cases in which bronchial fistulæ have occurred injections of bismuth paste have been substituted for the irrigations.

DISCUSSION OF PAPERS ON ACUTE AND CHRONIC EMPYEMA

Dr. John H. Gibbon, Philadelphia:

There lived in a certain city thirty years ago a surgeon who was fond of performing his own operation for hernia. Kocher's operation was introduced and he said at a particular clinic he would do the Kocher operation: the second day after operation the wound was full of pus, peritonitis had developed, and the operator's attention being called to the patient's condition, he said "well, that's one on Kocher." I think this anecdote too often illustrates the attitude of many of us toward new methods, and our opposition is due either to the fact that we did not discover and introduce them ourselves, or to the fact that someone else did. I say this because we have heard so much of the difficulties and failures of the Carrel-Dakin methods of sterilization of wounds. If by this method we can sterilize an old infected pleural cavity we should be able to sterilize anything. I want to report two cases which show that the method is not a complicated one. The first case is that of a man with an empyema operated on in September 1918; he had a persistent sinus. That man came into the hospital eight months later running a temperature, draining intermittently, showing loss of weight. He was put to bed and no operation was done except that this tract was slightly dilated and a Carrel tube introduced followed by intermittent irrigation. Two or three weeks later he went home and there the treatment was carried out faithfully; he reported once a week. This treatment was started in April and on August 22 the wound had healed, closing itself when it was sterile, and it has remained closed ever since. He has gained thirty pounds. The second case is of a man who represents one of the most difficult types. He had an empyema necessitatis in May, 1918. The abscess presented below the nipple in the sixth interspace and was opened and continued to drain intermittently. When the sinus was closed he expectorated pus; when it drained he expectorated no pus. He lost weight until he became a skeleton, and was then considered tuberculous. The *x*-ray showed an enormous irregular cavity going up as high as the second rib and draining below the nipple. When bismuth and oil were introduced to show the cavity he spat up this material for two days. He was brought into the hospital and on March 29, 1919, I resected the sixth rib, dilated the sinus, evacuated the pus and introduced a tube. The treatment was started ten months after the sinus had opened and he was kept in the hospital for several weeks.

This man was a chemist who lived on a farm in New Jersey and his wife who carried out the irrigation very satisfactorily. He reported once a week. His wound was sterilized and closed in August; then he filled up again and was opened and resterilized. The wound closed in September and has remained so since. He has gained 35 pounds and is now in perfect health. These cases show that this method is not too difficult even in complicated cases. In this case I did not start the Dakin irrigation until the drainage had allowed the bronchial fistula to close.

Dr. E. K. Dunham, New York City (by invitation):

I have been asked to show these charts which offer a sketchy survey of the earlier and critical stage in the course of the empyemata in two or three of the military cantonments in this country.

Three of the charts give a graphic presentation of the more important findings in 149 autopsies, showing the intrathoracic and the extrathoracic infections associated with the single, unilateral empyema that existed in all. Of the intrathoracic infections, it will be noted that pericarditis, chiefly suppurative, was present in 65 instances, bilateral pneumonia in 59, empyema or pleurisy with effusion on the opposite side in 49, pulmonary abscess or gangrene in 22, and mediastinal abscess in 17. Among the extrathoracic infections peritonitis occurred in 22 cases, erysipelas in 6, otitis media in 4, arthritis or abscess in soft parts in 19.

Forty-five of these cases died during the first three days in hospital, 55 from the 4th to the 14th, and 49 from the 15th to the 114th day. There is no very striking difference in these three groups in respect to the intrathoracic infections, but those in extrathoracic situations are less prominent in the first group than in those cases that survived for a longer period of time. There are only 15 cases in which autopsy failed to reveal one or more associated infection of a serious character, a trifle over 10 per cent. of the whole number.

It appears to me that these charts very clearly emphasize the importance in caring for such cases of not focussing the mind too strongly upon an obvious, unilateral empyema. This single condition recedes into the background of the true picture and loses in significance when compared with the gravity of these coincident infections. There is danger in reducing, even in slight degree, the functional capacity of either lung and septic absorption from a single pleural cavity is of relatively slight importance in the face of septic processes beyond surgical reach. It is on these grounds that I have ventured to call this period of multiple infection the critical stage in the course of the

disease. Operative interference should be undertaken only after a careful survey of all the conditions existing or likely to arise and, as far as possible, should not in itself involve a possibly irrevocable complication in the further progress of the case.

The fourth chart I am privileged to present illustrates the relative gravity of early costectomy in the critically ill. It is essentially a corollary to the first three charts.

The remaining charts set forth the relative gravity of infection with the hemolytic streptococcus as compared with the pneumococcus as affecting mortality or prolonging the period of convalescence. The mortality in the former was 68.5 per cent., in the latter 42.4 per cent. The longest stay in hospital of any pneumococcus case was 144 days, of a streptococcus case 515.

It must be understood that these figures are based on the experience in only two or three base hospitals in this country and will certainly be considerably modified when a larger number of cases come to analysis. These, however, suffice to call attention to pathological conditions of clinical importance in non-traumatic empyemata of the types which occurred in the military forces within the United States.

Dr. George W. Crile, Cleveland:

While in France I had the privilege of seeing Dr. Tuffier do some of these operations, and also of seeing many of his cases and an exhibition of his methods, and since that time I have followed his methods.

The American surgeons who were in France will agree with me that nowhere did we find so much help as in Professor Tuffier's knowledge of both military and civilian surgery. Whenever we turned to him he always gave freely of his time, knowledge and experience. In fact he gave his time to us as if he had nothing to do but to give us the advantage of what he and his colleagues had learned regarding the treatment of soldiers. Every one will agree that our American surgeons in France, and also our American soldiers, owe a great debt of gratitude to Professor Tuffier.

Dr. Alexis V. Moschcowitz, New York City:

There is continually a discussion as to what constitutes a chronic empyema; in the light of my present knowledge I would look upon a chronic empyema as one which cannot be sterilized by the Carrel-Dakin method. When confronted with one it is up to the surgeon to discover the reasons of the inability to sterilize the cavity, to remove these reasons, and thus to convert it into a sterilizable empyema, whereupon prompt healing is the usual rule.

According to the best statistics the mortality of empyema is approximately 20 per cent.; in some of the military camps it rose even to 80 per cent. In spite of these figures I am of the opinion that empyema as such has no mortality. When a case of empyema dies it is not from the empyema, nor from any of the complications of an empyema. It has been my experience that the cause of death is usually the condition which caused the empyema. I have personally operated upon a large number of both primary and secondary empyema, and with the exception of one case no patient died; the cause of death in this exceptional case was that of multiple pulmonary abscesses.

I cannot quite agree with those who advise an operative closure after the cavity has been sterilized. I have found that when the cavity is sterile the discontinuation of all treatment will be followed by a prompt closure of the external incision. This being the case, I see no particular advantage to be derived from the operative closure.

Dr. Joseph A. Blake, New York City:

It seems to me from what we have heard and what we will all realize when we think of it that the pleura is not peculiar in regard to its reaction to infection. We have thought that the pleura and the joints were. We have learned that the way to treat joints is not to leave drainage tubes in, and I think the same principle can be applied in the early cases of empyema. The fact that in these longstanding cases the cavity can be obliterated by a simple closure of the outer wounds may often lead to successful treatment in the early cases. In several I have simply left the drainage tubes in for from twenty-four to thirty-six hours, then removed them, and the entire cavity becomes obliterated and heals within a few days. These cases must be selected with judgment just as we treat cases of peritonitis, some we drain and some we think it wise not to drain. The same thing holds true of the pleura. In many cases of empyema with fibrinous and purulent exudate, a rapid resection and cleansing of the cavity, then the putting in of tubes for twenty-four hours will result in recovery. As a rule, there is no virulent infection in such cases. I mention this to bring out the fact that no one method of treatment must guide us, but they should be used with discretion and judgment.

Dr. John L. Yates, Milwaukee:

Different methods of treating empyema have been advocated and properly urged as especially adapted to the relief of one or another particular type of the disease since no method is applicable to all varieties. Dr. Dunham has indicated very clearly that there are

physiological principles which determine methods and to which inadequate attention has been given. His charts furnish irrefutable evidence for the contention I wish to make: it is the prevention rather than the treatment of empyema which gives the most desirable results.

The preservation of intrathoracic function is of the greatest importance because with restricted powers of respiratory compensation there is a proportionate curtailment of activity. Normal respiration is dependent upon normal mobility of the thoracic parietes, undiminished intrapleural negative pressure, and unimpaired pulmonary elasticity.

The pleural defensive power lies chiefly in the visceral layer because of its richer blood supply. This blood supply is, however, dependent upon a certain degree of active function and unless this is maintained the defense weakens. Illustrating the interdependence of respiration and pulmonary circulation, I would like to call your attention to a fact not generally recognized. It is usually accepted that air pressure is the only factor in producing pulmonary inflation whereas the distribution of capillaries around air cells is such that it functions as a sort of erectile tissue and is capable of producing a small degree of inflation.

The necessity of maintaining or reëstablishing the contact between the pleural surfaces is twofold, first to assure respiration and through respiration to provide an optimum circulation and the greatest powers of defense.

Dr. A. L. Lockwood, Rochester, Minnesota (by invitation):

I believe with Professor Tuffier that exactly as with certain closed types of gunshot wounds, acute empyemata should be considered as medical conditions at first, and treated by repeated aspiration; but under the close eye of the surgeon, physician, and radiographer. That is, chests when acute should be aspirated every twenty-four hours or oftener, if effusion is causing distress. This aspiration should be done carefully, with the same aseptic precautions as in a major operation. If treated in this way, a large majority, whether streptococcal or pneumococcal originally, will need no further operative procedure.

However, there is a type, both pneumococcal and streptococcal, which will require more radical measures. Of those which require an open operation, there is a certain and by no means small percentage which can be opened by intercostal incision after aspiration has failed, thoroughly cleaned, and closed at once, without the immediate necessity of sterilization. It was found in some hundreds of cases that all but about 22 per cent. could be dealt with in this way.

The cleansing of the thoracic cavity *cannot* be done by irrigating. I have shown that an irrigating can may be placed twenty feet above the table, fluid passed into the thorax at autopsy performed almost at once after death, and the flaky exudate which forms upon the visceral and parietal pleura and contains the infective organisms will not be disturbed at all. The visceral and parietal pleura should be swabbed carefully. Resection of a rib is rarely necessary, except in older subjects with emphysematous chests, where the elasticity of the thoracic wall does not allow a sufficient spreading of the intercostal space.

Professor Tuffier has spoken of a type of empyema which should not be operated upon, and I feel that a great many of the deaths in the recent influenza epidemics following operation were of this type, cases which should have been considered as medical and not as surgical. Such a patient has a variable collection of fluid, a rapid pulse, intermittent temperature, dyspnea, and *cyanosis*. In such a case there is pulmonary involvement, and the patient will not be benefited by any surgical measures other than aspiration. In all seriously ill cases pending operation the patient should be carefully gone over by the physician and the radiographer as well as by the surgeon, to make quite sure that there is not a pneumonic condition in the opposite lung.

In the small percentage of cases of empyema where the patient is acutely ill, due to the toxicity of the empyema, in which operation occasionally is necessary after aspiration has failed, if the lung is not adherent to the chest wall, the incision should be closed at operation almost regardless of the nature of the type of organism. But if the pulse tends to go up rapidly within twenty-four or thirty-six hours after operation, and the patient's condition is correspondingly worse, then it is necessary to simply open the original incision and Carrel it.

It seems to me that in the majority of cases where the chest has drained for more than six or eight weeks, the condition has become potentially chronic, and following a course of Carrel treatment an early attempt should be made to close the chest: and I am certain that a great number can be closed earlier than is generally considered to be possible. I feel that in our anxiety to maintain a low mortality rate, we sometimes overlook the morbidity, and that the social element as well as the scientific should be considered in determining the best method of dealing with these chronic cases. Recently I have seen a patient who had been draining for two and a half years. He sold his farm and has been all over America seeking treatment. He has used up all his wealth in the hope of finding help. We outlined a small cavity connected with a chronic fistula, running upward from the eighth space in the midaxillary line. The fistula was excised, the

cavity exposed, carefully cauterized, decorticated, a muscle flap sutured to obliterate the cavity, and the wound healed by first intention. The patient should remain well. In the majority of the chronic cases that we see now, no logical attempt has been made to expose the cavity or to determine the etiological factor in maintaining chronicity of the condition.

At present it is difficult to say how large a cavity can be closed with the skin or muscle graft; but I feel that either by grafting or by partial decortication, the great majority of these chronic fistulæ and cavities can be closed, and I think that an early attempt should be made to close all of these so-called chronic cases.

Dr. Joseph Ransohoff, Cincinnati:

During the epidemic of influenza I had 50 cases of acute empyema, of which 3 were double. There were over 3000 cases of influenza in Cincinnati and 625 died of empyema. Of these only 50 came to surgical operation and of these, all of whom I saw, 6 per cent. recovered and 3 were double. Fortunately these double cases were not synchronously double, and they all got well. My method of drainage is extremely simple: it is a small cannula introduced through an opening, usually after rib resection under local anesthesia. Pus comes out slowly and none of the air is sucked into the cavity during this time. I am suggesting this easy method of treatment for those men who are not satisfied with the way in which they are treating their cases at present. I will state that the excellent results we had are the best published so far as I can learn. Dr. Dunham's excellent chart has put the matter graphically, that the danger lies in operating too early. We are just getting away from that often quoted statement, *ubi pus ubi incisio.* There is another point I would bring out: I have made the contribution of dissection of the lung to the treatment of chronic empyema. One of the speakers has mentioned the simplicity of opening widely and exploring: I hope that the important contribution of Professor Tuffier to the treatment of chronic empyema will be borne out by further experience, that is, his suggestion to sterilize the empyema, close it up and allow it to take care of itself.

In his concluding remarks I wish Professor Tuffier would tell us if he has seen empyemata in which the entire lung is affected and in which there is an air space from the diaphragm to the cervical recesses of the pleura above the clavicle. We do not see many such cases now, only one once in a while, but when we do so see one, if we do one of these major operations for the cure of chronic empyema we will jeopardize the life of our patient.

Dr. Howard Lilienthal, New York:

In a series of 100 non-selected cases reported by me in the *Transactions* of 1917, the average time of healing for the 77 patients who recovered was 37 days.

Dr. Carl Beck, Chicago (by invitation):

In looking over a long series of cases of chronic empyema referred to us for bismuth paste treatment, I can find but three reasons for permanent suppuration.

First, tuberculosis, second, a bronchial fistula following gangrene of the lung and pyopneumothorax, and third, as mentioned by Tuffier, a too large cavity, offering a mechanical obstacle to healing with an atrophy of the lung which cannot expand any more.

The first two conditions are absolutely incurable and remain so by any method; but the last may be cured by a plastic method, removing the chest wall and spreading over the remaining pleura a pedicled flap of skin.

Dr. Theodore Tuffier:

You have done me the honor of inquiring if I have encountered any cases of total complete empyema without adhesions. I cannot positively affirm that I have, but of this I am sure, that I have evacuated purulent collections of from two to three liters, as I have indicated in my paper, and have been able to sterilize the cavities and cure the patients. But the truth is that we have generally to do with limited cavities, and I am convinced that with the methods of treatment of acute purulent pleurisy which we now possess, we will not be troubled in the future with the chronic cavities of the same type.

I desire to congratulate my colleague (Dr. Heuer) on his suggested method of mobilization and resection of the parietal layer of the pleura, which is an interesting application of the method of production of extrapleural pneumothorax which I described some twenty years ago. I have practised on several occasions the liberation of the pulmonary layer of the pleura, with or without resection of the parietal layer; I have resected both layers when compelled to do so, and I have insisted on the important point that it is at the boundaries of the cavity that one finds the thickest adhesions, which limit pulmonary expansion, and which must be gotten rid of, before the cavity can be abolished. There is certainly a field here for the application of the method as he has indicated and practised it.

Dr. Walton Martin, New York City:

My effort was to prove that chronic empyema should not occur. I beg to suggest that Dr. Ransohoff did an injustice to Hippocrates. Hippocrates was said to have advised that no operation should be done for empyema before the fifteenth day.

RESTORATION OF FUNCTION OF FACIAL NERVE FIVE YEARS AFTER ANASTOMOSIS WITH HYPOGLOSSAL

SPONTANEOUS RUPTURE OF THE DEEP EPIGASTRIC ARTERY

By HERBERT A. BRUCE, M.D.
TORONTO, CANADA

Restoration of Function of Facial Nerve Five Years after Anastomosis with Hypoglossal

Miss G. C., now thirty-three years of age, had suffered from left facial palsy for ten years, following an operation for mastoid disease, at which the facial nerve had been severed. There was no response to electrical stimulation of the left facial muscles.

An anastomosis between the facial nerve and the hypoglossal was made by me on June 21, 1915, at the Wellesley Hospital. The incision from the tip of the mastoid downward paralleled the anterior border of the sternomastoid for a distance of four inches. The sternomastoid muscle was retracted backward, exposing the parotid gland, surrounded by a dense mass of fibrous tissue which had evidently resulted from the previous mastoid operation. The occipital artery was exposed but the facial nerve could not be found at the posterior aspect of the parotid gland. The anterior portion of the gland was then exposed and the branches of the facial nerve found. On dissecting these backward through the gland the nerve was found to

have been divided close to the skull. The left hypoglossal nerve was isolated and divided at its lowest point. The proximal end of the hypoglossal and the distal end of the facial were brought together by suturing their sheaths with chromic gut and fine silk. The anastomosis was surrounded by green protective tissue the end of which was brought out through the wound and removed in a week's time. Healing took place *per primam.*

It was four years and a half before any visible change took place, when she found for the first time that she was able to move the left upper eyelid and eyebrow. A little later movement returned, to a slight extent, in the lower eyelid, the side of the nose and mouth. These movements have steadily increased in extent, until now, after a period of nearly five years since the anastomosis, she has almost complete restoration of function of all the muscles supplied by the left facial nerve.

The left side of the tongue has atrophied until it is very little more than half the size of the right. All the movements of the tongue, however, can be carried out, with perhaps some little difficulty on the left side. When protruded it is deflected to the left. Although it feels stiff there is no impairment of sensation or taste.

Spontaneous Rupture of the Deep Epigastric Artery

Mrs. A. M., aged thirty-nine years, who had had five children and was seven months pregnant, was suddenly taken with severe pain in the right side of the abdomen. Up to that moment she had been in good health, except for a cough, the strain of which, she thought, had caused the pain.

When her physician arrived he found a painful, fluctuating tumor about the size of an orange, a short distance above Poupart's ligament and apparently in the right side of the uterus. The character of the tumor suggested to him concealed accidental hæmorrhage within the uterus. A consultation was held and the patient moved to the Wellesley Hospital. Upon arrival in the

hospital she was profoundly shocked, with a rapid, thready pulse, cold, clammy skin and subnormal temperature.

When an operation was undertaken three hours after the first symptom the swelling had increased to the size of a large grapefruit, and could be readily seen, apparently in connection with the right side of the uterus. An incision through the sheath of the right rectus was attended by the escape of a considerable quantity of fresh and coagulated blood. After removing the large collection of clots it was difficult to find the bleeding-point on account of the continued free hæmorrhage.

On exploring the posterior sheath the spurting deep epigastric artery was found at the upper part of Hesselbach's triangle and was ligated. The blood had stripped up the parietal peritoneum as far around as the flank and had separated out many of the fibers of the rectus muscle, which were completely torn across in places. Two days later she was delivered of a female child. The patient made an uninterrupted recovery.

Chronic nephritis was not present, but she was suffering from the albuminuria of pregnancy, which cleared up a few weeks after labor. Her blood-pressure was normal and there was no arterio-sclerosis.

In the *Annals of Surgery*, February, 1916, Dr. John Speese reported a case of spontaneous rupture of the deep epigastric artery. His patient was sixty-two years of age and was admitted to the hospital with a diagnosis of intestinal obstruction. Ten hours before admission she was suddenly taken with severe pain in the abdomen, followed by a swelling below the umbilicus. At operation the deep, spurting epigastric artery was ligated. She stated that it did not follow a blow or strain.

Dr. Floyd Keene also quoted a case in Dr. Clark's service at the University Hospital following hysterectomy. Vomiting had caused symptoms of internal hæmorrhage, but operation disclosed an extraperitoneal blood-clot, due to hemorrhage from the deep epigastric artery.

AMPUTATION NEUROMAS: THEIR DEVELOPMENT AND PREVENTION

By G. CARL HUBER, M.D.
ANN ARBOR, MICH.

AND

DEAN LEWIS, M.D.
CHICAGO, ILL.

Odier at the beginning of the 19th century first described the enlargements or swellings which develop upon the distal end of a proximal segment of a peripheral nerve after partial or complete division. He spoke of these as nerve tumors. Since that time these enlargements, or neuromas, have been frequently studied. Interest in them has often been stimulated by war, for the number of painful stumps following amputations necessitated by mutilating wounds or infections have made a study of neuromas, with a view of determining the factors concerned in neuroma formation and the cause of spontaneous pain after they have developed, imperative.

The histological descriptions of neuromas differ widely. The variations are easily explained, for when the earlier histological examinations were made, histological methods were not refined and specific stains were not employed. With the introduction of the silver method which permits of clear differentiation of the neuraxes the descriptions have become more uniform. It is possible to determine now what rôle the different tissues entering the formation of the nerve play in the development of the neuroma.

Scar tissue has been considered by many as the determining

factor in neuroma formation. Senn, in an article published in the *Yale Medical Journal* in 1897, states that it is well known that amputation neuromas will only develop in connection with scar tissue and the irritation incident to the condition producing it and that every neuroma will be imbedded in more or less of scar tissue. It is more than probable that the cut ends of the nerve fibers become attached to the scar tissue which acts the part of a foreign substance and excites the active and abnormal proliferation upon which depends the formation of the neuroma. Senn quotes from an article published by an assistant of Nicoladoni in substantiation of his views, as follows: "The numerical increase in nerve fibers is apparent and not real for the increase is due to the formation of loops growing out of the elongation of preëxisting fibers. With proliferation or growth of these fibers the interstitial connective tissue proliferates under the same influence, the resulting tissue constituting histologically a true neurofibroma."

The importance of scar tissue as a factor in the causation of neuromas has been, as already stated, emphasized by many. The true amputation neuroma forms only on the distal end of the proximal segment of a divided nerve. The occurrence of these bulbous enlargements only on the distal end of the proximal segment of a peripheral nerve, and the fact that they are peculiar to nerves suggests that there are certain changes occurring during nerve repair which, when it does not pursue its regular course, ends in the formation of these bulbous enlargements. It will be shown by experiments which will be discussed later that neuromas develop upon nerves in the absence of scar tissue, or, when it is reduced to a minimum, and in wounds in which healing *per primam* has occurred.

It will not be necessary to review at length the different opinions which have been expressed concerning the histology of neuromas and their significance. It will be interesting to note, however, a few of the opinions.

Langstaff found in neuromas no evidence of the normal structure of a nerve. Probst and Smith regarded the neuroma as

composed of fibrous tissue without any nerve elements, while Legoust and Guerin thought the simple neuroma was caused by a hypertrophy of the connective-tissue elements of the nerve.

Chauvel made microscopic examinations of thirty-two neuromas. He found nerve fibers in these. The fibers increased in number from the periphery to the central part of the bulbous enlargement. He also found nerve fibers passing beyond the enlargement to end in the connective tissue lying beyond the cut end of the nerve. He believed that the neuroma was caused by the growth of the endoneurium and perineurium, and that although nerve fibers were found passing through the enlargement, that they did not undergo any change.

Virchow, in 1858, described the neuroma as consisting of a thick network of axis-cylinders between which were scattered small amounts of connective tissue. He found the nerve fibers arranged in bundles or fasciculi of varying but considerable size. These were surrounded by perineurium which separated them sharply from one another.

Kölliker believed that the neuromas which develop in clean wounds and in wounds in which there are no foreign bodies are new growths which are composed almost entirely of nerve tissue. Another group which develop in infected amputation wounds he regarded as inflammatory in character and as an expression of regenerative energy. More or less newly formed fibers are, according to him, always found in these enlargements.

Gottsacker thought that the neuroma developed as the result of hyperplasia of the elements entering into the formation of the nerve. The enlargement forms not as the result of the rolling up of nerve fibers but as the direct result of increase in numbers. Some of the neurofibrillæ grow beyond the cut surface of the nerve and form a tangle of nerve filaments in the connective tissue beyond it. The non-medullated fibers in the neuroma are but early stages of the medullated.

Klebs regarded the neuroma as indicative of an attempt to restore normal conditions. He believed that the growth of the neuroma ceased with the development of myelin sheaths, but

that there was a possibility that growth might continue even after the sheaths developed.

Schuh believed that the scar tissue which develops at the end of a nerve after division gives rise to a certain resistance to the growing or regenerating neurofibrillæ which causes them to leave the straight course which they usually pursue to zigzag in all possible directions, some of them turning back upon themselves within their sheaths. The neuroma consists of scar tissue and neurofibrillæ which are irregularly interlaced, with more or less completely formed medullary sheaths. The entire process is to be regarded as an attempt at regeneration which has been modified or thwarted by scar tissue. Some of the neuraxes are turned back upon themselves while others interlace or intertwine in the scar tissue in their attempts to pass through it.

Cruveilhier believed that the bulb formed to protect the nerve end, while Billroth thought that the neuroma represented the tissue growth associated with an attempt of the constituents of the central end of the divided nerve to reach the part of the nerve lying opposite and complete regeneration. Ziegler thought that the neuroma developed as the result of a growth exceeding physiological limits, a useless, tumor-like formation resulting.

Cone has recently drawn attention to the predominance of nerve fibers in neuromas. According to him microscopic examination demonstrates that the homogeneous mass consists of interlacing fasciculi of young nerves, the fasciculi varying from 10 to 50μ in diameter. The fibers making up the small fasciculi are young varicose ones, measuring from 1 to 3μ in diameter. Sometimes larger ones are found among these. When one sees larger fibers running parallel and bound together in bundles they usually belong to the original trunk from which the others spread. As a rule these are found on one side and away from the tip of the bulb. Sometimes, however, these bundles may be found at the very tip, for the trunk not infrequently coils around as a whole before sprouting at the end.

Small interlacing funiculi are the most characteristic feature of the neuroma, but not infrequently single tendrils growing wild in

the surrounding tissues are found. They are varicose, bulbed at the end, branch frequently and course in a spiral manner. The supporting surrounding tissue is, as a rule, cellular, vascular, wavy connective tissue, not loose areolar tissue. It is rather compact, more so than is usually the case with cellular connective tissue. Cone believes that many of the spindle-shaped nuclei are derived from the proliferating sheath of Schwann cells. A large number of nuclei are always found among the fibers. Sometimes they are staff-shaped; sometimes they are fusiform. The shape seems to depend somewhat upon the stage of regeneration. Cone has frequently seen these so numerous that the section resembled that of a leiomyoma.

It can be seen that the opinions which have been expressed concerning the histology of the neuroma vary and that the significance of the neuroma has been variously interpreted.

Suppuration undoubtedly contributes to their formation, as it increases the amount of scar tissue; but even at the present time, when sepsis is relatively uncommon, neuromas form frequently, although many are not associated with spontaneous pain.

REPORT OF EXPERIMENTAL WORK.

The experimental work which is about to be reported had as its first object the determination of the factors which caused neuroma formation and as its second object the prevention of the neuroma.

The operations were performed under strict aseptic precautions and the dissections were made along intermuscular septa to avoid hemorrhage. Thus the two factors, suppuration and hemorrhage, to the consequences of which so much importance has been attached in the causation of neuromas, were eliminated. When the nerve was exposed, the sciatic being used in all cases, it was divided transversely by sharp knife or scissors.

In all cases, even when perfect aseptic healing occurred, a neuroma developed. The neuroma was well formed by the nineteenth day after division. The bulb may vary somewhat

in shape, but all tend to become oval or spherical. If the bulb rests on bone or tendon or some resistant tissue the part of the bulb resting there may be somewhat flattened while the other parts increase in size, the increase in size taking place where there is the least resistance.

One of us (Lewis) has seen one instance in a war wound in which the divided ends of the nerve had been driven into the bone where no neuroma formed and he believes that in this instance the pressure of the surrounding bone prevented bulb formation which occurs with such frequency that it might almost be regarded as normal.

Figs. 1 and 2 represent the appearance of neuromas after longitudinal section. These are symmetrical enlargements. The growth as stated above may, however, not be symmetrical. Asymmetry is usually caused by different pressure relations, the greatest amount of growth occurring in the line of least resistance.

The gross general characteristics of a neuroma are well represented in Figs. 1 and 2. Evidently after a transverse section of a nerve the funiculi retract within the epineurium. Then the epineurium contracts down over the cut end of the nerve but does not completely cover it, for the cut end is covered by a connective tissue cap which becomes continuous on all sides with the epineurium. In Fig. 1 this cap seems to be placed on top of the epineurium. This connective tissue cap occurs quite regularly in neuromas. It indicates apparently the site of a blood clot which forms over the end of the nerve after division. This later becomes transformed into scar tissue by invasion of connective tissue from tissues surrounding the nerve end, from the endoneurium, perineurium and epineurium. This connective or scar-tissue cap does not block completely developing neuraxes for in a number of specimens neuraxes which have penetrated this cap are found in the connective tissue lying beyond the nerve.

In a microscopic examination of the neuroma, the most striking thing is the spirals which were apparently first described by

Perroncito in his experiments dealing with nerve regeneration. These will be described first, for they seem to indicate the factor which is most to be emphasized in neuroma formation.

FIG. 1.—Longitudinal section through typical neuroma, showing relation of epineurium and connective or scar-tissue cap to the end of the nerve. The straight longitudinal neuraxes may be seen in the proximal part of the neuroma just before they reach to scar tissue in the center of the neuroma. Nerve was divided transversely thirty-one days before this specimen was removed.

A high-power representation of a spiral is seen in Fig. 4. The growing neuraxes of the regenerating nerve is blocked by connec-

FIG. 2.—Typical neuroma, presenting pyramidal-shaped cap and relation of epineurium. Parallel bundles of neuraxes can be seen passing relatively low down in the outer part of the neuroma.

tive or scar tissue. They are unable to penetrate this and they then spiral back within their own sheath, using the original

neuraxis of the sheath as the axis around which they spiral. Developing from the branching neuraxis of this spiral are several end disks. These disks merely represent exaggerated forms of the smaller end-bulbs which are observed in nerves undergoing normal regenerative processes. A number of neurofibrillæ may de-

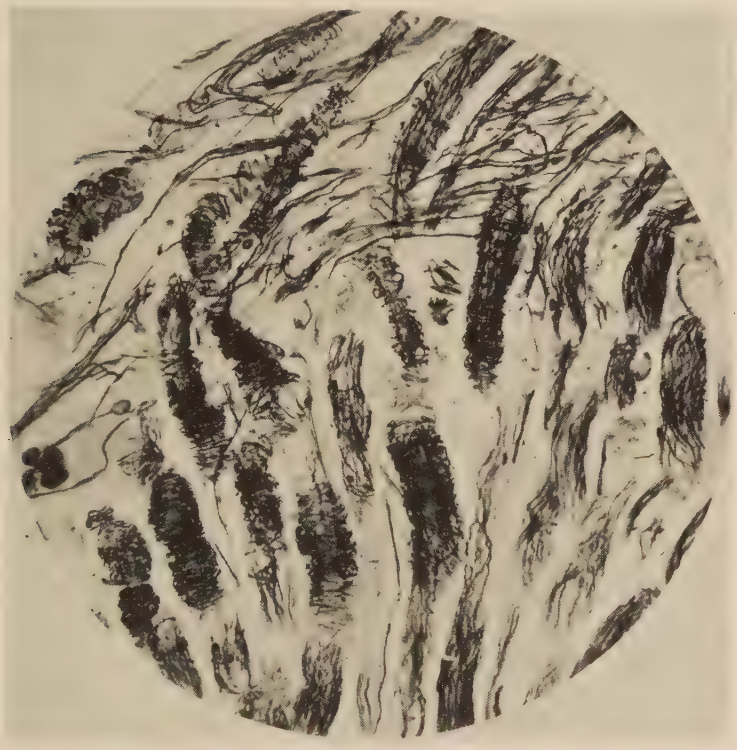

FIG. 3.—Group of spirals found in the proximal zone of a neuroma, just at the point where the straight longitudinal neuraxes first meet the connective tissue of the neuroma.

velop from each of these disks, or the disk may undergo a degenerative change. The center of the disk may disappear, leaving a nerve ring, which was also described by Perroncito, although he does not seem to have thought of the possibility of nerve-ring formation as a result of degeneration of the center of a

nerve disk. As a spiral enlarges, it may rupture its neurilemmal sheath. It then comes to lie directly in contact with the con-

FIG. 4.—High power of a spiral, showing neurofibrillæ spiralling back within the neurilemmal sheaths and several large end-disks. As the spiral enlarges it may break through the neurilemmal sheath and come to lie in the connective tissue. The center of these disks may disappear to form a nerve ring.

nective tissue of the neuroma. These spirals we believe to be one of the characteristics of an amputation neuroma in the

earlier stages of its formation. They indicate well the growth energy of neurofibrillæ stimulated to reproductive activity by division of a nerve.

Fig. 4 represents the number of spirals which may be observed in a neuroma. They have no constant position. The spiral represented in Fig. 4 was found at the periphery of a neuroma, while the spirals represented in Fig. 4 were found in the center of a neuroma in its proximal part where many of the fibers still retained their straight course and were not broken up and dispersed by scar tissue.

Fig. 5 represents the dispersion of neuraxes which occurs when the regenerating fibers reach scar tissue. The neuraxes which have a fairly straight course are found in the proximal part of the neuroma. As they approach the neuroma they become broken up and dispersed. In this instance, which is apparently quite accidental, these fibers bend in toward the center of the neuroma. Some small funiculi may be seen, but usually the neurofibrillæ are so broken up that a funicular arrangement is no longer preserved and the single fibers have an irregular zigzagging course through the scar tissue.

Fig. 6 is a section through the center of a neuroma. It indicates the irregular distribution of neuraxes in the scar tissue of the neuroma. In this section there is, however, an attempt at the formation of funiculi. There is no constant distribution of the different elements as has already been emphasized. A zonal arrangement in neuromas has been described by some.

In all sections numerous end-bulbs and disks indicative of marked attempts at regeneration may be seen.

The peculiarities of the connective tissue of the neuroma has been noted by many. Figs. 7 and 8 represent this tissue. It is rather loose and wavy and contains peculiarly shaped cells and fibers which appear to be swollen. It is rather a young connective tissue and remains so for some time. It is quite probable that the developing neuraxes in their regenerative activity stimulate this connective tissue to an excessive growth which continues for some time. In our attempts at prevention of neuroma forma-

tion, as will be shown later, it was thought that if the neuraxes could be prevented from regenerating until the tissue which

FIG. 5.—Proximal zone of a neuroma. Parallel neuraxes may be seen passing into the beginning of the neuroma. Several small end-bulbs and disks may be seen upon the neuraxes. The neuraxes become broken up and dispersed and irregularly distributed through the scar tissue.

developed in the cut end of the nerve had become adult connective or scar tissue, that the bulbous enlargement, which is formed

largely by developing neuraxes, but also by connective tissue, could be prevented. This loose, vascular tissue is formed by the endoneurium and perineurium, and also in part probably by the neurilemmal sheaths. It is practically impossible, however, to differentiate the sheath cells from the other cells which form constituent parts of the nerve.

In the older neuromas, as shown in Fig. 13, this scar tissue becomes more compact and sclerotic, and forms relatively heavy septa which surround and separate neighboring funiculi.

Corner, in discussing neuroma formation, states that divided nerve fibers first degenerate and afterward regenerate, undergoing two changes, while the connective tissue (endoneurium, perineurium and epineurium) commences at once to repair, undergoing but one change, and that as a result the connective tissue of the nerve gets a considerable regenerative start as compared with the neuraxes. Consequently in the early stages, according to Corner, the end bulb of a divided nerve consists very largely of fibrous tissue. Into this tissue the nerve fibers grow. The central part of the end-bulb is formed from the repairing inner coats of the nerve (the endoneurium and perineurium). Its outer and circumferential parts are largely formed from the outer coat (epineurium). This connective-tissue bulb has partly ceased to contract by the time the nerve fibers grow into it by reason of its early start, and it therefore offers a substantial buffer to the regenerating fibers.

The regenerative changes in neuraxes occur much more rapidly than Corner states. Within six hours after division of a nerve there are definite evidences of regenerative activity on the part of divided neuraxes. Some of these may be abortive, but some are definitive. The changes in the neuraxes and connective tissue occur and progress simultaneously, and it seems certain that the developing neuraxes stimulate the connective tissue to increased and continued growth.

A neuroma indicates an attempt—which is thwarted or blocked by scar tissue—on the part of the neuraxes of a divided nerve to seek the distal segment and thus complete nerve repair.

These regenerating neuraxes when blocked either form spirals or irregularly distributed and dispersed fibers in the bulb. These

FIG. 6.—Indicates the arrangement of the neuraxes in the center of the neuroma.

in their growth stimulate the connective tissue to increased and continued growth.

Any procedure which is employed with the intention of preventing neuroma formation must be directed against the neuraxes rather than against the connective tissue of the end of the nerve.

Intraneural Injection of Absolute Alcohol in the Prevention of Neuroma Formation. After division the trunk of the nerve is injected with absolute alcohol from three-quarters to one inch above the plane of section. Enough alcohol is injected to make the nerve appear a dull white, resembling quite a great deal cooked egg-albumin. The following experiments are cited to show the effect.

Rabbit No. 24. Large; full grown. Eleven days.

March 1, 1918. Left sciatic nerve exposed; large nerve—absolute alcohol injected at several different points. Approximately 2.5 cm. of the nerve were well injected. Nerve cut distal to the points of injection and about 1 cm. resected.

March 12, 1918. Rabbit killed. Sciatic nerve exposed. Distal end of proximal segment of nerve surrounded by small amount of pus. Nerve end slightly enlarged, having a light yellow color. Hemorrhage into nerve trunk, extending for a distance of about 3 cm. from end. Central segment removed and fixed in neutral formalin. Tissue stained by the Bielschowsky silver method.

Microscopic Findings. In several series of longitudinal sections of successive levels of the distal end of the proximal segment the neuraxes in the injected areas are broken up into short, irregular segments. The myelin of the fibers is present in the form of a granular detritus and smaller and larger globules. The neurilemmal sheaths appear well preserved. Here and there irregularly formed cellular elements are found within the neurilemmal sheaths, the histogenesis of which cannot be clearly determined.

Rabbit No. 40. Full grown. Eighteen days.

March 5, 1918. Left sciatic nerve exposed. Absolute alcohol injected at several points into the internal popliteal bundle by several point injections. Quite a little alcohol escaped into the

wound. The nerve was cut distal to the points of injection and resected. Wound closed.

March 23, 1918. Rabbit killed. Wound well healed. On exposing the sciatic nerve no material increase of connective tissue about the nerve was noted. Distal end of the proximal segment tapers to a fine point, which is slightly adherent to the underlying muscle. About 2.5 cm. of the proximal segment is of a light yellow color. Proximal sciatic segment removed and fixed in neutral formalin for Bielschowsky silver staining.

Microscopic Findings. In two series of longitudinal sections of successive levels of the distal end of the proximal segment it can be clearly determined that both of the divisions of the sciatic have been well injected, the alcohol evidently having passed into the main trunk of the nerve. Almost all of the neuraxes have been broken up into short segments and granules. The myelin has been broken up into a granular detritus. The neurilemmal sheaths are easily made out. In these many spindle-shaped enlargements are found at irregular intervals. Small nuclei, the origin of which is doubtful, are scattered throughout the granular myelin detritus. The fibrous tissue sheaths of the distal end of the proximal sciatic segment appear thickened. Fibrous tissue is found at the cut end of the nerve.

Rabbit No. 14. Full grown. Twenty days.

February 28, 1918. Left sciatic nerve exposed and injected with absolute alcohol, several injections being made. Very little alcohol escaped into the wound. Nerve cut distal to the points of injection and 1 cm. resected. Wound closed.

March 18, 1918. Rabbit found dead. Wound well healed. On exposing the sciatic the distal end of the proximal segment is found to taper to a fine line which is adherent to the underlying muscle. A small blood-clot surrounds the distal end of the proximal segment. Proximal segment removed and fixed in neutral formalin. Sections stained in iron-hematoxylin and picrofuschsin.

Microscopic Findings. In several series of longitudinal sections made at successive levels the structural appearance is

such that the sections would not be recognized as sections of peripheral nerve tissue. Endoneural connective tissue strands



FIG. 7.—Indicates the character and arrangement of the connective tissue in a neuroma.

and neurilemmal sheaths are the only parts which may be recognized in the larger internal popliteal bundle. The neuraxes have disappeared completely. The myelin has been broken up

into a granular detritus or appears as inclusions in large vesicular cells having very small nuclei. In the external popliteal nerve, not so fully injected, some normal neuraxes are to be found. In others degenerative changes resembling those occurring in a nerve after division are found. The neurilemmal sheaths of both the internal and external bundles present a structural appearance not unlike that of a normal nerve.

Rabbit No 28. Small; half-grown. Twenty-one days.

March 1, 1918. Left sciatic nerve exposed and injected with absolute alcohol. Successful injection, hardly any alcohol escaping. Nerve resected distal to the point of injection. Wound closed.

March 22. Rabbit found dead in the morning. Seemed well nourished. Wound healed well. On exposing the left sciatic nerve it was found but slightly adherent to the muscle bed. The distal end of the proximal segment tapers for a distance of 1.5 cm. to form a fine strand. It is of light yellow color. Distal end of proximal segment removed and fixed in neutral formalin. Sections stained with iron-hematoxylin and picrofuchsin.

Microscopic Examination. In several series of longitudinal sections, including the area of alcohol injection, the perineural sheaths of the funiculi appear slightly thickened. The neurilemmal sheaths of the old fibers are present only in part. In the areas in which they have disappeared and in some of the distended sheaths are found large vesicular cells, notably compressed, which have granular and globular inclusions. The cells have small nuclei. Such cells are less numerous in the distal part of the proximal segment. The nerve is consequently reduced in size.

Rabbit No. 11. Full grown. Twenty-four days.

February 26, 1918. Left sciatic nerve exposed and injected with absolute alcohol. Resected distal to point of injection.

March 22. Rabbit found dead in the morning. Seemed well nourished. Wound well healed. The nerve when exposed was found but slightly adherent to the underlying muscle. Distal end of the proximal segment presents tapering end. The

proximal part of the nerve was removed and fixed in neutral formalin. Sections stained with iron-hematoxylin and picro-fuchsion.

Microscopic Findings. In a series of longitudinal sections of the distal end of the proximal segment, including the part



FIG. 8.—Indicates the character and arrangement of the connective tissue in a neuroma.

injected with absolute alcohol and 2 cm. proximal to it, practically all the neurilemmal sheaths are preserved. Many of the old neurilemmal sheaths are greatly distended. Here and there they have disappeared. In such areas and within certain of the neurilemmal sheaths, large vesicular cells with small nuclei are observed. Both of the main bundles are equally involved.

Rabbit No. 1. Large; full-grown. Thirty-six days.

February 18, 1918. Left sciatic nerve exposed and raised from bed for several centimeters. Lifted on hook and injected with absolute alcohol. Nerve well injected, presenting milky white appearance. Resected distal to point of injection.

March 26. Rabbit died during morning; still warm when found. Much emaciated. Abscesses filled with cheesy material found in different parts of body. Wound well healed. On exposing the sciatic it was found that the external popliteal bundle was not cut at the operation and was not injected. Internal popliteal division found to have tapering end.

Microscopic Examination. It is evident from a study of several longitudinal sections that the internal popliteal is insufficiently injected, for a large number of the fibers are not affected. In the part injected the neuraxes and myelin sheaths have disappeared and are replaced by granular detritus and large vesicular cells with protoplasmic inclusions. Perineural connective tissue not materially thickened.

Rabbit No. 21. Full grown. Thirty-six days.

February 28, 1918. Left sciatic exposed and injected with absolute alcohol. Injected in two places 8 mm. apart. Nerve resected distal to points of injection.

April 5. Rabbit found dead in the morning; emaciated; wound well healed. On exposing the nerve a discoloration about distal end of proximal segment (probably due to hemorrhage) was noted. The distal end of the proximal segment tapers to nearly a point and presents a light yellow color. About 1.5 cm. proximal to the distal end the nerve presents a normal appearance. Nerve removed and fixed in formalin. Sections stained in iron-hematoxylin and picrofuchsin.

Microscopic Findings. In three series of longitudinal sections made at successive levels, taking in about 3 cm. of the distal end of the central stump, the following observations were made: Approximately 2 cm. proximal to the place of injection normal nerve tissue is reached. Distal thereto in progressive degree, neuraxes and myelin are replaced by granular detritus, globules and

phagocytic cells, in part within neurilemmal sheaths, in part in areas in which the neurilemmal sheaths have disappeared, only strands of endoneural connective tissue remaining. Downgrowing nerve fibers, in part with very thin myelin sheath, can



FIG. 9.—Effects of absolute alcohol injection upon the neuraxes. Finely granular material remains of degenerated neuraxes. Neurilemmal sheaths, many of which remain, are filled with granular masses and globules of fat.

be traced from the central undegenerated portion into the degenerated area. These fibers are found singly or in small bundles, have a very regular course, with direction in the main parallel to the long axis of the nerve, and reach to within 1 cm. of the distal end of the central stump. Here and there strands

of nucleated bands of syncytial protoplasm are noted in the degenerated portion of the nerve.

Rabbit No. 2. Large; full-grown. Forty-nine days.

February 18, 1918. Right sciatic exposed; partly freed and injected with absolute alcohol; cut distal to injection and 5 mm. resected. Wound closed.

March 18. Wound completely healed; hair growing over shaved area.

April 8. Found dead in the morning. On exposing the nerve it was found that the external popliteal but not the internal bundle was cut. External popliteal presents slight enlargement of distal end of central stump, which tapers to a fine strand and is of a light yellow color. Nerve removed and fixed in neutral formalin. Sections stained in iron-hematoxylin.

Microscopic Findings. Only cut external popliteal sectioned. It is evident from a series of longitudinal sections that this branch was only partly injected since in it only a small area in which neuraxes and myelin sheath disintegration is observed. The remainder of the stump resembles in structure closely an amputation neuroma, with proliferation of connective tissue and downgrowing neuraxes. This experiment cannot be regarded as successful.

Rabbit No. 43. Half-grown. Fifty-two days.

March 5, 1918. Left sciatic exposed and injected with absolute alcohol; one injection. Quite a little alcohol escaped to the wound. Nerve cut and resected. Wound closed.

April 25. Killed. Rabbit in good condition. On exposing the nerve this presents a normal appearance to about 2.5 cm. from the distal end of the central stump. Distal end shows a slight spindle-shaped enlargement centralward, then tapers to a fine strand. Streaks of yellow-white color, parallel to long axis observed. The distal end of the central stump removed and fixed in ammoniated alcohol for pyridine silver staining. Good differential silver staining obtained.

Microscopic Findings. In three series of longitudinal sections taken at different levels, it may be observed that in the distal

part of the central stump to the extent of about 2 cm. the neuraxes and myelin and in part the neurilemma sheaths of the nerves have been replaced by granular and globular detritus and vesicular cells, arranged in columns or groups, separated by strands of endoneural connective tissue and neurilemma remains. Single neuraxes or small groups of such, growing from the central undegenerated portion of the nerve, can be traced into degenerated area. These neuraxes have a regular course, in the main parallel to the long axis of the nerve. Nucleated protoplasmic strands accompany these neuraxes. In the distalmost part of the central stump as yet no new neuraxes are found; from this part also the granular detritus and vesicular cells have disappeared.

Rabbit No. 22. Full-grown. Fifty-six days.

February 28, 1918. Left sciatic exposed and injected with absolute alcohol; well injected. Nerve cut distal to field of injection and resected. Wound closed.

April 25. Killed. Rabbit in good condition; slight neurotrophic ulcer of left foot. Wound well healed. On exposing the nerve it is found that it presents a normal appearance to about 1.5 cm. from the distal end of the central stump, which presents only very slight enlargement, is of yellow-white color and tapers to a fine strand, which seems continuous with surrounding connective tissue. Nerve removed and fixed in ammoniated alcohol for pyridine silver staining. Successful silver differentiation obtained.

Microscopic Findings. In three series of longitudinal sections taken at successive levels it may be observed that numerous new neuraxes growing from the central undegenerated portion of the nerve have grown distally into the portion injected with absolute alcohol. These neuraxes course singly or in small bundles, having in the main a longitudinal course, the small bundles of neuraxes showing here and there interchange of fibers. Between these neuraxes are found columns or areas of granular detritus and vesicular cells. The down-growing neuraxes have practically reached the distal end of the central stump. There is observed no tangling or criss-crossing of neuraxes as seen in a

neuroma, nor in the intergrowth of neuraxes and connective tissue as observed at the end of a neuroma.

FIG. 10.—Section of specimen ninety days after injection. Degenerated neuraxes and myelin sheaths may be seen in lower part of the field. Straight longitudinal regenerating neuraxes may be seen in upper part. No evidences of spiral formation or end disks seen in this section.

Rabbit No. 41. Large; full-grown. Fifty-eight days.

March 5, 1918. Left sciatic exposed and internal and external popliteal bundles injected separately; the former injected twice; injection good. Nerve cut distal to injection and 1 cm. resected. Wound closed.

May 3. Rabbit found dead in the morning. Neurotrophic changes on left heel; popliteal lymph gland enlarged. On expos-

ing the nerve it is found that the central stump tapers to a fine strand and presents a light yellow color. About 2 cm. central to distal end of central stump nerve presents normal appearance with distinct funiculi. Nerve removed and fixed in Flemming chrom-osmic-acetic solution. Sections stained in safranin and licht grün.

Microscopic Findings. In three series of longitudinal sections taken at successive levels it may be observed, beginning with the most distally placed series, that the neuraxes and myelin of the nerve fibers of both of the main funiculi have entirely disappeared. Fine strands of endoneural connective tissue and neurilemmal sheath remain, forming a very open-meshed network, surrounding areas of granular and globular detritus, through which are scattered small round or oval nuclei. In the series of the next higher level the same general structure is found for the greater part of the section. In the more central portion of the sections small strands of syncytial nucleated bands of protoplasm are observed which become more numerous in the centrally placed of the three series. These nucleated protoplasmic bands have grown into the degenerated portion of the nerve from the central undegenerated portion.

Rabbit No. 38. Nearly full-grown. Sixty-three days.

March 5, 1918. Left sciatic exposed; quite a little bleeding which was controlled. Two injections of absolute alcohol made; both bundles injected. Nerve cut and 5 mm. resected. Wound closed.

May 13. Rabbit found dead in the morning; in fairly good condition. On exposing the nerve, distal end of central stump found tapering to fine strand slightly adherent to muscle bed. The distal end for a distance of about 2 cm. presents a light yellow color; central to this the nerve has a normal appearance. Nerve removed and fixed in neutral formalin. Sections stained in iron-hematoxylin and picrofuchsin.

Microscopic Findings. In several series of longitudinal sections taken at successive levels it is observed that in the distal end of the central stump, in the area of the alcohol injection,

neuraxes and myelin of the nerve fibers have entirely disappeared, fine strands of endoneural connective tissue and remnants of neurilemmal sheaths remaining. This portion of the nerve consists almost wholly of granular and globular detritus separated by the perineural sheaths. More centralward in the series of sections, nucleated protoplasmic bands growing distally from the undegenerated central nerve are to be observed; to one side, near the epineural sheath, these protoplasmic bands extend distally to near the distal end of the central stump.

Rabbit No. 18. Full grown. Sixty-five days.

February 27, 1918. Left sciatic exposed; large vein cut; clamped. Absolute alcohol injected and nerve cut just distal to injected field and resected. Wound closed.

May 5. Found dead in the morning. Protocol incomplete, simple statement: "No neuroma."

Rabbit No. 10. Full grown. Seventy-one days.

February 26, 1918. Left sciatic exposed and injected with absolute alcohol. Nerve cut distal to field of injection; 1 cm. resected. Wound closed.

May 8. Killed. Rabbit not in good condition; emaciated; "fungus" ears. On exposing the left sciatic central stump it is found ending in fine tapering strand, not especially adherent to the muscle bed; is of a light yellow color. About 2 cm. central to distal end nerve presents the appearance of normal nerve. The nerve was removed and fixed in ammoniated alcohol for pyridine silver staining. Very good differential silver staining obtained.

Microscopic Findings. From the miscroscopic appearances presented in the several series of longitudinal sections taken at successive levels it is evident that the injection of alcohol was not wholly successful in this experiment. Numerous neuraxes may be traced from the central portion of the nerve, toward the end of the central stump, numerous large end disks found at various levels. Especially to one side of the nerve, and about 2 mm. from its distal end, numerous complex spirals of neuraxes are to be observed. At the distal end of the central stump,

crossing and recrossing of neuraxes is observed, though there is not observed that intergrowth of neuraxes and connective tissue such as is generally seen in a neuroma. In the entire series of sections a few remains of myelin and neuraxes of the old nerve

FIG. 11.—Section of distal end of proximal segment of a rabbit's sciatic nerve ninety days after injection with absolute alcohol. Note tapering end of nerve without any evidence of neuroma formation. The ends of these nerves in the earlier stages often present a peculiar yellowish-white appearance, due to the degenerated myelin.

fibers are observed. The conclusion seems warranted that at the time of operation the nerve trunk was partially injected with absolute alcohol. After section of the nerve a partial neuroma developed.



FIG. 12.—Indicates presence of few neuraxes in injected part of nerve.

Rabbit No. 32. Full grown. Eighty days.

March 4, 1918. Left sciatic exposed. Several injections of absolute alcohol made, spaced at intervals of about 5 mm. Well injected. 1.3 cm. of nerve resected just distal to field of injection. Wound closed.

May 23. Killed. Rabbit in good condition; several neurotrophic changes affecting the left hind foot. On exposing the

left sciatic this presents a normal appearance to within 2 cm. of the distal end of the central stump. The end presents first a slight enlargement then tapers to a fine strand only loosely adherent to the surrounding connective tissue. Distal nerve segment completely degenerated. Central sciatic removed and fixed in ammoniated alcohol for pyridine silver staining. Good differential silver staining obtained.

Microscopic Findings. In three series of longitudinal sections and one series of cross-sections approximately 3 cm. of the distal end of the central sciatic stump was sectioned. The most centrally placed sections include a portion of the normal nerve. Numerous downgrowing neuraxes may be traced from this portion of the nerve into that portion immediately influenced by the absolute alcohol. In this latter portion areas and columns of globular and granular detritus are found, coursing between which there may be observed smaller and larger bundles of neuraxes, which have in the main a regular course, with here and there an interchange of fibers. These downgrowing neuraxes may be traced to the distal end of the central stump, but present no tangling or intertwining as observed in a neuroma. The perineural sheath surrounds these downgrowing neuraxes.

Rabbit No. 26. Full grown. Eighty-three days.

March 1, 1918. Left sciatic exposed and injected with absolute alcohol. Well injected. Nerve cut distal to field of injection and 8 mm. resected. Wound closed.

May 23. Killed. Rabbit in good condition. On exposing the left sciatic this presents a normal appearance to within 2 cm. of the distal end of the central stump. Distal end of central stump presents slight enlargement, then tapers to fine strand, adherent to underlying muscle. Nerve removed and fixed in ammoniated alcohol for pyridine silver staining. Good silver differentiation obtained.

Microscopic Findings. In two series of longitudinal sections in which approximately 4 cm. of nerve is sectioned it is observed that numerous neuraxes growing distalward from the central uninjured portion of the nerve extend into the portion affected

by the absolute alcohol. These neuraxes are enclosed within the thickened perineural and epineural sheaths and have in the main a longitudinal course, except those found in close proximity to the fibrous sheaths, many of them cross and recross and intertwine on the inner surface of the perineural sheath. These



FIG. 13.—Old neuroma indicating dense relatively sclerotic scar tissue surrounding funiculi. The fibers forming these funiculi have, for the most part, acquired their medullary sheaths.

downgrowing neuraxes can be traced to the attenuated end of the central stump. The remains of the fibers affected by the absolute alcohol are found in areas of granular detritus, interspersed with large vesicular cells, and fat cells, between which course the neuraxes.

Rabbit No. 29. Full grown. Eighty-three days.

March 1, 1918. Left sciatic exposed and injected with absolute alcohol; well injected. Nerve cut distal to field of injection and resected. Wound closed.

May 23. Rabbit found dead in the morning. Left femur found broken; apparently some days before death. On exposing the sciatic, tissues about the nerve were found much congested and contained extravasated blood, owing to fracture. The distal end of the central sciatic found to taper to a fine strand; relations not clear, owing to extravasated blood. Nerve removed and fixed in ammoniated alcohol for pyridine silver staining. Good silver differentiation obtained.

Microscopic Findings. In two series of longitudinal sections, including approximately 4 cm. of the distal end of the proximal stump, large numbers of downgrowing neuraxes may be traced from the uninjured central portion of the nerve to its distal end. These neuraxes are enclosed in the thickened fibrous tissue sheaths of the nerve and have in the main a regular course. Within the area injected with absolute alcohol a few columns and areas of granular detritus, certain large vesicular cells and many fat cells are found. Such columns and areas are separated by bundles of downgrowing neuraxes, a few of which cross such fields either as single fibers or as small bundles of such.

Rabbit No. 17. Nearly full grown. Eighty-four days.

February 27, 1918. Left sciatic exposed and injected with absolute alcohol. First injection not successful; nerve slightly torn. Second attempt at a higher level was successful; well injected. Nerve cut and resected. Wound closed.

May 22. Rabbit found dead in the morning; seemed in good condition; severe neurotrophic changes in left hind foot. On exposing the left sciatic the distal end of the central stump is found to taper to a fine strand; adherent to the underlying muscle. Several delicate nerve bundles appear to extend on the muscles bed for a distance of about 1 cm. beyond the cut end of the nerve. No evidence of a neuroma noted. Nerve removed and fixed in ammoniated alcohol for pyridine silver staining.

Good differential silver staining obtained. A portion of the nerve removed in this experiment was lost; the portion at hand represents the most distal portion of the central stump for the length of a little over 1 cm.

Microscopic Findings. In a series of longitudinal sections small bundles of fine neuraxes, enclosed within the thickened fibrous sheath, are observed. These bundles of neuraxes are found separated by areas of granular detritus and fat cells.

Rabbit No. 42. Half-grown. Eighty-four days.

March 5, 1918. Left sciatic exposed and injected with absolute alcohol; larger bundle in two stages; smaller bundle, one injection. Well injected. Nerve cut and resected 1 cm. Wound closed.

May 29. Rabbit found dead in the morning. Protocol incomplete. Nerve removed and fixed in ammoniated alcohol for pyridine silver staining. Good silver differentiation obtained.

Microscopic Findings. In three series of longitudinal and cross-sections in which approximately 4 cm. of nerve were cut, central neuraxes are found passing distalward through the area injected by absolute alcohol and have reached the distal end of the central stump, and as scattered neuraxes or as small bundles of such can be traced into the connective tissue overlying the muscle bed for a distance of about 1 cm. beyond the cut end of the nerve. In the main these neuraxes have a very regular longitudinal course. Very little detritus, the remains of the injured nerve fibers, found in the area injected with absolute alcohol.

Rabbit No. 8. Full grown. Ninety days.

February 23, 1918. Left sciatic exposed and injected with absolute alcohol; well injected. Nerve cut just distal to injection; 1 cm. resected. Wound closed.

May 23. Killed. Rabbit very much emaciated; severe neurotrophic changes in foot, two toes missing; large ulcer on heel. On exposing the sciatic this is found of normal appearance to within about 1.5 cm. from the end of the central stump. End of stump presents slight enlargement then tapers to a fine strand.

The nerve removed and fixed in ammoniated alcohol for pyridine silver staining. Faint but differential neuraxes staining obtained.

Microscopic Findings. In three series of longitudinal and one of cross-sections, taking in a little over 4 cm. of the distal end of of the nerve the following may be observed: Neuraxes in large numbers can be traced from the central practically uninjured portion of the nerve, through the area affected by the alcohol to the distal end of the central stump. In a series of cross-sections, taken about 2 cm. above the point of puncture for alcohol injection, the funicular structure of the nerve is not lost; the perineural sheaths are distinctly thickened. Within the funiculi numerous neuraxes are seen in cross-section, four to ten within one neurilemmal sheath. Not all of the funiculi are equally affected. In the more distal portion of the nerve, in two series of longitudinal sections, numerous neuraxes, having in the main a longitudinal course, and arranged in larger or smaller bundles, and separated by elongated areas and columns of granular detritus, vesicular cells and fat cells, are to be observed, enclosed within the thickened fibrous sheaths.

Rabbit No. 37. Full grown. Ninety-three days.

March 5, 1918. Left sciatic exposed and injected with absolute alcohol; both bundles well injected. Nerve cut about 5 mm. distal to place of injection and 1 cm. resected. A small amount of alcohol escaped into the wound. Wound closed.

June 6. Killed. Rabbit in fair condition; neurotrophic ulcer on left heel. On exposing the sciatic nerve it is found to present normal appearance to near the end of the distal stump, which tapers to a fine strand. Nerve removed and fixed in Flemming's chrom-osmic-acetic mixture. Sections stained with safranin and licht grün. In several series of cross- and longitudinal sections made from the distal 4 cm. of the central stump the following observations are made: In the series of longitudinal sections small bundles composed of nucleated protoplasmic bands and fine myelinated nerve fibers may be traced from the central normal portion of the nerve to the end of the distal stump. Between these there are found broader or narrower columns

composed of, in the main, large vesicular cells with small nuclei, having globular and granular protoplasmic inclusions. These cells would appear to have phagocytized the remains of the nerve fibers affected by the absolute alcohol. The fibrous sheaths of the distal end of the central stump are found materially thickened. In the distal 1.5 cm. the funicular structure of the nerve is lost.

Rabbit No. 34. Full grown. Ninety-four days.

March 4, 1918. The left sciatic exposed and injected with absolute alcohol; well injected. Nerve cut 5 mm. distal to the place of injection and 1 cm. resected. Wound closed.

June 5. Killed. Much emaciated; severe neurotrophic ulcer left heel. On exposing the left sciatic nerve it is found to be normal to within 1.5 cm. of the end of the central stump; presents slight enlargement then tapers to a fine strand; adherent to the underlying muscles. Nerve removed and fixed in neutral formalin. Sections stained in iron-hematoxylin and picro-fuchsin. Tissue not well embedded; sections torn.

Microscopic Findings. In the sections remaining it can be determined that nucleated protoplasmic bands extend from the central undegenerated portion of the nerve to the distal end of the central stump. These bands of nucleated protoplasm may be regarded as non-myelinated fibers. Between such bands or bundles are found columns or long spindle-shaped areas of large closely arranged vesicular cells with globular or granular inclusions.

Rabbit No. 39. Small rabbit; not full grown. Ninety-five days.

March 5, 1918. Left sciatic exposed; free venous bleeding. Absolute alcohol injected; larger bundle injected in several places; smaller bundle in one place. Well injected. A small amount of alcohol escaped into wound. Wound closed.

June 8. Rabbit found dead in the morning. On exposing the left sciatic this presents a normal appearance to within a short distance of the distal end of the central stump which tapers to a fine strand. Nerve removed and fixed in ammoniated alcohol for pyridine silver staining. Silver differentiation is successful.

Microscopic Findings. Several series of longitudinal sections showed that the neuraxes were not sufficiently differentiated to permit of the interpretation of no neuroma formation. The arrangement of the connective tissue, however, warrants this conclusion.

Rabbit No. 27. Full grown. Ninety-seven days.

March 1, 1918. Left sciatic exposed and injected with absolute alcohol. On first attempt, movement of animal prevented successful injection; on second trial successful injection was made. Nerve cut distal to injection and resected.

June 6. Killed. Rabbit in good condition. On exposing the left sciatic the nerve presents a normal appearance to near the distal end of the central stump, which appears to end in a fine tapering strand. The relations of the distal end of the central stump not clearly made out, owing to the presence of a dense cicatricial tissue at the end of the fine tapering strand. Nerve removed and fixed in ammoniated alcohol for pyridine silver staining. Fairly good silver differentiation obtained; sheath nuclei as well as neuraxes stained.

Microscopic Findings. Several series of longitudinal sections made. In these it is possible to trace numerous neuraxes from the more centrally placed sections, through the field affected by the alcohol injection to the distal end of the central stump. At the distal end of the central stump the neuraxes were found to cross and recross, especially those found in close relation to the outer fibrous sheath. In the more central portion the neuraxes present a more regular longitudinal course. In this portion of the nerve, between small bundles of neuraxes, large spindle-shaped areas composed of vesicular cells and granular detritus are to be found. In relation with the distal end of the central stump there was noted at the time the nerve was removed a small irregular mass about 5 mm. in diameter which appeared to consist of dense fibrous tissue. In sections this mass was found to contain a nucleus of osseous tissue surrounded by dense fibrous tissue. In this fibrous layer, mainly to one side, several small bundles of neuraxes were found. A study of this series of

sections suggests imperfect alcohol injection, and as a result partial neuroma formation with proliferation of fibrous tissue consequent to escape of alcohol into the wound.

Rabbit No. 15. Full grown. One hundred and two days.

February 26, 1918. Left sciatic exposed and injected with absolute alcohol; nerve cut distal to injection and 1 cm. resected. Wound closed.

June 8. Killed. Animal not in good condition; severe neurotrophic ulcer on the left heel; popliteal lymph gland greatly enlarged. On exposing the left sciatic the central stump was found tapering to a fine strand; distal end of light yellow color. Connective tissue in proximal part of the popliteal space quite dense. Central sciatic removed and fixed in ammoniated alcohol for pyridine silver staining. Good silver differentiation obtained, especially in the more central portion of the nerve.

Microscopic Findings. Two series of longitudinal sections, including the 2 cm. of the distal end of the central stump, made. In the more distally placed series, within the thickened fibrous sheath, a granular detritus and vesicular cells occupy nearly the entire area. No downgrowing neuraxes appear to have reached this portion of the central stump. In the more centrally placed series numerous new neuraxes are found; those more axially placed have a regular course, those more peripherally placed criss-cross on the inner surface of the fibrous tissue but do not present the intergrowth of fibrous tissue and neuraxes as noted at the distal end of a neuroma.

Rabbit No. 3. Large; full grown. One hundred and eight days.

February 18, 1918. Left sciatic exposed and injected with absolute alcohol. Nerve cut about 5 mm. distal to place of injection; not resected. Wound closed.

June 6. Killed. Left hind foot slight neurotrophic changes on heel. On exposing the sciatic it is found that the external popliteal division was not cut and probably not injected. Central stump of internal popliteal presents a tapering end. Some delicate fine strands seem to extend beyond the cut end. On

cutting these "fibers," no twitching of calf muscles observed. The nerve was removed and fixed in ammoniated alcohol for pyridine silver staining. Good silver differentiation obtained.

Microscopic Findings. The non-cut and non-injected external popliteal sectioned with the cut and injected internal popliteal cut together in a series of longitudinal sections. In the section the external popliteal presents the appearance of a normal nerve; here and there a few degenerated fibers are noted. In the distal end of the central stump of the internal popliteal, central downgrowing neuraxes can be traced to the distal end, having in the main a regular longitudinal course, and separated into smaller and larger bundles by long spindle-shaped areas, occupied by granular detritus and large vesicular cells. A few neuraxes can be traced into the connective tissue surrounding the distal end of the central stump of the internal popliteal.

Rabbit No. 25. Half-grown rabbit. One hundred and fifty days.

March 1, 1918. Left sciatic exposed and injected with absolute alcohol. Well injected; practically no alcohol escaped to the wound. Sciatic cut 5 mm. distal to place of injection and 1 cm. resected. Wound closed.

July 30. Killed. Rabbit not in good condition. On exposing the left sciatic the central stump is found to end in a fine tapering strand. No bulb. No nerve fibers could be traced beyond the cut end of the nerve. Central sciatic removed and fixed in ammoniated alcohol for pyridine silver staining. Good differential silver staining obtained. During embedding the end of the central sciatic stump became bent, so that it was not possible to cut longitudinal sections, including the entire length of the piece.

Microscopic Findings. It is evident on study of the entire series that downgrowing neuraxes coming from the central uninjected portion of the nerve have passed through the area injected with absolute alcohol and have reached the distal end of the central sciatic stump. These neuraxes have in the main a longitudinal course. Toward the distal end some criss-crossing of neuraxes is observed—not to the extent found in a neuroma –

and such criss-crossing of neuraxes as is observed occurs within the fibrous tissue sheath and mainly on its inner surface.

Rabbit No. 23. Nearly full grown. One hundred and fifty-seven days.

March 1, 1918. Left sciatic exposed and injected with absolute alcohol. Well injected. A small quantity of alcohol escaped into the wound. Nerve cut just distal to place of injection and resected. Wound closed.

August 5. Killed. Rabbit in good condition; foot missing; stump completely healed. On exposing the sciatic the central stump is found to end in a fine tapering strand from the distal end of which a fine filament can be traced toward the distal sciatic stump, but does not reach it. Calf and foot flexor muscles completely degenerated. Central sciatic removed and fixed in ammoniated alcohol for pyridine silver staining. Not wholly successful differentiation obtained; patchy.

Microscopic Findings. In a fairly complete series of longitudinal sections, taking in the distal 2 cm. of the central sciatic stump, it may be observed that numerous neuraxes, both myelinated and non-myelinated, grow distal through the field of alcohol injection to the extreme distal end of the central stump. Here the connective-tissue sheath of the nerve is found very materially thickened, the connective tissue extending into the interior of the nerve end and separating the nerves into small intertwining bundles. More centrally the neuraxes have a more regular longitudinal course, except those found in close relation to the fibrous tissue sheath which courses along the inner surface of the sheath without definite arrangement. The structural appearances presented are not those of a neuroma.

The microscopic findings in the distal end of the proximal segment one hundred and fifty-seven days after alcohol injection are interesting and instructive. By this time numerous neuraxes, both myelinated and non-myelinated, have passed through the injected part of the nerve to the extreme distal end of the proximal segment. The connective tissue sheath of the nerve is very materially thickened at this point. It extends into the interior

of the nerve and separates it into small intertwining bundles. More centrally the neuraxes have a more regular longitudinal course, except those in close relation to the fibrous sheath which course along the inner surface of the sheath without definite arrangement. The structural appearance presented is not that of a neuroma.

These findings are in marked contrast to those noted after operations, recognized surgical procedures, which are performed upon the end of the nerve. These are the so-called swing-door and the crush-and-tie operations. We shall quote but two typical examples of these.

Serial sections of a specimen removed two weeks after the swing-door operation revealed fairly dense fibrous tissue over the end of the nerve. Distinct neuroma structure is found in the distal end of the proximal segment. At the end of the nerve, just proximal to the fibrous cap, many interlacing newly formed neuraxes are found in the fibrous tissue. Some of the developing neuraxes are growing into the connective tissue distal to the end of the proximal segment. Many spirals are found at all levels in the series in the part undergoing neuroma formation.

Four weeks after the swing-door or reversed V operation the typical neuroma structure is found. The pyramidal fibrous cap, spirals with interlacing neuraxes and much fibrous tissue are observed. Small bundles of neuraxes with a more regular course are found distal to the area in which the interlacing neuraxes are so numerous. The large number of end disks indicate actively proliferating fibers. There are a good many spirals. These are mostly grouped in several areas.

Four weeks after the crush-and-tie operation a distinct neuroma picture is found. The distal end of the proximal segment has a relatively long connective-tissue cap which is pyramidal in shape. The newly formed neuraxes have grown into this long connective-tissue cap. In the region just proximal to this scar tissue there is a marked interlacing of newly formed neuraxes in the fibrous tissue. Many spirals are found in the various fields.

These two operations which are recommended and employed in clinical surgery do not prevent neuroma formation. While the neuroma seems to form a little more slowly after the crush-and-tie operation it is well formed at the end of four weeks.

Even as early as one week after these operations there is distinct evidences of neuroma formation indicated by the development of end-disks and spirals which indicate a connective- or scar-tissue block.

An objection has been raised against the injection of alcohol with the view of preventing neuroma formation, as it is claimed that the alcohol may escape into the surrounding tissues and increase the amount of scar tissue. The surrounding tissues may be easily protected from the alcohol, little if any of which escapes if the injection is carefully made. We have never seen a material increase in the amount of scar tissue and have never observed the formation of a neuroma at the site of injection.

Conclusions. 1. A neuroma indicates an attempt, which is thwarted or blocked by scar tissue, on the part of the neuraxes of a divided nerve to seek the distal segment and thus complete nerve repair.

2. When blocked the regenerating neuraxes form spirals and end-disks and become irregularly dispersed throughout the connective tissue of the bulb.

3. The regenerating neuraxes react upon the connective-tissue elements of the bulb, which, as a consequence, increase in number and maintain their embryonal characteristics longer than is normally the case.

4. The swing-door or reversed V operation and crush-and-tie operation do not prevent neuroma formation.

5. Any method to be successful must be directed against the neuraxes.

6. Absolute alcohol injected in the nerve some distance (from $\frac{3}{4}$ to 1 inch) above the plane of section is more successful in preventing neuroma formation than any of the other methods ordinarily employed.

DISCUSSION

Dr. Joseph A. Blake, New York City:

I should like to know the technic employed in an ordinary amputation above the knee and what percentage of alcohol is injected?

Dr. George W. Crile, Cleveland:

I should like to ask if Dr. Lewis can give an explanation for the spontaneous pain?

Dr. Dean Lewis, Chicago (in closing):

Absolute alcohol is injected into the nerve from three-fourths to one inch above the plane of section. Enough alcohol is injected to make the nerve a dull white, resembling in color cooked albumen, at the site of injection. I believe that in many cases it is impossible to account for the pain, while in other instances the pain is undoubtedly associated with or dependent upon an inflammatory process in the neuroma as in the nerve proper and its bed.

THE RADICAL TREATMENT OF ROENTGEN-RAY BURNS

By JOHN STAIGE DAVIS, M.D.
BALTIMORE, MD.

Roentgen-ray burns were quite common when long exposures were necessary to secure satisfactory plates and before the methods of protecting patient and operator were understood. They are now comparatively rare, but during the last ten years I have had a number of them referred to me and can recall several occasions when I have had three or four such cases in the hospital at one time.

These burns are usually caused by the use of roentgen rays in the treatment of skin lesions, such as psoriasis, eczema and superficial epithelioma; by frequent exposures extending over a long period of time in the treatment of inoperable or incompletely removed carcinoma; by the reckless use of the apparatus in the hands of unskilled operators and by long fluoroscopic exposures.

I have had under my care burns situated in almost every region of the body.[1] Some of them have been of the first degree, where the skin is reddened; a few of the second degree; where blisters formed; but the vast majority have been of the third degree, where the full thickness of the skin and often the underlying tissues were involved. It is the latter group in particular that I wish to consider in this paper.

A peculiarity of a roentgen-ray burn is that considerable time may elapse (several weeks or months) before the extent of the

[1] Scalp, face, neck, chest, back, shoulder, arm, forearm, hand, abdominal wall, penis, thigh, leg and foot.

damage done becomes apparent. Some very severe burns have followed single exposures, others have been the result of multiple exposures. One patient in my series had been given more than 450 treatments, scattered over several years; another had fifteen minute exposures every day for nine months and several others had more than 100 treatments. Some of the deeper burns had existed from a few weeks to as long as fifteen years before coming under my care.

On inspection the burned area may be considerably hollowed out. The skin is hairless and atrophied, smooth, dry and shiny, with or without a blotchy brownish pigmentation. In the majority of cases there are characteristic telangiectases which may be discrete or occur in reddish patches. Punctate hemorrhages due to rupture of dilated capillaries may be present.

On palpation the tissue is hard and board-like. Its outline where it merges into surrounding skin may be quite irregular. Occasionally the entire area is covered with a sharply differentiated, brown, mummified tissue.

The ulcers may be superficial or may involve the full thickness of the skin, with a considerable depth of the underlying soft parts.[1] The history of many of them is that they heal slowly and then break down, this process being repeated over and over. Some of the ulcers never heal without operative interference.

There is usually an irregular-shaped patch of tightly adherent necrotic tissue occupying the central portion of the ulcer. The edges are thickened and grayish red in color; are very hard and are often everted. In fact, the clinical appearance is suggestive of malignancy. From the edges outward to normal skin we find the tissue more or less infiltrated with scar.

Exquisite sensitiveness is characteristic of the deep burns. The pain in an ulcerated area may be due to irritation caused by infection, which is always present; to changes in the nerves themselves or to pressure on the nerves by scar tissue. Any one or all of these conditions may exist. Addiction to narcotics is

[1] I have seen the entire thickness of the abdominal wall involved in a burn.

not uncommon, as the burning pain even from a tiny ulcer may be severe and continuous. There may be intense pain, making operative interference necessary, after spontaneous healing has taken place. This pain in a healed burn may be due to nerve changes, to pressure by scar tissue or to both conditions.

There is said to be a marked tendency to malignant degeneration in chronic roentgen-ray burns, but my experience has been that this tendency is no more marked in these burns than in any other chronic ulcer.

Microscopic examination of the excised tissues in all my cases, where the full thickness of the skin was involved, has been negative for malignancy.

Dr. J. C. Bloodgood sends me the following report after study of the excised tissues: "The characteristic features in a roentgen-ray burn as compared to a leg ulcer or any other type of simple ulcer are—roentgen-ray keratosis at the edge of the ulcer with atypical downgrowth of epithelium, with or without pearly body formation; a very superficial zone of cellular granulation tissue; unusual scar tissue formation which, as a rule, extends to the muscle; thickening of the walls of the bloodvessels with endothelial obliteration and minute abscess formation beneath the surface of the ulcer."

There is, however, a distinct tendency toward malignant degeneration when chronic ulceration follows the breaking down of a patch of keratosis, such as we find on the hands of the pioneer roentgenologist Two such cases have been under my care. In both the axillary glands were involved and were removed. In one case too short a time has elapsed to predict the ultimate result, but in the other there has been no recurrence after the lapse of a number of years.

Treatment. Recent roentgen-ray burns of all degrees should be treated as ordinary burns, but unless there is a fairly prompt response to such treatment it is a mistake to continue it.

Palliative measures should be used in burns of the first degree. Paraffin films are often comforting; painting with collodion,

or the application of sterolin[1] or some bland ointment are useful procedures.

Burns of the second degree, when there is blistering, have been quite rare in my series, although I have in mind one case in which both hands had been treated several times for localized sweating of the palmar surfaces. Blistering began about one week after the last exposure and the entire skin of each hand came away like a glove after about two weeks.

It is difficult to tell at first the depth of such a burn, as one which seems to be merely blistered will turn out to be much deeper in places after the blisters have been removed. I have found that wet dressings have been more comfortable in these cases than paraffin or ointments.

In burns of the third degree which do not heal promptly and permanently by the usual methods we must adopt a more radical procedure. The ulcer and surrounding area of induration should be excised with a wide margin out to and down to healthy tissue. It is impossible to tell the depth of the destructive process until excision is done.

The tissues are of extreme hardness and will often turn the edge of a scalpel. The subcutaneous fat may be completely destroyed, but if present is a deep yellow color and is very firm and resistant, due to scar tissue involvement. In deep burns the muscle may be entirely replaced by dense scar tissue or there may be varying degrees of infiltration with scar. The bleeding is always marked after excision and is often difficult to check, as there is general oozing from all portions of the wound.

After excision the defect should be grafted immediately if the base of the wound is of normal tissue, but if doubtful tissue is left (owing to the impossibility of complete excision), grafting should be deferred until granulations form. The type of graft used should depend upon the situation. I use "small deep grafts" in the majority of instances, but have used with satisfaction Ollier-Thiersch or whole-thickness grafts in selected positions.

[1] Formula: Balsam of Peru, 4 c.c.; castor oil and Venetian turpentine of each, 2 c.c.; alcohol (95 per cent.) 100 c.c.

Pedunculated flaps from neighboring tissues or from a distant part have been of great use in situations where a pad of fat, in addition to whole-thickness skin, was necessary.

The best method of relieving the pain, aside from the excision of the affected area, is to divide the nerves supplying the area.

Roentgen ray and radium have been used in the treatment of roentgen-ray burns, and several patients have come under my care who had been treated in this way. I have seen no benefit follow such treatment

Patches of keratosis which exist on the roentgen-ray operator's hand, following frequent exposures without protection, may be successfully treated by freezing with carbon dioxide ice. This is a tedious and painful process. Radium may be used with success, but the reaction is also painful. In my opinion it is less safe than the carbon dioxide ice. Should the patches of keratosis ulcerate, neither of the methods just mentioned should be employed. Complete excision with immediate or subsequent grafting is then the method of choice.

Comments. Roentgen-ray burns often cause complete loss of function of a part. In more severe burns of the hands one is struck by the rigidity of the fingers, due to involvement of the tendons and overlying soft parts, and even of the joints themselves.

In those instances in which tendons have been destroyed it is advisable to fill the defect with a pedunculated flap of skin and fat and later to restore the tendon by the method best suited to the particular case.

When large areas are involved we seldom excise sufficient tissue, and I have noticed that infection sometimes occurs in the margins of these wounds. Occasionally there is sloughing of the entire margin of the wound, although the excision has been apparently complete, and for this reason alone it may be wise to defer grafting or the transference of a flap.

Fulminating infections occur in areas of skin which have been burned by roentgen rays. Prompt excision with a generous margin is indicated, or even amputation of the part may be necessary to control the rapid spread of the infection.

The after-results of excision with grafting or flap-shifting have been most gratifying. I have no record at the present writing of a case in which a break-down has followed the thorough application of the method. Furthermore, function is restored in many instances and patients who have been incapacitated for years have been returned to their former activities.

AN OPERATION FOR CURE OF LARGE VENTRAL HERNIA

By CHARLES L. GIBSON, M.D.
NEW YORK

A brief description of this operation was made in my article on "Postoperative Intestinal Obstruction," *Annals of Surgery*, April, 1916. My experience in this particular procedure now numbers eight cases, and the results have been very gratifying. This operation is not intended to supplant the customary operations for repair of incisional hernia or cure of umbilical hernia, but it is intended for those cases for which the ordinary operations are not applicable and, in fact, usually quite impossible. The bulk of these cases would have been denied operative relief or subjected to some procedure of doubtful value, such as the implantation of a filigree.

The first operation in 1914 was done on the spur of the moment in an effort to give the patient a competent abdominal wall which was necessary to her profession as physical training instructor. It was felt at that time that the particular procedure used was somewhat hazardous, and it was a source of surprise and gratification that the operation succeeded perfectly, and at the end of six years there are no signs of any recurrence, and the functional result is perfect.

Encouraged by this original result, similar operations were performed in cases of increasing magnitude, some of them apparently too great to be overcome. Success, however, attended all cases except the last (No. 8), which showed that the limit of operative possibilities had been attained. This was a recurrent

case (Fig. 8), with enormous prolapse, and a conservative estimate was made at the time of the operation that the abdominal gap would easily correspond to the size of an adult head.

Operation. The main principle of the operation is to close the gap chiefly by approximating the refreshed edges of the sheath of the rectus, tension being relieved by releasing incisions parallel to the line of suture on either side. This procedure is exactly similar to the operation for closure of cleft palate according to Langenbeck, by double pedunculated flaps.

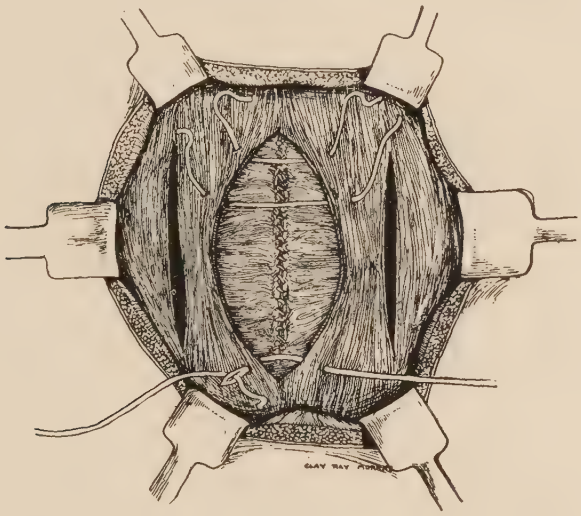

Fig. 1.—Releasing incisions in the fascia of the rectus muscle parallel to the line of suture.

The operation is long and tedious. Before the abdominal incision can be closed the herniated contents of the sac must be properly separated and reduced. The closure is made in layers: first, peritoneum which usually does not present any great difficulty. The next layer is usually quite deficient, as the muscles have disappeared, either from the original suppuration and sloughing or from atrophy. However, as much tissue as can be sutured under the fascial layer is secured. The releasing incisions can be made before or after the suturing of the refreshed

fascial edges. In extreme cases it must be made before. The width and length of the fascial flap can be determined by the conditions of tension. One must have the courage of one's conviction and extend the releasing incisions sufficiently to take off all undue tension. Ordinarily the flap of fascia would be about two inches wide. The greatest difficulty in making these flaps is in cases of hernia through the upper midabdomen, where the releasing incisions have to be carried on to the costal arch. Chromic catgut, mostly interrupted, sutures have been used for

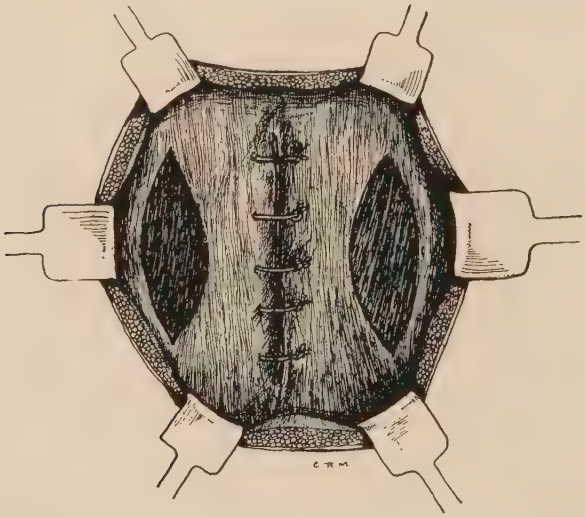

FIG. 2.—Edges of fascia reunited in midline without tension.

the fascial closure. These sutures may be sometimes reënforced to advantage by passing some silkworm-gut through all the layers superior to the peritoneum.

Experience has shown that most of these wounds do not heal by primary union, and a certain amount of discharge, usually non-purulent, is to be expected. It is possible that this accident is caused by spots of necrosis due to too great tension on the fascial sutures. Therefore the superficial wound should be appropriately drained. Notwithstanding this complication in

wound-healing, none of these cases seems to have been injured as far as regards curative results.

My experience comprises eight cases. The ninth case, done according to the technic described here by one of my colleagues in my service, did not survive, succumbing to operative shock and paralytic ileus. Of the remaining eight cases only No. 8, the severest, has shown any signs of recurrence. Case No. 5 is particularly interesting, as the patient had been subjected to numerous operations for an abdominal hernia which developed sixteen years prior to my intervention and had worn a filigree for five years, which had successfully overcome the hernial protrusion for four years.

The surprising feature in the after-results of these cases is the lack of weakness of the abdominal wall where the fascia gaps as the result of being pulled away. I had feared originally that there would be more trouble from possible protrusion at this point than of recurrence of the hernia, but with the exception of the case noted no trouble has developed.

Case I.—I. F., female, aged thirty-four years.

First Operation. February, 1912. Operation for appendicitis.

Second Operation. April 14, 1913. Resection of 20 inches of ileum and anastomosis with Murphy button, for intestinal obstruction. At discharge, June 14, 1913, wound was closed save for a small spot at lower angle.

Third Operation. February 24, 1914. Hernia appeared three months previously (November, 1913). Operation for ventral hernia complicated by chronic adhesive peritonitis. Several feet of intestines unravelled. Wound healed by primary union save where hematoma had formed, broken down and discharged. Discharged March 20, 1914.

Follow-up Notes. June 10, 1914. Abdominal wound firm. No suspicion of bulging in the wound or elsewhere in the abdomen. February 1, 1920. Excellent condition.

Case II.—N. W., male, aged thirty-nine years.

First Operation. Cholecystostomy for cholelithiasis, February 13, 1915. Complicating operation patient had an acute bronchi-

tis and in coughing stiches yielded. Large hernia has formed in scar.

Second Operation. October 9, 1915. On ninth postoperative day wound was found infected. On tenth postoperative day free

FIG. 3.—Case 11 *A*. Taken September 28, 1915.

discharge of bile, probably coming out of sinus in the midline. Union of fascia and muscle for the most part seems firm, bulk of wound having escaped infection. On twenty-third postoperative day still profuse biliary discharge. Hernia operation seems to

have held; condition excellent. On thirtieth postoperative day discharge markedly decreased. Abdominal repair seems to be firm. On thirty-ninth postoperative day patient was discharged. (November 17, 1915.) Wound healed by primary union save at

FIG. 4.—Case 11 *B*. Taken January 5, 1917.

upper angle, where wound opened to allow escape of biliary discharge, now slight in amount.

Follow-up Notes. January 3, 1916. Discharge has returned. No impairment of abdominal wall.

May 16, 1917. Wound firmly healed. Excellent condition.
May 31, 1919. Excellent condition. No recurrence.

FIG. 5.—Case III. Photograph taken April 1, 1916.

CASE III.—L. P., male, aged nineteen years.

First Operation. June 12, 1913. Appendectomy and drainage for acute appendicitis. Hernia developed two weeks after discharge. Has gradually increased in size until protrusion is now the size of two fists.

Second Operation. April 3, 1916. Convalescence delayed by superficial hematoma. Discharged on thirty-eighth post operative day. Skin edges still separated. No impulse on coughing.

Follow-up Notes. October 26, 1916. Wound firmly healed. No impulse. January 10, 1917. Excellent condition. Gaining flesh. Scar firm. February 27, 1919. Excellent condition.

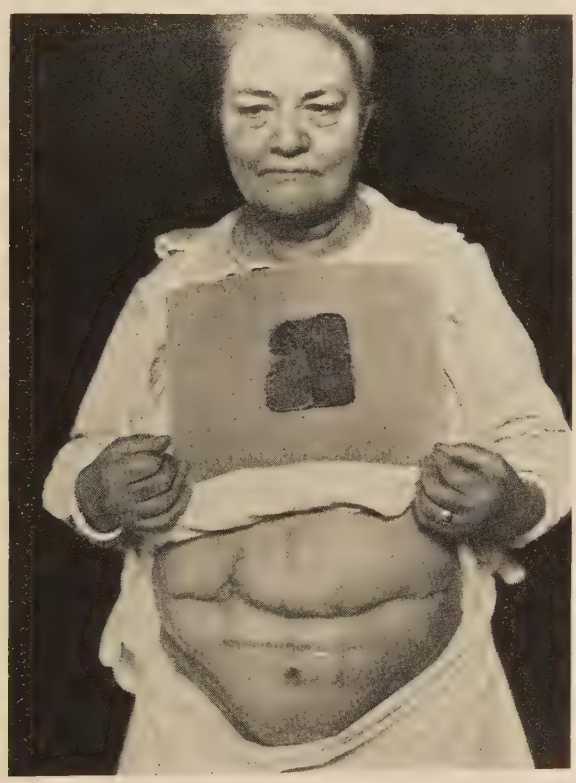

FIG. 6.—Case V. Taken March 30, 1920, showing filigree removed at fourth operation.

CASE IV.—J. F., male, aged sixty years.

Hernia not postoperative. Has had ventral hernia for over four years. Came out gradually. Is now about the size of a fist. Strong impulse on coughing.

Operation, July 26, 1918.
Discharged August 13, 1918. Wound healed primarily.
Follow-up Notes. March 6, 1920. No recurrence.

FIG. 7.—Case V. Taken March 30, 1920.

CASE V.—C. S., female, aged fifty-one years.

First Operation. October 16, 1902. For epigastric hernia.

Second Operation. August 15, 1912. Repair of ventral hernia.

Third Operation. September 8, 1913. Repair of ventral hernia, with insertion of wire filigree (local anesthesia).

Fourth Operation. Readmitted October 29, 1918. One year ago patient noticed bulging to the left of the old ventral hernia

repair scar. Wire broke through skin about one-half inch, about six weeks before this admission. Some of the wire was removed. Has pain at site, especially on coughing. Filigree removed under local anesthesia on October 31, 1918. November 23, 1918. Operation for repair of ventral hernia. Thirty-eighth postoperative day wound explored under ether. Skin tunneled along line of incision. Involved area widely converted into one large wound, which was packed with balsam gauze. Fifty-first postoperative day allowed up. Sixty-ninth postoperative day still has a small granulating area. Hernia apparently cured. No impulse or bulging on coughing. Abdominal wall firm at site of former hernia. Patient discharged.

Follow-up Notes. May 1, 1919. Firmly healed. Excellent condition. March 30, 1920. Excellent condition. No recurrence.

Case VI.—M. M., female, aged fifty years.

First Operation. December, 1901. Left salpingectomy for ectopic gestation.

Second Operation. December, 1902. Laparotomy through old scar. Right salpingo-oöphorectomy for salpingo-oöphoritis. Convalescence complicated by fecal fistula.

Third Operation. Readmitted July 7, 1919. Hernia appeared eight or nine years after last operation (1910 or 1911). Two lumps, size of orange, one at each end of incision. Has worn belt ever since she first noticed them. Operated July 8, 1919. Discharged August 10, 1919. Wound healed by primary union.

Follow-up Notes. June 1, 1920. Excellent result. No bulging.

Case VII.—B. W., male, aged fifty-eight years.

First Operation. One year before second operation. Extensive operation for cholelithiasis. Wound broke down and hernia developed two months later.

Second Operation. Examination: Very large individual. Ventral hernia size of child's head at term through scar in midline, reaching from umbilicus to ensiform. Operation May 23, 1919. Operation attended with much difficulty, lasting two hours and a half.

Follow-up Notes. August 1, 1919. Patient writes that he is exceedingly well. Later but indirect reports indicate continuance of good result.

FIG. 8.—Case VIII. Taken November 23, 1919.

CASE VIII.—M. Z., male, aged forty-eight years.

First Operation. 1914. Operation for gall-stones

Second Operation. 1916. Operation for ventral hernia which, appeared six months after last operation.

Third Operation. 1918. Operation for recurrent ventral hernia. Hernia appeared three months after last operation.

Fourth Operation. November 26, 1919. On twenty-sixth postoperative day there was considerable discharge. There is a

sinus which extends upward and to the left. Counter incision made. Drainage. Fortieth postoperative day discharge stopped. Small sinus at either angle. Forty-sixth postoperative day, discharged.

FIG. 9.—Case VIII *B*. Taken April 15, 1920.

Follow-up Notes. February 26, 1920. General bulge but apparently not a recurrence as yet. March 22, 1920. Little recurrence in midline and some bulging without protrusion at site of releasing incision on left side.

DISCUSSION

Dr. Authur A. Law, Minneapolis:

We have had the same unhappy experience exhibiting the filigree silver screen in ventral herniæ as those mentioned by the author of this paper. Our experience with all methods of restoration in these vast postoperative herniæ was so unsatisafactory that in the cases of extreme diastasis and atrophy of the recti muscles from overstretching and an accompanying atrophy and fatty degeneration of the abdominal wall aponeuroses, we were led to try a method, which, in seven instances has proved eminently successful, namely the transplantation of large sheets of fascia lata.

In these great herniæ, where so much of the bowels lie without the abdominal cavity and have lost their habitat, after their return to the abdomen the increase of abdominal pressure is so extreme we have not felt secure depending upon the Mayo imbrication method alone so have reënforced these imbrications with large sheets of fascia tacked down over the repair. In one instance a fascial transplant of approximately nine inches square was used. We know perfectly well that according to Roux's law, that unless an autotransplant is given specific work to do it does not retain its identity. In experimental research upon the lower animals, we found that the fascial graft in the abdominal wall, lacking specific work to do, lost its identity as fascia lata and degenerated into a thick layer of connective tissue, which, however, very well reënforced and supported the weak abdominal wall. While our work was done in a charity clinic where the follow-up system has not been followed, we have not, however, heard of failures following the use of this method, so suggest it as giving an ultimately good result in these herniæ.

Dr. Vilray P. Blair, St. Louis:

In connection with the idea of a transplant of fascia I want to cite a case. It was for a hernia in which there was also an intestinal fistula and a large fascia lata transplant was made. The superficial part of the wound broke open and for about eight weeks several inches of the transplant was visible, first turning yellow then giving off granulations and the wound healed. Three years later I heard of the case and the hernia had not returned.

Dr. Leonard Freeman, Denver:

For a number of years I have used fascia lata in operations upon large ventral herniæ, obtaining the idea from a foreign publication

the author of which advocated its immediate use in every case of bad postoperative hernia owing to the danger of recurrence if other methods are employed. I have come to believe that this is the proper thing to do unless the operation suggested by Dr. Gibson answers a better purpose. Fascia lata does not stretch, it grows in anywhere, and one can get any quantity of it without serious injury to the thigh. Experiments have even been carried out in which the whole abdominal wall of a dog has been replaced by fascia lata with a firm and satisfactory result. I have operated in this way many times and I know of but one failure, and this followed sloughing of the fascia from infection. I am convinced that in cases of bad postoperative hernia it often is better to proceed to the use of fascia lata at once rather than to risk failure by other methods.

Dr. Miles F. Porter, Fort Wayne:

I should like to ask if after making the vertical incision on either side of the opening it is usually possible to bring the split margins forming the hernial ring together? Would it not often be possible to prevent infections and sloughing in transplanted fascia, whether fascia lata or not, by making numerous perforations into it with a view to permitting the union of granulations from either side and relieving tension, thus increasing its powers of resistance while at the same time its powers of reproduction are stimulated?

Dr. William B. Coley, New York City:

I have had a considerable experience in operating upon large herniæ at the Hospital for Ruptured and Crippled, and we never use the wire filigree because we have observed the bad results in so many cases operated upon by other surgeons. Personally, I believe there are few cases that cannot be cured by the overlapping of the vertical incision, or by the Mayo method, transverse overlapping. There is a considerable group in which it is unwise to undertake any operation, and Dr. Gibson has found this limit. If you find a hernia so large that when you try to reduce it there is no place in the abdominal cavity to put it, you have reached the limit of operability. It is surprising how large a hernia can be cured by simple overlapping of the fascia and muscles. Sixteen years ago I assisted Dr. Bull in operating upon a very large ventral hernia, which was larger than an adult head. By overlapping the fascia we got a good closure and the patient is well without recurrence today. I cannot speak too strongly against the use of the filigree wire in these cases. As regards the fascial transplant, I have had no experience.

Dr. E. Wyllys Andrews, Chicago:

Dr. Gibson did not emphasize the fact that in the case of ventral hernia not reduced the patient will die of intestinal obstruction. The operation therefore becomes a necessity for life.

Dr. Astley P. C. Ashhurst, Philadelphia:

I want to call attention to the advice years ago of Sir Astley Cooper regarding the preliminary treatment in cases of large irreducible herniæ. It is to put the patients to bed, raise the foot of the bed, keep the patients on a light diet until they begin to get thin, then the hernia will be spontaneously reduced. Then the abdominal wall can be closed without difficulty.

Dr. Theodore Tuffier:

I have operated on a large number of cases of weak cicatrices of the abdominal wall, the operation comprising two distinct steps: one, the resection of all of the cicatrix as far as the normal structure of the abdominal wall; the second, the peritonization of the intra-abdominal adhesions which are a constant feature of these cases.

1. For the resection of the wall I remove all of the cicatricial tissue as far as the point where I find the different planes which constitute the normal anatomical arrangement.

2. The intestino-parietal adhesions are suppressed, and the perfect continuity of the intestinal peritoneum is reëstablished. For this purpose I divide the parietal peritoneum beyond the point of adhesion to the bowel at a variable distance, according to the extent of the adhesions, obtaining in this manner a collar of peritoneum; I then mobilize completely the intestine as far as the point of contact with it, and then turn the collar of peritoneum derived from the wall over the raw surface of the bowel, and suture it in such a manner as to completely cover the bowel with normal peritoneum. The gap in the parietal peritoneum is restored by suture, so that at the completion of this stage its continuity is reëstablished, and the visceral peritoneum is perfectly free.

The problem is often more difficult on account of the adhesions between the loops of bowel or between the peritoneum and the omentum. It is not possible then to practise the complete operation, and I have been in the habit of using liquid paraffin over the freed and raw loops of gut, of the value of which I cannot speak.

3. I reconstruct the abdominal wall by separate suture of each of the anatomical layers.

One precaution it is necessary to take in cases where one has to

deal with stout subjects, especially very fat women, and that is to make them reduce, either before or after operation, as in this manner one diminishes the abdominal tension, and obtains a better cicatrix. Some twenty years ago I operated on a case in which I neglected this precaution, and the patient took on a considerable amount of fat afterward, so that a second operation was necessary, at which I found small hernias of the subperitoneal fat had traversed the scar. After the operation the patient was placed upon an appropriate regimen, lost her fat and remained cured.

Dr. George E. Brewer, New York City:

I should like to ask Dr. Gibson if in the lateral incisions he always expects to find muscle? If he does not find muscle then what procedure does he adopt?

Dr. Charles L. Gibson, New York City (in closing):

I should like to make it perfectly clear that this operation does not compete with any other operation for ventral hernia. It only competes with no operation at all—I use it in those patients whom a few years ago I would have abandoned. Regarding Dr. Brewer's question as to what you do if there is no muscle, I should say that you have to take whatever offers. As stated in the paper, I had expected disaster for leaving these thin walls without muscle covering, but with the exception of the last case which has some recurrence, there has been no other evidence of a lateral bulge to my knowledge.

TRAUMATIC FAT NECROSIS OF THE FEMALE BREAST AND ITS DIFFERENTIATION FROM CARCINOMA: WITH A REPORT OF TWO CASES

By BURTON J. LEE, M.D.
AND
FRANK E. ADAIR, M.D.
NEW YORK

The subject of this report is to briefly set before you the clinical, operative and pathological findings of two cases of traumatic fat necrosis of the breast, recently encountered at Memorial Hospital. Although much has been written concerning the differentiation between the benign lesions and mammary carcinomata, a careful search of surgical and pathological literature has failed to reveal any reference to this subject, for it has apparently hitherto been unrecognized.

We have the hope that the data presented and the discussion stimulated by the study of these two cases may result in a better understanding of the clinical and pathological aspects of this subject and lead to its more accurate diagnosis in the future.

Clinically the simulation of carcinoma is very startling, and we desire to place special emphasis upon this point. In one of the cases, a radical amputation of the breast, muscles and axillary contents was performed, the operator believing that the tumor was malignant. In the other patient only local removal of the mass was practised at first, but gross examination of the cross-section, in the operating room, led one of the writers to a diagnosis of carcinoma, which was confirmed by another surgeon, but not concurred in by a third. The breast was

removed, but the muscles were not sacrificed. A more careful analysis of the gross and microscopic appearances made the real character of the lesion apparent.

CASE REPORTS

CASE I.—E. B. The woman was a white, native-born American, aged fifty-two years, and was a widow. She was admitted to the Memorial Hospital August 29, 1919.

Chief Complaint. A growing mass of considerable size in the right breast.

Family History. Negative for carcinoma.

Past History. Previous illnesses: She was operated upon at the Memorial Hospital, six years previously, for an abscess of the right side of the neck. She had had several miscarriages. Her past history was otherwise negative.

Breast History. She had had no lactations and there had never been any ailment with either breast.

Present Illness. In May, 1919 (three months before her admission to the hospital), she received a definite trauma to the right breast. This occurred while she was sitting in a street car. A woman carrying a child fell heavily against the patient, delivering a severe blow, with her elbow, against the right breast. This incident was not followed by tenderness or pain. Three months later (three days before her admission to the hospital) the patient noticed a lump, about the size of a lime, at the site of the former injury, in the upper outer quadrant of the right breast. This mass has been unassociated with pain.

Physical Examination. The patient was a well-developed, well-nourished white woman, weighing about 190 pounds. Her general physical examination was negative, with the exception of the lungs, which showed on percussion slightly increased dulness between the scapulæ, together with a few scattered sibilant rales. Roentgen-ray examination of the chest showed no evidence of tuberculosis or metastasis. The Wassermann was twice reported negative.

Breasts: The mammary glands were of large type. A tumor was present in the upper outer quadrant of the right breast, measuring about 5 by 4 cm. There was no retraction of the nipple, nor was there any discharge from it. The mass showed moderate fixation to the skin, with some slight surface dimpling. There was some attachment to deeper structures. No axillary or supraclavicular nodes were palpable. The left breast was normal.

Provisional Diagnosis. Primary carcinoma of the right breast.

Operation. On September 23, 1919, the right breast, muscles and axillary contents were removed by Dr. Bolling.

Pathological Examination. Gross Examination. Three centimeters above and outside of the nipple, situated in the breast was a tumor mass 2 cm. in diameter, irregular, circumscribed, but not encapsulated. It merged along one border with the fat tissue and elsewhere with the breast tissue. The tumor was opaque, brownish yellow, as in a xanthoma, and there was irregular hyperemia along the upper edge. The growth lacked definite cicatricial character and chalky streaks.

The whole breast was uniformly fibrosed and contained no cysts. The axillary nodes were slightly enlarged and apparently not cancerous.

Microscopic Examination. Sections showed broad areas of fat necrosis, surrounded by a broad zone of new cellular connective tissue, in which large vessels showed active obliterating endarteritis. Along certain segments of necrotic areas there was granulation tissue containing several large giant cells. A search for spirochetæ in the tissues was negative.

The patient was discharged from the hospital, October 1, 1919, eight days after operation, having had an uneventful convalescence.

Subsequent Notes. The patient was readmitted on November 10, 1919, because of persistent hemorrhage from the vagina. Examination revealed a small bleeding-point on an otherwise normal cervix. On either side of the vaginal vault were fungoid epithelial growths and half-way down the posterior wall was another small tumor.

Sections taken from the vaginal growths were reported to be basal-celled carcinoma.

The patient was treated with radium by Dr. Bailey, and is still under his observation.

March 31, 1920, no evidence of disease in the vagina and cervix was apparent. The final outcome of the vaginal tumor will have to be subsequently reported.

Dr. Ewing has stated that the vaginal growth bears no relation of any sort to the traumatic fat necrosis of the breast, but these data are included as a part of the follow-up history of the case.

CASE II.—R. R. The woman was a Roumanian, aged thirty-six years, and was married. She was admitted to the Memorial Hospital January 15, 1920.

Chief Complaint. A lump in the right breast, which was steadily increasing in size.

Family History. Negative for carcinoma and tuberculosis.

Past History. Occupation: housework. Habits: abstemious. Weight: her usual weight was 211 pounds, and this was approximately her weight at admission.

Previous illnesses: She had always been well, with the exception of two extra-uterine gestations, both of which necessitated operative procedure.

She had never had any miscarriages.

Her past history was otherwise negative.

Breast History. There had been three lactations: the first one fifteen years ago, the last one four years later, the duration of each having been about a year.

The nipples had always protruded.

There had never been any unusual breast incident during her nursing period.

Present Illness. June 22, 1919 (about seven months before her admission to the hospital), her last operation for ectopic pregnancy was performed. Pleurisy and pneumonia developed and she became dangerously ill. She was given a hypodermoc-

lysis under the right breast, three quarts of saline being introduced. No unusual pain was associated with this administration. One month later (six months before admission) she first accidently noticed a small lump, the size of a walnut, in the upper and inner part of the right breast at the site of the previous injection. This mass had caused no pain whatever, but had been steadily increasing in size.

FIG. 1.—Traumatic fat necrosis. Gross appearance.

Physical Examination. The patient was a robust, middle aged woman, of unusually large build. Her appearance indicated perfect health. The general physical examination was negative. The lungs were clear throughout and fluoroscopy of the chest was negative.

Breasts: Large and pendulous. The left breast was normal. The right breast showed no retraction of the nipple, nor was there any elevation of it. About 3 cm. to the inner side of the right nipple was a mass, 3 by 2 cm. in diameter, making it approximately the size of a small hen's egg. The tumor was roughly cylindrical, fairly sharply circumscribed, and had a

FIG. 2.—Traumatic fat necrosis. Gross appearance.

distinct firm edge. The mass was hard in consistency. It lay just beneath the skin on the upper inner aspect of the breast, near its posterior surface. The tumor showed slight skin adherence, but was, however, movable in the breast and not attached to deeper structures. There was one small soft lymph node in the right axilla.

Provisional Diagnosis. The provisional diagnosis was carcinoma of the breast, although the circumscribed character of the mass suggested the possibility of a benign adenoma.

Preoperative Treatment. The patient received the usual preoperative roentgen-ray cycle for the chest, breast, axillary

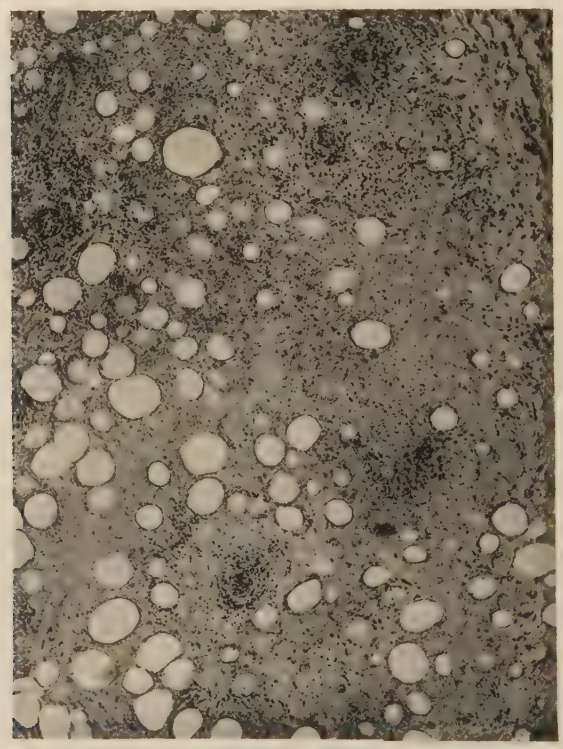

FIG. 3.—Microscopic appearance, showing endarteritis and periarteritis; also fat cells and area of necrosis.

and supraclavicular regions, the cycle being completed on January 21. Operation was performed nine days later.

Operation. Under ether anesthesia a local excision of the tumor was made through the anterior aspect of the breast, going well wide of the involved area. This local excision was done

because the mass was so sharply defined that it seemed possible that malignancy might not be encountered. The tumor was immediately sectioned after its removal, and was found to consist of two sharply outlined solid areas, while between them lay a

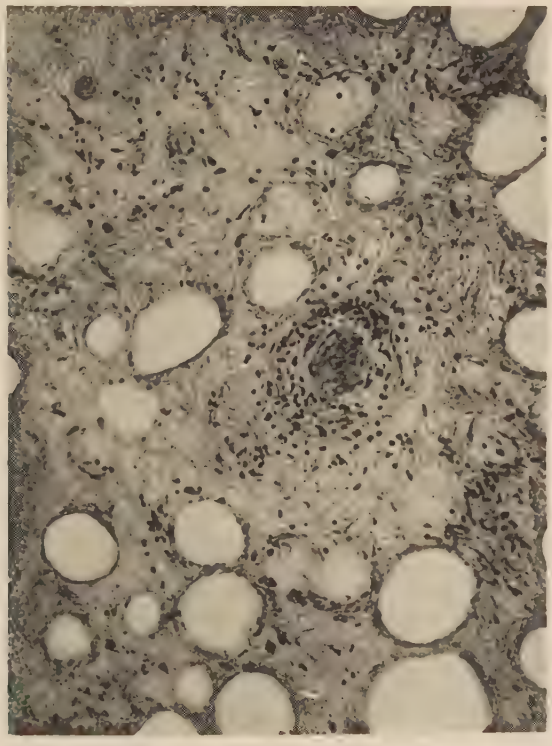

FIG. 4.—Microscopic appearance, showing enlarged view of Fig. 3. Shows fat cells dividing and poise of saponification in many fat cells, also some necrosis.

small cavity containing thick, oily fluid. As the knife passed through the solid tumor tissue one had the same impression of cutting a hard, granular substance, that one experiences in sectioning a carcinoma. Although none of the minute yellow points so frequently seen in carcinoma could be distinguished,

its extreme hardness made us feel fairly certain that the case was one of cancer of the breast. Another surgeon present concurred in this gross diagnosis. However, Dr. Stone did not believe the tumor was carcinomatous.

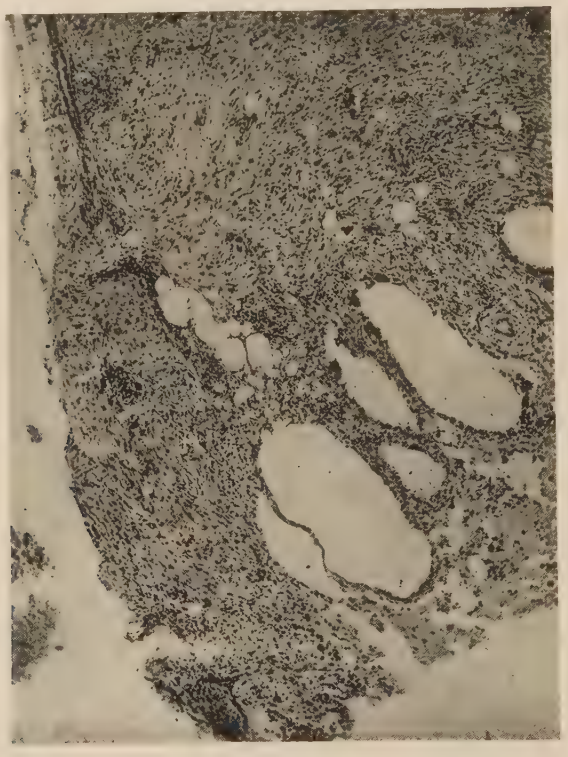

FIG. 5.—Microscopic appearance, showing productive inflammation; giant cells along tissue spaces containing liquified fat.

An amputation of the breast was then performed down to and including the fascia covering the pectoralis major muscle. The muscles themselves and the axilla were not disturbed. Further operative procedure was to depend upon the report of the pathologist.

Postoperative Diagnosis (by the Operator). Carcinoma of the breast. Following the operation the operator was considerably

concerned about the outcome of the case, having a fairly definite conviction that a more radical operation should have been performed. He was therefore very anxious to learn the result of the gross examination, anticipating criticism of the incompleteness of the operation. He was greatly surprised, however, to be told

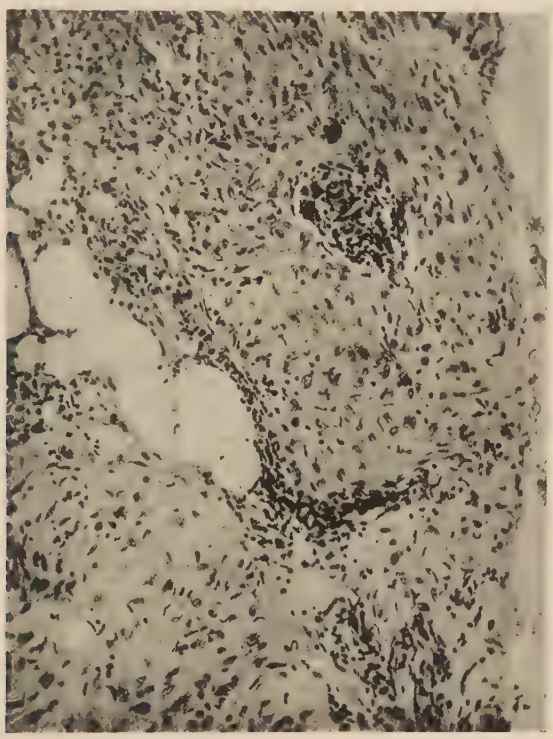

FIG. 6.—High-power picture of Fig. 5.

that the breast itself should not have been removed, that local excision of the tumor was all that had been indicated and that the lesion had no malignant features.

Pathologic Examination. Gross Examination. There was an indurated area, 2 by 1 by 4 cm., slightly cicatricial, not quite hard enough for carcinoma; well circumscribed, almost entirely

encapsulated, apparently a fat lobule, which suggested a tumor process. On cross-section the texture was opaque, xanthomatous and light yellow in color, not translucent, without definite chalky or silvery points. Adjoining was a smaller fat lobule, with a few similar slightly opaque points. Adjoining also was a

FIG. 7.—Microscopic appearance, showing productive inflammation about fat cells.

cyst, 1 cm. wide, containing creamy contents, having a smooth blood-stained wall.

Gross Diagnosis. Chronic inflammation in fat tissue. The remainder of the breast was normal.

Microscopic Examination. The structure of the lesion showed chronic productive inflammation in fat tissue. There were no

evidences of carcinoma. The fat cells were proliferating, replacing fat, and many small giant cells were present. There was much diffuse new fibrous tissue, which accounted for the opacity. In places there were collections of lymphocytes and occasionally a few cysts. The large cyst was lined by large epithelial cells

FIG. 8.—Microscopic appearance. High-power picture of Fig. 7.

of the sweat-gland type. A few accompanying breast alveoli showed round-cell infiltration.

There was no unusual incident in the patient's convalescence.

Incidence. At the Memorial Hospital the ratio of traumatic fat necrosis of the breast to mammary carcinoma is as 2 to 330, or 0.6 per cent.

Pathology. In our study of the pathology presented in these two cases we are greatly indebted to Dr. James Ewing, pathologist at Memorial Hospital, and he has outlined the following points in the gross examination of traumatic fat necrosis of the breast.

FIG. 9.—Traumatic fat necrosis. Gross appearance.

Gross Appearances. The differential diagnosis of the gross lesions in these two cases presented an interesting problem. A careful study of the details of the naked-eye appearance led to the conclusion that in neither case was the lesion carcinomatous.

In the case of E. B., the presence of a rather large area of opaque discolored fat tissue, nearly diffluent in the center, was

satisfactory evidence that the chief material was necrotic fat. This area along one side was sharply demarcated from normal fat tissue, as is infiltrating mammary cancer; but this zone failed to show the positive signs of carcinoma, such as cicatricial contraction, grayish luster and fatty and chalky points and streaks.

FIG. 10.—Microscopic appearance, showing new connective-tissue production about spaces containing fluid fat.

Likewise the rather broad zone, 2 to 3 cm., of cellular granulation tissue did not present the form, outline or texture of carcinoma. Accordingly a gross diagnosis against a neoplastic process was rendered.

In the case of R. R. the gross diagnosis was more exacting, but

was accomplished by careful adherence to the criteria of gross anatomical diagnosis of mammary cancer. Here there was one separate area, 2 x 2 cm., of necrotic fat, which was readily recognized. A second area presented greater difficulties. This was an oval area 2 x 1 cm., firm and cicatricial in appearance,

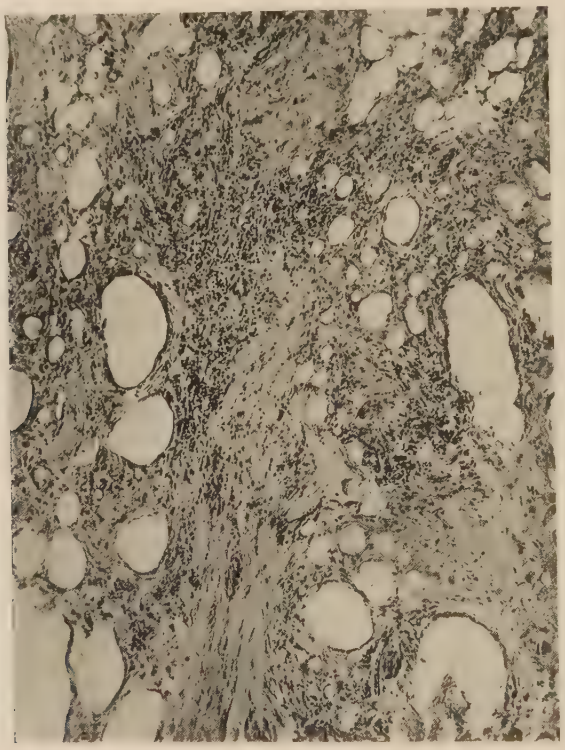

FIG. 11.—Microscopic appearance, showing giant cells growing about tissue spaces containing difficult fat, also new connective-tissue production.

with xanthomatous texture and considerably resembling carcinoma. However, it was observed that this area was fairly well encapsulated; that in size and form it was exactly similar to the adjoining fat lobules; and that it did not present the smooth opaque texture of carcinoma nor the chalky points or streaks.

On these data the diagnosis of chronic inflammation of fat tissue was given. Paraffin sections revealed a productive inflammatory process with multiplication of many cuboidal fat cells lying in alveoli, which would have been difficult to distinguish from alveolar carcinoma in a frozen section.

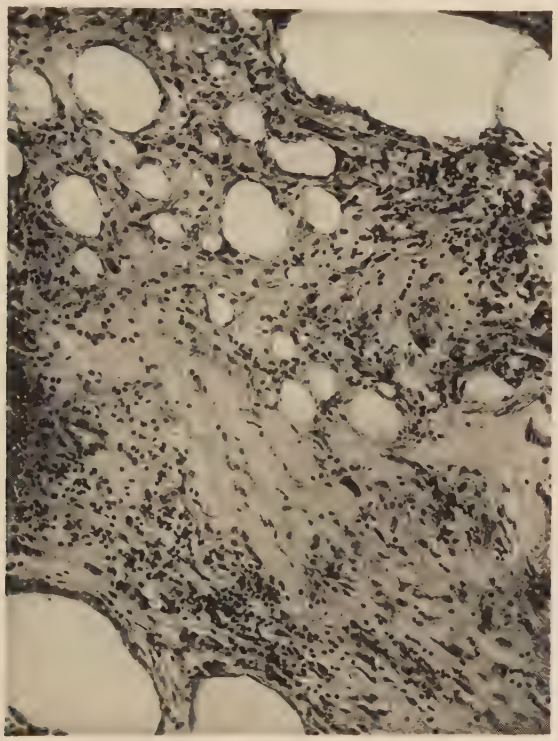

FIG. 12.—Microscopic appearance of high-power picture of Fig. 11.

Microscopic Appearances. Areas of necrosis in fat tissues were to be seen with new connective-tissue cells, growing in and about these areas of necrosis. This growth of new tissue was very abundant, and with the giant cells which one saw scattered throughout the tissue a luetic granuloma might superficially be suggested. Many of the giant cells were markedly flattened, the syncytial tissue being closely applied

along the borders of huge vacuoles, which corresponded to large tissue spaces containing diffluent fat. These giant cells were, therefore, of the so-called foreign-body type. Certain portions of the sections show proliferation of the nuclei of fat cells, these same cells showing also an opaque zone close to the periphery of the cell, probably representing certain changes in fat saponification.

The bloodvessels show an obliterating endarteritis which was apparently of recent origin and a perivascular infiltration with lymphocytes.

Diagnosis. Trauma appears to be an essential and distinctive etiological factor in connection with fat necrosis of the breast. A history of the appearance of a mammary tumor with no preceding definite trauma would practically eliminate fat necrosis as a possible diagnosis. Although trauma is not infrequently encountered in the history of a mammary cancer, it is often indefinite and frequently absent. A recent exception to this rule was met in a young woman, aged twenty-six years, who received a terrific blow upon the breast by a hard-hit baseball. Six months later she developed, at the exact site of the injury, an encapsulated papillary-cyst-adeno-carcinoma of the breast. It is well known that this particular type of cancer is one of the less malignant varieties. In general, however, the surgeon should weigh carefully the evidence of distinct trauma to the breast and remember the possibility of a fat necrosis and the secondary chronic inflammatory changes attending it.

Simultation to Carcinoma.

Clinically, traumatic fat necrosis of the breast very closely simulates mammary carcinoma and the differentiation may be very difficult. The symptoms of fat necrosis which strongly suggest malignancy may be enumerated as follows:

1. *Rapid Increase in Size.* The mass of traumatized fat increases rapidly because of the proliferation of new connective tissue associated with the chronic inflammatory process. A

period of several weeks or months may elapse from the time of the receipt of the injury to the appearance of the tumor; and from that time on the increase in size strongly suggests the possibility of malignancy.

2. *Skin Adhesions.* Both the patients under report exhibited the same skin adherence which one sees in many cases of malignant disease of the breast. The tumor mass seemed held to the skin by several lines of adhesion and gave the impression of a solid tumor with superficial surface closely adherent to overlying skin. This feature so often regarded as pathognomonic for malignancy was striking in both instances.

3. *Consistency.* The consistency of the tumor in each instance was as hard as in the average case of malignancy. Although some of the benign fibro-adenomata are very hard, the two characteristics above mentioned are lacking in this type of growth. Upon the other hand one must bear in mind the exceedingly soft, brain-like encapsulated carcinomata which are the most malignant of all types of mammary cancer. In general, hardness in a breast tumor suggests malignant possibilities, and traumatic fat necrosis with the reaction attending it produces a distinctly hard mass.

4. *Lack of Pain.* No pain was experienced in the cases of fat necrosis. This gave an exact parallel to malignancy, because tumors of the latter type in their early stages exhibit an entire absence of pain. Only in the later, more advanced periods does a cancer of the breast cause pain.

5. *Adherence to Deeper Structures.* One of the patients showed definite fixity of the tumor to the underlying muscles. This symptom is almost invariably regarded as a sign of malignancy, and its presence, therefore, strongly influenced the surgeon in reaching a diagnosis of malignancy.

Differentiation from Carcinoma.

The points of differentiation from malignant disease may be outlined as follows:

1. The history of trauma is more exact and definite than with the average carcinoma.

2. The tumor in fat necrosis is fairly well circumscribed, while the mass in carcinoma is usually more diffuse.

3. The tumor is rather more movable in the breast than is usual with carcinoma.

4. Axillary nodes if present have not the hard consistency of those associated with cancer. This differential point would, of course, be of no value in a very early mammary cancer without metastasis in the nodes.

5. The characteristic gross appearances of fat necrosis upon cross-section of the tumor have already been outlined under the paragraph on Pathology.

Discussion. Several points worthy of discussion may briefly be referred to:

In connecting the appearance of a tumor with a history of trauma one should bear in mind the four medicolegal points usually required:

1. The history of trauma must be sufficiently definite and of a severity adequate to produce the tissue damage.

2. The site of the trauma and the location of the lesion must be identical.

3. A proper time relationship must exist from the receipt of the trauma to the appearance of the tissue changes.

4. Proof should be at hand that the tissue was normal before the receipt of the trauma.

All of these requirements, save the fourth, are met in the cases of fat necrosis, and it is obviously impossible to fulfill the fourth requirement.

When the wide distribution of subcutaneous fat is considered one may well ask the question, does fat necrosis from traumatism ever occur in this tissue? Our colleague, Dr. Farr, of the New York Hospital, has completed a paper, about to be published in which several cases of traumatic fat necrosis in subcutaneous tissues are reported. Boxers and wrestlers must be subject to a tremendous number of traumatisms to the superficial fat. It seems

probable that some defensive mechanism must exist to prevent the development of necrosis in fat tissue following trauma. In the cases in this report it seems fair to assume that some peculiar conditions may have been present, permitting the trauma to bring about the lesions described.

In the first case lues might be thought of as a possible etiological factor, on account of the miscarriages, the granulomatous appearance of the tissue and the obliterating endarteritis. However, two Wassermanns in expert hands were negative and a careful search for spirochetes failed to reveal any organism.

The second patient showed nothing in the tissues quite comparable to the extensive granulomatous changes found in the first patient, and here syphilis could be dismissed at once.

We feel, therefore, that a luetic element in these cases may be positively dismissed as having no bearing upon the pathology of this disease.

Conclusions. 1. Traumatic fat necrosis of the female breast is a definite clinical entity.

2. It must always be included with the benign lesions of the breast.

3. Clinically it more closely resembles carcinoma of the breast than any other tumor, and must be differentiated from it.

4. A distinct history of trauma to the breast and a well-circumscribed, firm mass, showing rapid increase in size, unassociated with pain and without axillary nodes that are firm, suggest the possibility of fat necrosis.

5. Local removal of such a mass is justifiable if a proper gross diagnosis can be made in the operating room. Should the gross examination reveal carcinoma, complete amputation may then be performed.

6. The diagnosis of traumatic fat necrosis of the breast by gross examination is possible. The gross features of this lesion should therefore be clearly understood by every surgeon.

7. Further lines of research, along chemical as well as along morphological lines, may throw additional light upon the real nature of this process.

THE REQUIREMENTS OF TECHNIC IN OPERATIONS FOR CANCER OF THE BREAST

By JABEZ N. JACKSON, M.D.
KANSAS CITY, MO.

The primary object of an operation for cancer should be the permanent cure, if possible, of that cancer. This purpose should never be lost sight of.

Essential Principles. In the accomplishment of this purpose two primary principles present themselves:

1. The operation must be sufficiently thorough to ensure the complete removal of all probably infected tissues within the limits of reasonable surgical access.

2. Dissemination of the infection during the operation must be guarded against; likewise contamination of the wound with liberated cancer cells which may be left to regraft the disease.

In the evolution of a surgery which will fulfil these demands in cancer of the breast, the pioneer work of American surgeons such as our Fellows, Prof. Halstead and Willy Meyer, has largely blazed the way. Their work, based on accurate knowledge of the pathology of cancer and its routes of extension, supplemented by the later studies of the English surgeon Handley, has pretty well standardized the extent of resection required.

Extent of Operation. The standard excision of today, therefore, involves the following:

1. *Skin.* A wide area of skin covering the breast. In this respect American surgeons are inclined to go rather farther than the English. Many insist on the complete removal of the entire skin over the mammary gland. The English surgeons, as a rule, demand less skin removal, but insist on an extensive deeper resec-

tion. At least a wide area surrounding the underlying focus of infection must be removed. With present methods, complete ablation can be followed with equally satisfactory subsequent management.

2. *Mammary Gland.* The entire mammary gland must, of course, be removed. It is well to remember there are often outlying lobes, and these must not be overlooked.

3. *Pectoral Muscles.* It has been pretty fully demonstrated that lymph vessels containing cancer cells may be found running through the pectoralis major muscle and between the two pectorals. These muscles should therefore be included in the ablation. The clavicular portion of the pectoralis major is probably free from suspicion, and for good reason is by many not sacrificed. Its retention particularly saves a very troublesome vacant space just below the clavicle, which is hard to obliterate and causes tedious convalescence. Some divide the pectoralis minor for axillary dissection and then resuture. We are unable to note any disadvantage to the patient in its absence, and its removal makes clean axillary dissection much better.

4. *Axillary Glands, Fat and Fascia.* All lymph-bearing structures from the axillary fossa require clean and complete dissection. After the pectoral muscles have been divided and retracted an incision to the outer side, and parallel to the axillary vessels and nerves, divides the loose fascia down to the line of cleavage of these structures. Then dissection on this plane inward clears these structures completely of all fat, fascia and glands. This clearing is carried high up beneath the clavicle toward the subclavian vessels and supraclavicular space. Branches from the axilla vessels are clamped close to their origin and divided, thus enabling one to make a complete dissection. This tissue clearing is continued down the under side of the scapula until the subscapular muscle stands out clearly and below and posteriorly the latissimus dorsi. Likewise the thoracic wall is cleared of all loose tissue, including the pectoral muscle above, leaving the ribs and intercostal muscles bare. This muscle and fascia clearing runs quite to the median line.

5. *Superclavicular Space.* Some surgeons, as routine, make a similar clearing of the subclavian triangle above the clavicle. We believe this adds little to safety and perhaps much to embarrassment. We prefer the postoperative raying of these areas.

6. *Abdominal Fascia.* Handley claims that metastatic spread is largely along fascial planes, and that by this route the abdomen is reached. Hence he advises, further, the removal of the fascia of the rectus on the side involved down to the umbilicus and in part the corresponding fascia of the external oblique. We have done this in certain cases but do not believe the practice has become general with American surgeons as yet.

DISSEMINATION AND CONTAMINATION. In operating we must further remember that *dissemination* may take place during the operation through uncut lymphatics, or *contamination* of the wound may occur with cancer cells escaping from cut lymphatics.

Dissemination may occur by milking the lymphatics in the manipulation of the infected breast during operation. Manipulation, or squeezing of the breast, should therefore be carefully avoided. More important, however, in preventing this complication is the suggestion, original we believe with Willy Meyer, to begin work in the axilla, dividing the lymph vessels at their highest point before the breast is handled at all. Thus the routes of dissemination are cut off. We go further and completely circumscribe the breast in our primary dissection, early, dividing as well the pectoralis major at its sternal attachment so as to cut off the route of dissemination through the chest wall into the thorax. The breast itself is therefore not handled at all until its peripheral zone has been completely shut off from its lymphatic connections.

Contamination. We are also of the opinion that perhaps many of the cases of local recurrence are due to cancer cells escaping from the cut lymphatic vessels during the operation. These implanted in the wound after its closure serve as grafts which in their home soil readily develop into new growths. While this idea is not demonstrable it is at least thoroughly plausible. To prevent such contamination we are wont to utilize two resources:

(1) Incision at the outset is made complete as planned and the flaps on all sides which remain are dissected up to the extent required. They are at once covered with hot gauze pads to protect their surface from contact of escaping cells. As the dissection proceeds we extend the process of gauze protection, covering both the area of the wound to remain, and as well the cut surfaces of the ablated breast to prevent the escape into the wound of cells from divided lymphatics. (2) Fearing that despite these precautions there may yet occur contamination, we thoroughly irrigate the wound before suturing, with a stream of water of some force, accompanied by light mopping with gauze. In our experience local external recurrences are rare, and we feel that perhaps these precautions have aided in the results.

Secondary Considerations. Admitting the fulfilment of the above essentials in the detail of operative technic, looking to the primary object of cure of the cancer, an ideal surgical procedure yet involves other considerations. We know that of all factors of success an early operation is the best possible promise of a permanent cure. Surgery must therefore win women to the idea of an early operation. In considering this purpose we must recognize the psychological and utilitarian aspects of surgery. Surgery must be made as attractive as possible, or, perhaps better expressed, less repulsive. We have seen many results in the past in which this aspect of the case was not impressive. An arm disabled, with contracting and binding scars, which rendered it almost useless, long and tedious wound-healing with prolonged hospital stay and mounting hospital expenses—sapping the often-times limited financial resources—repulsive scars from extensive skin-grafting, with the ribs showing through and the heart beats almost visible; is it remarkable that with these pictures shown in their friends, women should shrink from surgery in their own needs? Our results in cancer are not brilliant at best, but they are the best that science offers up to date. As surgical results we can probably only improve them through universal resort to early operation. We must therefore bend our

efforts to make the primary results of surgery at least as attractive as possible.



FIG. 1.—Outline of incision, marked with a scratch-stroke of the knife in author's original operation.

Of these utilitarian and psychological factors that of first importance is the preservation of a good function of the arm.

FIG. 2.—Quadrilateral flap of the skin and superficial fascia stretched out by tenaculum forceps and transferred inward to cover defect created by removal of skin of breast.

Function. Painless, free, unrestricted movements of the arm constitute good function. Excess of scar tissue or improper

placement are the chief factors producing disability. To prevent these troubles several points should be observed:

FIG. 3.—Method of insertion of figure-of-eight coaptation sutures.

1. The line of scar should not run transversely from arm to chest. If it does the inevitable contraction of scar tissue is

FIG. 4.—Flap sutured in place, with drainage-tube inserted.

inclined to draw the arm toward the chest and prevent full elevation, abduction and external rotation. A line of suture

running in the long axis of the arm up to the level of the shoulder-joint and then on to the chest would appear ideal.

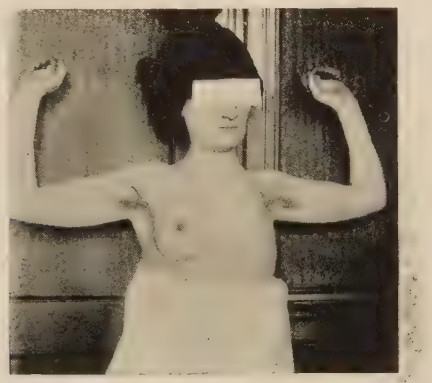

FIG. 5.—Photograph illustrating exact method of mapping-out flap in author's original method.

2. The proper obliteration of the emptied axillary fossa presents a problem. Unless satisfactorily accomplished the large

FIG. 6.—Demonstrating unrestricted use of arm and relation of scar to the arm when thus used.

cavity must be finally obliterated by organization of new tissue with scar formation, which further restricts mobility. What

may even be more troublesome to the patient is the compression by such scar tissue of the brachial plexus, with much ensuing pain, or the compression of axillary vessels with impairment of circulation. A paper by our lamented Murphy, presented before the Western Surgical Society in 1904, emphasized these particular points. As a corrective he advised leaving a flap from the lower border and outer end of the pectoralis major muscle, which was carried closely around the axillary structures and sutured to pro-

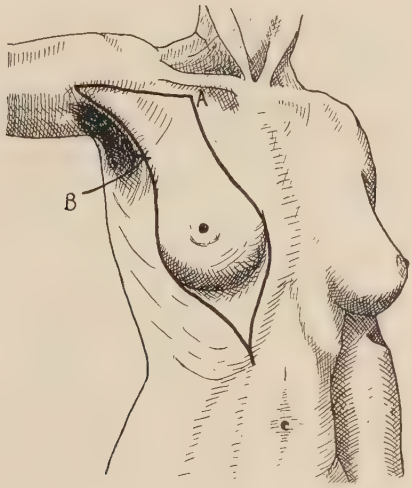

No. 1.

FIG. 7.—Incision of new method, meeting demands in certain cases.

tect these from scar contractures. To us it seemed that this expedient was subject to criticism in that it left the portion of this muscle likely to be infected. Endeavoring to meet the obvious demands in a better manner led to our original work on this subject, which involved the technic which we presented to the Western Surgical Society in December, 1905, and published in the *Journal of the American Medical Association*, March 3, 1906. The complete obliteration of the axillary fossa by bringing the skin from the under side of the pectoralis major, or the floor

of the axilla, up to a longitudinal incision in the line of the arm covered these vessels snugly, and we consider it the chief value of that technic. When this was done in this way we found the skin covering the front of the pectoral fold lax, and rather accidentally we slid it over to cover the area of the breast excision, and thus the flap evolved. While the flap proved an aid in covering the area of denudation, and this contributed to the value of the operation, the chief virtue sought and developed

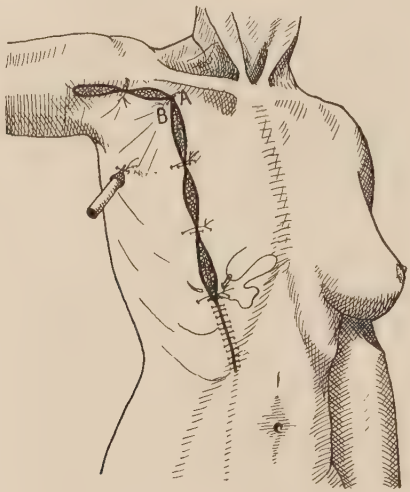

No. 2.

Fig. 8.—Illustrating method of closure.

was in placing the scar line properly and in readily obliterating the axillary fossa.

3. In the rapid restoration of function we have found another expedient valuable. If the case is dressed after the operation with the arm down to the side we find it difficult to get a timid patient to raise, abduct or externally rotate the arm. They are thus very slow in being educated to get the arm upward or backward, and hence are unable to dress their hair or otherwise wait upon themselves. To remedy this we from the outset keep the

arm up at right angles to the trunk. They are put to bed with the arm in this position. Then early passive motion is begun, while between times the arm is kept up. With this method there is no tension even with the arm in this extreme abduction, and the rapid improvement in arm function is pronounced.

Short Convalescence. Methods which ensure prompt wound-healing and correspondingly shorten convalescence save time

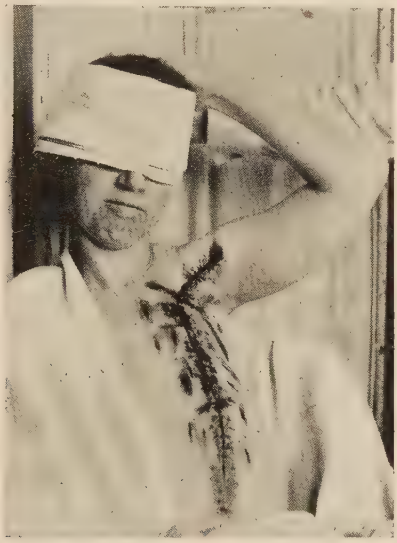

FIG. 9.—New method immediately after closure with position of placement of arm. Photograph likewise shows stab wounds to ensure drainage of venous engorgement of flap.

and hospital expense—both matters oftentimes of much concern. These indications are best met by methods which permit *primary closure* of the wound without undue tension and primary union. It is remarkable how much can be done to facilitate suture by proper undercutting in dissecting up the flaps in *any* operation. With a wide skin removal, however, this can in some cases not be accomplished except by some *plastic method.* To these plastic methods some have objected, saying "When one seeks to close

a wound at the end of his operation he will probably not be radical enough in the operation." If this were true there would be nothing to say. But, on the contrary, it is much more probable that a surgeon will do a radical operation always if he is possessed of resources which still permit closure without tension and primary union in most cases.

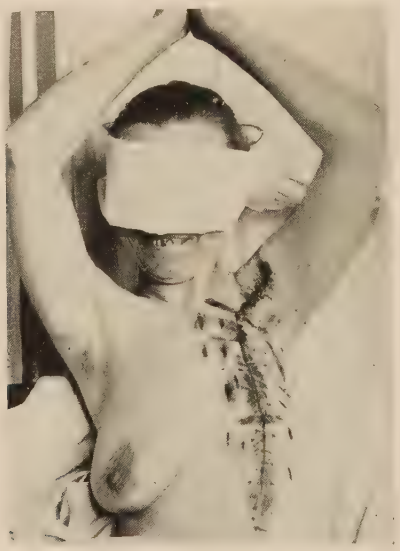

FIG. 10.—Showing complete elevation of arm one week after operation.

In either plastic flaps or undermined flaps we will sometimes have inadequate terminal vessel supply for every inch of skin margin, and hence there may be some small area of consequent necrosis. These areas when present are small. In many instances they result from venous engorgement with secondary capillary compression and obstruction. *Multiple* small *stabs* scattered over the flap will permit drainage of venous engorgement and obviate these areas of gangrene quite decidedly. It is a small point, but worth noting.

Cosmetics. Finally, of the minor factors is that of cosmetic appearance. Women are naturally quite sensitive of their

person. A disfiguring scar produces repulsion and horror both in the individual as well as in other women who see it. A wound

FIG. 11.—Position of arms two weeks after operation. At this time mobility was complete and voluntary, as illustrated. Author's new method.

covered by a skin graft is certainly not a thing of beauty at best and may be a determining factor in keeping others from needed surgical attention. We believe that in the present day,

FIG. 12.—Position of arms two weeks after operation. At this time mobility was complete and voluntary, as illustrated. Author's new method.

with methods available, skin-grafting should almost never be necessary.

Author's Operations. In meeting all these requirements of an ideal operation in cancer of the breast, after nearly fifteen years' experience with it, we yet believe the method we first published in 1906 comes more nearly serving than any we know. In detail of technic there have been several changes noted in the preceding lines, and we will not enter into any further description than may be obvious from the pictures herewith presented, supplementing the former article. Theoretically it has been perhaps criticised, as are all plastics, that in seeking closure infected tissues are left behind. On the contrary we do a more radical operation than any we have witnessed in other clinics, and do so because we know we can yet secure easy closure. Perhaps it might be thought that the flap itself might be the site for local recurrence. In answer we might note that the skin which forms the flap is not removed in any described technic to our knowledge. We admit to having seen cases done elsewhere in which the flap had been apparently taken too far inward and came from the mammary region. But correct observance of our method discloses that the outer incision runs quite out to the deltoid, and its inner parallel should be entirely outside of the mammary gland. In experience we have seen only two recurrences in the flap, and excision of the small nodules in both these cases showed that they had origin in the fascia of the chest and not in the tissues of the flap. Both of these experiences were in early cases, and we believe were due to contamination. Since employing the methods suggested we believe these recurrences will be rare at least. In fact it has been rather noteworthy in our experience how rare have been external or so-called skin recurrences, and that in these instances how immune the flap area has been. In fact, we believe the method readily applicable to all cases except in those of most extensive skin involvement or in those rare cases in which the extension may be out on to the skin over the axillary fold itself.

In just such a case as this we were obliged to forego the flap entirely in a case about a year ago. We have remarked before that, after all, the flap is the least valuable feature of our operation. We found in this instance we were still able to preserve

the more characteristic advantages of our original operation, and this method we wish briefly to present. The diagrams presented reveal the nature of the incision better than can be expressed in words. By this method all of the skin over the pectoral area, as well as that of the mammary region, is removed —a more radical skin removal than any heretofore presented. In closure of the wound, however, it is observed that the axillary fossa is obliterated exactly as in our first method. Likewise the scar in the long axis of the arm to above the shoulder and thence to the chest presents the same advantages of scar location to favor functional utility of the arm. With the usual rather extensive undermining, we have found that even this large wound closes rather readily without practically any tension, and we have secured primary union in all cases. As a matter of fact, to prove it out we have employed this method in most of our cases in the past year, whether specially indicated or not. We find quite as good functional results. It does not present quite so attractive a cosmetic appearance.

DISCUSSION OF PAPERS BY DRS. LEE, ADAIR AND JACKSON

Dr. Samuel J. Mixter, Boston:

There are three or four points which should be emphasized in operations for cancer of the breast: First, of course, is radical removal, second is utility, and third is the cosmetic effect, the latter of very small account comparatively. In dissecting the axilla the only thing that need be left there beside the axillary vein is the second subscapular nerve. The next point is to have the scar outside the axilla. The method proposed, of turning this flap over, is a good one but I think the same thing can be accomplished and more skin removed by making the scar higher, starting down on the arm and carrying it way above the axilla. It wants to be carried high enough. It always drags down and when it draws across the axilla you have hampering of action. I still like the method I presented to this Association many years ago, my friends call it the cyclops operation. It is perfectly simple and covers in very easily with good tissue an enormous defect. I like it much better than the other plastic methods.

Dr. John H. Gibbon, Philadelphia:

I wish to recall to the Fellows a paper read by our late Fellow Dr. Francis T. Stewart, at the Rochester meeting. Dr. Stewart described an incision which enables us to remove the disease as widely as any other incision and certainly appealed to me because of the cosmetic result. I have seen him use this incision and I have used it myself for eight years and I believe it is the best incision. Not only does it give the best cosmetic but the best functional results. The paper was published in the *Annals of Surgery* and although the illustrations are very poor the incision has proved most satisfactory. Stewart got away from what I think is the defect of all breast incisions, that is the incision going up to the axilla and into the pectoral border. Any incision going up there certainly gives a troublesome scar and tends to interfere with function, and that interference with function may sometimes increase after operation, although the patient may be able to go through the motions shortly after operation. Dr. Stewart's incision is a transverse incision and can be modified with the situation of the tumor. It is utterly impossible to confine oneself to one incision because these tumors are situated in different areas of the breast. This transverse incision offers this advantage that it can be shifted to suit the situation of the disease. If this incision is used and the flaps mobilized, when you come to the excision of fat and tissues beyond the breast you can take

out more tissue than if you mobilize the flaps later. These patients after operation have a scar directly across the chest, looking as if the operator had not entered the axilla. The incision is made below the hair line of the axilla and one can dissect up the flap and hold it out with a retractor and obtain an excellent exposure of the axilla. The removal of the pectoralis minor muscle I believe is of great advantage, as Dr. Jackson says, not because you are apt to get a recurrence in it but because it gives access to a region where glandular involvement may be overlooked. We talk a great deal about whether we shall take out the pectoral muscle or fascia as if that were the only muscle to consider. The rectus muscle may be just as important. In growths in the outer and lower part of the breast the sheath of the serratus muscle is the important one. The fascia of all these muscles should be removed extensively in the direction in which the growth is situated.

Another thing, regarding the late results of cancer of the breast. I think my own results have been 25 per cent. better since using the *x*-ray in all cases, regardless of the stage of the malignant disease; it is surprising to see how long recurrence is in making its appearance, and for this the *x*-ray and not the surgery is responsible. Every case of malignant disease is *x*-rayed for six months to a year with much better results than formerly.

Dr. Fred B. Lund, Boston:

With regard to Dr. Lee's interesting paper I would mention my experience with fat necrosis. Last October I operated for carcinoma of the breast in which the growth was a small one and I was in doubt whether or not it really was a carcinoma, so I incised it before doing the complete operation. The growth turned out to be carcinoma so I sutured the incision with great care and took every precaution to avoid contamination during the operation. I did not tell the patient she had carcinoma, and just a few days ago she turned up with four small flat nodules in the middle of the scar, not firmly adherent to the fascia and not adherent to the skin, but there was induration and the area was tender, and my heart sank for fear of an early recurrence. I excised a piece of skin with the four lumps in it and they proved to be necrotic masses of fat. There was no recurrence. I do not know of any traumatism in this case except I feel perfectly sure that the patient felt of that scar every day to see if she had a recurrence. I have also operated for a lump in the breast, a fat necrosis following subpectoral infusion which makes another case in the line of Dr. Lee's paper with a history of definite traumatism. We must think of fat necrosis in supposed recurrence after removal of carcinoma. I think

Dr. Stewart's operation gives excellent results as far as the arm goes. I have used all these methods but am apt to suit the operation to the given case. Regarding the function of the arm, we might follow the example of Rutherford Morrison, who, in order to have these patients get restored function as soon as possible told them to keep their arms perfectly still, not to use them at all—and of course they were constantly trying to find how much they could use them and thus obtained the desired result.

Dr. Charles H. Peck, New York City:

Just a word about the Stewart incision: I can corroborate everything said for it. Since hearing Dr. Stewart read his original paper some years ago I have employed it in a great majority of my cases, I was rather skeptical about it at first as I did not think it possible to get an adequate exposure of the axilla, but it took very few trials to show this fear was unfounded. The retraction of the upper flap gives perfectly adequate exposure. As to arm motion it seems to me that it gives the best results I have had. The scar is not in the upper axilla but crosses the axilla at its lower part, and avoids the scar on the shoulder or in the axillary border so that the cosmetic result is excellent. If the nodule is in the inner part of the breast the incision can be swung down and I think it gives by far the best cosmetic results of any breast incision. I have used it in a great many cases since it was presented. One other point in regard to the pectoralis minor. I do not altogether agree with Gibbon in the removal of that muscle. Unless there is very great involvement of the glands beneath it I do not think its removal is imperative. In many instances it is easily retracted so that you can make a perfectly clean section up to the clavicle beneath it. I have often divided, resected, and restitched it. I have a notion that its retention in some way protects the line of the axillary vein and helps to prevent swelling of the arm due to cicatricial contraction afterward.

Dr. L. L. McArthur, Chicago:

With regard to Dr. Lee's slides, none of them showed any evidence of glandular tissue, and therefore the question arises in my mind whether the diagnosis of fat necrosis of the female mamma is a correct one in these cases. I would ask him to elaborate on this subject because it does not seem to involve the mammary tissue proper, nor did the cases cited by Lund. It was my good fortune to see the original slides presented by Handley at the Second International Congress mounted serially under microscopes; they were presented by him for

the purpose of showing that the secondary metastases from the female breast when they occurred were more frequently in the liver than lung. He showed that if the tumor is in the lower quadrant of the breast whose lymphatics run along the rectus muscle to the umbilicus and thence into the round ligament, metastasis follows this route.

Dr. George W. Crile, Cleveland:

Most surgeons today do not greatly fear a local recurrence after operation. Dr. Jackson has presented a logical description of a good method. For years I heard Dr. J. B. Murphy say that unless the pectoralis minor was involved its removal was unnecessary. I have followed that plan for quite a long time and I do not recall any recurrence. Removal of the fascia over both muscles and absolute dissection must be done. My own experience has been that the use of the *x*-ray directly after the operation while the wound is open is beneficial. If metastasis to the lungs were excluded I believe the greater number of deaths by recurrence would be excluded; the greater number of recurrences in my own cases have been in that region rather than in the liver. I have seen a recurrence in one of my own cases which was operated on twenty-three years ago.

Dr. Miles F. Porter, Fort Wayne:

I wish to corroborate everything said about the Stewart incision provided the case is properly selected, and then I want to make another point in connection with breast operations—as with most surgery the technic should be made to fit the patient and not the reverse. One little point regarding the mobility of the arm: we should remember that scar tissue will bend without any trouble but will not stretch, then get the scar tissue against the joint. This emphasizes the placing of the roll that Dr. Gibbon spoke of to hold the axillary skin and fascia well up or by a few stitches we attach the skin flap to the immediate neighborhood of the joint with catgut and it holds it there. Another point is the immediate use of the arm, allowing the beginning of its use at once after the operation. The rule is that they will bring it to the head, that is the average patient with average courage, before the end of a week. One other point. I have been trying to get rid of drainage in these cases and I am convinced that if we spend a little more time and attention to obtaining perfect hemostasis we can get rid of drainage in a lot of cases, which, to say the least, is very uncomfortable for the patient. At best you want to remove it at the end of forty-eight hours.

Dr. Alexander Primrose, Toronto:

I should like to refer to one point in anatomy in connection with the pectoralis minor muscle. Two speakers mentioned invasion under the pectoralis minor. It is not here that we expect invasion, the dangerous region is under the costocoracoid membrane in the region above the upper margin of the pectoralis minor and beneath the clavicle. It is impossible to explore this region satisfactorily until the pectoralis minor is divided and turned up. Someone has suggested that the pectoralis minor, after dividing it from its origin, makes a very good retractor, making traction upon it upward and outward and thus giving a good exposure of the great vessels, nerves and glands in that region. Where you have glandular involvement at all in the axilla you almost invariably find invasion of the glands under the costocoracoid membrane, and therefore I think the pectoralis minor must always be divided so that this particular region may be thoroughly exposed.

Dr. Arthur Dean Bevan, Chicago:

I cannot see any advantage in the flap operation proposed. I think any one plan is bad as a routine; if you have a carcinoma of the breast it is my idea that you should remove it as widely as you can with the carcinoma as the center of the block of tissue removed, and so any routine operation is logically bad. If you have a carcinoma around the nipple then the ordinary incision can be made. An incision high on the arm itself will have a scar there but it protects the axilla, and this old incision, as old as Billroth or some other old master, is the incision which should be modified with that basic principle in mind, that the primary focus should be made the center of the block.

Dr. Burton James Lee, New York City (in closing):

With regard to Dr. McArthur's question as to the diagnosis, I would say there were two proofs of the fatty necrosis being such in breast tissue in our cases; the first was the gross examination of both specimens, in each instance the tumor mass being surrounded by breast tissue. The second proof was that the microscopic slides showed normal breast tissue.

Dr. Jabez N. Jackson, Kansas City, Mo. (in closing):

I am amazed to hear surgeons advocate the entrance upon any serious surgical problem without any special plan whatsoever. It is possibly true that no one plan may be absolutely adaptable to every conceivable condition. There should, however, be some definite plan

appropriate to that specific condition. It is our belief that one of the two methods which we have suggested will come nearer meeting all indications than any other. There are two objections, in our judgment, to the Stewart operation.

1. The incision is quite a distance below the axilla, and therefore requires considerable undercutting and retraction to render favorable access to the axilla for its proper dissection. This objection, however, is not fundamental.

2. Our chief objection is that finally there is a tremendous axillary space which is not definitely obliterated, and in their method it requires compression and pads in which results are uncertain. In fact this is the criticism made by Murphy of previous methods, and which led us to our efforts with the fundamental principle which we have devolved for clean primary obliteration of the axillary fossa. I believe that no other method described accomplishes the same result. But, whether one adopts one method or another, we certainly would insist upon at least the adoption of some fundamental principle of operative technic for an operation of the breast.

DIVERTICULA OF THE ESOPHAGUS

By ARTHUR DEAN BEVAN, M.D.
CHICAGO

I DESIRE to make a brief report of the experiences that we have had in my clinic with pulsion diverticula of the esophagus.

Until eight to ten years ago comparatively few of these cases had been recognized and operated upon, and the results up to that time had not been satisfactory on account of the excessive mortality attending the radical operations for the cure of this condition. Within the last ten years a much larger number of these cases have been recognized and much better results have been obtained by radical operations. There is, to begin with, a wider knowledge of the fact that these cases are by no means rare. The typical symptom-complex which they produce is more frequently recognized and a definite demonstration of the size and location of the diverticulum is now easily made by barium solution and *x*-ray examination.

My own knowledge of the subject dates back about ten years, when I operated upon my first case. Since that time I have had the opportunity of studying a considerable number of cases with my colleague Dr. Bertram W. Sippy and his associates. I should like to present to you the facts which we have been able to obtain from this clinical experience and the method of operation which we have developed and which has proved to be very satisfactory.

One word first in regard to the anatomy of this condition: Pulsion diverticula of the esophagus always occur at exactly the same point, just as do inguinal herniæ. Inguinal herniæ always come out through the external abdominal ring. Pulsion diverticula

present themselves at the junction of the esophagus and the pharynx in the midline posteriorly. At this point there is a

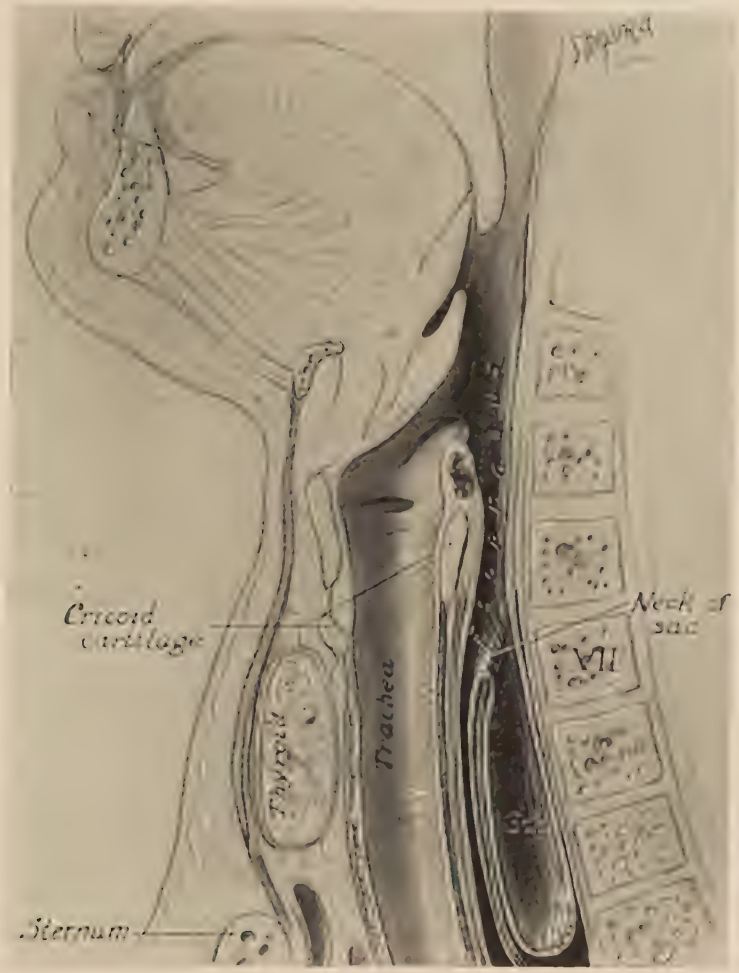

FIG. 1.—Sagittal section of neck, showing anatomical relation of hernial sac.

triangular area where the oblique muscles of the pharynx and the transverse circular muscles of the esophagus meet, leaving a small area not covered with musculature but simply by a sub-

mucous layer (Fig. 2). In cases where a diverticulum develops it is probable that there is more than the usual normal weakness at this point, probably a congenital absence of muscle fiber over a large area permitting a pushing out of the mucosa and sub-

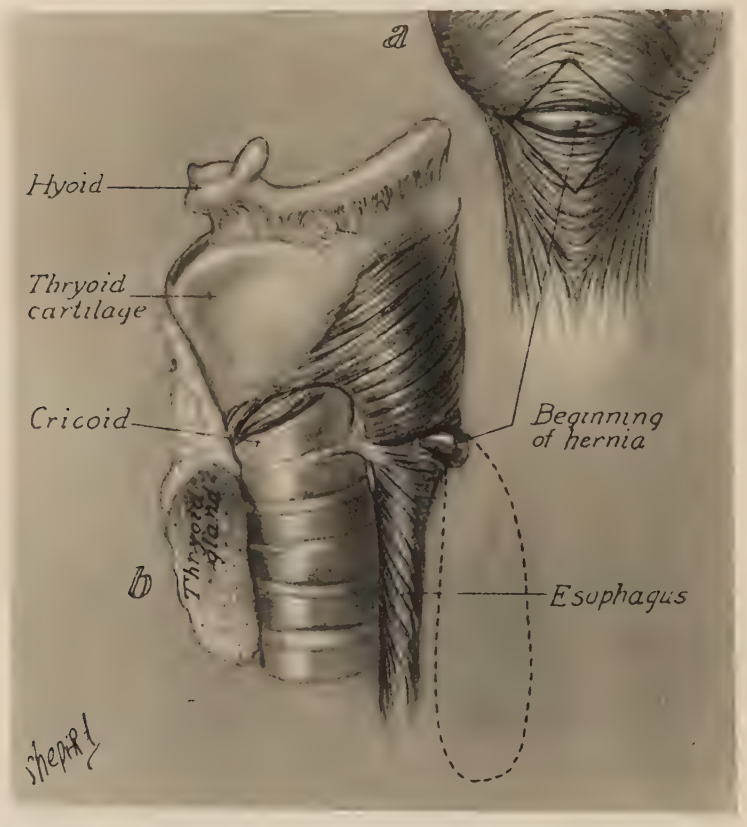

FIG. 2.—Point of rupture of muscle structure of esophagus.

mucosa in the process of deglutition, so that with this impulse applied to this weak area during swallowing a pouch of mucous membrane and submucosa is pushed out through this small triangular defect. The neck of the pouch always remains comparatively small. The pouch itself may reach a size sufficient

to hold 8 or 12 ounces or even more. Developing, as it does, always from the same point, the sac occupies a position in the middle line behind the esophagus and in front of the vertebral column, as shown in sagittal section in Fig. 1 and as shown in cross-section in Fig. 3.

We must not confuse pulsion diverticula of the esophagus with traction diverticula, which are frequently discussed at the same time. Traction diverticula may occur at any point, especially within the thorax, and, as a rule, are caused by cicatricial contraction of some old inflammatory process drawing the wall of the esophagus outward and making more or less of a funnel-shaped diverticulum. These cases are seldom if ever of interest to the clinician except for the primary lesion which is responsible for their production.

Pulsion diverticula vary greatly in size and in the severity of the symptoms which they produce. Many of the small diverticula are of little moment and are associated simply with a little irritation in swallowing and with an occasional slight regurgitation, and produce no great amount of discomfort to the patient and no serious impression upon his health. On the other hand, diverticula of larger size may become a very serious menace and may produce a fatal termination. As they increase in size, and as the amount which they can contain not only increases but becomes a source of danger and discomfort from decomposition of the contents, swallowing becomes more and more difficult until in the extreme picture the patient in his effort at swallowing simply fills up the diverticulum and little food, even liquid food, passes into the esophagus, and the patient, unless relieved, may die of starvation. I have, in fact, had the opportunity in one case of seeing this serious picture of death from acidosis and starvation in the case of an esophageal diverticulum, and have had in one other case a patient in such a serious condition that operation on the esophagus had to be preceded by a gastrostomy, so that we could feed the patient and get him in good enough condition for operation on the diverticulum. In minor cases, where the patient has a small diverticulum causing little distress

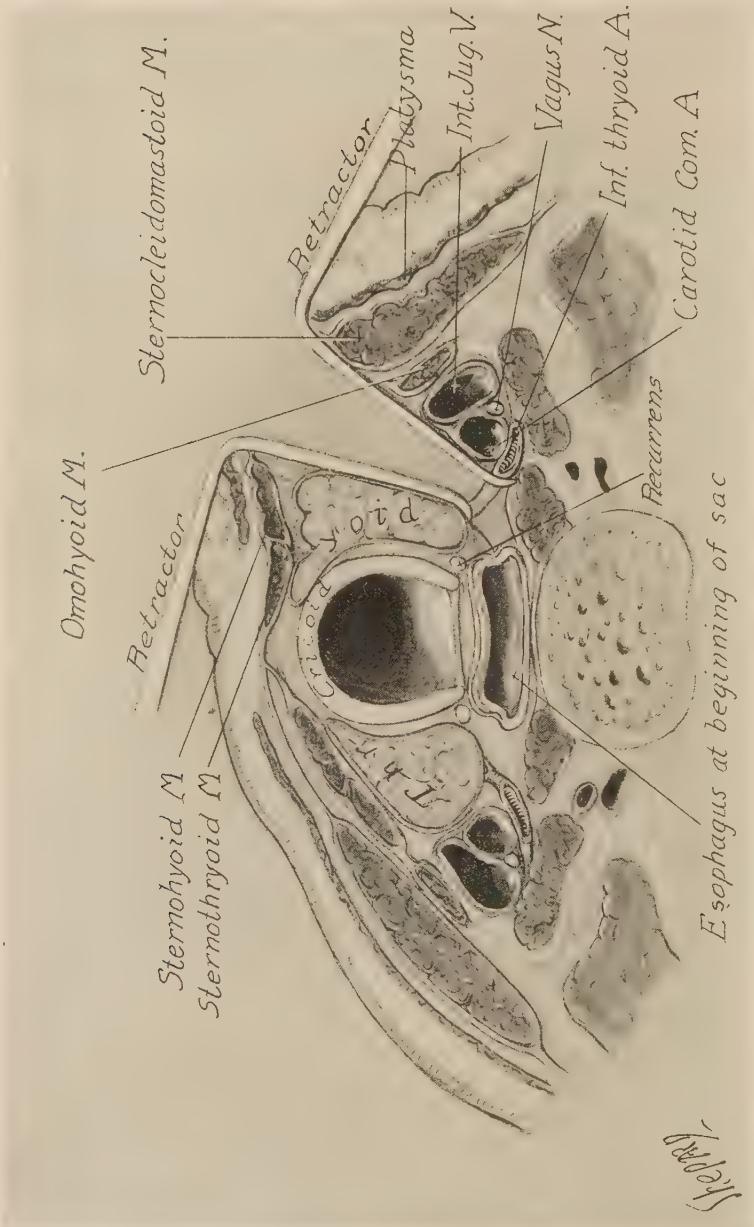

FIG. 3.—Cross-section of neck at cricoid cartilage, showing approach to esophagus and neck of sac.

and where the general health is still unimpaired, one might safely permit these patients to go on without interference if they so desire until the symptoms become more annoying. On the other hand, because of the fact that these small diverticula can be cured so safely and readily, I think that good judgment would dictate an operation unless there was some special contra-indication in the way of age or organic lesion to any operative interference. In the outspoken case where the diverticulum is of fair size and the condition is an annoying one, because of regurgitation and decomposition of food and the peculiar gurgling noise that is made while the patient is eating, which is sometimes so distressing and annoying that the family of the patient does not like to eat at the same table with him, there can be little doubt but that the patient should be given the benefit of a radical operation.

Until comparatively recently this operation carried so much risk that it was regarded as a very serious undertaking and one which was not to be advocated unless there was great urgency. In the old operation the risk was due to the fact that the diverticulum was isolated and cut off and the opening closed with sutures, with the result that many of them leaked into the raw tissues of the operative wound and the patient very often died of sepsis and from mediastinitis. The great risk of the older methods of handling these cases was the danger of infection from leakage. My colleague, Dr. Sippy, was very much impressed by a case which he had had operated upon by one of our best American surgeons and which had died from leakage and infection, and he felt that some operation should be developed that would eliminate this risk. Talking the matter over with him, and after studying a case which he had referred to me, I devised a plan of operation which had for its purpose the obliteration of the diverticulum without carrying with it any risk of leakage, or at least reducing the dangers of leakage to a minimum. The plan which we have adopted is as follows:

First, we do all of these operations under local anesthesia, using 2 per cent. novocain or apothesin solution in distilled water

with 1 to 200,000 adrenal. I have made my incision usually on the left side. We infiltrate very thoroughly all the tissues on the inner side of the left sternocleidomastoid from the hyoid bone

FIG. 4.—Incision along internal border of sternocleidomastoid muscle.

down to the sternum. We then divide the skin and superficial fascia for a distance of five or six inches along the inner border of the sternocleidomastoid (Fig. 4). The sternocleidomastoid is then drawn to the outer side with retractors and the deep cervical

fascia is divided parallel with the external incision and the great vessels of the neck, the internal jugular and carotid and the pneumogastric nerve are drawn to the outer side. The thyroid gland, sternohyoid and sternothyroid are drawn to the inner side. In the bottom of this wound one very often finds interfering with the free exposure of the diverticulum the inferior thyroid artery, and where this is in the way it is doubly ligated and divided between the ligatures. This enables one to draw the thyroid gland well to the inner side and to expose the lateral wall of the esophagus; usually by having the patient swallow the diverticulum comes into view. In most of our cases we have found it lying in some loose areolar tissue and that it could be very readily pulled into view. One must be careful to use a dissecting forceps without teeth and to very carefully draw the diverticulum out from its bed so as to avoid rupturing its coats (Fig. 5). As the diverticulum is drawn out through the wound it looks like a hernial sac. One should remember that it is composed simply of mucous membrane and a submucous fibrous coat. If the diverticulum is small, not larger than one's thumb, that is to say, 2 or 2½ inches long and not more than 1 inch across, it can be very readily handled by invaginating it into the esophagus with three purse strings, because a diverticulum of this size invaginated into the esophagus cannot do any harm. It is, however, dangerous, as we know by experience, to invaginate a large diverticulum into the esophagus because of the danger of its being carried up in the effort of vomiting and closing the opening of the larynx. A diverticulum larger than the thumb should therefore be handled not by invagination alone but in the following way:

We should invaginate with three purse-string sutures of black silk or Pagenstecher linen one-half of the diverticulum into the other half, as shown in Fig. 6, *A*. Then the balance of the diverticulum should be obliterated by longitudinal sutures, six or eight, running parallel with the long axis of the diverticulum. When the operation is complete as far as the esophagus is concerned it gives one the picture shown in Fig. 6, *C*.

In a large diverticulum another method may be employed.

Instead of the one I have just described the diverticulum can be crushed at its center with a pair of heavy forceps, tied with a silk ligature and the portion distal to the ligature then cut off with the electric cautery. The remains of the diverticulum, which

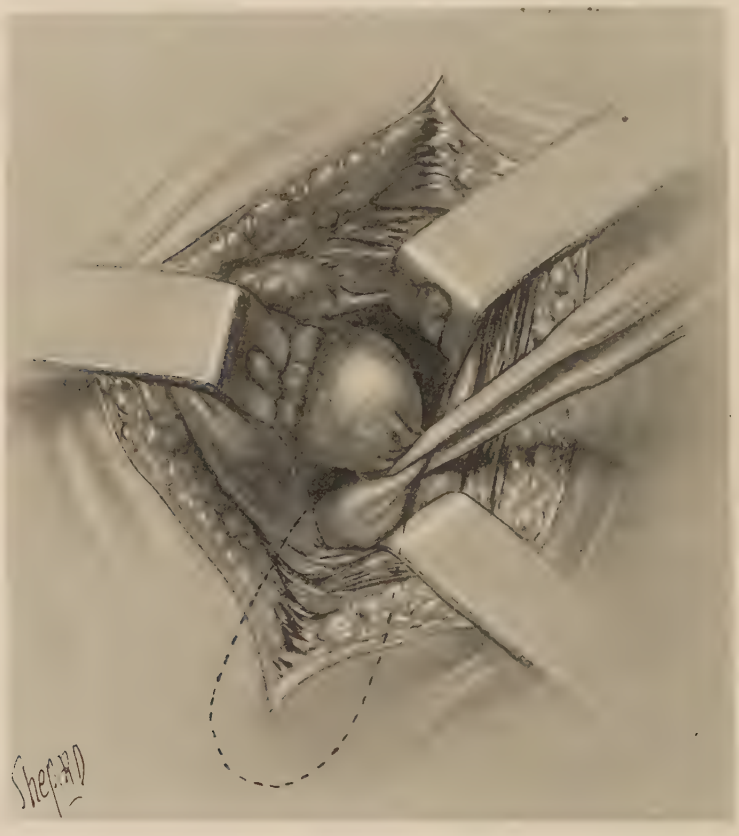

FIG. 5.—Dissection made and sac pulled out from mediastinum.

are then no larger than one's thumb, can be treated by invaginating them into the esophagus with three purse-string sutures, just as we handle the smaller diverticula (Fig. 7).

I am uncertain in my own mind which of these is the better plan. I believe that we should do a series of cases by both

methods to determine which should be adopted as the standard procedure. I feel, however, that I am in a position to say, with a good deal of positiveness, that small diverticula, not larger than a thumb, can be very safely handled and permanently cured

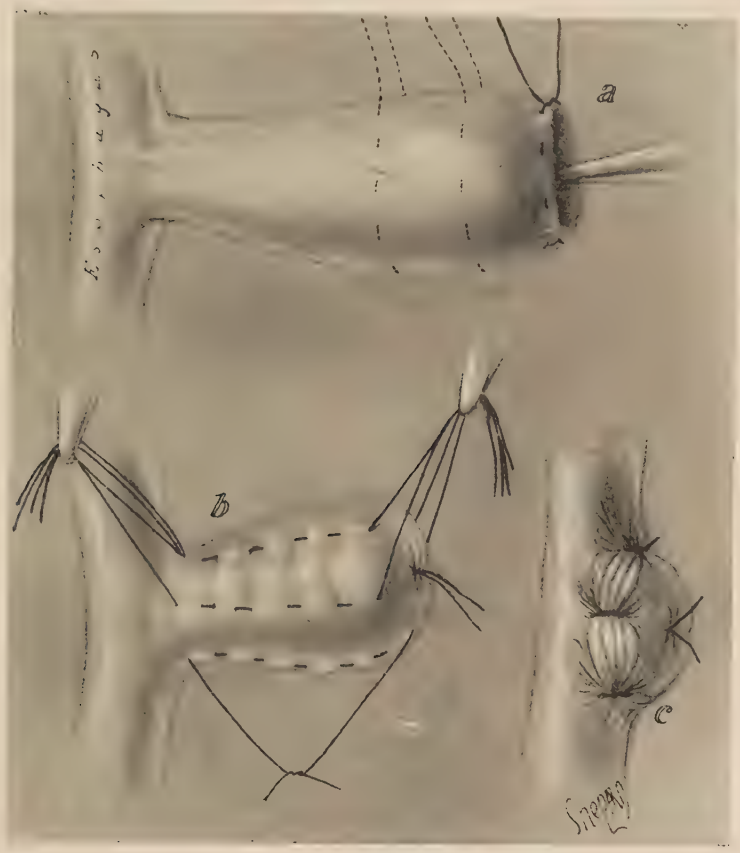

FIG. 6.—*a*, invagination of sac; *b* and *c*, longitudinal sutures placed and tied.

by invagination into the esophagus and immediate closure of the external wound. On that basis I think it is probable that if we reduce in size by removing the excess portion all our diverticula cases to cases not larger than a thumb that it will furnish us a very satisfactory operation for all of these diverticula cases.

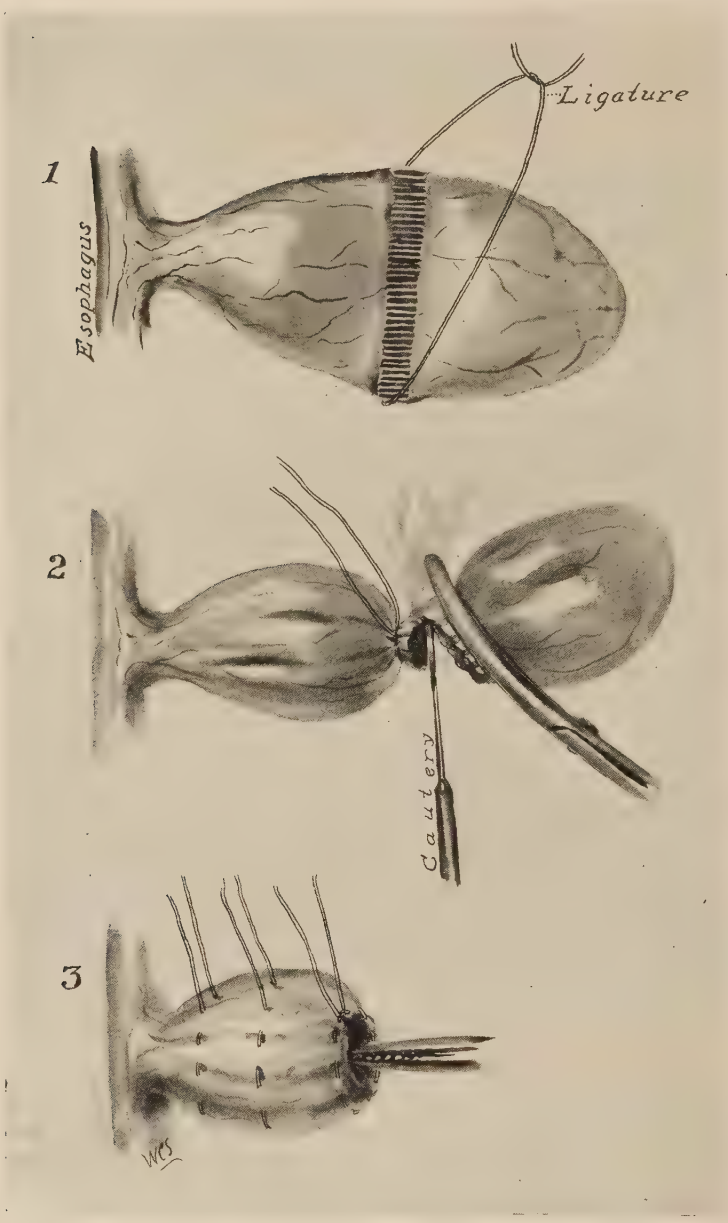

FIG. 7

The remaining steps of the operation are simply leaving a very soft rubber tube containing a strand of iodoform gauze in the center of the wound from the operative field of the esophagus to the middle of the external incision and closing the rest of the wound; this soft rubber drain containing the iodoform gauze should be removed at the end of forty-eight hours.

The patient is fed in quite a simple way, introducing a No. 14 American size catheter into the esophagus three times a day and giving the patient fluid nourishment and plenty of water through this tube and not permitting him to swallow until wound-healing is complete, about ten days.

I should like to emphasize especially three points in the ordinary handling of these cases: First, in the extremely rare case in which the patient is so reduced by starvation that he has little or no resisting power, the importance of doing a gastrostomy, feeding the patient and getting him into better condition before undertaking the operation on the diverticulum; second, the importance of local anesthesia; third, the importance of a technic such as I have described, or at least a technic which will prevent the risks of leakage and infection.

DISCUSSION

Dr. Albert E. Halstead, Chicago:

About eighteen years ago I published a paper on diverticula of the esophagus in the *Annals of Surgery*, and reported a case operated on by the invagination method which I accredited to Girard, of Lausanne, who had done the operation several years before. Girard recommended the invagination method in small diverticula only, saying that it should not be used in any in which the size was over that of the distal phalanx of the thumb. Since that time I have operated on a number of cases, using a two-step method. The mortality in the cases reported has been due to infection of the mediastinum. Having that in view, I dissect out these diverticula through the same incision used by Bevan, twist the diverticulum on its transverse axis about once and a half and then pack the cavity from which it has been lifted loosely with gauze and allow the patient to remain in that condition for ten days. Immediately after twisting the diverticulum and pulling it into the wound the patient can swallow any kind of food as well as ever. There is no necessity of feeding with a catheter or tube. I have demonstrated this in about eight cases. At the end of ten days the wound is reopened under local or general anesthesia and the diverticulum excised and the stump turned in by purse-string suture. This effects a cure. The criticism that I should offer of Dr. Bevan's method is that in the first place it has been demonstrated that it is dangerous to invaginate a large diverticulum. If you reef the diverticulum and sew as Bevan does I see no reason why a recurrence could not take place. If you excise the diverticulum you are rid of it forever and the operation as performed by me is without mortality. In this operation I never found it necessary to divide the inferior thyroid artery but have divided the superior thyroid artery and the superior and middle thyroid veins. I have operated on some very large ones and since using this two-step method have had no deaths.

Dr. Charles H. Mayo, Rochester, Minnesota:

I have operated in many cases of diverticula of the esophagus. One patient died of a pulmonary embolism after leaving the hospital. He had one of the first large diverticula that I operated on, and I thought that I performed the first two-stage operation for it. The diverticulum held more than a pint and was almost wholly in the right upper chest. The patient was on the table, his chest elevated. The diverticulum was partly filled, and when I squeezed it the lungs filled with the fluid;

the patient developed a bronchopneumonia but improved later. As I brought the sac out of the chest and heard the air going into the mediastinal space I realized that the old method of excision could not be used, since if I excised the sac and closed the wound the patient would develop an infection. I decided to twist the pedicle and let the diverticulum hang outside; in two days it was black and I cut it off. A fistulous opening remained, but with good protective tissue. I later enucleated the mucous fistula and closed the opening. Recently I noticed an article on projecting forceps down through the esophagus into the sac, drawing it up and projecting it down the esophagus from the inside, accomplishing what Dr. Bevan does from the outside. Probably this is a good method if the sac is large, and folded on the posterior wall. There are several methods of dealing with these cases, but it is only in the cases in which the mediastinum is involved in which the two-stage operation should be used or the sac twisted.

There is the question of why diverticula occur. Attention has been called to the fact that the area in which the pharyngeal muscles cross behind the cricoid cartilage is weakly supported and allows for the stretching of the wall and bulging out of a diverticulum.

Dr. Arthur Dean Bevan, Chicago (in closing):

It seems to me that the technic which I have presented does away with the two-stage operation. I am rather convinced that it does, and that if we try a large series of cases we will get away from the two-stage procedure. Whether in the large diverticula we will invaginate part and reef in the balance or whether it will prove a better procedure to make a small diverticulum of a large one by cutting it off with the Pacquelin or electric cautery after crushing, is an open question in my mind. But the fundamental principle is of not opening in any way the diverticulum. If we observe this point it will change the old high mortality to a very reasonable percentage.

THE CALLOUSED ULCER OF THE POSTERIOR WALL OF THE STOMACH

By W. J. MAYO, M.D.
ROCHESTER, MINNESOTA

From July 1, 1914, to July 1, 1919, 647 operations were performed in the Clinic on 638 patients with gastric ulcers, with an average operative mortality of 3.2 per cent. All patients who died in the hospital following operation are statistically classified as having died from operation, without regard to the cause of death or length of time after operation. During this same five-year period 2734 operations were performed on 2720 patients with duodenal ulcers, with an operative mortality of 1.2 per cent.

In twenty-eight of the series of 638 gastric ulcers the ulcers were multiple. Five hundred thirty-four were located on or around the lesser curvature of the stomach, eighty-five involved the posterior wall, nine were on or around the greater curvature, five were on the anterior wall, and five were not located exactly because of the emergency nature of the operation.

Ulcers of the Posterior Wall of the Stomach. In dividing the stomach into thirds (Fig. 1), the pyloric third showed only 8.2 per cent. of ulcers of the posterior wall, the middle third the great preponderance of 75.3 per cent., and the cardiac third 16.5 per cent. The ulcer crater varied from 2 cm. to 11 cm. in diameter. All the ulcers were of the chronic perforating varieties; in fifty-three cases the coats of the stomach were penetrated and the crater of the ulcer encroached on a neighboring viscus, usually the pancreas; a few also encroached on the liver, or the transverse colon, or were imbedded in a mat of adhesions. Fifty-seven of the eighty-five patients with ulcers of the posterior wall of the stomach

were males and twenty-eight were females. The average age was 43.9 years; the oldest patient was 69 and the youngest 18. The average duration of symptoms was six years and six months. The average weight loss was 17.8 pounds, the greatest loss 39 pounds, and the least 3 pounds. Fourteen patients had marked secondary anemia, and anemia was present in all, often accompanied by a cachexia. The maximum hemoglobin was 66, the minimum 26. The pain was in the epigastrium in fifty-six patients, in the back in twenty-four; it radiated to the right in fifteen cases, to the left in eight, and downward in eight; in eleven it was given indefinitely as in the stomach and mid-abdomen. Food gave relief in fifty cases. The obstruction was not extreme in any case, although distinct lagging of food or obstruction varying from slight to moderate was demonstrated in 35 per cent. of the series.

Hour-glass stomachs were excluded from the series. Acids averaged about normal for the age, and there was little difference between the acid (five points above) of the patients who had hemorrhages and those who did not. Nineteen patients (20 per cent.) had gross hemorrhages; seventeen vomited blood, and twelve, whether or not they vomited blood, had blood in the stools. The clinical diagnosis was correct in seventy-one cases. Cancer was diagnosed in six cases, pyloric obstruction in two, gallstones or gastric ulcer in four, and duodenal ulcer in two. The *x*-ray diagnosis was correct in seventy-one cases; duodenal ulcer in two, and "negative stomach" in ten. No *x*-ray was made in two cases. The ten cases in which the diagnosis was negative represent a type which is now better understood. Within the last three years the *x*-ray technic has improved and diagnosis by this means is established in above 90 per cent. of lesions of the stomach.

To epitomize: The main characteristics of ulcer of the posterior wall of the stomach are: chronicity, lesions usually large, more or less continuous distress, occasional exacerbations from localized peritonitis, and anemia often accompanied by marked cachexia.

Even at operations it is sometimes difficult to determine whether the condition is ulcer or cancer until the lesion is actually exposed and a specimen secured for immediate microscopic examination. In our early experience in some cases clinically diagnosed as ulcer in which gastro-enterostomy only was done, the patients died later from carcinoma of the stomach but at a time remote from the operation. It must be admitted that this is an impressionistic view because there was no specimen removed for evidence that the growths in question were not cancerous at the time the operations were performed. But since the ulcers were not removed, why did the patients live so long before the cancers became manifest? The opposite mistake certainly was made, because in some cases (seven) that were clinically diagnosed cancer and in which gastro-enterostomy was done, the patients lived too long after the operation for the original diagnosis to have been correct. And here is just the difficulty in trying to settle the question of the frequency with which chronic ulcers of the stomach undergo malignant degeneration. Clinical diagnosis is notoriously defective, postmortem evidence cannot prove the original disease, and operations that do not permit the actual excision of the lesion or the removal of a specimen for microscopic examination are open to objection. No matter how we view the question *a priori*, however, the experience of Robson, Moynihan, Pouchet, Deaver, and others, and the experience in our clinic is too large for the data to be controverted by the opinion of clinicians who have not had specimens removed and accurately examined during the life of the patient. Aschoff very properly points out that if the lesion is cancer originally the base of the ulcer will prove to be cancer. Wilson and MacCarty have shown in our cases of cancer on ulcer that cancer existed in the overhanging margin of the ulcer and not in the base.

An interesting side-light is thrown on the problem of peptic ulcers by Balfour's investigation of the frequency of hemorrhage following operation for ulcer of the duodenum and stomach. He found, in cases of duodenal ulcer in which nothing but gastro-enterostomy was done and in which there had been hemorrhage

before operation, that 1 in 8 had hemorrhage afterward, although all the other signs and symptoms were abated. In cases of gastric ulcer, however, hemorrhage occurred in only 1 in 12 following operation. Balfour explains this discrepancy as due to the fact that gastric ulcer, because of its carcinoma liability, was subjected to radical removal, while duodenal ulcer, having little or no cancer liability, was not usually excised. Balfour found that if duodenal ulcers were excised the liability to secondary hemorrhage disappeared and the mortality of cautery excision with gastro-enterostomy was not greater than gastro-enterostomy without excision. That all varieties of gastric ulcer are more serious than duodenal ulcers has been shown by data compiled from our cases by Dr. Hunter, Actuary of the New York Life Insurance Company; the death-rate from duodenal ulcer in the first four years after operation was practically the same as the normal, as a matter of fact better, while for gastric ulcer the average death-rate in the four years was three times normal. A study of these tables cannot fail to leave a well founded suspicion that at least a minority of the patients died from cancer of the stomach.

SUMMARY OF RESULTS IN 85 CASES OF CALLOUSED ULCER ON THE POSTERIOR WALL OF THE STOMACH IN WHICH OPERATION WAS DONE FROM JULY 1, 1914 TO JULY 1, 1919

		Per cent.
Cases	85	
Operations	87	
Deaths in hospital	4	4.7
Deaths after leaving hospital	10	11.7
Living patients reporting their condition	43	50.5
Improved	14	32.5
Unimproved	3	6.9
Cured	26	60.4
Patients not located	28	32.9

A. Cautery or Knife Excision. Cautery alone or knife excision alone has a limited field of usefulness in cases of small ulcers in all situations. It has given good results when care is

exercised not to disturb the nerve supply and the muscular efficiency. Opening the stomach and applying the cautery to the base of an adherent ulcer is not a sound procedure.

B. Gastro-enterostomy. At times the general or local condition of the patient may indicate posterior gastro-enterostomy, or the extent of the posterior lesion may warrant anterior gastro-enterostomy.

C. Resection. Resection of the pyloric half of the stomach by the methods of Billroth or the Polya-Balfour, gives good results in suitable cases, and is the operation of choice when the pyloric region is involved. But when the ulcers lie high on the body of the stomach the operation removes a large part of the uninvolved organ that is capable of good function. Resection in continuity (sleeve resection) of the ulcer-bearing area of the stomach, if the ulcer is in the middle third, is an excellent method, as has been shown by our experience and corroborated by Stewart. A circular piece of the stomach including the ulcer is removed and the proximal and distal parts of the stomach are united end to end with catgut.

D. Excision and Gastro-enterostomy. After a good specimen has been secured for microscopic diagnosis the ulcer is excised with the cautery, the defect is closed with catgut sutures, and a posterior gastro-enterostomy performed. Excision of the ulcer and gastro-enterostomy would seem the logical procedure in the average case, but experience has shown that the method may fail to give complete relief if the ulcers are on the posterior wall of the stomach because it is sometimes followed by the reformation of crippling adhesions that immobilize the posterior wall.

Operative Technic. The procedure herewith described combines excision of the ulcer and gastro-enterostomy and is satisfactory at least in that it usually prevents subsequent posterior fixation of the stomach. The approach to the posterior wall of the stomach can be made either from above or below. I have tried both, and perhaps because I have had a larger experience with the upper approach I prefer it.

The gastrohepatic omentum is divided (Fig. 2), if necessary the gastric artery is tied, and the adhesions high on the lesser curvature are separated to secure adequate operating space. After all the adhesions are cleared away I insinuate my finger around the adherent ulcer. This hooks the involved stomach and pancreas in such manner that they can be drawn up into the wound and exposed. The stomach and its posterior attachments are held up by the finger, or by a gauze tape, and the ulcer is

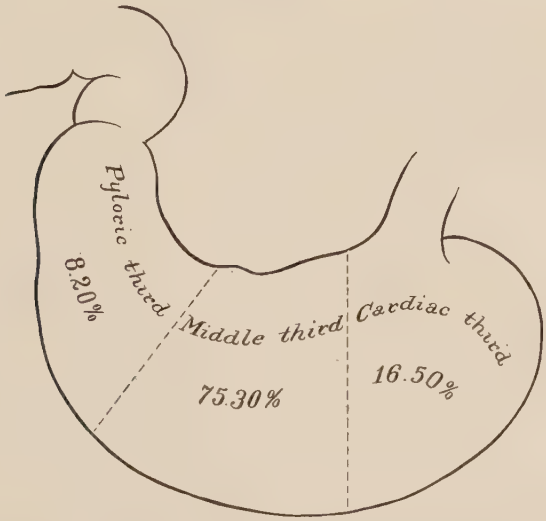

FIG. 1.—Diagram of location of ulcers found on the posterior wall of the stomach, at operation, from July 1, 1914, to July 1, 1919.

shaved off from the pancreas deep enough to include all the base. Sometimes in the huge ulcers the pancreas cannot be exposed sufficiently for the safe excision of the entire base of the ulcer. In such cases the pancreatic defect is carefully seared with the cautery. I have never seen fat necrosis or any harmful evidence of pancreatic leakage follow these maneuvers. The margin of the ulcer is caught with forceps in order to further its exposure. If the stomach contains a considerable quantity of fluid which has not been removed by the preliminary use of

the stomach tube, the fluid should be removed by suction. Frozen sections of the base of the ulcer, of the involved pancreas, and

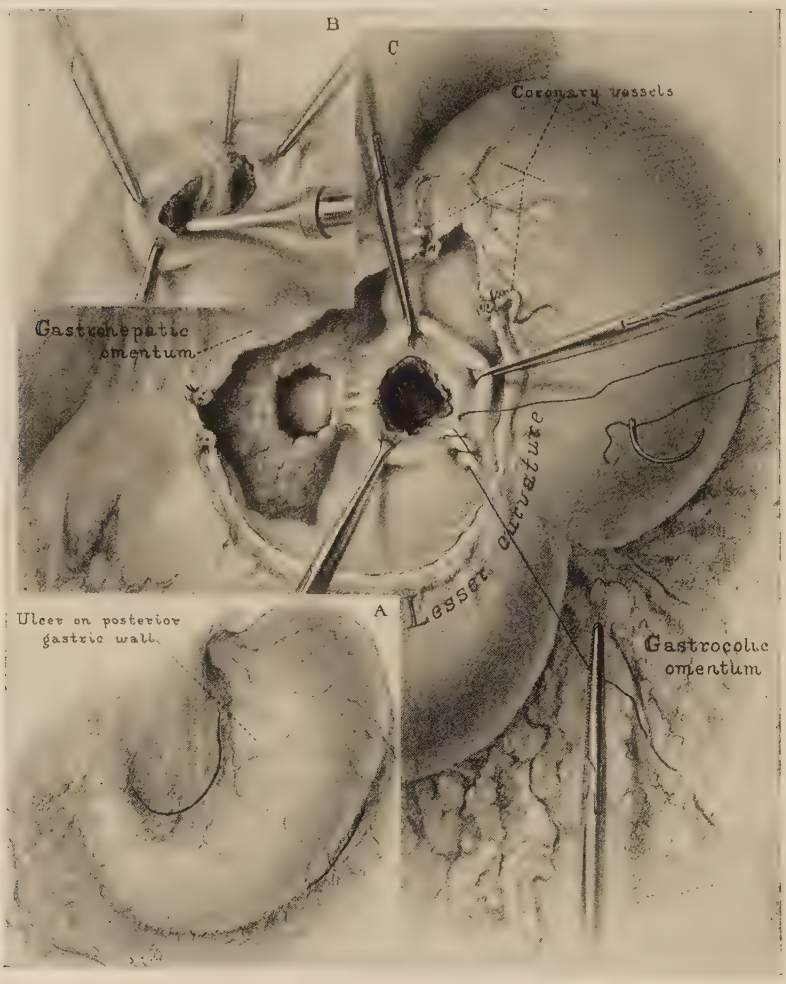

FIG. 2.—*A*, lines marking proposed incisions in gastrohepatic omentum for exposure of ulcer which is removed for microscopic examination, and in gastrocolic omentum to draw the left-hand portion of the omentum proper into the lesser peritoneal cavity; *B*, excising the ulcer with cautery; *C*, crater of the ulcer on the posterior wall of the stomach separated from the pancreas for three-quarters of its extent, thereby exposing ulcer cavity in the pancreatic surface.

of the margin of the ulcer area in the stomach are subjected to microscopic examination, and after this the ulcer is excised with

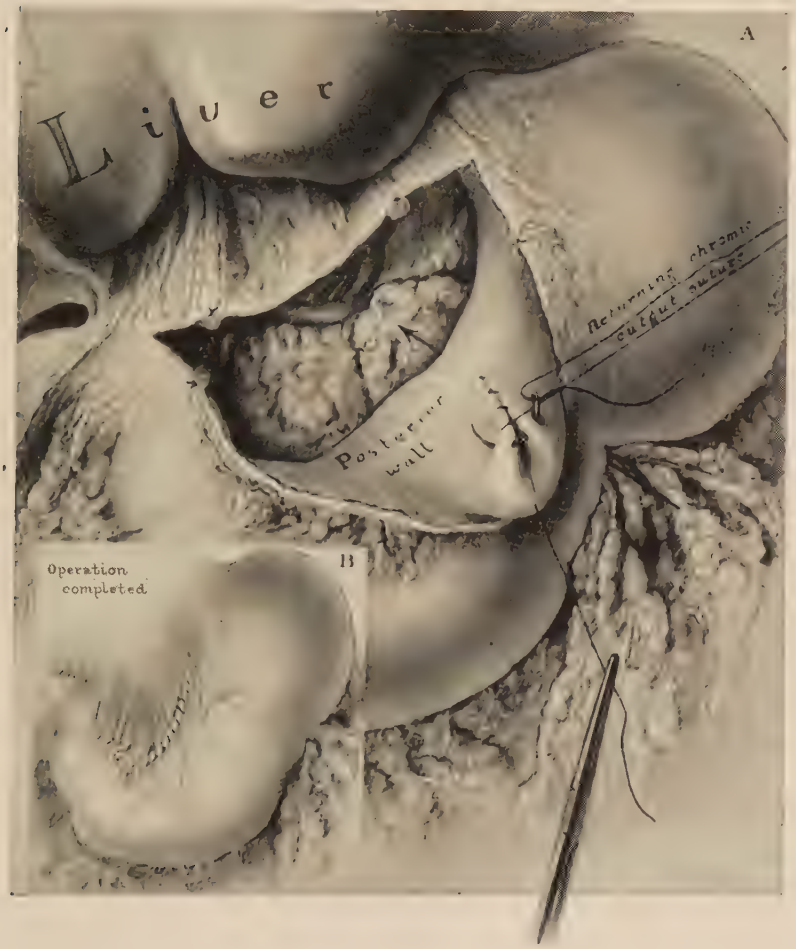

FIG. 3.—*A*, ulcer being sutured transversely and omentum drawn behind the stomach covering the pancreatic incision and operative field; *B*, operation completed.

the cautery. The posterior wall of the stomach above the ulcer will be found dilated and pouched, and the gap in the stomach is

easily closed with through-and-through catgut sutures, bringing the cauterized margins of the stomach directly into contact. A second row of catgut sutures turns this line in. The direction of the suturing which prevents narrowing naturally suggests itself (Fig. 3). An opening is then made below the greater curvature through the gastrocolic omentum, and the tip of the omentum is drawn upward behind the stomach and fastened in a manner to cover the whole of the operative field. This insures speedy union and permanently separates the posterior wall of the stomach from the pancreas and liver. A posterior gastro-enterostomy completes the operation. Even if the field of operation is considerably soiled I make a proper toilet and do not use drainage; I have had no occasion to regret the omission.

Bibliography

Aschoff, L.: Ueber die mechanischen Momente in der Pathogenese des runden Magengeschwürs und über seine Beziehungen zum Krebs, Deutsch. med. Wchnschr., 1912, i, 494–496.

Balfour, D. C.: Surgical Treatment in the Bleeding Type of Gastric and Duodenal Ulcer, Jour. Am. Med. Assn., 1919, lxxiii, 571–575.

Deaver, J. B.: Early Recognition of Carcinoma of the Stomach, New York Med. Jour., 1919, cix, 749–751.

Hunter, A.: Gastric and Duodenal Ulcers: Mortality after Operation, Association of Life Insurance Medical Directors, 1919.

Moynihan, B.: Disappointments after Gastro-enterostomy, British Med. Jour., 1919, ii, 33–36.

Pauchet, V.: Traitement de l'ulcère chronique de l'estomac (gastroctomie suivie de gastro-jejunostomie termino-latérale), Presse méd., 1916, xxiv, 445–450.

Robson, A. W.: The Operative Treatment of Ulcer of the Stomach and its Chief Complications, British Med. Jour., 1906, ii, 1345–1350.

Stewart, G. D., and Barber, W. H.: Segmental Resection for Gastric Ulcer, Ann. Surg., 1916, lxiv, 527–536.

Wilson, L. B., and MacCarty, W. C.: Pathologic Relationships of Gastric Ulcer and Gastric Carcinoma, Am. Jour. Med. Sc., 1909, cxxviii, 846–852.

DISCUSSION.

Dr. J. M. T. Finney, Baltimore:

I simply want to offer a suggestion for what it may be worth in the way of dealing with this class of cases in a way that is a little less radical than is suggested in this paper. I have done this operation in perhaps a dozen cases covering a period of more than three years. In this class of cases which we all recognize as very difficult with which to deal, it seems to me that the pyloroplasty, in favor of which I am prejudiced, will avail in certainly a very large percentage of cases. In dealing with the ulcer it has seemed to me that the same principles that you apply to chronic ulcers of the leg will apply to chronic ulcers of the stomach. Years ago I found, in studying healing in chronic ulcers of the leg, a paper published some twenty years ago in which it was stated that if one would take a chronic leg ulcer and make deep parallel or crucial incisions down to the fibrous tissue at the base which is very poorly supplied with bloodvessels, all of which will be found the subject of marked arteritis, one could get that limb into fairly normal condition well supplied with blood; by cutting deeply enough one will find in a short time a layer of granulation, first a retraction of the tissues due to fibrous tissue, then a line of granulations coming up through these areas, and then the epithelium rapidly growing in along these lines: So that you can bisect or do anything you like with the base of an ulcer in the matter of healing by simply furnishing good blood supply in this way. One may do that to the base of chronic ulcers on the posterior wall of the stomach where you cannot get at them, say, in lifting up the ulcer on the posterior wall on your finger, as Mayo describes; you can expose the ulcer on your finger, then through an elliptical incision which allows you to explore the inside of the stomach in a satisfactory manner you can make this same incision through the base of the ulcer down to, and sometimes into, the substance of the pancreas; but even if you do penetrate this organ it is going to drain into the stomach so that it does not seem to make any difference, at least it did not in the cases in which I have had this happen. Then complete your pyloroplastic operation, being sure that you have made a good free opening, that is a good wide pylorus, so that you get the same advantage of neutralization of the hyperacid content, or whatever it is. This group of cases have all done so satisfactorily that I have been encouraged to continue it still further. I simply call attention to this procedure which in a dozen cases resulted satisfactorily for me, as it is attended with certainly a good deal less risk than the more radical operation described in Dr. Mayo's paper.

Dr. George W. Crile, Cleveland:

Any paper from the Mayo Clinic on this subject leaves very little for discussion. There is, however, one statement regarding the disabling end-results of the resection of a large ulcer, whether on the posterior wall or the lesser curvature, that leads me to make a suggestion. As practiced by Dr. Ochsner such a condition can be dealt with very satisfactorily by a little change in the technic.

In those cases in which the stomach is mobile or can be made so, the ulcer is approached by an incision through the bloodless fold of the stomach. Such an opening allows the protrusion and inspection of the ulcer and ready access to its borders, so that the sutures can be inserted at the time that the ulcer is delivered through the opening, and the ulcer itself excised with a cautery. An extra line of suture is then introduced and the ulcer area dropped back. This leaves uninvaded the regions posterior to the stomach, and has the advantage of giving a clearly visible field. The two ends are then sutured in the opposite direction, thus making a plastic operation, which makes up in diameter for whatever is lost in the removal of the ulcer.

Dr. Alexander Primrose, Toronto:

I was just about to mention an operation somewhat similar to that detailed by Dr. Crile, which was suggested to me by the transgastric operation as described by Moynihan. There is one suggestion I would make regarding the technic which makes it easier to accomplish our purpose; its value was proved in a recent successful case. First of all, the stomach is carefully washed out and a small opening is made in the gastrohepatic omentum. With fingers introduced through this opening it is easy to separate the stomach from the pancreas. It is then a comparatively simple matter to bring the posterior wall of the stomach through the anterior incision in the stomach wall and deal with it as Dr. Crile has described. The advantages is that one gets an excellent opportunity for thorough examination of the ulcer and one can close it with precision; in my case we suspected cancer but subsequently we found no evidence of malignancy. The objection has been raised that this is apt to produce an hour-glass stomach. In our earlier cases of operations upon the stomach we were apt to turn in a larger area of stomach wall than was necessary; the danger of producing an hour-glass stomach is greatly reduced by carefully conserving the amount of stomach wall included in our stitches. In the particular case mentioned, in which I had an ulcer of large size with a patient in bad condition the operation was done with a minimum amount of shock and there was very little contraction to suggest any

trouble later from an hour-glass constriction. The expedient which Dr. Crile has mentioned would overcome that however.

Dr. C. H. Mayo, Rochester:

In the first place: what is the cause of ulcer? Rosenow's work leads us to believe that infection plays an important role in its causation. Does trauma from swallowing something sharp and hard ever cause ulcer? I think not. An ulcer does not develop from injury alone; the blood supply to an area must be destroyed before it becomes permanently ulcerated. The greatest relief from treatment is obtained in cases in which the acid content of the stomach is high. Paterson's contention that gastro-enterostomy reduces the acids by one-third points to one line of treatment. One of the drawbacks to plastic operations on the pylorus is that they do not lower the acidity of the stomach unless there is a backing up of the duodenal contents.

Of course it is admitted that in ulcer of the stomach cancer is prone to develop, although ulcer in the duodenum is not subject to malignancy perhaps because the duodenum is an alkali-producing field. Many of us have seen ulcers cured by free perforation. In posterior perforations the margins are glued to the pancreas and cannot come together. Some surgeons excise ulcers but will not perform gastro-enterostomies. Others perform gastro-enterostomies but do not remove the ulcers.

HYPERPLASTIC TUBERCULOSIS OF THE SMALL INTESTINE

By JOSEPH RANSOHOFF, M.D.
CINCINNATI, OHIO

The protean manifestations of tuberculosis, which elsewhere demand surgical intervention, are not often staged in the alimentary canal. The terminal ulcerations without any trace of reparative effort found in nearly 40 per cent. of cases of fatal pulmonary tuberculosis are practically never surgical.

In the tuberculous peritonitides which call for operation the causative intestinal lesion has either undergone repair or cannot be found. There remain then two conditions which are distinctly surgical: (1) The strictures from healed tuberculous ulcers, almost always found in the small intestine either singly or in numbers, and (2) the more or less localized processes, which because of their chronicity permit of excessive efforts at repair and therefore assume the guise of neoplasms. It is to this class of cases that the term "hyperplastic tuberculosis" has been given.

Practically all of the cases reported since Hartman and Pillet[1] first called attention to and named this condition have been found in the cecum and the terminal coil of the ileum. Just why this segment of the intestine should be the chosen seat for tuberculosis, typhoid and actinomycotic lesions probably is difficult to answer. Less resistant perhaps because of its fixed position, the first stasis in the there-unto fast moving intestinal

[1] Bull. de la Soc. anat., 1891, p. 471.

current, favoring germ growth and last, but perhaps not least, the trouble-brewing appendix, may separately and together be invoked in explanation of this striking fact.

Cecal tuberculosis in contrast with the widely disseminated terminal type in pulmonary cases is nearly always primary, and appears in otherwise fairly healthy individuals of between twenty and forty years. A few cases have been recorded between ten and twenty years. Guinon and Pater saw one in a child four years old. (Hartman.)

Since Hartman[2] was enabled to analyze 229 operations for cecal tuberculosis before the London Medical Society, and very many more cases have been reported since, there would be no justification in adding one or more of this region. Of tuberculosis of hyperplastic type and limited to the small intestine I have been enabled to find only one other case, that of Soubeyran.[3] The patient was a female, aged twenty-five years. The lesion involved 9 cm. of the ileum. Resection was followed by death nineteen days after the operation.

The case which I beg to present involves the small intestine only, and that at a part far removed from the cecum.

B. S., aged nine years, was admitted to the General Hospital, pediatric service, October 13, 1919. The chief complaint was pain in the stomach. Family history negative. Had whooping-cough three years ago. Last winter patient had scarlet fever, followed by enlargement of the cervical glands. After continuing for five months the gland was removed and was shown to be tuberculous. Cardiorespiratory functions normal. Roentgen ray of the chest shows no enlargement of the lymph nodes.

Digestive System. Patient eats fairly well, but does not drink milk. The bowels move three or four times a day, usually with loose stools. For the past two or three years patient has been troubled with cramps in the stomach, coming on four or five times a day, and having no relation to bowel movement, but coming on soon after food intake and irrespective of the kind of

[2] British Med. Jour., 1907, i, p. 849.
[3] Montpelier Medecine, xiv, 470.

food. Pain is often very severe, causing him to double up. It usually lasts about an hour and is finally relieved by the application of hot-water bottle. Pain sometimes comes on suddenly during sleep. It seems to be localized in a small area immediately to the left and slightly below the umbilicus. Patient does not vomit at any time. Renal and vesical functions normal.

PRESENT CONDITION. Patient is a white male child, apparently about five years of age, but in reality about nine. Expression rather listless, greenish-yellow cast to skin. On the left side of the neck there is an oblique scar, marking the site of previous operation. One small gland palpable in the anterior triangle in the left side of neck.

Chest. Bony framework very prominent, owing to lack of nutrition; development poor. Scapulæ winged, shoulders markedly "rounded," right more so than left, showing a tendency to retraction at the apices of lungs. Veins plainly visible. Spine exhibits marked kyphoscoliosis, right shoulder droops more than left. Expansion fair, lagging over left apex. Percussion elicits impaired resonance posteriorly to left of spinal column in interscapular space. Ausculation; puerile breath sounds heard through chest, no rales heard.

Abdomen. Pot-belly in type; rigidity interferes with palpation; no special tenderness at any point and muscular tension about equal on the two sides. On the left side there is a mass, about the size of an apple, can be felt to the left of the midline, below the umbilicus. The mass appears fixed.

Urinalysis, October 14, 1919.

Blood Examination:

Hemoglobin	65	per cent.
Red cells	3,100,000	"
White cells	7,250	"
Polynuclears	74	"
Large lymphocytes	7	"
Small lymphocytes	15	"
Eosinophiles	4	"

ROYAL SOCIETY OF MEDICINE
16
1922

FIG. 1.—Gross appearance of specimen before section.

FIG. 2.—Appearance after section of wall of intestine.

Temperature slightly elevated and irregular, ranging to 100° in the evening. Pulse accelerated most of the time, in the neighborhood of 100. Stool is well formed, devoid of parasites.

Test of blood negative.

Wassermann negative.

Von Pirquet positive.

Roentgen-ray examination, October 21, 1919, of the intestinal tract, following injection of opaque enema and the giving of barium, shows the tract to be normal in position and size and presents no evidence of filling defect. Barium meal passes normally through small intestine.

November 5, 1919, transferred to surgical service for exploratory operation. Tentative diagnosis: Retroperitoneal tuberculous glands. Ether anesthesia. When complete relaxation of the abdominal muscles was achieved it was found that the tumor mass, irregularly nodulated, was distinctly movable. Through a median incision the mass was easily delivered and was found what appeared to be a discrete growth of the small intestine, situated in the lower part of the jejunum. It involved about seven inches of the gut, and with the exception of a broad omental adhesion at one part it was not attached. The lymph nodes in the mesentery were enlarged in lessening degree from the intestinal attachment toward the root. About ten inches of the intestine were resected, together with the mesentery and an end-to-end anastomosis, with sutures made in the usual way. A thorough exploration of the abdominal cavity failed to reveal any other pathological lesion, nor were any lymph nodes discernible. The recovery of the patient was uneventful. His condition six months after the operation is satisfactory. He attends school regularly, is free from pain and presents no evidence of recurrence.

Pathological Report. The specimen removed is a segment of the small intestine, about ten inches in length. It presents the gross appearance of an irregular tumor mass. On section the tumor mass is found to consist entirely of the enormously thickened intestinal wall. This is very rigid and is cut with some difficulty. In thickness this wall varies from $\frac{1}{3}$ cm. to 1 cm.

At the central part there is an attached tag of omentum 3 cm. wide. Directly underneath this there is an indurated ulcer. There is a loss of substance in the mucosa measuring 1 cm. by $1\frac{1}{2}$ cm. The mesenteric glands on section are of uniform consistency and present no evidence of caseation or other necrotic changes.

The rest of the mucosa, to the naked eye, appears unbroken. The surface has a glazed and uniform appearance; the valvular. folds normal to this part have quite disappeared. Here and there are minute polypoid elevations.

Microscopic Report. In the sections of the tissues fixed with formalin and stained with hematoxylin and erythrosin the much thickened wall of the gut is seen to be composed entirely of small round cells and polymorphous epithelioid cells. Only very rarely a multinucleated giant cell can be found. This sarcoma-like tissue extends from the muscular coat to and into the villi of the mucosa, replacing, for the most part, the tissue of the intestine. In only one section are villi able to be seen, and here the submucosa is filled with epithelioid cells, numerous lymphocytes and a few polymorphonuclear leukocytes. The sections show only a slight amount of connective tissue, but many bloodvessels are present. In a few areas there is a transition from cells that resemble spindle cells (from the outer surface of the wall of the intestine) to uniformly round cells (in the more central portion of the tumor mass). In other areas the tissue is degenerated, the cells being indistinct and their nuclei staining very poorly. There is no definite structure or arrangement of the cellular elements but only a diffuse cellular proliferation.

Bacteriological Report. Attempts were made to stain acid-fast and other bacteria with negative results. It must be said that failure may have been due to the method of fixation used.

Remarks. The above case presents several points of interest. The outstanding clinical sign, which should have led us to a correct preoperative diagnosis was the severity and frequency of the intestinal cramps, which were present for a year or more.

The growth appearing fixed until complete abdominal muscular relaxation was obtained, under anesthesia, and the previous

FIG. 3.—Small-cell infiltration of villi.

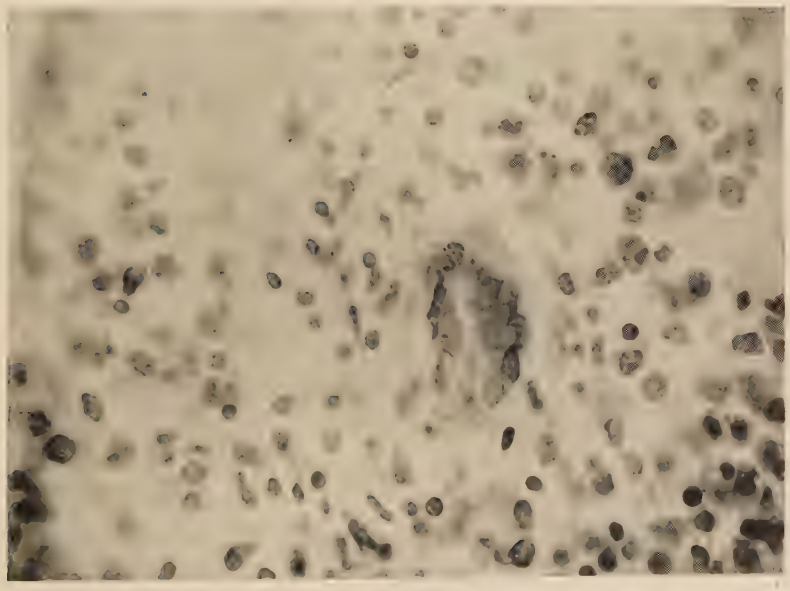

FIG. 4.—Giant-cell infiltration of villi.

existence of enlarged glands in the neck, led us to believe the mass to be probably of retroperitoneal type. This case well represents, therefore, the clinical value of abdominal examination under anesthesia.

In contradistinction to the value of roentgen-ray examinations in diseases of the stomach and of the large intestine it is found in this instance, as is generally the case, that neither fluoroscopy nor the taking of radiograms is of much service in lesions of the small intestine.

I have termed this a case of hyperplastic tuberculosis. Of its originally being tubercular in character there can be no question. A study of microscopic sections, however, makes one feel that in many ways the cells resemble those of an ordinary type of lymphosarcoma. A differentiation from microscopic appearances alone seems impossible, and it is a question in my mind whether it is not possible that we are dealing with the development of a sarcomatous condition in what was primarily purely tubercular. Of the tuberculosis one must be certain, because of the clinical history and the ulcer, and perhaps the policeman-like characteristic work of the omentum, as shown in the illustrations. Unfortunately, because of faulty preparation of the specimen when removed, the bacillus could not be demonstrated.

The absence of metastasis at the time of the operation, and the continued well-being of the patient, leads me to hope that the suspicions of malignancy are not well founded. Nevertheless, there have been a few cases reported, particularly of the intestine, in which tuberculosis was associated with sarcoma, and particularly lymphosarcoma.

According to Mikulicz[4] a combination of tuberculosis and sarcoma, especially of lymphosarcoma, is not unusual. Nothnagel in one case found a lymphosarcoma developed in the base of a healed tuberculous ulcer. A further difficulty is that sarcoma of the small intestine appears in a diffuse form over quite extensive segments of the gut.

[4] Handbuch der Praktischen Chir., iii, 373.

The question of the relation of tuberculosis to malignant disease is not a new one. Since the days of Rokitansky, and after him Virchow, there has been a general belief that tuberculosis and malignant growths do not develop in the same soil. As a rule this is unquestionably true, but by numerous cases it has been shown that they are not incompatible. The most recent publication upon this subject, although it relates more to carcinoma than to sarcoma, in relation to tuberculosis, comes from the Mayo Clinic, in an article by Broders.[5] He reports on 20 cases of tuberculosis and malignant disease occurring in the same organ or tissue eight times, or 40 per cent., in seven cases, or 35 per cent., the two conditions were actually associated in the same microscopic field.

[5] Mayo Clinic, 1919.

FAILURE OF PRIMARY ROTATION OF THE INTESTINE (LEFT-SIDED COLON) IN RELATION TO INTESTINAL OBSTRUCTION

By EMMET RIXFORD, M.D.
SAN FRANCISCO, CALIF.

Whatever be the cause of the inhibition of the primary rotation of the intestine, it is perfectly obvious that when this condition is accompanied, as is usually the case, by failure of fixation of the mesentery of the midgut, the conditions are ideal for the production of volvulus of large portions of the intestine. In this condition, which for brevity's sake is often called "left-sided colon," the mesentery on the right side ordinarily does not adhere to the posterior peritoneum. Why, we do not know unless it is because we have to do with the mesentery of the small intestine.

In the normal condition of rotation of the intestine, when the hepatic flexure of the colon grows over to the right or is pushed over by growth of that portion of the transverse colon which lies to the right of the duodenum, the superior mesenteric artery, through its large branch, which becomes the middle colic artery, furnishing a relatively fixed point, the large intestine itself generally adheres on the right side, though not so uniformly nor so extensively as the descending colon adheres on the left side, and it is not unlikely that adhesion of the intestine occurs before that of the mesentery. At least the irregularity of the mesenteric adhesion leaving, as it often does, crypts and fossæ which are sometimes of surgical importance in relation

to internal hernia, suggests that the intestine adheres first. The mechanism of this adhesion is also unknown. It is hardly competent to say that it is congenital. The fine cicatricial bands which are commonly observed about the ascending and descending colon suggest that the cause of the adhesions is some prenatal inflammatory process, prenatal peritonitis, if you will. Possibly the large bowel is less actively mobile and more penetrable by irritating substances. Certainly there is much material absorbed by the colon in prenatal life desiccating the fluid contents of the small bowel into the stiff paste of meconium. If a prenatal inflammation of the outer wall of the large bowel is presupposed it would readily enough account for these adhesions and other congenital bands which are not infrequently found. Such explanation has been offered for the production of this most interesting congenital anomaly: the failure of rotation of the intestine. An example of an adventitious band occurred in the second case here reported in which there was found a cord-like mass of tissue leading from the posterior wall of the abdomen to the posterior surface of the cecum, which lay in the right iliac fossa notwithstanding the fact that the small intestine lay completely to the right of the colon. The band was manifestly the result of adhesion of the cecum. Such a band of adhesion would furnish perfect conditions of obstruction by herniation of loops of bowel through the opening between it and the mesentery, but also if it were accompanied by "left-sided colon" it would furnish a fixed point about which the entire intestine might be twisted, making a double volvulus—right and left.

Under normal conditions that part of the intestine between the lower part of the duodenum and that portion of the transverse colon which is supplied by the mesocolic artery rotates to the left, *i. e.*, so as to form a left-handed spiral at the point of crossing of the large and small intestines, throwing the duodenum to the left beneath the superior mesenteric artery, so that afterward the artery is found to pass down directly over its anterior surface. The angle of this left-handed rotation

is said to be 180°, but, as a matter of fact, it is 270° or more, for in early embryonic life, when the intestine is attached to the umbilicus by the vitelline duct, the mesentery lies in the sagittal plane. As the gut grows and the loop of the small bowel and

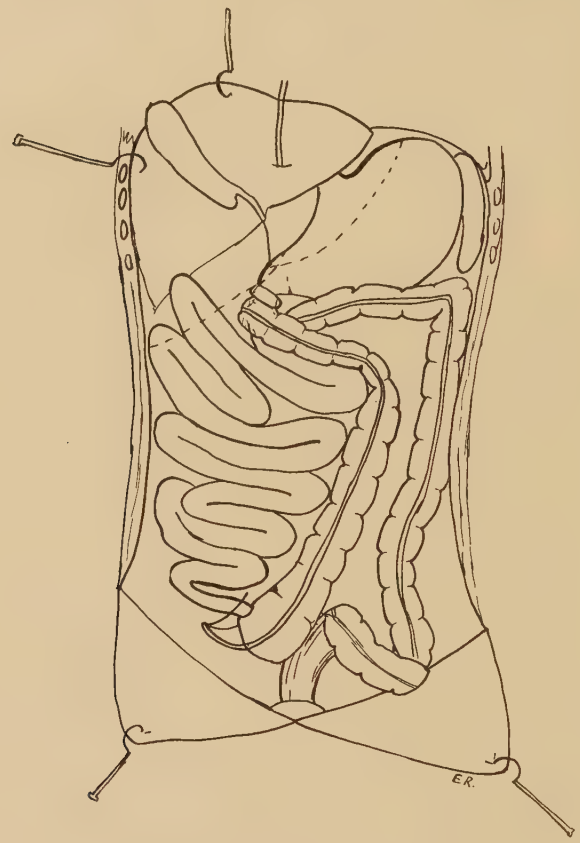

Fig. 1

cecum became drawn out and rotation takes place, as it were, about the vitelline duct or Meckel's diverticulum as an axis, what was originally the left side of the mesentery becomes not merely the right side (rotating 180°, which would place the large bowel simply in front), but by further rotation of 90° becomes the

posterior layer, *i. e.*, it adheres to the posterior layer of the peritoneum and lies in the coronal plane or beyond.

It is said that bands of adhesions are sometimes the effective cause of the inhibition of rotation, but of the three cases of "left-sided colon" here reported such were not made out in the first case although a most careful autopsy was made. In the second case observation is simply lacking, since in the hurry of a desperate operation there was neither time nor justification on other grounds for extended search after interesting phenomena. In the third case, however, there were very definite bands, one on each side, nearly an inch wide, consisting of simple fibrous tissue, which if of inflammatory origin, must have been very old, even prenatal, for they presented no evidence of inflammatory reaction, no thickening, no cicatricial contraction, no adventitious bloodvessels. Had they been the result of bacterial inflammation secondary to the volvulus they would almost certainly have contracted sufficiently to have caused strangulation of the intestine or fatal obstruction. But admitting that these bands were the cause of the failure of rotation of the intestine there is still a question as to their origin.

In the three cases here reported, all that I happen to have seen of "left-sided colon," the condition was found at operation for intestinal obstruction. In the first case the obstruction was not the result of the congenital anomaly but was due to carcinoma of the transverse colon. In the other two the failure of rotation of the gut and fixation of the mesentery was the predisposing if not the direct cause of the obstruction.

Case I.—A man, aged sixty-two years, merchant, of Seward, Alaska, who had always enjoyed rugged health, came to operation for obstruction of the transverse colon which had been progressive for a year. The distention was greatest on the right side and in the upper abdomen. Incision for a proposed right inguinal colostomy showed the right flank filled with distended hypertrophied coils of small intestine, the cecum was not found; a large, hard, fixed tumor in the region of the transverse colon; liver filled with metastases; an immense elastic

coil of distended colon on the far side of the small bowel, evidently the ascending colon. The hepatic flexure was successfully brought to the lateral abdominal wall in front of the small bowel, sutured into the incision and opened some hours later. The patient escaped peritonitis but succumbed on the fourth day to bronchopneumonia. Autopsy showed "left-sided colon," no cicatricial or other bands about the duodenum or jejunum, carcinoma of transverse colon, involving the mesentery and invading the portal vein with a shower of metastases in the liver.

In brief, the "left-sided colon" in this case in no wise interfered with a long and active life, but the unusual and not to be anticipated location of the colon with reference to the distended loops of small intestine added much to the difficulties of the operation for relief of the obstruction.

Case II.—A woman, aged forty-one years, mother of one child, had always been strong and well until depleted by hemorrhage from a large myoma. Hysteromyomectomy, rendered difficult by extensive adhesions from some old pelvic inflammation, entailed considerable traumatism to the lower peritoneum. Because of the weakened condition of the patient time was not taken for exploration of the upper abdomen nor removal of the appendix. Patient made an excellent primary recovery, but on the fifth day developed a temperature of 102° and on the sixth day, 105°, pulse 124, leukocytosis, vomiting, evidence of infection of the uterine stump and abdominal distention more marked on the right side. Enemas, hot compresses and withdrawal of food gave much relief The distention which remained was thought to be due to inflammatory ileus or to obstruction from adhesions about the cecum. Patient so far recovered as to be able to take food for about a week, but the symptoms of obstruction became more marked and secondary septic symptoms coming on the abdomen was opened on the nineteenth day. The distention was entirely in the cecum and small bowel. The cecum was adherent to the anterior abdominal wall, where it had perforated. The appendix, which was six inches long, was inflamed and adherent by its tip to the uterine stump. It was

first removed to get it out of the way, and then it was found that the obstruction of the colon was due to volvulus, a right-handed twist. The twisting was difficult to explain because the relations of the terminal ileum and cecum were normal and the mesentery of the cecum was attached to the posterior abdominal wall by a cord nearly an inch in diameter and six inches or more long. The rotation in the volvulus therefore could only have occurred by the gut (cecum and portions of the small intestine) passing around itself as an axis, the mesenteric cord being a sort of pivot, at a time anterior to the attachment of the appendix to the uterine stump. The most likely explanation is that in withdrawing gauze pads which were used to hold the intestines back in the first operation they rubbed or pulled on the bowel sufficiently to give it the right-handed twist. When the volvulus was untwisted the large bowel was found to be necrotic in spots and had to be resected. There were embarrassments in making the necessary lateral anastomosis, for the ascending colon was in the pelvis and adherent and led upward toward the splenic flexure on the left side of the small intestine. Anastomosis was accomplished and the patient made a normal recovery. She was well when last seen, some six years later.

Case III.—A boy, aged five years, whose history from birth was that of a delicate child who suffered from early infancy from recurring attacks of colicky pain and vomiting. His nutrition was always the greatest concern of his parents, but he managed to grow somewhat in spite of his starvation. He was bright mentally and had learned to refrain from eating whenever he felt one of these attacks coming on, and that was quite frequently, for when the stomach was empty the attacks sooner subsided. He had never known what it was to have a full meal. When he came under our care he was just recovering from his severest attack of obstruction. He was far below normal in weight, had almost no fat, his face was pinched and purplish and his extremities blue and cold. He was too weak to be up more than a short time each day. Loth to move, he was quite content to lie in bed and watch other children play.

The abdomen was distended above but was concave below; the abdominal wall tense, as in the atrophy of starvation but not spastic. No tumor could be made out. No icterus.

From the history and the findings it was evident that the child was suffering from some form of chronic obstruction high up in the intestine, not complete, but probably due to some

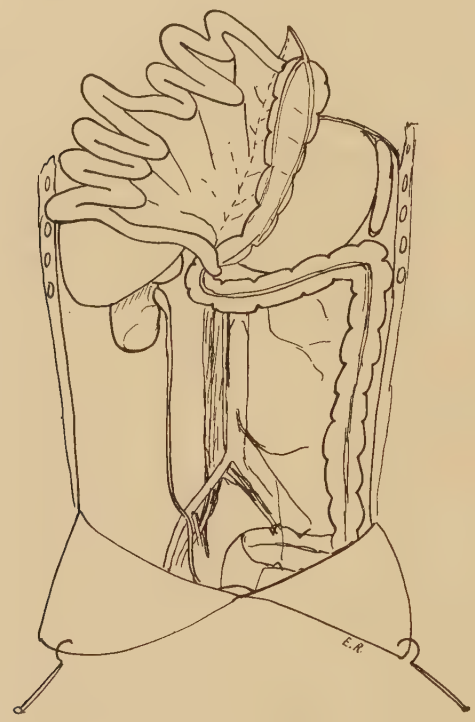

Fig. 2

congenital anomaly. We thought possibly congenital stricture of the duodenum or hypertrophic pyloric stenosis. After administering fluids by rectum we opened the abdomen and found the explanation of the obstruction in a volvulus of the intestine at a point just below the biliary papilla. Included in the volvulus was the entire small intestine, the ascending and

part of the transverse colon. Only the stomach, pylorus and upper duodenum were distended; the remainder of the intestine was collapsed.

The entire mass of the intestine having no other attachment than at the point of the twist, which consisted of a cord hardly more than an inch in diameter, was lifted bodily out of the

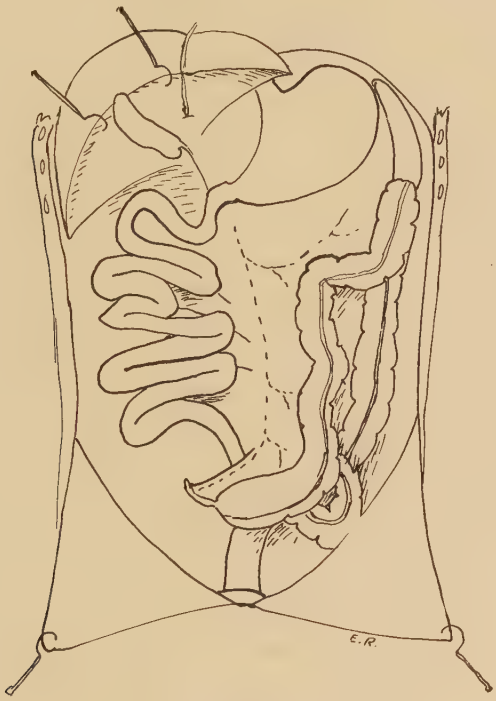

Fig. 3

abdomen. The posterior peritoneum was continuous from the descending colon across to the right side of the abdominal wall, and because of the absence of fat was transparent, so that the right kidney and ureter, the aorta and the vena cava and their branches were clearly visible in their normal relations as in an anatomical drawing. The left kidney was not visible, being covered by the descending colon and its mesentery. When

lifted out of the body the intestinal mass could be twisted about at will freely in any direction. The mesentery seemed to be disposed somewhat in the form of a trough, with V-shaped cross-section ending at the ileocecal valve, with the superior mesenteric artery running along the apex of the angle, and, in the coronal plane, making nearly a straight line for the meso-appendix, in which it found its termination.

Untwisting the bowel to the left through a complete circle (360°), two bands of fibrous tissue came into view, one on each side, binding the duodenum to the transverse colon, so that they were in contact. The bands were cut, care being taken not to injure the mesenteric artery and vein, and this permitted the loops of intestine to be separated an inch or more. The intestinal mass was then laid in the abdomen in the normal relation of rotation, the ascending colon to the right, the small bowel to the left, the superior mesenteric artery passing in front of the duodenum. The tissues assumed this so-called normal position quite readily. The boy reacted normally—in fact, began almost at once to make up for his five years of starvation. He grew like the blossom stalk of an aloe, and is now a strapping normal boy of thirteen.

ACUTE INTESTINAL OBSTRUCTION: THE CAUSE OF THE CONTINUED HIGH MORTALITY AND HOW IT MAY BE REDUCED

By JOHN E. SUMMERS, M.D.
OMAHA, NEBRASKA

Almost the last written words of the late John B. Murphy were upon subjects included in the title of this paper, and I want to make a short quotation from what he wrote: "From most reliable statistics we find 40 per cent. mortality in acute intestinal obstruction. One may well ask, Will this appalling mortality ever cease? Why does it exist? Because the diagnosis is not made in time for a life-saving operation. The technic in this line of operation is superlatively good, but the clinical recognition is extremely tardy." Personally I believe that both the operative technic in certain instances and the postoperative treatment can be greatly improved, thus contributing toward lessening the mortality.

In a paper published in the *Annals of Surgery*, February, 1915, entitled "The Mortality Statistics of Two Hundred and Seventy-six Cases of Acute Intestinal Obstruction," Deaver shows that of these 276 cases there were 118 deaths, or a mortality of 42 per cent. All of these patients were admitted into the German Hospital under his care during a period of ten years. There were 156 cases of strangulated hernia and 120 of the different types of internal strangulation. In 241 cases there were adequate records of the average time from the onset of the condition to the time of operation. In the cases that recovered it was 61.7 hours, or over two and a half days, and in the

cases that died ninety-seven hours, or four days and one hour. Deaver remarks, "Under such conditions it is to be wondered at that so many cases had a fortunate outcome." In a letter of recent date, Deaver writes me and says: "In my hospital and private practice I have not noticed any decrease in the mortality of acute intestinal obstruction since 1915, nor have I noticed any difference in acute appendicitis; both conditions are either not recognized early or have been badly treated by purgation, as you and I both know. The younger men who have graduated in the last two or three years, I am sure, will be the ones to reduce this mortality. I quite agree with you, too much has to be gone over before the essential is grasped."

Sir Berkley Moynihan says that "To operate early in a case of intestinal obstruction is an experience that few surgeons often enjoy." He says that "There are few surgeons who can show a mortality lower than 50 per cent."

In every country where medical education is acknowledgedly in keeping with the age the same story is told—patients with intestinal obstruction come to operation too late, hence the chief reason for the high mortality. One report from St. Bartholomew's Hospital, London, gives a recovery of only 15 cases out of a total of 60. In France and Italy the same kind of reports are to be found.

Before this audience it would be a supererrogation upon my part to attempt to add anything in the differentiation of acute intestinal obstruction from other pathology as generally recognized within the abdomen, but I would strongly recommend the teachings of the late J. B. Murphy, as published in his *Clinics*, as the best expositions of the diagnosis of acute intestinal obstruction.

I would also like to recommend particularly the writings of our fellow-member, John B. Deaver.

When the diagnosis is made within the first twenty-four hours, the operation done promptly, the obstruction relieved and the gut viable the patient usually recovers. The small mortality results from the same causes as when the operation is done

later, only there is added in the latter the condition of enormously distended intestines filled with poisonous gases and fluids. In no circumstances should the bowel ever be left in this condition. It should be largely evacuated through one or several small incisions which are later closed with perhaps a drain in one, fastened in with purse-string sutures. I do not like the employment of an enterotomy tube as recommended by Moynihan, for the immediate drainage of the distended bowel. If the same patient has been copiously vomiting foul, fecal-smelling fluids my judgment is that through a high left rectus incision a 20–22 (French) catheter should be introduced into the jejunum as near the origin as recognizable and fastened in as indicated above. Nature points out the route; the drainage direction has become retrograde; the intestinal current is reversed; its drainage will remove the source of the fatal auto-intoxication which is killing the patient; the absorption, too, from the upper small intestine, considered so fatal, is greatly reduced. *The vomiting ceases.* This is a positive proof of the efficacy of the procedure. It is remarkable the large amount of foul fluid that will drain out of a catheter so placed; very much more and in a much shorter time than will take place through a drain introduced in the lower part of the distended gut. When we consider that Nature is trying her best to rid the bowel of its poisonous contents and relieve the pressure against the obstruction by reversing the current and expelling the fluids and gases by vomiting, not to assist her by opening the jejunum would appear unfair. I am convinced also that in advanced cases the introduction of a catheter drain into the jejunum will not infrequently save life provided no attempt is made to open the abdomen for exploration or other surgical effort. The cause of the obstruction can be taken care of later. Of course, there is always the risk of a fatality from peritonitis secondary to gangrene. Postoperative peritonitis with paralytic obstruction and foul vomiting should be given the hopeful help of a jejunostomy. It can be used as a prophylactic measure when postoperative peritonitis may be

anticipated. My attention was first called to this jejunostomy procedure by a paper of Victor Bonney's in the *British Medical Journal*, April 22, 1916, entitled "Fecal and Intestinal Vomiting and Jejunostomy." He had advocated and practised the procedure and published it in the *Middlesex Hospital Reports* in 1910. He reported 6 successful cases. Bonney's technic was the establishment of drainage through a jejunal fistula, which later required a second operation to close.

McKinnon, of Lincoln, Neb., who has saved a number of lives by the technic I have outlined, says that the catheter comes away after two or three days and that the opening in the jejunum closes shortly afterward. My experience is the same. We know that the opening closes likewise when the catheter is properly placed in the bowel lower down. Bonney divides the obstructed intestine into three segments: the lower, middle and upper; the lower more or less collapsed, the middle containing gas and the upper containing fluid. My experience is that the lower and middle segments contain gas chiefly; the upper segment most of the fluids.

"The character of the vomited matter indicates the condition of the upper part of the intestinal tract, for when the vomiting is fecal or intestinal the stomach forms the highest part of the fluid-containing segment. This upper segment does not necessarily reach as high in every case of intestinal obstruction when it first comes under clinical observation, nor need it at first include any part of the small intestine; for if the primary obstruction is situated low down in the large intestine, the total area of distention may not at first extend above the ileocecal valve. In such the 'segment of toxicity' will comprise the cecum and descending colon. In this phase the vomit is neither fecal nor intestinal, but simply the stomach contents. In all cases of obstruction, however, the stomach and jejunum will eventually be included in the fluid-containing segment, and as soon as this occurs the fact is made patent by the change in the character of the vomit, which at first becomes intestinal and finally fecal.

"This upward extension of the limits of the fluid-containing segment is due to a rapid upwardly extending infection of the canal by organisms of the lower intestine."

As Bonney says, "The drainage opening must tap the fluid-containing segment."

When the obstruction is in the sigmoid a drain should be put into the cecum. My time is too limited to more than suggest the intra-abdominal technic indicated by conditions presented. When the mechanical cause of the obstruction has produced gangrene of the annular or napkin ring area type, resection should not be done but the gangrenous area should be invaginated as an intussusceptum, and the gut properly sutured so as to form an intussusception. The gangrenous part sloughs off and the integrity and continuity of the canal are restored. I introduced this technic, reporting cases, in a paper published in the *Journal of the American Medical Association*, 1907. It is a reliable procedure and its principles can be broadened. I have recently shown in the December, 1919, number of the *Nebraska State Medical Journal* how the principle can be applied when resection is deemed advisable. Girdin, of Rio-de-Janeiro, adopted my suggested method of resection without opening the gut, and Pauchet recently reported in the *Bulletins et Mémoires de la Société de Chirurgie de Paris* 3 cases of megalocolon resected after this manner. The making of an anastomosis, thus side-tracking an obstruction is a wise thing to do if the releasing of the obstruction threatens to injure the bowel so that a resection might be necessary. The saving of time is one of the most important elements in the carrying-out of a successful operation.

I am a great believer in the scientific principles upon which Crile bases his operative and postoperative treatment in general surgery, and more particularly so in its application in grave cases of abdominal surgery. The profession, except perhaps in goiter surgery, has not grasped the importance of Crile's work.

Crile says that "by employing water, hot-packs and morphin in postoperative treatment—this latter to reduce the respiration 10 to 14 per minute—the surgeon can play the patient almost at

will. The control of the drive as marked by the changes in the respiratory rate in particular is dramatic. Morphin lowers the respiratory rate, decreases the peristalsis of the intestines, reduces pain and secures physiological rest and sleep, the prime means of recuperation."

This same kind of postoperative management is the one I have been using for some time and it gives me great confidence in handling dangerous cases. As far as the employment of morphin is concerned it has always been my practice to employ it as Crile indicates. Alonzo Clark was my teacher and I have always followed his teachings in the treatment of peritonitis. I have never been guilty of giving salines in the treatment of peritonitis, which was for some years in vogue as the result of the recommendations of several surgeons and physicians then in high authority. I am convinced that by early operation and the doing of only the essential, doing it rapidly and well, the establishment of proper drainage, and the employment of the "anociated" treatment, the mortality of acute intestinal obstruction can be reduced 25 per cent., perhaps 50 per cent. In reply to a recent personal note to Dr. Crile he writes me: "In our clinic the high mortality attending the critical situation presented by acute intestinal obstruction did not begin to fall until we became cognizant of the damage resulting from auto-intoxication, *per se*. With the recognition that this danger by so much lessened the patient's chance for recovery we employed the shortest possible operation, avoided lipoid solvent anesthetics, employed hot packs and the Alonzo Clark opium treatment after the operation, with sodium bicarbonate and glucose per rectum. A study of over 219 operations for intestinal obstruction shows a falling mortality rate beginning with the adoption of the methods outlined above."

Among a number of cases of intestinal obstruction seen during the past year I want to briefly report, as illustrative of types, 6 operated cases:

1. Acute obstruction in a case of carcinoma of the sigmoid. A large heavy man, aged fifty-four years. Late operation.

(Clarkson Hospital), third day of obstruction; exploration disclosed a carcinoma of the sigmoid adherent to the abdominopelvic wall; small bowel and colon much distended and dark in color. Cecostomy; three weeks later, resection of the sigmoid; deep cauterization, with soldering irons, of the area where the carcinoma was adherent to and infiltrating the abdominopelvic wall. Later closure of the cecostomy. Man now in perfect health. Operation done one year ago.

2. Woman, aged fifty-five years; in poor general health; acute obstruction from carcinoma of splenic flexure of the colon. Exploratory incision (Clarkson Hospital); colon much distended; cecostomy; two weeks later, resection of the colon; death in a few days from exhaustion.

3. Woman, aged forty years; marked abdominal distention; foul vomiting. Late operation (University Hospital). Median incision—small bowel very dark and enormously distended. Nearly two basinfuls of contents evacuated through three small incisions; openings sutured; anastomosis by suture around a loop of small gut adherent to the left abdominal wall—so tightly adherent as to cause obstruction and in a condition so threatening perforation that I feared to attempt its release. Patient left the table in a collapsed condition but recovered.

4. Young man entered the Clarkson Hospital; he was very sick, having been ill for ten days with appendicitis; there was a large abscess bulging in the lower middle abdomen; incision and drainage of the abscess was done; a fecal fistula developed, evidently in the lower ileum. The bowels moved naturally and through the fistula; later only through the fistula. Operation: anastomosis by suture around the fistula; death some days later from exhaustion. Postmortem disclosed the anastomosis perfect; fistula in ileum only a few inches from the ileocecal valve.

5. Woman, aged thirty-eight years. Operated in a neighboring city (Fremont). Acute obstruction for forty-eight hours; foul vomiting; considerable distention. Incision disclosed that the obstruction was due to a band, probably from a pelvic operation done four years previously; the band was divided.

Although the intestines were distended and dark I did not drain them and I believe I took an unwarranted chance in not doing so. The woman recovered.

6. A man, aged sixty-five years, came to the Clarkson Hospital with an appendicular abscess, which was opened and drained. Before the wound closed he developed an acute intestinal obstruction. A jejunostomy as described was done at night, under local anesthesia, the patient being in bed. Relief was prompt; the obstruction was overcome and the jejunostomy incision closed satisfactorily.

Conclusions. 1. Teachers of medicine and surgery should impress by personal acts the philosophy of early diagnosis and prompt surgical treatment.

2. A safe two- and three-stage operation is preferable to any radical procedure, which would add much risk as a completed operation.

3. When vomiting has reached the stage of being foul and fecal-smelling, always drain the small bowel as high in the jejunum as it is recognizable. Nature points out this route.

4. Anesthesia should be local, plus gas oxygen if necessary.

5. Postoperative. Opium should be administered after the Alonzo Clark formula. Large quantities of normal salt solution should be given by hypodermoclysis. Sodium bicarbonate and glucose in 5 per cent. solutions should be administered by the Murphy drip method. Under this treatment the skin will be active if kept warm and reaction from shock and toxemia favored.

MESENTERIC THROMBOSIS: WITH A REPORT OF SIX CASES

By GEORGE G. ROSS, M D.
PHILADELPHIA, PA.

Thrombosis of the mesenteric vessels is a condition of interest to the surgeon, not only because of its comparative rarity but also because of its gravity, the difficulty of diagnosis and the corresponding lack of success in its treatment.

Two cases of mesenteric thrombosis are noted in the records of the Lankenau Hospital, Philadelphia, in a period of ten years (1909 to 1919), during which time there were about 30,000 surgical admissions.

The anatomical points in this connection are well known and need be only hastily reviewed. The superior mesenteric artery alone supplies the small intestine and practically all of the large bowel, with the exception of the descending colon, sigmoid and rectum. The duodenum has a double blood supply. The superior mesenteric artery is stated to be an end-artery; the inferior mesenteric is said not to be.

The superior mesenteric artery then is not only much more frequently the seat of the thrombosis, but the condition in this vessel or its branches should be correspondingly more serious than when it occurs in the inferior mesenteric area. The latter statement would be difficult of proof, because in either location the condition is of such gravity that recovery is extremely rare.

There seems to be no doubt that arterial blocking in the mesentery is far more common than obstruction of the venous circulation. Statistics have been given to show that it is twice as frequent (other authors state the ratio to be five to one).

In the reported cases there has often been no effort to differentiate between thrombosis of the mesenteric vessels and embolism. Indeed, this must often be impossible. The symptomatology is the same in either case, and even at operation or autopsy it is difficult to determine whether in a given case we are dealing with primary thrombotic or embolic condition. Venous conditions are, of course, thrombotic.

Arterial obstruction occurs either by embolic plugging of the vessel or thrombotic obliteration or by thrombosis developing at the site of lodgment of an embolus. (Smith, *Wisconsin Med. Jour.*)

Venous obstruction is said to be either of the ascending or descending variety. Whatever the nature of the beginning of the process, its course, prognosis and treatment are the same.

There have been described also certain forms of vascular stoppage more chronic in character, but all of those with which the surgeon has to deal are acute in their course.

Perhaps of more interest as a classification is the division of these cases into those in which the process is the primary one surgically, *i. e.*, the one for whose diagnosis and treatment the surgeon is called (*vide* Cases 1, 2, 3, 4 and 5) or those in which the condition follows directly after some surgical condition (Case 6), already dealt with as a complication or secondary involvement.

A great deal of attention has been given to a consideration of symptoms and diagnostic points in connection with mesenteric thrombosis. Elaborate classification and tabulations of histories and groups of cases have failed to bring out a symptom-complex upon which even a probable diagnosis can safely be made in a fair percentage of the cases seen. It is true that in some of the instances, especially those that are postoperative, slow in onset and of the venous form of thrombosis, there are no symptoms which would even lead us to suspect the true condition interfering with the patient's recovery.

A consideration of the sequence of events in thrombotic conditions will at once point out the chief fact in symptomatology and diagnosis, and one practically always overlooked.

When a thrombosis occurs the blood supply of a certain segment of intestine is stopped or diminished to a great degree. With the diminution in blood supply of such a segment there comes the natural lessening of function, manifested as lessened peristalsis. If the segment of bowel affected be other than a very minute one, peristalsis ceasing in it soon causes stoppage, due to local paralytic ileus, and we find that the case develops the signs of intestinal obstruction. Of the further changes, gangrene, perforation, etc., little need be said. They are terminal stages only.

To repeat, the symptoms of mesenteric thrombosis, insofar as they may be grouped, are the symptoms of an acute intestinal obstruction.

We have not even arrived at a point of diagnostic skill that enables us to differentiate with certainty the variety of intestinal obstruction when such an obstruction is known to exist. How much more difficult it must always be to recognize definitely the occurrence of such a rare cause of diminished or absent intestinal action as mesenteric thrombosis. But we should always be able to recognize the fact that there has taken place a grave occurrence within the abdomen demanding immediately definitely planned and executed surgical attention.

In the five cases which I have to report pain was a prominent symptom, as it is in every acute intestinal obstruction.

In Case 1 (Germantown Hospital, January, 1919) the patient was taken sick ten days before admission with a severe attack of abdominal pain in the region of the umbilicus, and then becoming general throughout the abdomen. Similar (?) attacks have been noted for fourteen years prior to admission.

In Case 2 (Germantown Hospital, February, 1919) the attack began suddenly, with abdominal pain, nausea and vomiting.

In Case 3 (Lankenau Hospital, 1915) the chief complaint is given as pain over the whole abdomen. It is described in detail in the history as beginning seven days before admission as an epigastric pain of gradual onset, becoming worse three days after the beginning of the pain.

In Case 4 (Lankenau Hospital, 1917) the illness is described as beginning two days before admission, with pain in the right lower abdomen, soon followed by vomiting. In this case the pain remained localized in the right lower abdomen.

In Case 5 (University of Pennsylvania Hospital, service of Dr. Deaver) the patient was seized with a severe pain in the epigastrium.

It is evident then that we have in all five cases a very definite history of pain as an early symptom, in only one of the instances described as of general onset.

A brief consideration of the case histories themselves will make plain the fact that these are cases of obstruction not often diagnosed.

Case 1, operated upon by my assistant, Dr. Wm. B. Swartley, at the Germantown Hospital. About ten days before admission the patient began with a severe attack of abdominal pain in the region of the umbilicus, radiating and becoming general, although worse near the midline and about the umbilicus. There was much tenderness and rigidity. The patient had not been constipated. Shortly after admission to the hospital there was a peculiar looking tarry stool.

The patient states that for the last years she has had frequent attacks of severe abdominal pain, coming on suddenly, causing her to go to bed, and to be away from her duties seven to ten days. At these times the pain was located in the central part of the abdomen and in the right lower quadrant; the abdomen was sore and rigid; the bowels often constipated. She had anorexia and at times vomiting during these attacks. Such attacks occurred three or four times a year.

The history otherwise is unimportant; no menstrual disturbances; one child, living and well.

Physical examination shows a fairly well-nourished woman of forty years. The patient is extremely anemic but not jaundiced. The tongue is coated. The patient has pyorrhea to a marked degree.

Chest shows slight dulness over the apex of the right lung. No rales.

The heart shows slight enlargement to the left and a soft systolic endocardial murmur, which is not transmitted.

The abdomen is distended and tympanitic. Much general tenderness and rigidity on deep pressure and an area of dulness in the right flank suggesting fluid. No peristalsis is heard. No palpable masses or liver enlargement were found. The pain on pressure is slightly more severe to the right of the umbilicus. Vaginal examination negative.

The leukocyte count, January 5, 1919, was 15,000; on January 6, 1919, it was 9000; hemoglobin, 26; red blood cells, 2,690,000. Occult blood test on fecal matter was negative January 6, 1919, but a note, January 13, 1919, states there were definite signs of intestinal hemorrhage. The urine showed a faint trace of albumin.

A right rectus incision was made and an appendix showing chronic obliterative appendicitis was removed. One foot of the lower portion of the ileum was found to be black and almost gangrenous, due to a thrombosis of the branch of the mesenteric artery supplying the portion of the bowel. There was a V-shaped infarcted area in the mesentery. The patient's condition did not permit of resection and the wound was closed and the patient put to bed. Under intravenous saline and stimulation the patient lived about four hours.

The appendix removed was 30 and 5 mm. The canal was obliterated. The coats white, fibrous and thickened, and the appendix somewhat hooked, due to a shortening of the meso-appendix. This case shows several features of great interest. The history shows first a pyorrhea, a possible original focus of infection. The condition of the removed appendix and the history suggest previous attacks of acute or subacute appendicitis. The heart murmur suggests a possible endocarditis and the origin to be an embolus instead of a simple thrombosis of the mesenteric vessel.

The findings on admission show clearly the picture of a late stage of obstruction. The bloody stools and anemia secondary to intestinal hemorrhage are said by some authors to suggest

thrombosis. Such a marked anemia, however, wou'd be more likely to be taken, other things being equal, as pointing to possible malignant disease.

Most striking, however, is the ten-day interval between onset and operation, rendering cure out of reasonable expectation.

Case 2. Miss C. J., aged sixty years. The patient was admitted to the Germantown Hospital February 21, 1919, having first been seen on that day by Dr. Moxey, who at once realized the gravity of her condition. The patient was sent in with a diagnosis of acute obstruction—this being entirely correct. The patient when first seen by her physician had been ill about two days. The onset had been sudden, with severe abdominal pain, nausea and vomiting. The patient had been constipated and had, without avail, used both purgatives and enemata.

Physical examination showed a heavily built woman evidently very ill; in fact, *in extremis*. She was dyspnœic and cyanotic. The abdomen was distended and tympanitic, but not rigid. No peristalsis; the patient complained of nausea but there was no retching or vomiting. A fatty myocarditis may have been a factor in causing the respiratory embarrassment.

Operation was undertaken as a forlorn hope. The patient died before anything could be done to relieve her condition. The small intestine, for approximately ten feet, was found to be gangrenous, swollen but not markedly distended. The mesenteric arteries were thickened, rigid, hard and thrombosed, and there was no demonstrable attempt at the formation of a collateral circulation. The cecum and ascending colon were thickened and distended and the hepatic flexure moderately bound down by adhesions but not obstructed.

This case shows the involvement of a far greater extent of gut than Case 1, a complete shutting off of the blood stream and a fulminating course. Had this patient consulted a physician at once some hope could have been entertained for her, since her condition would have been evident at any time after the onset of the disease and early operation with resection might have been possible.

Case 3 (Lankenau Hospital, operated on by Dr. John B. Deaver). B. B., aged forty-six years. Admitted February 13, 1917. Two days before admission the illness began with pain in the right lower abdomen. The pain continuing, after a few hours the patient began to vomit. He was given purgatives but the patient's bowels did not move and the pain continued more or less constantly up to the time of admission. The patient complained of no fever or chill but showed marked anorexia.

His previous medical history notes: "Two previous attacks of pain—one a month ago and one six months ago."

On admission the patient is seen to be fairly well nourished. The abdomen was somewhat distended, with a tumor-like fulness in the right iliac fossa. There was rather marked tenderness and rigidity in the lower right abdomen, where a mass was vaguely palpable. Peristalsis was present in the upper and left portions of the abdomen. Rectal examination revealed distinct tenderness to the right and very slight tenderness to the left side.

Operation. Four days after admission, February 17, 1917. Under ether anesthesia, a McBurney incision was made and enlarged upward. At a point a hand's-breadth above the cecum in the ascending colon partial necrosis was evident, and on slight manipulation the bowel wall gave way and fecal material poured out into the field of operation. A glass drainage tube was placed in the pelvis and purulent fluid evacuated. A large rubber tube was placed in the rent in the ascending colon and the bowel closed about the tube and then sewed to the parietal peritoneum. Gauze was packed about the tube.

Peritonitis steadily became more marked after the operation and the patient succumbed.

Postmortem inspection through the wound showed thrombosis of the mesenteric veins, leading to the ascending colon.

The salient points of the history here cited are few but important. They are: (1) The simulation of an attack of acute appendicitis. The history is not typical but was sufficiently deceptive to have caused the postponement of operation for four days and the employment of a McBurney incision. (2) The

early localization of symptoms correctly indicating the position of the abdominal lesion itself.

The operative procedure—drainage alone—was the correct one, the outlook hopeless at the time of operation.

Case 4. G. A., aged fifty-two years (Lankenau Hospital, case of Dr. John B. Deaver). Admitted October 22, 1915. Died October 23, 1915.

The patient's illness began seven days before admission, with pain in the epigastrium, gradual in onset. Purgatives were given and the patient's bowels moved freely. Three days after the onset of the illness the patient seemed to get worse and the whole abdomen became painful. The patient began to vomit dark material and vomited every thing taken by mouth thereafter. No one spot could be given as the seat of the most intense pain. There was no jaundice or chill.

The previous history mentions frequent attacks of indigestion and the use of alcohol. Physical examination: The patient is a very large man, evidently in great pain. Complexion sallow; tongue heavily coated. The abdomen is greatly distended and generally tender, this tenderness being more marked in the epigastrium and left lower quadrant. Peristalsis absent. Blood-pressure, 125–80.

The patient died twenty hours after admission, not being operated on. Autopsy showed mesenteric thrombosis, with gangrene of the proximal four to six feet of ileum.

A rather concise history here shows an obstruction, with typical symptoms at the onset unrecognized. Three days after the onset the severe obstructive and peritonitic manifestations render it evident that operative intervention could have accomplished nothing.

Case 5 (University Hospital, operated on by Dr. John B. Deaver, admitted September 25, 1918). D. H. G., aged fifty-one years. The day before admission the patient was seized with a severe pain in the epigastrium. In the course of an hour or so this pain became generalized, affecting both the upper and lower right quadrant. The pain was paroxysmal in character,

leaving the patient with a dull ache between the paroxysms. One such paroxysm of pain lasted an hour. The patient has vomited several times, once following a dose of magnesium sulphate and again following a dose of mustard water. No fecal vomiting. Bowels have not moved since beginning of illness.

Past medical history is unimportant as bearing on the present illness.

Physical Examination: The abdomen is tender and rigid in the epigastrium and the right iliac regions, the point of maximum tenderness being in the left upper quadrant. Little if any abdominal distention was present, but the upper abdomen was tympanitic on percussion. Auscultation shows peristalsis of an exaggerated and gurgling type.

Blood examination: White blood cells, 13,280; polymorphonuclears, 76 per cent.

After admission an enema was given, with but slight result and no relief of symptoms. Lavage disclosed gastric contents having a decidedly fecal odor and appearance. A diagnosis of intestinal obstruction was made and immediate operation performed.

Operation by Dr. John B. Deaver: Ether anesthesia. A right rectus incision was made. No mechanical obstruction was found, but there was a thrombosis of a branch of superior mesenteric artery supplying a segment of the ileum. There was considerable hemorrhage into the mesentery and a small amount of free blood in the abdominal cavity. The segement of bowel affected was in fair condition, apparently being taken care of by the collateral circulation. Dr. Deaver expressed the opinion that no further surgical procedure would benefit the patient and the operation was terminated. During the operation the patient received 750 c.c. of salt solution intravenously.

The first two days after operation were somewhat stormy for the patient, but after this he rallied and made an uneventful recovery.

He was discharged on the fourteenth day after operation in very good condition. When last heard of through the family physician he had had no return of symptoms.

This, the only case operated upon that recovered, is of note in several ways: (1) The correct diagnosis, of intestinal obstruction, was made early and operation was performed at once. At operation good judgment based upon experience saved the patient from an extensive and uncalled-for procedure. The case proves upon the living patient a fact noted at autopsy, namely, that the collateral circulation, perhaps more often than would be supposed, has overcome the effects of mesenteric thrombosis.

Case 6 (Germantown Hospital). Mrs. C., aged thirty-seven years. This patient had been operated upon for a pelvic condition. Intra-abdominally a cyst of the left ovary was excised, the appendix removed and the round ligaments shortened by the Gilliam method. There were also done a trachelorrhaphy, and colporrhaphy and perineorrhaphy. For six or seven days her convalescence progressed favorable. She had been catheterized regularly. Upon one occasion the nurse, after having by mistake introduced the catheter into the vagina, made the error of introducing it into the urethra without resterilizing it. The following day the patient had a well-developed septic cystitis, with a rise of temperature, chill and frequency of urination and severe burning pain. Forty-eight hours later she had another chill, with phlebitis of the left saphenous vein. The phlebitis continued an upward course into the iliac veins, with involvement of the inferior mesenteric veins, through the middle hemorrhoidal vein which is the avenue of communication between the systemic and portal circulations. Her abdomen became distended and tympanitic and extremely tender. There was intense pain, nausea and vomiting. The bowels were moved by enema and at no time did she show signs of intestinal obstruction.

Blood culture showed a colon bacillemia. The diagnosis of thrombosis of the inferior mesenteric veins seems justified by the symptomatology and the sequence of events, although positive corroboration must be lacking because of the patient's recovery without a second operation.

A careful consideration of the foregoing case reports and of the

numerous similar cases on record, would lead us to a number of definite conclusions. They may be summarized as follows:

1. Arterial mesenteric thrombosis is a lesion causing a form of acute intestinal obstruction, rare, but occurring with sufficient frequency to make it imperative to remember its possible occurrence.

2. Its symptom-complex is that of an acute intestinal obstruction, slower in onset than the purely mechanical forms of acute obstructive ileus (adhesion, volvulus, etc.).

3. Venous mesenteric thrombosis is a condition of vaguer symptomatology and slower course than that found in arterial obstruction. It tends more to spontaneous cure and is more likely to be a secondary or postoperative condition. When, however, its remedy by the establishment of collateral circulation does not occur it gives the same final symptoms as does the arterial form of obstruction.

4. The treatment of mesenteric thrombosis is the treatment of any form of acute intestinal obstruction—early operation. The procedure employed must vary with the condition found at operation.

(*a*) If the vitality of a segment of gut has been gravely affected resection is indicated.

(*b*) If the patient's condition contra-indicates resection the gut should be drawn out of the abdomen, fastened to the edges and a Paul tube introduced, resection to be performed later.

(*c*) In the one operated case of this series that recovered nothing was done to the intestine and spontaneous cure resulted. While it is true that this may at times occur, and the judgment of the operator may indicate such a course, such isolated instances do not refute the general rule of early radical procedure.

DISCUSSION OF PAPERS BY DRS. RIXFORD, SUMMERS AND ROSS

Dr. L. L. McArthur, Chicago:

I wish first to thank Dr. Summers in the name of the several cases I have been able to save since he recommended the invagination of that portion of the gangrenous bowel in such severely sick patients that a resection could not be entertained: *e. g.*, in an acute Littré hernia involving one-third the circumference of the bowel, relieving the obstruction and invaginating the gangrenous area at the femoral ring, or under bands in others.

In urging the assistance of medical men toward an earlier diagnosis and an earlier visit to the surgeon I want to cite three cases which have come in my practice in the past year brought to me by pediatricians who suspected obstructions in small children probably obstruction by intussusception. Dr. Summers has not mentioned what the causative factor may be. One case was relieved in such a simple way that I have felt it is justifiable to call the attention of this association to it. In cases of intestinal intussusception in young children if the doctor is called within the first twelve or fourteen hours he takes the baby to the *x*-ray department of the nearby hospital and has them give an opaque enema: you then can watch the column come up to the obstruction where it forms a characteristic cup-shaped shadow —you cannot miss it. If one continues the injection, one can watch the cup go along the colon until sometimes complete reduction is accomplished, giving the cup effect of invagination pushed completely back. Then the surgical reduction is easy. Therefore whenever there is a suspicion of intussusception this enema given under the *x*-rays is the simplest diagnostic measure, and is occasionally curative, by making the reduction complete.

Dr. Albert J. Ochsner, Chicago:

There is one feature of Dr. Summers' paper that should be emphasized especially. He alludes to it in the body of his paper but does not repeat it in his conclusions, and I think it is important enough to be so mentioned. In our own experience the mortality has been almost entirely in patients that have been vigorously treated before coming to the hospital by the use of cathartics. We have operated as late as the ninth day after the acute obstruction on patients that have not received cathartics and still the patient has recovered. Where a patient has had cathartics we have not been able to save any more

than two days after cathartics were given. When one opens such a patient one finds an enormous distention just above the obstruction: In 2 of our cases the cathartics had been used so vigorously that there was a perforation. We still see in text-books a statement to the effect that "after the use of enemas and cathartics have failed to bring relief in the presence of characteristic symptoms" an operation should be made immediately. It should be stated that *before* giving any cathartic the operation should always be made. We have seen recoveries in a number of cases in which a late operation has been done in which the patient had previously been treated without catharsis with the use of the gastric lavage and the Murphy drip to supply the fluids necessary. The supplying of great quantities of fluid subcutaneously after these operations is of the greatest importance. Murphy of St. Louis discussed this feature fully two or three years ago. The invagination of which Dr. Summers speaks is tremendously valuable and we have used it in a number of cases with good results.

Dr. James E. Thompson, Galveston:

I rise to corroborate the statement made by Dr. Rixford in reference to the pathology of complete volvulus of the intestine. Strictly speaking, it should be called volvulus of the midgut; *i. e.*, the portion of the intestine supplied by the superior mesenteric artery which includes the greater part of the duodenum, all the small intestine and the proximal portion of the large intestine to a point a little to the left of the middle of the transverse colon. One knows that this portion of the gut in the early embryonic condition exists as a single loop which is slung up to the posterior body wall by its dorsal mesentery. The ventral mesentery has disappeared. Such a condition predisposes to volvulus. I have verified this point in 2 cases, one was a girl eleven years old, who had previously been operated on for acute appendicitis. At time of operation there was no evidence of rotation of the gut, but unfortunately, no mention was made of the unrotated condition of the large intestine. The small intestine and the proximal portion of the large intestine had twisted one and a half full turns from left to right. The other case occurred in an adult about thirty years of age, who showed from the start a condition of frank intestinal obstruction. The operation revealed a similar twist of the intestines from left to right, which it was impossible to relieve until the extended coils of small intestine were emptied. For this purpose the Moynihan tube was employed. The extent of the rotation was a little more than a complete turn from left to right. This patient also recovered.

Dr. Howard Lilienthal, New York City:

One feature of x-ray diagnosis of intussusception has not been mentioned and that is that it is sometimes possible to see the shadow of the opaque emulsion between the septum and the intussusception as two fine opaque lines.

As to intestinal obstruction the matter of early diagnosis has been here emphasized but as a rule unfortunately the diagnosis is made so late that the operative mortality is greatly in excess of what it should be. I have even known of a surgeon who waited for a blood count and for laboratory tests thus losing valuable time. In my experience the intravenous injection of pituitrin is the most valuable diagnostic method which we have. Particularly in the early cases if this injection is not at once followed by a free evacuation or the passage of large quantities of foul gas the operation should not be delayed. In advanced cases I agree heartily with Dr. Summers that the site of the obstruction should not be sought at the first operation but that the bowel should be drained as a primary measure.

Dr. Carl A. Hamann, Cleveland:

Dr. Ross has called attention to the symptomatology of mesenteric thrombosis referring particularly to that group of cases which is characterized by obstruction. That is one definite form, a sudden onset with symptoms of intestinal obstruction. There is another group with the same sudden onset but a bloody discharge from the bowel. These two well recognized groups of cases I have seen instances of several times; in one case of the latter group there was a sudden onset in an elderly patient with arteriosclerosis; he had abdominal pain and bloody diarrhea. The diagnosis of thrombosis was confirmed at post-mortem. In the diagnosis of obstruction there are two factors not always emphasized, namely the investigation of the hernial orifices and the examination of the rectum by the finger. Every surgeon of experience has seen instances where these examinations were not made and thereby an easily recognized case postponed until operation was too late.

Dr. Ellsworth, Eliot, Jr., New York City:

In the operation to relieve acute intestinal obstruction the nature of the obstruction should, if possible, be determined. If the obstruction is the result of obturation, jejunostomy, as advocated by Dr. Summers, is frequently a life-saving measure. On the other hand, where the obstruction has impaired the viability of the intestine, that measure can give no relief. To determine the type of obstruction

does not require evisceration nor does the necessary examination unduly prolong operation.

Mesenteric thrombosis may be conveniently considered in two groups, viz., those in which there are advanced changes in some part or parts of the circulatory system and those in which no such self-evident cause exists. In the former the symptoms of the primary lesion frequently overshadow those due to the thrombosis which, under these circumstances is apt to be slow in invasion with a clinical course so gradual in development that the actual condition may be discovered only on autopsy. In the latter group—which, owing to its uncertain origin, may be considered "idopathic"—the invasion is usually acute with symptoms of intense peritoneal irritation and is not infrequently associated, as Dr. Hamann has pointed out, with rectal discharges of blood. If this symptom is present an erroneous diagnosis of intussusception may be made. If no such focal symptom exists the actual condition, although it may be suspected, is usually recognized only after opening the abdominal cavity, a procedure always justified by the abdominal physical signs.

While in the first group of cases the extent of the thrombosis may contra-indicate resection, and while where resection is justified, the associated circulatory lesions may make the prognosis very grave, more favorable conditions for resection are presented in the second group and are frequently so limited as to afford an excellent prospect for recovery, especially in view of the much younger age of patients of this group. Resection in any event, however, removes the result of the thrombosis without affecting its cause unless, as is probable, it had previously existed in the thrombosed loop, for if the cause were other than local in character or origin a recurrence of the thrombosis should reasonably be expected at some future time in some other part of the alimentary tract, and yet no instance of this kind is mentioned in the literature. On the whole, no satisfactory solution of the actual cause of "idiopathic" mesenteric thrombosis has ever been made.

In this connection I would like to briefly mention two instances, not previously reported, that illustrate the two groups of cases to which I have referred. One occurred in an elderly man with acute abdominal pain, intense symptoms of peritoneal irritation and rectal bloody discharge due to a thrombosis in the lower ileum. After a resection with end-to-end anastomosis the patient was convalescent when a sudden fatal pulmonary thrombosis occurred. As no autopsy was held, it was impossible to determine whether the pulmonary lesion was due to the previously existing endarteritis or was connected

in any way with the operative procedure. The other case illustrated a probable thrombosis where the extent of the lesion was so slight as not to terminate in gangrene and, consequently, as not to require resection. The invasion in this case, was also acute with severe abdominal pain, physical signs of peritoneal irritation and rectal discharges of blood so profuse as to resemble a colitis. On operation a loop of small intestine was found in the lower ileum, purple in color, distended, smooth, without loss of glistening appearance with a sharp line of demarcation, below which an accumulation of blood was visible through the intestinal wall. Local applications of hot pads to the affected loop restored its normal appearance and dimensions and the abdomen was closed without further complication. This condition, indicating an early stage of circumscribed thrombosis, has been observed by others and while a restoration of the circulation of the affected loop has taken place in some cases, in others loss of vitality with gangrene has resulted. It is particularly in those cases in which gangrene does not take place that a recurrence of the thrombosis might reasonably be expected.

Dr. Charles H. Peck, New York City:

I have seen two cases that confirmed the points made by Dr. Ross in the case reported of recovery without resection. The cases puzzled me a good deal, and I would like to present them to the Association to see if any explanation of the condition can be given. They were cases apparently of thrombosis of the mesenteric vessels or of circulatory disturbances bordering on thrombosis. The first was a man over fifty, rather alcoholic, presumably with some arteriosclerosis, who was taken suddenly ill: I saw him twenty-four to thirty-six hours later when his abdomen was distended, his pulse 150, skin cold and clammy, in an apparently almost fatal condition that we took to be acute intestinal obstruction. On opening the abdomen we found a most extensive mesenteric thrombosis. The small intestine from upper jejunum to lower ileum was mottled mahogany and purple in color, had lost its glistening appearance and was considerably distended. The peritoneum had a large amount of bloody peritoneal exudate in it. We took it to be a mesenteric thrombosis, a fatal case, and did not consider resection because of the extent of the trouble. In closing the abdomen I did a cecostomy to relieve the circulation, and much to our surprise he rallied and the opening functioned well. He was irrigated with hot salt solution frequently from cecostomy to rectum and made a complete recovery. I have followed the case for eleven years and he is now in good health. I saw a second

case two months ago. A young woman of twenty-eight who was in vigorous health with no previous illness or abdominal history. At about half past three o'clock P.M. she was taken with sudden abdominal pain suggestive of acute appendicitis. I saw her about nine o'clock. The pain had recurred in wave-like exacerbations in spite of morphin and it was much more violent than usual in appendicitis. However, we thought it probably appendicitis and operated about half past ten, that is within nine or ten hours of the onset of the pain. We found nothing the matter with the appendix. On opening the peritoneum a considerable amount of bloody peritoneal exudate escaped and a deeply congested coil of ileum presented. This began with a sharp line of demarkation five or six inches from the ileocecal juncture: I followed it for three or four feet where another sharp line of demarkation distinguished it from the normal gut above. There were little ecchymotic subperitoneal spots, a type of edema, no loss of gloss, the process seemed to extend into the mesentery but the gut was not black or gray, and the question was what to do. I had my former case in mind, and in view of the rather extensive resection which would have been necessary I decided to return the intestine without resection. She made an uninterrupted recovery with no recurring symptoms. These two cases seem an example of some type of definite disturbance of the mesenteric circulation which did not go on to complete occlusion and gangrene. They were very clean-cut clinical pictures. I believe they have a bearing on this paper and indicate that there is a group in which a very definite circulatory disturbance, perhaps incomplete thrombosis, is capable of restoration of function and return of viability of the gut.

Dr. J. M. T. Finney, Baltimore:

I want to call attention to three conditions which have not yet been mentioned which one has to consider, especially in the case of children. (1) that group of cases about which little is known, Reynaud's disease; (2) angioneurotic edema; and (3) Henock's purpura. These latter cases may be confused with acute intestinal obstruction in children, producing as they do bloody diarrhea, abdominal pain, distention, etc. Regarding Henock's purpura, the first case was in the person of one of my own children, the diagnosis being made by Dr. Osler. Having been put wise by that case the other three cases were fortunately recognized and not operated on, but the symptoms of these four children were such that it was impossible for me to distinguish them with any certainty from intestinal obstruction. Regarding angioneurotic edema, I operated upon one patient, the wife of a

colleague, supposedly for either acute appendicitis or an acute intestinal obstruction. The *x*-ray did not help in the diagnosis and her condition was so grave, and growing worse, that I operated and found an acute condition perfectly typical of angioneurotic edema involving the appendix and cecum. We later gathered a marked family history of acute angioneurotic edema which had not before been suspected. In regard to the third condition, Reynaud's disease, I wish to speak of a patient of the late Dr. Osler that had been to the hospital on many occasions for the most pronounced form of this disease. The condition was so marked that she was compelled to spend her winters always in the South as changes in temperature would precipitate an attack almost at once. While in New York on a shopping trip one year just before going South she encountered a sudden cold snap; she suffered a severe attack, being in a hotel at the time: was seen by the hotel physician who made a diagnosis of acute intestinal obstruction, but she insisted against his excellent advice on getting on the train and coming to Baltimore. That took several hours and when she arrived she was in bad shape, with symptoms unquestionably those of sudden obstruction. Having seen her several times, on the strength of her past history I made a diagnosis rather jokingly of mesenteric thrombosis, operated, and found three feet of the ileum just above the ileccecal valve black. We did a resection and she made a good recovery. I recount this case as a possible explanation of some of the conditions cited by Dr. Summers and Dr. Peck.

Dr. Emmet Rixford, San Francisco:

In speaking of thrombosis of the mesentery I am reminded of a paper presented before the Surgical Association by Dr. Gerster in which he called attention to a series of cases of portal embolism following appendiceal inflammation. A distinction should be made between thrombosis of the mesenteric veins and of the arteries. Many of the cases so far mentioned in this discussion have been of thrombosis affecting comparatively small portions of the areas of distribution of the mesenteric vessels. It has been my misfortune to have three cases of total obstruction, two of the mesenteric artery and one of the portal vein. My first case was a strapping young man, sitting playing cards and drinking beer at midnight when taken suddenly with terrific pain in the precordium. Two grains of morphin had no effect but the pain was relieved by amyl nitrite as in angina pectoris. Six or eight hours later he was apparently moribund and his abdomen was distended. We opened it with the intention of drainage but discovered that the entire small bowel was dead and ascending colon. The man

died, and autopsy showed a syphilitic ulcer at the arch of his aorta which produced a dissecting aneurysm, and the blood running down between the muscular coat and the adventitia had extended into the iliac arteries and had dissected down the superior mesenteric artery, closing it. The intestine was flaccid and black. The other case was one of blocking of the mesenteric artery from a chip off a heart valve. In the third case the patient was suffering from recurring attacks of gall-stones. This man, a banker, went to Carlsbad and was "cured" of his gall-stones and came back to San Francisco. He promptly had another attack, returned to Carlsbad, was again "cured" of his gall-stones and returned home. About this time he developed terrific excruciating pain in the abdomen, and operation done twelve or fourteen hours later showed the small bowel completely necrotic as well as all of the bowel supplied by the portal vein. He had a constriction of the portal vein produced by the encroachment of fat necrosis upon the portal vein. The vein was narrowed to about the size of a small goose quill. The sudden onset of symptoms was caused by the plugging of this narrow portion of the vein by a newly formed clot.

Dr. John E. Summers, Omaha:

Dr. Eliot spoke of trying to find the cause of the obstruction. This is obligatory or desirable according to circumstances, but if anybody has to operate upon me at the stage of fecal vomiting, I do not want any such attempt made. Drain as indicated in my paper, and give me a chance. Seeking the obstruction when the abdomen is greatly distended can seldom be followed by success without more or less evisceration of the intestines, and it may be extremely difficult to replace them. I have seen one case of angioneurotic edema in the right iliac fossa, and was able to diagnose it because I had learned about such a condition from my reading. As to mesenteric thrombosis, in the few cases that I have seen an early symptom was hemorrhage from the bowel. When you get an old man with a strangulated or incarcerated hernia which you can reduce by taxis, not infrequently there is a hemorrhage from the bowel after the reduction. This results from a mesenteric thrombosis due to pressure upon the aged vessels in the mesentery. Trauma may produce the same result in younger individuals. I have seen, for instance, in a case of my own operated for strangulated umbilical hernia, in which I had to remove a considerable quantity of omentum, the patient die within a few hours after operation, from hemorrhage of the stomach due to a mesenteric thrombosis. I have also had a patient die from hemorrhage from the descending colon after operation upon the left kidney, the autopsy

showing that the hemorrhage resulted from thrombosis of the mesenteric vessels.

Dr. George G. Ross, Philadelphia:

We all recognize that hemorrhage from the bowel is supposed to be a clinical symptom of mesenteric thrombosis yet it occurred in only one of the five cases I have reported. The obstruction is due to a loss of function in that part of the bowel deprived of its blood supply.

CAUSES OF DEATH AFTER OPERATION FOR ACUTE APPENDICITIS

By ARCHIBALD MAC LAREN, M.D.
ST. PAUL, MINN.

The best pathologists tell us there are five varieties of peritonitic inflammation caused by pyogenic germs, and that it is not always possible to distinguish between them, and that all five types may exist in the same case at the same time.

A. B. Johnson's *Surgical Diagnosis* gives the following varieties:

1. Localized abscess.
2. Diffuse spreading acute peritonitis with fibropurulent exudate.
3. Acute peritonitis with cloudy serous exudate.
4. Fibrous type alone, fibrin existing in thick masses.
5. Accumulations of slightly cloudy sterile serum.

Johnson says that one of the most frequent causes of peritonitis is the rupture of a gangrenous appendix. Some of the worst cases of peritonitis that we have had to deal with were caused by the rupture of an appendix which was not gangrenous but which contained from ½ dram to 1 teaspoonful of pus. Such appendices may lie dormant for months following a preceding acute attack, but ulceration eventually occurs with the sudden discharge of the contained pus directly into the free peritoneal cavity, the first pain, under such circumstances, meaning the commencement of a septic peritonitis.

When we include in the study of acute appendicitis cases which do not show pus at operation, we are deceiving ourselves, and confusing the subject by including cases in which there is almost no mortality, with cases that are extremely dangerous. In

our clinical experience it has often been impossible to determine whether in certain border-line cases we were dealing with appendicular abscess or some other form of appendicular peritonitis.

In this list we have eliminated all cases of relapsing appendicitis, even when operated upon during an acute attack. We have limited this study to septic peritonitis due to perforated appendices, and to appendiceal abscesses, including no case in which pus was not present.

We have not been able to lay down any definite rule which we should always follow in treating the individual appendiceal case. Each one must be decided on its own merits. We have occasionally postponed operation when we felt sure that the attack was subsiding. But, if the case was growing worse, and from a short study was progressing toward a fatal termination, we have not hesitated to operate at any time during the attack. In this list of 255 cases no case has been denied operation. Every one has been given a surgical chance.

In studying the 13 cases in this series which have died, we will not be sure but that 2 of these patients might have had a better chance of escape if they had been delayed, according to Ochsner. But, on the other hand, we cannot forget some 4 cases which died in the hospital under our care years ago, when we were trying out "the waiting for the eighth day policy."

Incision. When it has been decided that an operation should be performed for acute appendicitis, we advise making a simple straight incision over the appendix just to the outside of the right rectus muscle. Do not use a cross-muscle incision for this class of cases. We have had two deaths, due to the cellulitic, or gas bacillus, infection with excessive sloughing of the loosened-up muscular and fascial planes in the McBurney incision. In one case reported later in this paper the cellulitis ran around into the tissues of the back, and the patient died on the eighteenth day, with a clean peritoneal cavity. We would also advise against sewing these wounds up tightly. We feel sure that we have saved some of these worst septic peritonitis cases by not putting

in any stiches at all, simply relying upon adhesive strapping to keep the intestines in the peritoneal cavity. The strapping does not interfere with drainage and the ultimate wound results are amazingly good. In treating these cases we should remember that we are trying to save the patient's life, not to avoid hernia. The operative hernia can be repaired at some future date. The patient has only one chance of escape.

In treating these bad septic peritonitis cases we should remember that animal experimentation has tended to prove that peritonitis in itself is not necessarily fatal, only when the animal has a raw surface under his liver, following cholecystectomy in the presence of septic peritonitis was the case sure to die, and usually in the first twenty-four hours (experiments P. P. McNeen, Rickett's Laboratory), which proves what we have known clinically for many years "that the peritoneum protects the system against bacteremia."

A great measure of success in the treatment of septic peritonitis cases depends upon the wise handling of the complications of the disease. After thorough drainage the peritonitis usually quickly subsides. But occasionally an undrained accumulation of pus will form in either kidney pouch, above or below the liver, but usually in the pelvis. When we have recognized these accumulations early and drained them the case usually has recovered. When we have not found them early enough the case has died even after drainage. We have always found at postmortem in these cases an unrecognized abscess, which if we had discovered early enough, and drained, the case perhaps might have recovered. Intraperitoneal drainage uphill will work well for from twenty-four to possibly forty-eight hours but after that time the intestinal coils become so firmly adherent to each other around the drain that all intraperitoneal pressure is destroyed and we are then trying to drain an iron pot through a drain put in at the top. We have frequently seen an old ten- to fifteen-day appendicular case discharging profusely through an upper drainage opening while the pelvis was filled with a large abscess bulging against the anterior rectal wall.

More than one-half of our deaths have been late deaths, the patient dying not from acute peritonitis, but rather from exhaustion due to prolonged intraperitoneal suppuration. A few die from intestinal obstruction due to bands, but more frequently these obstruction cases are septic ileus.

Our cases have died chronologically after operation:

One on the eighth day.

One on the tenth day.

One on the twelfth day.

One on the eighteenth day.

Two on the twenty-first day.

One on the thirty-third day.

As regards time of operation after perforation we have operated during the first forty-eight hours 69 times with 5 deaths, or a mortality of 7.1 per cent.

After the first two days up to the commencement of the eighth day: third day, 29 times; fourth day, 11 times; fifth day, 14 times; sixth day, 8 times; seventh day, 7 times; total 69 operations during the dangerous period of Ochsner, with the same mortality 7.1 per cent. One case that died of opium poisoning the same night which she was operated upon has been excluded from this classification. Of the remaining 117 cases all have been operated upon on and after the eighth day, with two deaths, or a mortality of less than 2 per cent.

We have at times drained a well-marked accumulation of pus in the pelvis either through the vagina or through the rectum as a preliminary or first step, and then immediately after have opened the abdomen and dealt with the intraperitoneal pathology according to ordinary surgical rules. Our experience has been that quantity as well as quality of pus is an important factor in the danger attending this operation, so if by pelvic drainage we can reduce the quantity of pus in a certain case we have by that amount lessened the danger of the succeeding laparotomy.

After pelvic drainage we have usually found that there was at least one other abscess aside from the accumulation in the cul-de-sac, and this was, as a rule, next to the perforated appendix.

This is the reason why it is not wise to rely upon pelvic drainage alone. If the patient, often a child and in bad physical condition, is seen several days after perforation it may be wise to drain through the rectum one day and postpone the opening of the abdomen until the next day, but not much longer. (See Case 12.)

The secret of success in these cases is eternal vigilance. Watch them with great care. Make frequent rectal examinations. Palpate the left side of the abdomen and be prepared to explore with local anesthesia. If there is a return of pain and rigidity, or a marked rise in temperature and pulse, early opening and drainage of secondary abscesses will save the patient; later opening of this same abscess will not always help. We have had two deaths within the first twenty-four hours. After finding and draining the large, late abscesses (Cases 3 and 11), with the 255 cases, which we are here reporting, there has been thirteen deaths, or a general mortality of 5.09 per cent. In securing these results vaginal drainage of pelvic abscess was used ten times; rectal drainage was used 33 times, occasionally before operation, but usually some days after laparotomy.

In complicating intestinal obstruction the formation of fecal fistula of drainage by the intestine with a Paul tube has been at times a great help. This has been done ten times.

In this paper I am reporting in detail the 13 deaths which have occurred in 255 acute appendicitis cases, hoping they may be of interest and furnish some instruction. These 255 cases are all consecutive cases operated upon personally at the St. Paul, Minneapolis, and Stillwater Hospitals. A few more operated upon in the country when it was not possible to keep close watch and make frequent examinations have not been included.

This list extends back some six years, and during that time we have materially changed our views regarding treatment, so that we now feel that some of the cases which have died have been properly treated and the deaths could not, in our present judgment, have been avoided. Others were not given as good a chance as they would have today, and we think that some of them should have been saved.

Morphin Poisoning

Case 1.—No. 2994. Child aged six years, sick five days; evening of fifth day became distended. Temperature, 103°; acute gangrenous perforated appendix; accumulation of serum in the cul-de-sac; abscess opened and drained. That night very restless; nurse had difficulty in keeping her in bed. At 10 P.M. nurse gave hypodermic of morphin, $\frac{1}{12}$ gr.; two hours later (because of no relief) second hypodermic, $\frac{1}{12}$ gr. morphin. Died 3 A.M.; morphin poisoning; pin-point pupils and respiration of six or less.

Operations Performed in First Forty-eight Hours

Case 2.—No. 3465. In this case perforation occurred forty hours before seen.

Diagnosis. General septic peritonitis, gangrenous perforated appendix. Appendix removed; drain through stab, just outside cross-muscle incision. On the eighth day was very sick from extensive carbuncle-like infection of skin of side and back. Died on the eighteenth day. General septicemia, with enlargement of all glands everywhere. Abdomen, no accumulation of pus.

Case 30.—No. 3717. Young man, aged twenty-seven years; first attack commenced thirty-six hours before seen. Took long auto ride day previous. Vomiting at night; temperature, 100°; pulse, 85; abdomen rigid; operation, St. Luke's Hospital; septic peritonitis; acute gangrenous perforated appendicitis; three ounces of thick pus, with dense adhesions about appendix. One pint of thin serous pus in cul-de-sac, split rubber tube into pelvis through stab opening. Two days later tube out and catheter drain put in. Quite well until ninth day; pelvic distress; temperature, 101°, and vomiting; on the twelfth day rectal section; three pints of serous pus let out and tube put in. Patient died same night. Postmortem: No pus in pelvis, but large amount of pus in upper abdomen.

FIG. 1.—Abscess behind bladder pressing against the anterior wall of the rectum.

FIG. 2.—Abscess anterior to rectum bulging through the dilated anus.

Case 4.—No. 4368. W. C.; under care of Dr. Humphrey, of Stillwater; several attacks before; last attack three months ago; this attack commenced eighteen hours before seen; operated in Stillwater Hospital; acute gangrenous perforated appendix; pint of thin serous pus all through lower right abdomen; not much pus in the cul-de-sac; drain through the suprapubic stab; peritonitis. Postmortem: Mesenteric thrombosis; several intestinal perforations; one in transverse colon, two or three in lower ileum.

Case 5.—No. 4671. Man, aged forty-three years. Two previous attacks. This attack commenced five and a half hours before operation, rapidly growing worse. Septic peritonitis; gangrenous perforated appendix; pocket of seropus about appendix, also a large accumulation in cul-de-sac. Wound left opened; strapped. Died twenty-four hours after operation.

Case 6.—No. 4759. N. W. T., under care of Dr. Humphrey, Stillwater. Operation at Stillwater Hospital. One previous attack eight months ago. This attack commenced forty hours before seen, with very severe pain, running into the pelvis and right testicle and general rigidity. Gangrenous perforated appendix, enterolith in perforation. Eight ounces of seropus, with marked intestinal distention. Appendectomy. Two cigar drains, one into pelvis and one into right loin. On the fourth day sudden vomiting of a very large quantity of black liquid. The man strangled during vomiting and died at once, drowned in his own vomit. Postmortem: No peritonitis, but acute dilatation of stomach.

Operations Performed After First Forty-eight Hours and Until the Commencement of Eighth Day

Case 7.—No. 3057. Under care of Dr. Kerr Martel, aged forty years. Perforation five days before seen. Temperature, 102°; pulse, 100. Not doing well. Abscess opened and drained through cross-muscle incision (free peritoneal cavity not opened). One pint of thin serous pus. Died of general septic peritonitis

twenty-four hours later on the sixth day. Postmortem: General peritonitis and perforated gangrenous appendix.

CASE 8.—No. 4255. M. L. Under care of Dr. Perrin, Star Prairie. Aged thirty-five years; perforation six days before seen. Temperature, 103°; pulse, 120; had colicky pains several days before perforation. Acute septic peritonitis. Large accumulation of fluid in right abdomen up into right kidney pouch and large accumulation in cul-de-sac. Appendix gangrenous and perforated, leaking pus; small incision outside of right rectus. Appendix removed and pus sponged out. Pelvis drained. Tapped with tube. Pus spurted two inches above abdominal wall, when the tube was put into the cul-de-sac. Felt much better that night. Died the second night after operation. Postmortem: Septic peritonitis.

CASE 9.—No. 4804. C. A. Under care of Dr. Epley, New Richmond. Man, aged forty-five years; several attacks before. This attack commenced five days ago. Acute perforation four hours before, evidently due to rupture of abdominal abscess. Septic peritonitis, perforated gangrenous appendix. Appendix removed. Two drains, one tube in right loin, one into cul-de-sac through wound. On the seventh day on account of intestinal obstruction, rectal section. On the ninth day intestine drained with a Paul tube. Died of exhaustion on the twentieth day. Postmortem: Large abscess. Two pints of serous pus in left side of abdomen.

CASE 10.—No. 5028. Under care of Dr. Paxton, St. Paul. Young man, aged twenty-one years. First attack commenced four days before seen. Not very sick until 2 A.M. on fifth day, when he gave first symptoms of perforation. Immediate operation. Acute septic peritonitis. Small intestine coils red and distended. Ruptured appendiceal abscess, with gangrenous perforated appendix. One pint of serous pus. Appendix removed. Cecostomy and drainage of intestine, with a Paul tube. Died on the eight day; septic peritonitis.

CASE 11.—No. 4376. A. S. Boy, aged twelve years. First attack commenced four days before seen. Gangrenous per-

forated appendix, abscess outside of cecum. Gangrenous spot on cecum; size of quarter of dollar. Appendix removed. Stab drain into pelvis, second drain into right loin through wound and tube drains. On the fifth day, fecal fistula discharged through wound. On the twentieth day another abscess opened. Died on the twenty-first day of exhaustion.

Operations When the Abdomen was Opened on or after Eighth Day

Case 12.—No. 3116. Little girl, aged seven years; sick five days; temperature, 104°; pulse, 130.

Diagnosis. Acute gangrenous perforated appendix, large pelvic abscess. Rectal section: Pint of pus. Should have had laparotomy on the second day: Eight days after, rise of temperature and pulse, with vomiting; laparotomy abscess in right loin, gas and much pus: Two days later (or tenth day) died of exhaustion.

Case 13.—Last case seen with Dr. DuBoise, Sauk Center. Brought to St. Paul on a cot in baggage car. General abdominal rigidity. Temperature, 102°; pulse, 125; some vomiting. Deep pelvic abscess presenting in rectum. Rectal section on fourth day; one pint of seropus let out. On the eighth day laparotomy, gangrenous perforated appendix removed and small right loin abscess opened and drained. Wound left open, strapped. On nineteenth day subdiaphragmatic abscess ruptured, with return of rigidity. Temperature, 103°; pulse, 140; very sick; abdomen opened, under local anesthesia; large left seropurulent accumulation opened and drained; cecum opened and tube put in. Died on the thirty-third day of exhaustion.

Bibliography

Lund, F. B.: Value of Enterostomy in Selected Cases of Peritonitis, Jour. Am. Med. Assn., July 11, 1903.

Hageboeck, A. L., and Kornder, L. H.: Enterostomy as an Emergency in General Peritonitis Following Operation in Acute Appendicitis, Jour. Am. Med. Assn., April 12, 1919.

Acute Appendicitis: 822 Patients with Acute Appendicitis Operated at Cook County Hospital; Appendectomy with Drainage, 312–32 Deaths; Mortality, 10 per cent., Jour. Am. Med. Assn., March 24, 1917.

Coffey: New York Med. Jour., August, 1906. 13,445 cases collected from various hospitals in this country; mortality, 7.4 per cent.

Irwin, S. T.: Acute Appendicitis, London Lancet, January 18, 1919.

Molat: London Hospital, 1900–1904, 17.2 per cent.

Mutch: 545 cases at Guy's Hospital, 13 per cent.

Beatson: 73 cases, 9 deaths, 12.3 per cent.

Billington: 360 cases, 48 deaths, 13.3 per cent.

Burgess: 365 cases, mortality 10.6 per cent.

Paterson: 56 cases, mortality 8.9 per cent.

Richardson: 350 cases, mortality 13.7 per cent.

Irwin: 84 cases, mortality 11.9 per cent.

Rullison, E. T.: Annals of Surgery. 263 cases from Presbyterian Hospital, New York. Mortality, 9.1 per cent. No cases of vaginal or rectal drainage.

DISCUSSION

Dr. Fred B. Lund, Boston:

In the last two or three years I have been impressed with the value of the rectal opening of appendiceal abscess. You will sometimes be called to see a case that has been operated on but for some reason is not doing well, running a temperature, though the patient looks well and the bowels are moving all right. It is surprising how many of these patients will show an abscess on rectal examination. Lots of patients have been cured by opening these abscesses through the rectum. I have found this frequent in my own practice in children perhaps because they cry and because it is hard to attend to the drainage, dressings, etc. I have found many times, that by making a rectal examination you can feel the abscess and by giving a little gas and putting in a curved hemostat you can relieve the condition. I think we owe a great deal to Dr. MacLaren for calling our attention to these cases.

THE RELATIONSHIP BETWEEN RANULA AND BRANCHIOGENETIC CYSTS

By JAMES E. THOMPSON, M.D.
GALVESTON, TEXAS

The name "ranula" is usually applied to a cyst with mucous contents which is found underneath the mucous membrane covering the floor of the mouth on one side of the frenum of the tongue. The wall of the cyst is thin and is loosely attached to the surrounding tissues. It consists of fibrous tissue of a loose variety. The inner surface is often covered by a single layer of tessellated epithelium. The contents are of mucus of the consistence of white of egg. These cysts vary in size. They rarely cross the midline. When large they extend outward and downward. Wharton's duct and the sublingual gland can usually be seen superficial to the cyst but apparently not structurally connected with it. The cyst usually lies entirely within the buccal cavity on the upper surface of the mylohyoid muscle (Fig. 1, *A*). Not infrequently a prolongation of the cyst extends around the posterior border of the mylohyoid, producing a swelling in the submaxillary region (Fig. 1, *B*), which may reach the size of a small mandarin orange. Occasionally the submaxillary swelling may consist of two separate cysts, one of which alone communicates with the intrabuccal cyst (Fig. 1, *C*).

Various theories have been advanced from time to time to account for the presence of ranula. Up to the present time none has been satisfactory. It has always appeared to me that a cyst which presents such consistent anatomical and pathologi-

cal features must have one and only one origin, and therefore I have never believed that a ranula could at one time be derived from Wharton's duct, at another from the sublingual gland, at another from one of the mucous glands and at still another

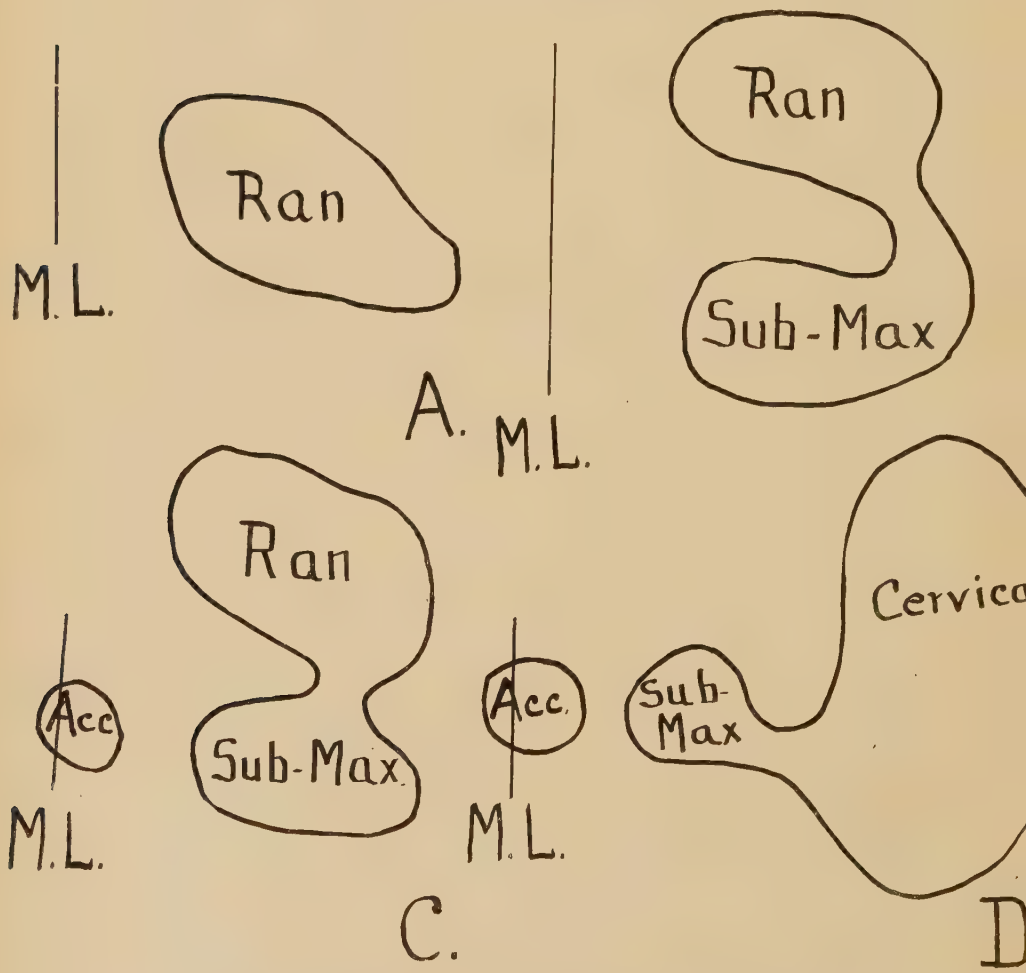

FIG. 1.—A diagrammatic representation of the anatomical distribution of the cysts met with in the deep cervical, submaxillary and sublingual regions. *A*, represents a simple ranula; *B*, a ranula and submaxillary cyst communicating with one another by a neck; *C*, a ranula and submaxillary cyst communicating with each other, also a small isolated cyst in the submental region; *D*, shows a deep cervical cyst communicating with a submaxillary cyst, also

from an adventitious bursa (Fleishmann's). I have satisfied myself in every case of ranula that has come under my observation that neither Wharton's duct nor the sublingual gland is responsible by finding that these structures were healthy and

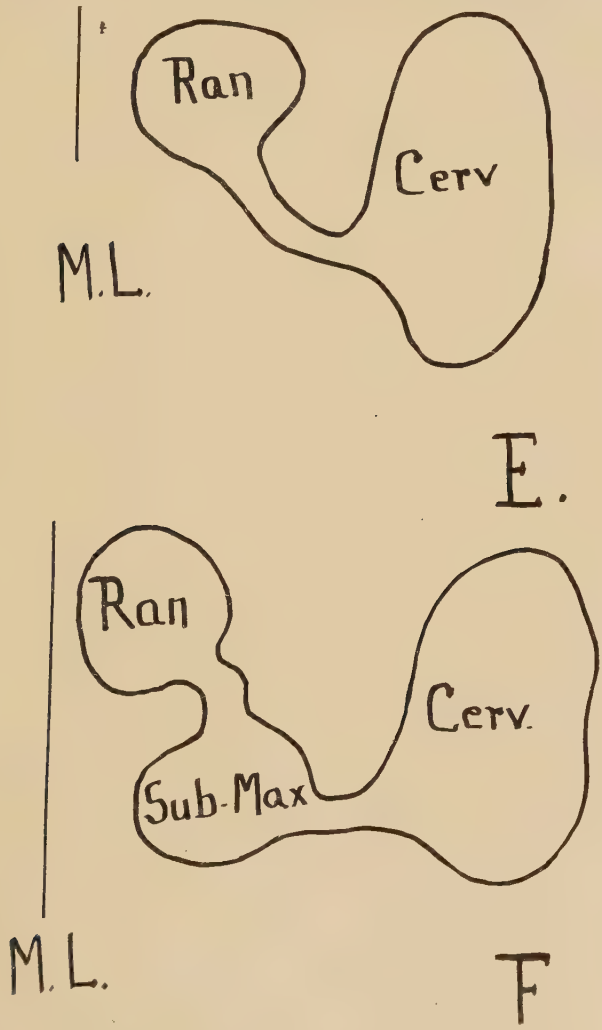

an isolated submental cyst; *E*, shows a deep cervical cyst communicating with a ranula by a long narrow neck which traverses the submaxillary region; *F*, shows a deep cervical cyst communicating with a submaxillary cyst which in turn opens into a ranula. The letters *M L* mean "middle line of the neck." For purposes of comparison all the cysts have been drawn on the left side of the body.

normally placed. To refuse to believe that some cysts may not have their origin in the mucous glands of this region would be unwise. One meets with examples of mucous cysts of considerable size arising in the mucous membrane of the mouth. These cysts, however, are very superficial, very closely connected with the mucous membrane and do not separate it from the subjacent tissues. In other words, they do not show the frank, burrowing qualities of true ranula. As to Fleishmann's bursa, I may say frankly that I have never seen it, and, further, that many anatomists in a life's experience have failed to satisfy themselves as to its real existence.

With the hope of throwing some light on the origin of ranula, I venture to present a careful analysis of a group of cases which I believe will prove that a direct relationship exists between cysts of undoubted branchiogenetic origin and cysts in the submaxillary region and the floor of the mouth. In 1906[1] I reported two cases of cysts of the upper region of the neck that were identical with each other in their anatomical and pathological features. In each case the cyst was deeply placed in the upper portion of the neck under cover of the parotid gland and the ramus of the jaw. In one case the cyst communicated with a ranula under the tongue by a narrow communicating track which passed across the submaxillary region (Fig. 1, *E*) In the other case there was no ranula, but the cyst opened in front by a short passage into a large cyst occupying the submaxillary region. In front of this a small accessory cyst was found in the middle line underneath the symphysis of the jaw (Fig. 1, *D*). Since that time a number of cases of cervical cyst have come under my observation identical in every particular as to structure and location. Each cyst had associated with it either a submaxillary cyst or a ranula, or both, with which it communicated freely. In Fig. 1, *D*, *E* and *F*, drawings of the different types of cyst are shown which picture in a striking manner their close relationships with one another. Two of

[1] Texas State Journal of Medicine, December, 1906.

these types, *D* and *E*, were described in my original paper and I have verified the accuracy of my original description by cases seen subsequently. Type *F* has been added since, and inasmuch as it embodies all the most typical features of these compound cysts it will be used as the basis of a common clinical and pathological description.

The history and anatomical findings are as follows: Mrs. L. F., aged thirty-one years, white, came under my care suffering from a ranula under the left side of the tongue, which was the size of a walnut. The submaxillary region of the same side was also occupied by a cystic swelling which increased in size when pressure was made on the ranula. The two cysts evidently communicated freely. In addition there was a swelling between the angle of the jaw and the mastoid process, which obliterated the natural hollow in front of the lobule of the ear. The ranula had been noticed a few years previously and several attempts had been made to cure it by tapping and snipping out parts of the wall of the cyst. The swellings in the submaxillary and parotid regions were of recent onset. Recognizing the nature of the case I suggested operation. The neck was opened by a semicircular incision such as is employed for ligature of the lingual artery. The ranula and submaxillary cyst were dissected out in one piece. It was found necessary to remove the submaxillary salivary gland to facilitate the dissection. The posterior part of the submaxillary cyst led into a narrow neck, which penetrated the deep compartment of the cervical fascia separating the submaxillary gland from the deep cervical fascial space to open finally into a large cavity which lay in the upper part of the neck under cover of the parotid gland and the inferior maxilla. This contained thin mucus and its walls were smooth and firmly attached to the surrounding tissues. The boundaries of the cavity were as follows: *Above*, one could feel the base of the skull represented by the under surface of the petrous portion of the temporal bone. All the bony irregularities were clearly distinguishable. *Below*, the cyst wall turned on itself about the level of the greater cornu of the hyoid bone. *Extern-*

ally, one could feel distinctly the inner surface of the ramus of the inferior maxilla covered by the internal pterygoid muscle, the projection of the spine of Spix and the deep surface of the parotid gland. *Posteriorly*, the anterior surface of the mastoid and styloid processes were clearly palpable. *Internally*, the cyst extended for a short distance in front of the transverse processes of the upper cervical vertebræ. The internal carotid artery could be felt very close to the posterior wall of the cyst. A small portion of the cyst wall was removed and stained for epithelium. No epithelial lining could be demonstrated. Complete removal being clearly an impossibility, the mucous contents were evacuated and the interior of the cavity thoroughly scrubbed with gauze soaked in tincture of iodin. A drainage tube was inserted. This was retained two days and then removed. After considerable reaction the wound healed up by first intention and the patient left the hospital at the end of three weeks, apparently cured. I heard from the patient about a year afterward and found that the cervical part of the cyst had refilled and that she was contemplating another operation.

All the cysts seen so far have been so characteristically alike that the above description is accurate in its main essentials for every one of them as regards the cervical compartment. Considerable variation has been present in the submaxillary and lingual regions. Fig. 1, *D*, *E* and *F* represent the types observed so far. It is almost certain that further experience will reveal others.

Microscopic examination of the lining membrane of the cyst wall has been rather unsatisfactory. In most cases we were unable to find epithelium. When present it was of the tessellated variety. The fibrous tissue was fairly dense and the fibrous bundles were separated by large lymph spaces containing very few cellular elements.

I have made a somewhat exhaustive search of reported cases, but so far I have been unable to find cases that correspond anatomically to those reported above. The anatomical boundaries of the cervical portions of these cysts are so unusual, definite

and consistent as to negative mere coincidence as to structure and origin and to make it reasonably certain that they result from a definite cause and therefore are likely to be met with true to type in the practice of every surgeon. It is more than probable that they are not rarities but that they have escaped accurate description. A study of *A*, *B*, *C*, *D*, *E* and *F* in Fig. 1 leads one to the inevitable inference that each picture is a complement of all the rest, like a fragment of a picture puzzle, and that the different cysts have a common origin. They give us the impression of being daughter cysts which have been segregated from a mother cyst and carried by some agency into regions remote from their original home, during which process obliteration of one or more of the daughter cysts or even of the mother cyst has occurred, producing a final picture corresponding more or less closely with one of those in the figures. The potentialities of such a mother cyst are present in the neck of the human embryo of four weeks at a period when the external gill cleft depressions are existent and the cervical sinus is in process of formation. The persistence of the cervical sinus in whole or in part is probably responsible for all branchial cysts and fistulæ, and inasmuch as the stages in its development are inseparably connected with those of the branchial arches and clefts it will be necessary to add a description of the life history of the latter to enable us to handle the subject intelligently.

In the third week of fetal life the branchial arches make their appearance (Fig. 2). The pharyngeal region of the embryo resembles that of an adult fish, but whereas in fishes the arches are separated by clefts here they are separated by depressions. These depressions, generally spoken of as internal and external cleft depressions, are visible on the outer aspect of the neck and the inner aspect of the pharynx. They are separated by a membrane which is lined on its outer side by epiblast and on its inner side by hypoblast (Fig. 3). In the normal course of development the membrane never disappears, so that it is incorrect to speak of gill clefts in the human embryo in the same sense that we use the term in referring to fishes. In the rare

instances in which the membrane is perforated a complete cleft is formed which may persist in the adult and may be the forerunner of a branchial fistula. The growth of the neck is so

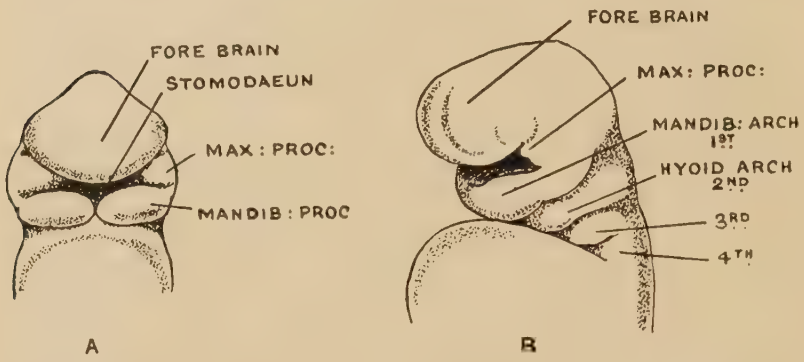

FIG. 2.—The branchial arches and stomodeum of a human embryo of the third week. Front and side views. (From Keith's Human Embryology.)

rapid that by the end of the sixth week all external evidence of the branchial arches and cleft depressions have disappeared.

BRANCHIAL ARCHES. Six arches are usually described, of which four can be distinguished on the surface of the neck (Fig.

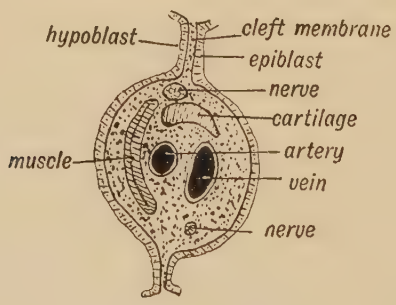

FIG. 3.—Schematic section of a visceral arch. (From Keith.)

2). The posterior ends of the two anterior are connected with the bony skeleton, but those of the posterior four lie free in the tissues. Each arch contains (1) a basis of cartilage, (2) a

vascular arch, (3) nerves, (4) muscle elements (Fig. 3). The *first arch* is the mandibular. Its basis (Meckel's cartilage) forms the foundation of the lower jaw, although the greater part disappears. The posterior end persists as the malleus and the anterior end as the part of the lower jaw which carries the incisor teeth. The nerve of the arch is the third division of the fifth. The artery of the arch disappears, but the origin of the external maxillary (facial) marks the place where it arose from the ventral aorta (external carotid). The *second arch* is the hyoid. Its posterior end persists as the stapes, the middle portion as the styloid process and stylohyoid ligament and the anterior end as the lesser cornu of the hyoid bone. The nerve of this arch is represented by the facial and auditory (seventh and eighth). The artery of the arch disappears, but the lingual artery marks the place where it arose from the ventral aorta. The *third arch* is represented in the adult by the great cornu and body of the hyoid bone. Its nerve is the glossopharyngeal (ninth). The artery of the arch persists as the first part of the internal carotid. The superior thyroid arises from its place of origin from the ventral aorta. The *fourth arch* is represented in the adult by the upper part of the thyroid cartilage. Its nerve is the superior laryngeal branch of the vagus. The vascular arch is represented on the right side by the first part of the subclavian artery and on the left side by that part of the arch of the aorta between the origin of the left carotid and the point of entrance of the ductus arteriosus. The *fifth arch* is represented in the adult by the lower portion of the thyroid cartilage. Its nerve is the inferior laryngeal branch of the vagus. The *sixth arch* is represented in the adult by the cricoid and arytenoid cartilages and the cartilaginous rings of the trachea and bronchi. Its nerve is the inferior laryngeal branch of the vagus. The vascular arches of the fifth arch probably disappear early. Those of the sixth persist. On the left side it forms part of the right pulmonary artery and the ductus arteriosus; on the right it shares in the formation of the right pulmonary artery.

The *muscles of the arches* deserve special consideration. At

first they are limited to the area of their respective arches, but with the increase in length of the neck of the embryo and the differentiation of different structures, such as the tongue, palate and larynx, many of the muscles are carried into regions remote from their origin. As they always carry their nerves with them we can distinguish the embryonic origins of all the muscles of the neck by their nerve supply. From the first arch (mandibular, fifth nerve) are derived the muscles of mastication, the mylohyoid and the anterior belly of the digastric, the tensor palati and the tensor tympani. From the *second arch* (hyoid, fifth nerve) are derived the stapedius, the stylohyoid, the posterior belly of the digastric, all the muscles of facial expression and the platysma. From the *third arch* (ninth nerve) are derived the stylopharyngeus and some of the muscles of the soft palate. From the *fourth arch* (superior laryngeal nerve) are derived some of the muscles of the soft palate, the constrictors of the pharynx and the cricothyroid. From the *fifth arch* (inferior laryngeal nerve) are derived the intrinsic muscles of the larynx.

Great irregularity is shown in the movement or migration of these muscles, and this is strikingly exemplified in the soft palate, where one of the muscles (tensor palati, fifth nerve) is derived from the first arch while the rest are derived from the third and fourth arches (ninth and tenth nerves). The most extensive migration is seen in the muscles derived from the second arch (hyoid) (Fig. 4). A remarkable muscular bud makes its appearance which grows upward into the face and scalp over the surface of the first arch and downward into the neck over the surfaces of the posterior arches. From it the occipitofrontalis, all the muscles of expression and the platysma are derived. The branches of the seventh nerve carried with these muscles identify their origin.

To these disturbing agents in the orderly arrangement of parts is added another muscular migration which arises in the seventh, eighth and ninth body segments, which are situated behind those supplied by the tenth and eleventh nerves (Fig. 5).

These segments are supplied by the twelfth nerve (hypoglossal). The path and extent of this migration is clearly indicated by the course of the hypoglossal nerve and the situation of the muscles supplied by it. It may be divided into two parts; an upper (lingual), from which the geniohyoid, the geniohyoglossus, hyoglossus and all the intrinsic muscles of the tongue are derived, and a lower (infrahyoid), which forms the depressors of the hyoid bone. One of these muscles, the omohyoid, extends downward

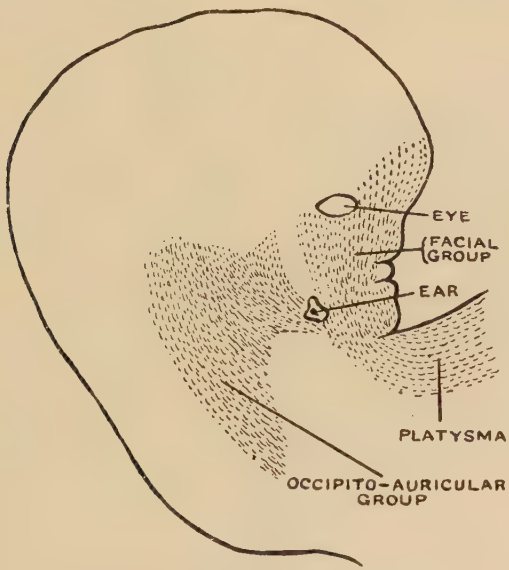

FIG. 4.—The expansion and migration of the platysma sheet in a human embryo of six weeks. (From Keith.)

as far as the scapula. The actual path of migration of the upper (lingual) division is charted accurately by the course of the main trunk of the hypoglossal nerve. The descendens hypoglossi is a similar guide to that of the lower division. The upper muscular division penetrates into a bud of hypoblast which is situated on the posterior surface of the fused anterior ends of the first, second and third arches. This bud, called the lingual bud, is developed from two separate parts (Fig. 6),

an anterior (buccal), which arises from the anterior ends of the first visceral arch (tuberculum impar), and a posterior (pharyngeal), which arises from the anterior ends of the second and

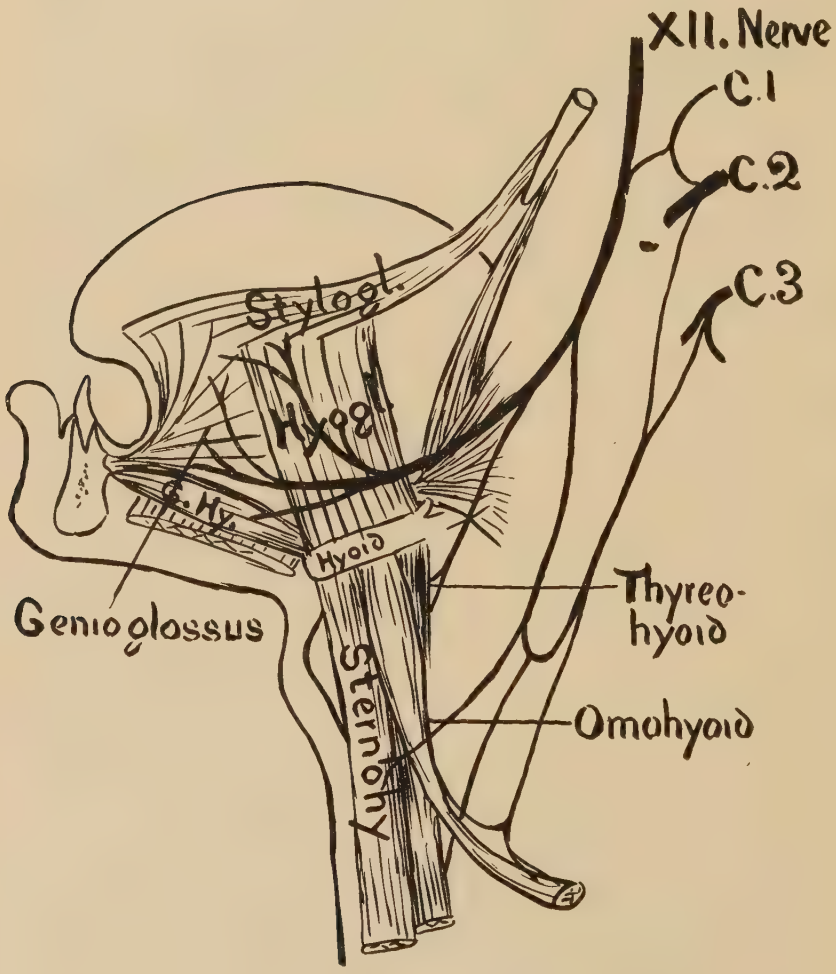

FIG. 5.—Modified from Cunningham. Showing the muscles supplied by the hypoglossal nerve (XII) to illustrate the migration of the muscles derived from the seventh, eighth and ninth body segments. It must be noted that the infrahyoid muscles are probably derived from the cervical segments behind the hypoglossis group.

third arches. The epithelium covering these buds retains its original nerve supply. That to the anterior, which forms the anterior two-thirds of the tongue, comes from the nerve to the first arch (fifth lingual) while that to the posterior, which forms the posterior third of the organ, is derived from the nerves of the second and third arches and is represented by the chorda tympani (seventh) and the glossopharyngeal (ninth). The resulting organ offers an interesting picture of a muscular mass innervated by the twelfth nerve and covered by mucous membrane supplied by the fifth, seventh and ninth nerves.

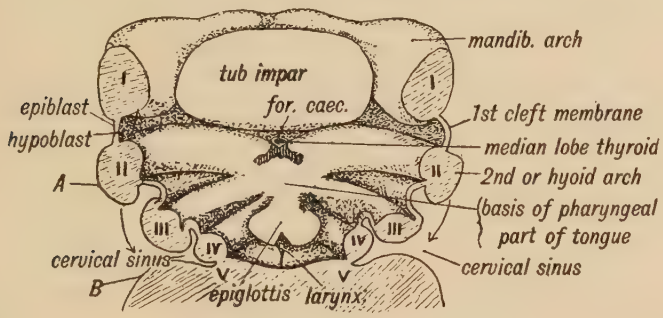

FIG. 6.—The floor of the pharynx in a human embryo of the fourth week. Five branchial arches are shown separated by cleft depressions. The early stages of the development of the cervical sinus are shown, also the separate hypoblastic eminences that form the anterior and posterior parts of the tongue. (From Keith.)

The muscular migrations have been described in some detail, because our final argument is based on the hypothesis that they are responsible for carrying cysts from one region of the neck to the other.

BRANCHIAL CLEFTS. Four cleft depressions can be recognized in the embryo. The *first cleft* (hyomandibular) persists. Its external depression is represented by the external auditory meatus. In connection with the internal depression the Eustachian tube and the tympanum are developed. The membrana tympani is supposed to represent the cleft membrane. The

second, third and fourth clefts disappear and usually leave no trace of their existence. In a very young embryo (fourth week) the second arch (hyoid) grows downward and covers the third and fourth and comes into contact and fuses with the body wall behind the fifth. By this growth, which is analogous to that forming the gill covers of fishes, the orifices of the second, third and fourth cleft depressions are covered up and a space is shut off into which they open. This is called the *cervical sinus* (Fig. 6). A knowledge of the ultimate fate of the cervical sinus is of fundamental importance in explaining the characteristics of branchiogenetic cysts. Under normal conditions it disappears. If it persists a cyst or a fistula may result. The sinus may open externally on to the neck or internally into the pharynx. The external opening is invariably along the line of the anterior border of the sternomastoid muscle. It may be placed anywhere between the angle of the jaw and the sternal notch, but it is usually about the middle of the neck. When an internal opening is present it is usually due to perforation of the second cleft membrane and the pharyngeal orifice is situated in the tonsillar crypt (Fig. 7). Internal openings due to perforation of the third and fourth cleft membranes are infrequently seen. The pharyngeal orifices of these openings are situated lower down in the sinus pyriformis. The tracks leading from the cervical sinus into the pharynx through the membranes of the second, third and fourth clefts would, in the adult neck, course in widely diverse directions. That passing through the second cleft always courses upward between the arch of the carotid arteries and penetrates the pharyngeal muscles above the glossopharyngeal nerve; that passing through the third cleft courses upward below the internal carotid, above the superior laryngeal nerve and below the glossopharyngeal nerve; that passing through the fourth cleft must pass downward, hook around the subclavian artery on the right side and the aorta on the left and course upward alongside the inferior laryngeal nerve. When both internal and external openings are present a fistulous track passes from the surface of the neck to

the pharynx. When there are neither internal nor external openings present but the sinus persists either in whole or in part a cyst results. In Figs. 8 and 9 an attempt has been made to show in a diagrammatic manner the relationships of the fistulous tracks of branchial origin with the nerves and arteries of the

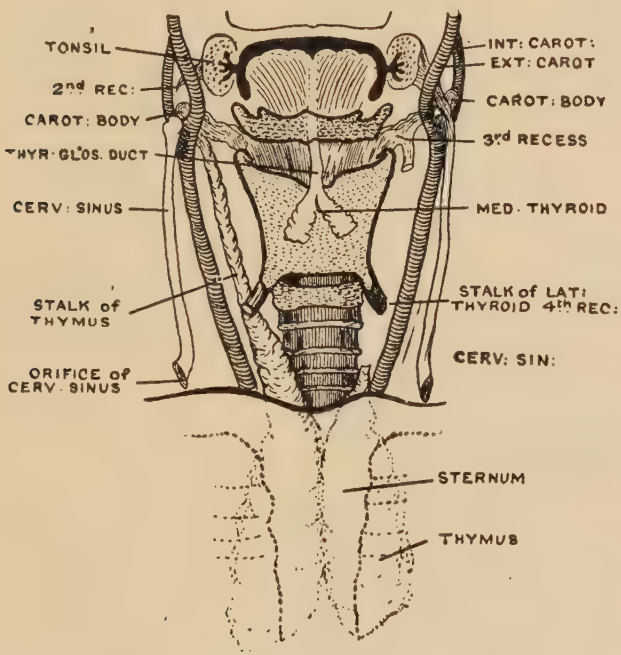

FIG. 7.—A diagrammatic representation of the structures developed in connection with the inner cleft recesses. Note on the right side of the figure a branchial fistula due to perforation of the second branchial cleft and persistence of the cervical sinus. This figure should be studied in connection with Figs. 8 and 9. (From Keith.)

branchial arches. A careful study of these plates will convince us that the description of the fistulæ in question has hitherto been very loose and inaccurate. This is particularly the case with those due to the persistence of the third and fourth clefts. The statement that a fistula due to the persistence of the cervical sinus always passes upward between the fork formed by the

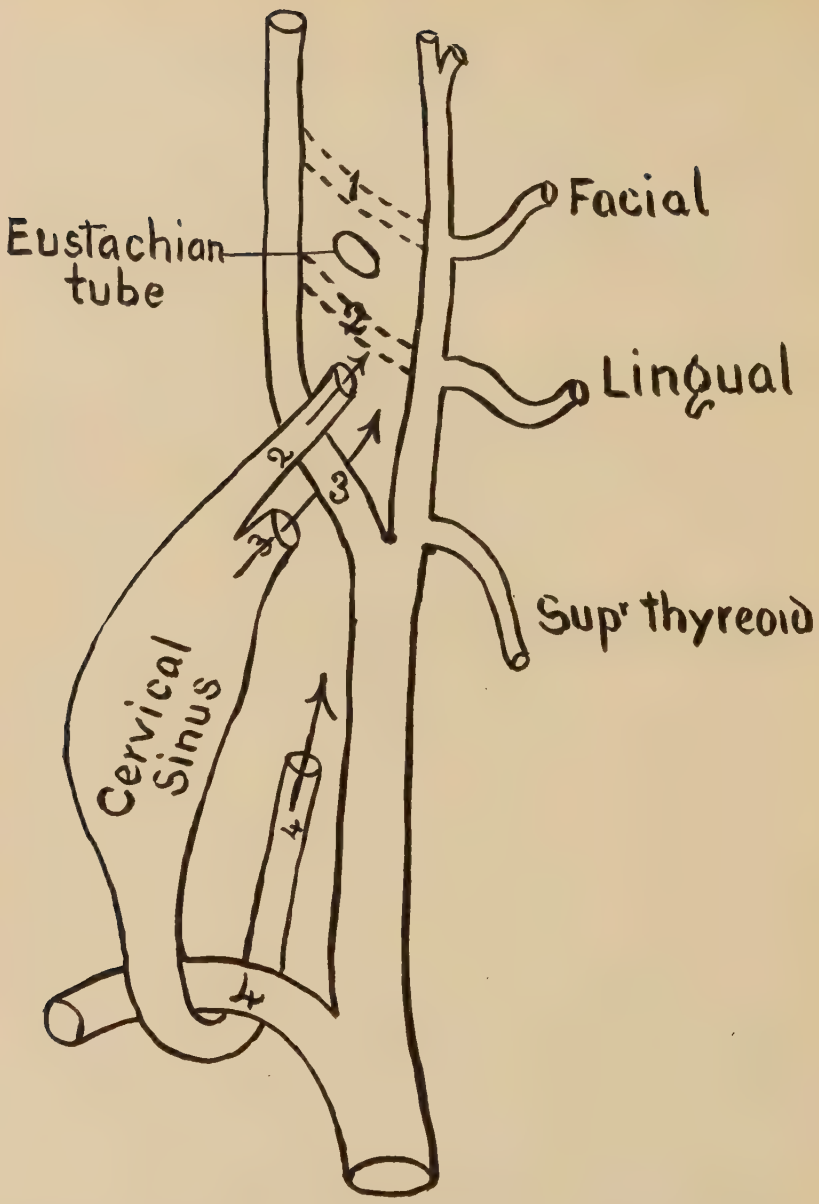

FIG. 8.—A diagrammatic representation of the cervical sinus to show the anatomical paths which would be taken by fistulous passages passing through persistent second, third and fourth clefts. This figure shows the relationships of these fistulæ to the vascular arches of the neck. The large figures are on the vascular arches; *2* is on an obliterated trunk; *3*, is on the commencement of internal carotid; *4* is on the right subclavian. The smaller figures near the arrows are on the fistulous tracks. Note that track *3*, passes below the fork of the carotids and track *4* passes below the subclavian artery (right side).

external and internal carotids, can only be true on strict embryological grounds when the second branchial cleft persists. That almost all fistulous tracks take this direction is absolute proof

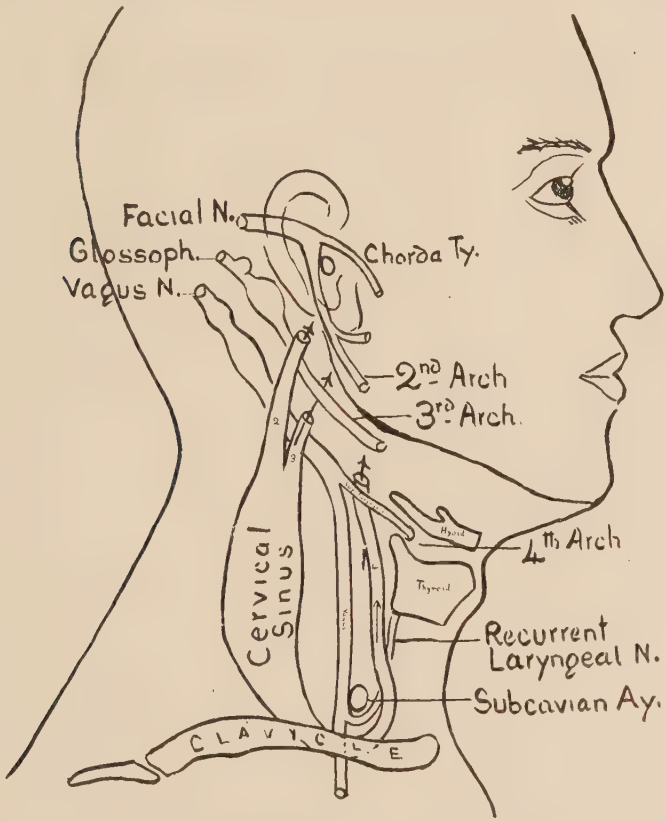

FIG. 9.—A complementary picture to Fig. 8, to show the anatomical relationships of persistent branchial fistulæ to the nerves of the neck. Arrows are placed in the fistulous tracks leading from the cervical sinus. Note that track *3* passes beneath the glossopharyngeal nerve and above the superior laryngeal branch of the vagus; also that track *4* passes downward below the subclavian artery (right side.)

of the persistence of this cleft in the great majority of cases. Too few careful records of dissection are available to enable us to speak authoritatively as to the frequency with which the

third cleft persists, while I am not acquainted with any observation showing a fistulous track passing around the subclavian artery or the aorta, the only possible route when the fourth cleft persists.

There is abundant evidence to justify us in attributing lateral cysts and fistulæ situated in the middle of the neck to the persistence of the cervical sinus and the branchial clefts. But it is more difficult to explain how cysts situated close to the base of the skull and those in the submaxillary and lingual regions can be derived from the same source. It will be conceded that the cysts under consideration conform to the type of branchiogenetic cysts in anatomical structure and contents. Therefore the difficulty in accepting them as truly branchiogenetic will disappear if a satisfactory explanation can be offered as to the manner in which they are carried from their original location and disintegrated into two or three separate fragments. It appears to me that if we admit the possibility of these cysts being carried from a lower level to a higher by muscular agency in the rearrangement of the muscular planes of the neck that the problem is easily solved. After due deliberation I have adopted the theory that ranula, submaxillary cyst and deep cervical cyst of the type described are derived from the cervical sinus which has been carried from its original position by the muscles of the branchial arches and those of the hypoglossal segments during the process of their migration. On this theory the deep cervical cyst which has such characteristic anatomical boundaries would be carried upward by the palate muscles, all of which except the tensor palati (first arch) are derived from the third and fourth arches, whereas the cysts found in the submaxillary and lingual regions would be carried upward by the muscles of the tongue derived from the hypoglossal group which belongs to the seventh, eighth and ninth body segments.

CANCER OF THE OVARY, WITH INVASION OF THE SIGMOID FLEXURE

By P. E. TRUESDALE, M.D.
FALL RIVER, MASS.

Approximately 3 per cent. of cancer deaths in females results from malignant disease of the ovaries. This is about one-tenth as many deaths as are recorded from cancer of the uterus, but Taylor[1] observes that it does not correctly indicate the frequency of malignant disease of the ovaries, because many more of these cases are cured than of cancer of the uterus.

From the annual reports of the Massachusetts General Hospital for six years (1914–1919) it was found that there were 29 cases of cancer of the ovary among 758 cancers in females and approximately 5500 laparotomies performed on females for all causes. Of these 29 cases, 16, or 55 per cent., were found to be inoperable when examined by laparotomy.

In the reports from the Mayo Clinic for a period of five years (1914–1918) there were 150 operations for cancer of the ovaries and 26 "exploratory" operations for the same cause among 5175 laparotomies for diseases of the uterus, tubes and ovaries.

Among 1700 abdominal sections for diseases of the female organs in our clinic at Fall River, Mass., 30 cases of cancer of the ovary were found. During the same period there were 250 cases of cancer in women, making the relative frequency of ovarian cancer 12 per cent. in our records. Of the 30 cases examined by abdominal section, 17, or 56.6 per cent. proved to be inoperable.

[1] Bulletin 6, October, 1915, Am. Soc. for Control of Cancer.

The average duration of illness, *i. e.*, discovery of a tumor or complaint of pelvic trouble, in our series was nineteen months; 21 of the patients were married and 9 were single. The relative ages were as follows: 20 to 30, 3; 30 to 40, 6; 40 to 50, 9; 50 to 60, 5; 60 to 70, 7.

The important feature in the study of these records is the high percentage of cases of cancer of the ovary found inoperable when examined by laparotomy. Add to these figures the number of cases classified as inoperable upon physical examination, on account of palpable metastatic nodes and ascites, and it becomes clear that the disease is more common than present statistics show. Occurring, as it does, most frequently within the period of the menopause the moderately discomforting symptoms of the early or midperiod of the disease are too frequently ignored.

Ovarian cysts are signposts of cancer and their dangers will continue to be disregarded until the frequency of their inoperability is given wide publicity. The root of the difficulty lies in the unwarranted fear of operation, the false sense of security enjoyed by women carrying painless tumors, and occasionally an almost entire absence of symptoms in the early stage of ovarian cancer.

A pelvic tumor in a woman of cancer age cannot be "watched" with impunity any more than a tumor of the breast. "Watching" tumors until there was abundant evidence of malignancy resulted in an increase in cancer deaths from 66.9 per 100,000 in 1900 to 92 per 100,000 in 1915. Fewer women and fewer doctors now make a business of "watching" tumors and the percentage of cancer deaths has not increased since 1915. Yet the fact that in the average hospital more than 50 per cent. of the cases of ovarian cancer are found to be hopeless at the time of operation opens up a small field at least in which a reduction can be made in the total deaths from cancer. This can be done if every easily palpable pelvic tumor, especially the ovarian cyst, is looked upon as potentially cancer and extirpated without inordinate delay.

ORIGIN. The precise origin of cancer of the ovary is still a mooted question. The subject is so intricate and so laden with theoretical dogma that the authors of gynecological pathology frequently record their observations and allow the reader to make his own interpretation.

Goodall has made an intensive study of the origin of ovarian tumors, publishing the results of his investigations in 1911[2] and again in 1920.[3] From his contributions a more intelligent understanding of the genesis of ovarian cancer is obtainable. In his study of the comparative embryology, histology and function of the cow's ovary which bears a close resemblance to the human, Goodall expresses the belief that epithelial tumors of the ovary do not spring entirely from fetal rests, but that they do arise from postnatal structural defects as well. In nearly every ovary in women over thirty-five years of age he observed a dipping of the germinal epithelium into the deep crevices over the whole surface of the ovary, owing to the cicatrization of the corpora lutea; and in this same class he demonstrated the resolution of the corpora to be less rapid and less complete and marked by fibrosis and scar. On the contrary, in the child resolution is complete without shrinking or mutilation of the ovary or its surface. Therefore it seems fair to assume that while cancer finds its origin in the primordial follicles deep in the ovary, many tumors arise from the intractions of the germinal epithelium in the cicatrization of the corpora lutea. When the cells of the corpora lutea proliferate they occasionally lose all signs of epithelial arrangement, and when they give rise to neoplasm they develop an interstitial cell growth histologically sarcoma rather than carcinoma.

A striking feature in connection with the malignant tumors of the ovary is the mixed character of the tissue growth. Several types may exist in the same specimen. The tissues may change almost imperceptibly from carcinoma to perithelioma and then to sarcoma, a process which in itself indicates the complexity of

[2] Goodall: Tr. Am. Gynec. Soc., vol. xxxvi.
[3] Goodall: Surg., Gynec. and Obst., March, 1920.

its birth cells. In the fetus and child the ovary is frequently found lobulated, and the sinking of the germinal epithelium into the primitive deep clefts gives rise to cysts which sometimes degenerate into cancer in later life. What the agent is that provokes this change remains an enigma. One thing is clear: That the defence against cancer growth possessed by the tissues of early life is lost and a local irritation only is needed to produce a cell activity in structures which are prone to take on aberrant growth.

The cystic carcinomata commonly arise in cystadenoma or the papillomatous varieties. They do not attain a very large size, and before removal they frequently are not recognized as malignant unless the papillomatous growth has extended through the wall of the tumor to invade the peritoneum. When this happens the true character of the growth is revealed by its exuberant vegetation giving rise to peritoneal and other metastasis.

The attempt to classify ovarian neoplasms has proved so difficult that the older writers were content to divide cancer into two forms, the cystic and the solid. This is a practical arrangement from a clinical point of view, though it fails to indicate the embryological or developmental origin of these tumors.

Adami[4] has classified the malignant tumors of the ovary in three types:

1. New growth of epithelial type
   - *a.* Cystic carcinoma.
   - *b.* Solid carcinoma.
2. New growth of connective tissue type
   - *a.* Endothelioma.
   - *b.* Perithelioma.
   - *c.* Sarcoma.
3. Mixed tumors
   - *a.* Myosarcoma.
   - *b.* Adenosarcoma.
   - *c.* Sarcocarcinoma.
   - *d.* Cystic carcinoma.
   - *e.* Cystic sarcoma.

[4] Principles of Pathology, p. 854.

Symptoms. The symptoms of carcinoma of the ovary vary widely according to the size of the tumor, its rapidity of growth and the degree of encroachment upon adjacent organs. When cancer is the result of degeneration of an ovarian cyst the symptoms may be those of the cystic tumor only, which are usually a feeling of fulness and weight in the abdomen. When carcinoma becomes superimposed there may be constitutional symptoms, such as loss of weight, interference with appetite, digestion, etc. Symptomatic evidence of cancer of the ovary may be very vague even in the mid-period of the disease. Cachexia and ascites are usually symptoms of inoperability.

Prognosis and Treatment. The outlook for favorable results in dealing with cancer of the ovary depends upon the extent of growth before the standard operative treatment of complete removal of both ovaries is adopted. Since ovarian cyst is a known precancerous condition, this type of tumor should be removed when found and its extirpation should be accomplished always without rupture of the cyst wall. Peritoneal metastasis, proving rapidly fatal, may result from spreading the excrescences of malignant papillomata over the peritoneum. Prompt examination of an apparently benign cyst should be made for malignant changes while the abdomen is open. Whenever new growth is found the other ovary, potentially cancerous, should also be removed, because it is common knowledge among pathologists that when fetal rests occur in one of the bilateral organs they are always present in the other.

The papillary type is often of a low grade of malignancy, and although it is found disseminated over the peritoneum, the use of radium and roentgen rays after the removal of both ovaries will retard if not cure the condition.

The prognosis in solid carcinomas of the ovary, which are also unilateral or bilateral, is not so good, inasmuch as they frequently metastasize before they are discovered. Graves[5] describes this form as genuine idiopathic carcinoma which

[5] Graves's Gynecology, p. 339.

develops directly from previously unchanged ovarian tissue. They are rare and frequently found to be inoperable. This form is usually of the medullary type but may be scirrhous or myxomatous. According to Nicholls[6] the ovarian tissue is

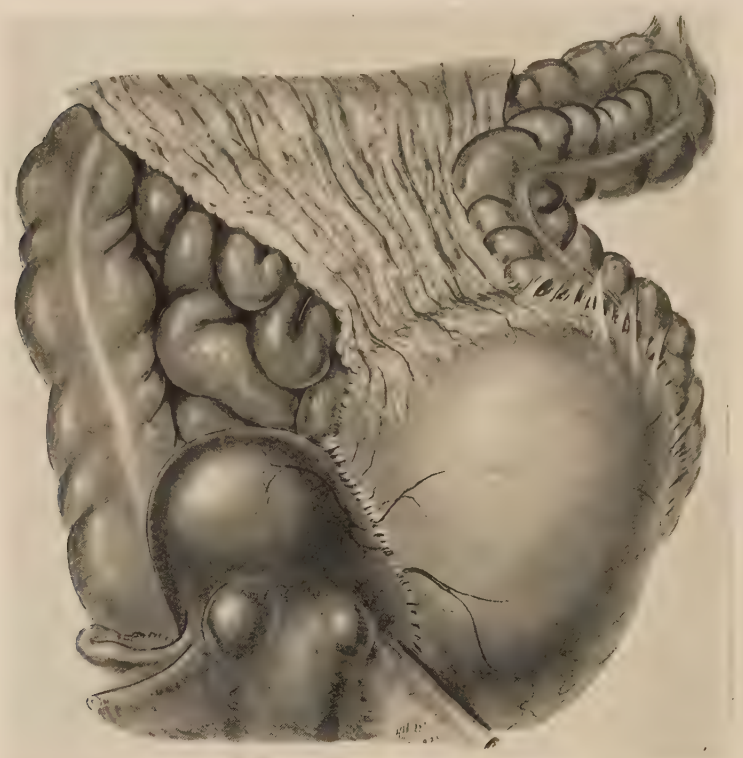

FIG. 1.—Case No. 2170. Showing large ovarian tumor adherent to fibroid uterus, omentum and bowel. Bloodvessels from the adjacent structures are seen entering the periphery of the rapidly growing tumor.

frequently diffusely infiltrated or destroyed or the main mass of the organ may be pushed to one side in the course of growth. The solid tumor, though usually small, may attain the size of a child's head. On account of the rapid growth, blood supply

[6] Montreal Med. Jour., 1903, xxxii, p. 326.

at the periphery of the tumor may become inadequate and the vitality of its tissue is sustained by adhesions to the parietal peritoneum, intestine and omentum. Such a condition was found to be the condition in the following case:

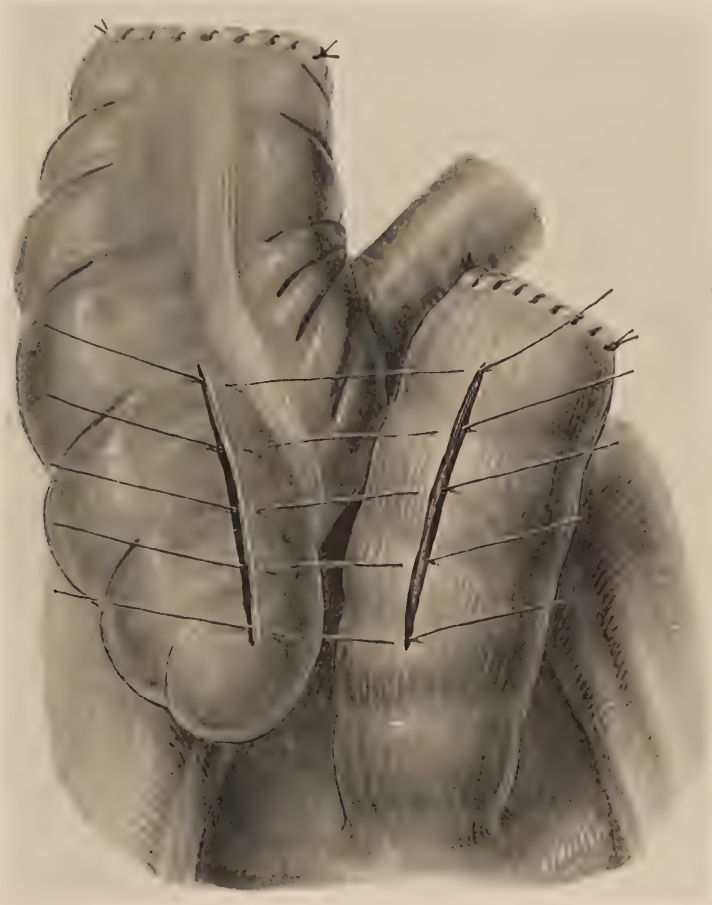

FIG. 2.—Case No. 2170. Anastomosis between the cecum and the severed end of the rectum.

CASE 2170.—Aged forty-nine years; single. Admitted to our hospital in Fall River, Mass., March 7, 1915.

The patient had known for years that she had a tumor in the lower abdomen. From this she had suffered no special discomfort until October, 1914, when there developed a feeling of

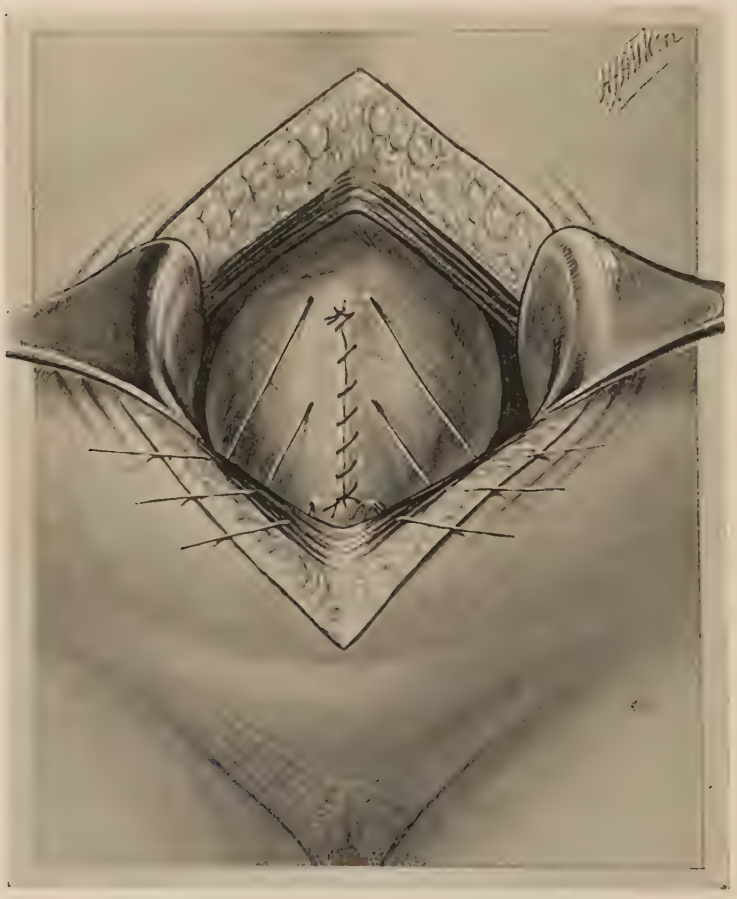

FIG. 3.—Case No. 2170. Stump of cecum suspended in the lower angle of the abdominal incision.

fulness and pressure in the lower abdomen. Indigestion supervened in the form of distress at varying intervals after eating, anorexia, flatulence, sour stomach and obstipation. During the last three months she noticed a rapid increase in size of the

tumor in the left side of the lower abdomen. Her physician had advised operative treatment several months ago, and suspecting malignant disease, he now prevailed upon her to report for operation. She had lost thirty pounds in weight in six months.

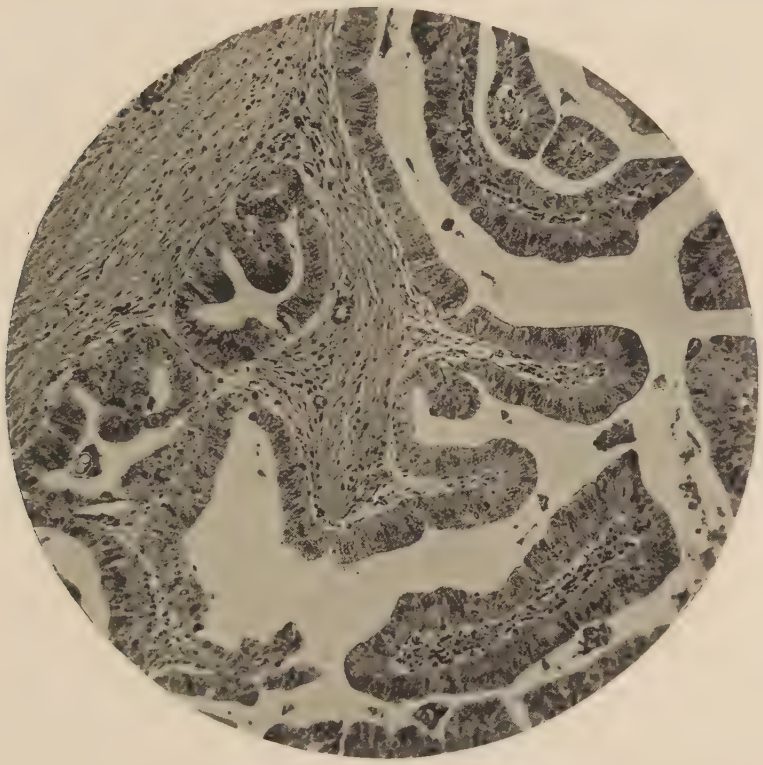

FIG. 4.—Microphotograph, Case No. 2170. Cylindrical type of epithelium resembling that of the intestinal mucosa.

Physical examination revealed no disease other than a tumor occupying the lower abdomen. It consisted of multiple solid growths arising in the pelvis, apparently uterine fibromata. On the left side an oval, smooth, solid tumor had reached the umbilicus. The entire mass had a very narrow range of mobility.

The operation revealed multiple fibroids of the uterus crowded

to the right side by a solid tumor of the left ovary about the size of a cocoanut. This tumor was the fixed portion of the entire mass. It was involved in adhesions to the parietal peritoneum, descending colon, omentum and loops of small gut.

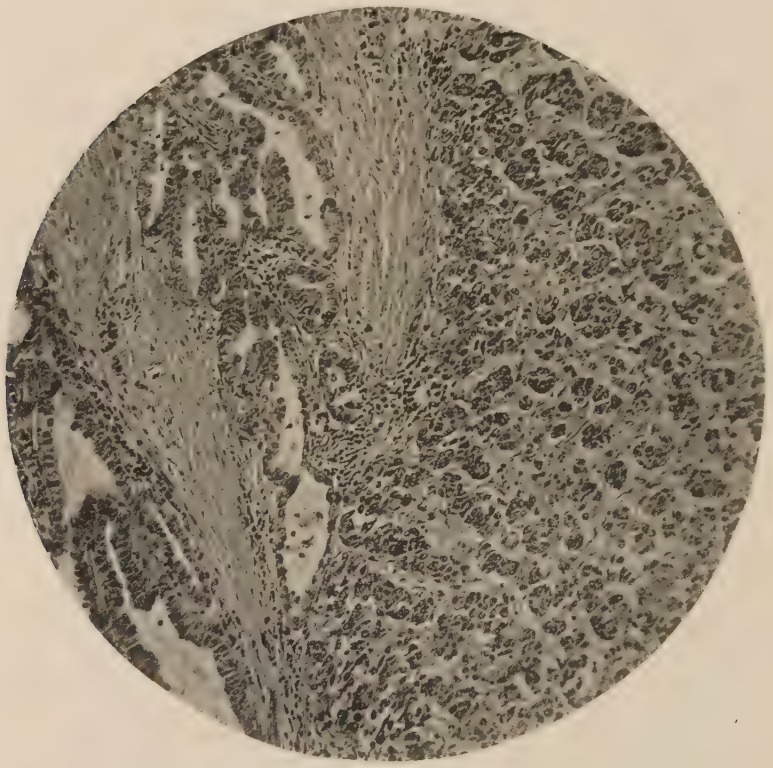

FIG. 5.—Microphotograph, Case No. 2170. Same type of tissue growth combined with ordinary adenocarcinoma; the cells are arranged in solid cords, with bare suggestion of a lumen.

The picture presented did not invite interference, except for the reason that the ovarian tumor had the appearances of malignancy. There was very little free fluid and no metastatic nodes were discovered within the abdomen or elsewhere. Therefore a considerable operative risk for the eradication of the disease

was deemed justifiable. A subtotal hysterectomy was done. The adhesions to the ovarian tumor were unusually vascular, indicating the proliferation of numerous small vessels to sustain the vitality of the tumor. For a distance of 10 cm. the growth had invaded the descending colon, destroying the coats of the

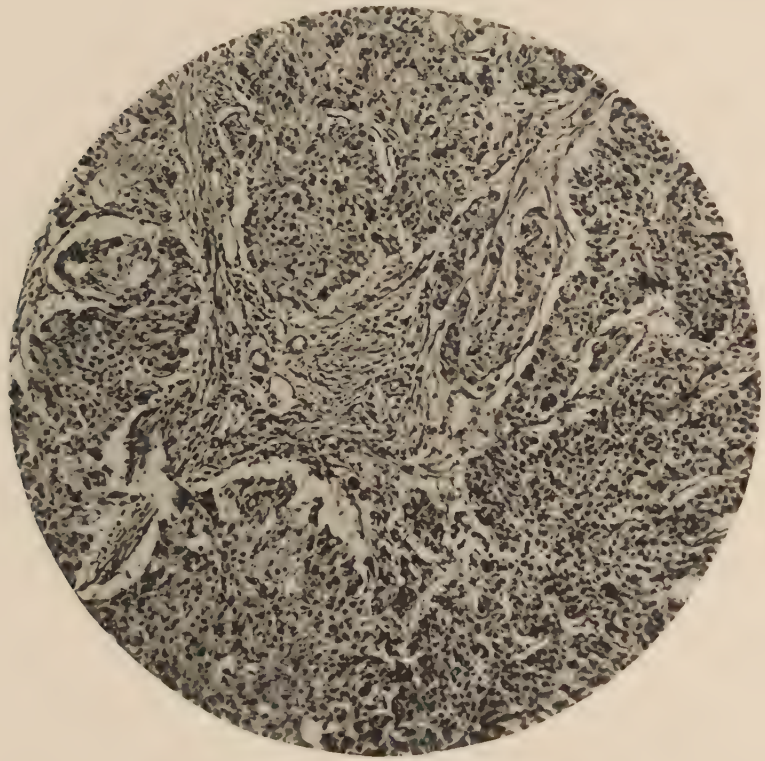

FIG. 6.—Microphotograph, Case No. 2170. Undifferentiated epithelium, with masses of connected tissue stroma between alveolar groups of cancer cells.

bowel. About 30 cm. of the colon was excised with the tumor. The distal stump of the bowel was infolded with a purse string of fine silk. An artificial anus was made with the proximal end. Aside from the troubles incident to a recent colostomy the convalescence was uneventful.

Two years later, in March, 1917, the patient's general state was very satisfactory. There was no evidence of recurrence, and she requested that the normal outlet of the colon be restored.

March 19, 1917, the second laparotomy was done. After opening the abdomen no return of the disease was discovered

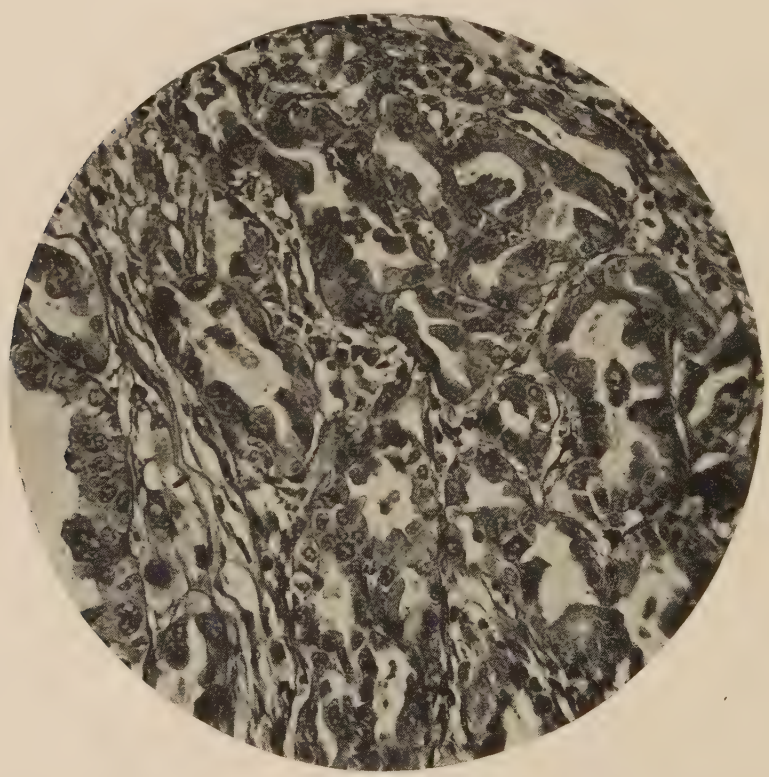

FIG. 7.—Microphotograph, Case No. 2170. The cuboidal and tubular form of cell arrangement suggesting that of convoluted tubules in the kidney.

and the field surveyed with the purpose of making an end-to-end anastomosis of the colon. This seemed impracticable, owing to the wide separation of the opposing ends of the colon and the firm adhesions in the left upper quadrant of the abdomen. A workable alternative was in plain view by the juxtaposition

of the head of the cecum and the blind end of the rectum. Between the two a lateral anastomosis was made. Under these conditions the function of the large bowel became a source of interest. In spite of a competent anastomotic opening between

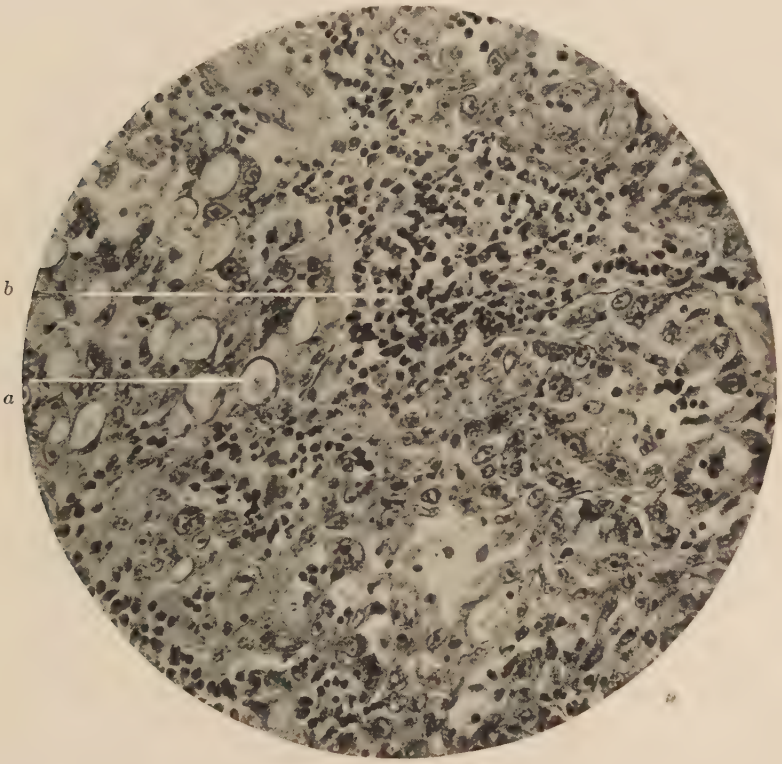

FIG. 8.—Microphotograph, Case No. 2170. Tubular arrangement not evident: (*a*) the cells have become vacuolated, suggesting adrenal structure; (*b*) groups of plasma cells in the stroma.

the cecum and the rectum the normal one-way passage of intestinal contents continued by evacuation of the bowel through the artificial anus. This could not be considered extraordinary while there was the resistance at the anus of the closed sphincter muscle; but the result was the same when a tube of large caliber

was placed in the rectum. An enema given through the artificial anus returned in the presence of a closed rectal sphincter, but passed out through the indwelling rectal tube. A little later enemas given by the artificial anus returned, and it seemed

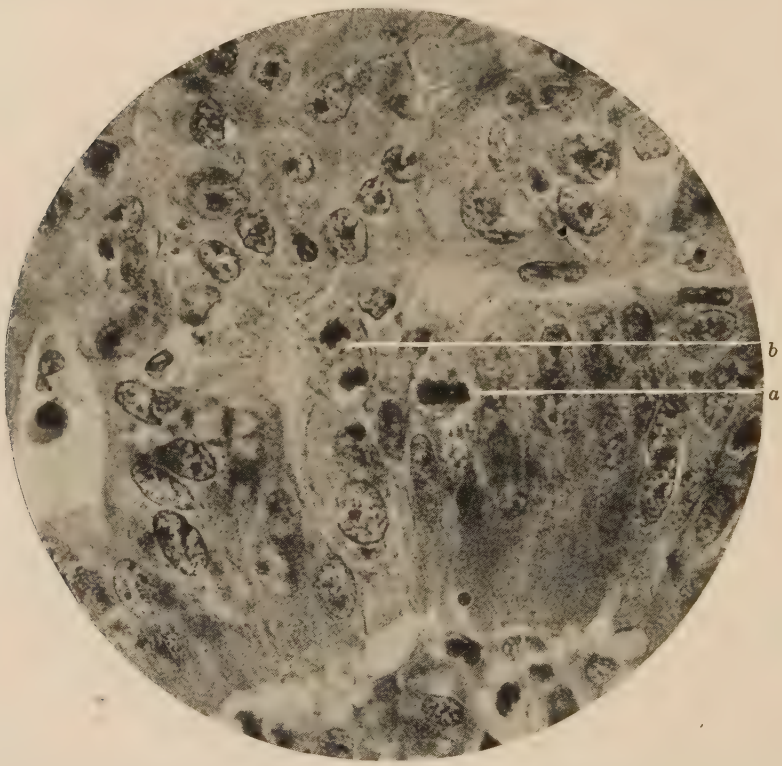

FIG. 9.—Microphotograph, Case No. 2170. Rapid growth of the tumor is observed here in the appearance of numerous mitotic figures in areas where the cylindrical type of epithelium prevails: (*a*) monaster; (*b*) diaster.

probable that the anastomotic opening had closed. An examination with the sigmoidoscope revealed the communication adequate. Therefore it was deemed wise to resect the colon. This was done, leaving the cecum with its sutured end suspended in the lower angle of the abdominal incision. An indwelling

rectal tube was employed to relieve back pressure. This tube was removed in ten days. About a week later a fecal fistula developed which closed spontaneously after two months.

The patient is now well five years after removal of the growth, and the result makes justifiable an occasional excision of wide proportions in the presence of an extension of cancerous growth by contiguity.

It is hoped that the report of a case of this character, with its complications and hazards and the suffering entailed with good luck in pursuit, will serve as a reminder that "a stitch in time will save nine," and that the average woman, even of the intelligent class, is not yet aroused sufficiently to the importance of early examination for pelvic disorders and the wisdom of adopting prompt surgical measures for the removal of pelvic and abdominal new growths.

References

1. Taylor: Bulletin 6, Oct., 1915, Amer. Soc. for Control of Cancer.
2. Goodall: Transactions Amer. Gynecological Soc., vol. xxviii.
3. Goodall: Surgery, Gynecology and Obstetrics, March, 1920.
4. Adami: Adami and Nicholls, Principles of Pathology, p. 854.
5. Graves: Graves' Gynecology, p. 339.
6. Nicholls: Montreal Med. Journal, vol. xxxii, 1903, p. 326.

DISCUSSION

Dr. Albert J. Ochsner, Chicago:

Dr. Truesdale's paper recalls a fact that was brought before this Society a good many years ago by Professor Pozzi. He reported some cases of this form of malignant growth originating in the ovary in which the secondary tumors covered the parietal peritoneum and various portions of the intra-abdominal organs. He showed at that time that the recurrence in these cases after the removal of the original tumor was usually in the broad ligament, and thought it was possible for some of these advanced cases to recover completely and for the secondary tumors covering the peritoneum to disappear entirely provided the primary growths in the broad ligament were removed. In our hospital we have encountered a number of these instances in which we had considered the patient hopeless and still in which the patient has lived, in one case as long as eighteen years; in this case we had given an absolutely hopeless prognosis. But the fact should be remembered that unless one removes both ovaries and tubes and the uterus and as much as possible of the broad ligaments that one will almost invariably have a recurrence in the broad ligament and that then the malignancy seems to be so severe that a secondary operation no longer is feasible. If we find a cyst on one side filled with colloid material or if there is a ruptured cyst with colloid material no matter how perfectly normal the other ovary may be one should invariably remove both ovaries, the uterus and as much of the broad ligaments as is possible. We have had some cases in which a primary cyst was removed and in which the other ovary had been left in place as it seemed normal, but in each case the patient later returned with a secondary carcinoma such as Dr. Truesdale has described.

BLOOD TRANSFUSION IN ASSOCIATION WITH OTHER SURGICAL PROCEDURES IN THE TREATMENT OF PERNICIOUS ANEMIA WITH REPORT OF CASES

By NELSON MORTIMER PERCY, M.D.
CHICAGO, ILL.

This paper is based upon the study of 129 carefully diagnosed cases of pernicious anemia which have come under my observation and treatment during the past seven years. While it is not within the scope of this paper to discuss the symptoms and diagnosis of pernicious anemia, I have been so impressed with the importance and constancy of a few signs and symptoms that they may be worthy of mention.

Achlorhydria. In all cases in which a test was made, with one exception, no trace of free hydrochloric acid was found in the fasting contents and in the specimens of test-meal. The exception was a very early case and showed a very low hydrochloric acid content. A few cases were in such an extreme condition that it was not deemed advisable to subject them to the strain of passing the stomach-tube. In all other cases the gastric analysis was part of our routine in making the diagnosis. The absence of free hydrochloric acid occurred with such regularity that I would hesitate to make a diagnosis of pernicious anemia in any case showing the presence of free hydrochloric acid in the stomach unless it was a very early case and the acid content very low.

Tongue. The appearance of the tongue was noted in every case, which revealed a peculiar, smooth, glossy surface. In

some this was present only on the sides of the tongue, in others its whole surface was involved. This appearance of the tongue, which was always present but in varying degrees, is due to an atrophy of the mucous membrane. A glossitis was present in a large percentage of our cases. Hunter[1] lays particular emphasis upon the lesions in the mouth and claims there is no other anemia in which glossitis is so constant and persistent. The appearance of the tongue is so constant it may be considered the most important external sign of pernicious anemia.

Pigmentation. Pigmentation was found to be present in the majority of cases, especially on the backs of the hands. In some this may be diffuse, in others freckle-like.

Hypertension (Chronic Nephritis). It was noted that hypertension (chronic nephritis) frequently coexists with pernicious anemia, both probably being due to chronic infection, but having no definite connection with each other. The cases having high blood-pressure were of middle age or beyond. Strange as it may seem the hypertension persists through periods of severe weakness and with a blood count as low as one million or under, only letting down when the patient becomes extremely ill in the terminal state of the disease.

The disturbance of renal function which accompanies marked cases of pernicious anemia, as pointed out by Christian, was noted in many of our cases. The disturbance is similar to that found in patients with advanced nephritis, but is not accompanied by hypertension or any other evidence of chronic nephritis. The disturbance seems to be due to the anemia and subsides as this improves. It is important from the standpoint of prognosis to determine in each case whether the disturbance of renal function is due to the anemia or to chronic nephritis.

Diarrhea and Vomiting (Intermittent). Attacks of diarrhea and vomiting, especially the former, were frequently noted and were found difficult to control by medical means. These cases yielded readily to blood transfusions, followed by administration of large doses of hydrochloric acid. The

[1] British Med. Jour., Nov. 9, 1907.

vomiting invariably stopped immediately following transfusion and the diarrhea usually subsided within a few days. In a number of instances an attack of diarrhea was the first symptom of the disease noted by the patient.

Nerve Manifestations. The nerve symptoms noted were many and varied, ranging from the most common, that of tingling in the fingers and toes, to those simulating tabes and multiple sclerosis. The tingling sensation in the fingers, the presence of which varies from time to time, was noted in practically every case. Marked psychical disturbances were noted in some cases.

The characteristic appearance of the tongue, the pigmentation and the achlorhydria occur with such constancy that their presence may often be the deciding factors in the diagnosis in which there is a borderline blood picture.

The transfusion of blood in pernicious anemia has recently received a great deal of attention and has been advocated by some as the sole means of treating this disease. Others have recommended splenectomy. The results from both have been disappointing. The group of patients who have been splenectomized for pernicious anemia during the past few years is sufficiently large to permit the conclusion that removal of the spleen will not cure this condition. Since it seems that pernicious anemia is the result of infection which is primary elsewhere than the spleen, it is evident that some further attempt should be made to relieve this condition than mere removal of the spleen.

While the etiology and pathogenesis of pernicious anemia is still a perplexing problem, it seems evident that besides there being present a condition of increased hemolysis there is some toxic action on the bone-marrow. From the study of our cases we have been impressed with the value of the observations of Hunter[1] with respect to the toxic or even infectious nature of the disease. Just what the infective agent or toxin concerned in pernicious anemia may be is a matter of much speculation.

[1] Loc. cit.

Moffit[1] believes there is an agent which may act differently at various times, or that there may be several hemolytic poisons which may cause splenic, hemolymphatic or marrow hemolysis.

The fact that removal of the spleen brings about a marked reduction in the blood destroyed would indicate that the increased hemolysis occurring in pernicious anemia is in some way associated with an abnormal functioning of the spleen. Robertson,[2] in studying the blood destruction in pernicious anemia before and after splenectomy, found that the greatly increased hemolysis before operation showed a constant and marked decrease after operation.

Early in our work, in studying two cases of pernicious anemia, it was noted that symptoms of chronic cholecystitis were a prominent feature of the history and had been present for a considerable time previous to the onset of the anemia. The existence of an infected gall-bladder was demonstrated in both cases when the gall-bladder was drained. Since then every case has been studied for the existence of a chronic infection, and in 95 per cent. infective foci were demonstrable. The regions in which foci were found were the gall-bladder, appendix, teeth, tonsils and accessory sinuses to the nose.

In a bacteriological study of 9 consecutive cases of pernicious anemia subjected to laparotomy all specimens removed were sent to the laboratory of clinical research of the Sprague Memorial Institute. The report on specimens follows:

Case 1.—Specimens examined: Spleen, gall-bladder and appendix. The hemolytic streptococcus and Streptococcus viridans were grown from the appendix. No growth from spleen or gall-bladder.

Case 2.—Specimens examined: Spleen, gall-bladder and appendix. The hemolytic streptococcus and colon bacillus were grown from the spleen. The hemolytic streptococcus and Streptococcus viridans from the appendix. No growth from gall-bladder.

[1] Am. J. Sc. 1914, cxlviii, 817.
[2] Archives Int. Med., 1915, xvi, 429.

CASE 3.—Specimens examined: Spleen and gall-bladder. Appendix had been previously removed. The colon bacillus was grown from the gall-bladder. No growth from spleen.

CASE 4.—Specimen examined: Spleen. The appendix had been previously removed and the gall-bladder was pronounced negative at time of operation. No growth obtained from spleen.

CASE 5.—Specimens examined: Spleen, gall-bladder and appendix. Hemolytic streptococcus was grown from the spleen. The hemolytic streptococcus and Streptococcus viridans from the appendix. No growth from gall-bladder.

CASE 6.—Specimens examined: Spleen, gall-bladder and appendix. The colon bacillus was grown from the gall-bladder. The hemolytic streptococcus from the appendix. No growth from the spleen.

CASE 7.—Specimens examined: Spleen, gall-bladder and appendix. The Staphylococcus albus was grown from the spleen. The colon bacillus and hemolytic streptococcus from the gall-bladder. No growth from appendix.

CASE 8.—Specimens examined: Spleen, gall-bladder and appendix. No growth from spleen. Hemolytic streptococcus was grown from the appendix. Hemolytic streptococcus and colon bacillus from the gall-bladder.

CASE 9.—Specimens examined: Spleen, gall-bladder and appendix. Spleen and gall-bladder were negative. The hemolytic streptococcus and Streptococcus viridans were grown from the appendix.

In this series of 9 cases of pernicious anemia, bacteria were grown from 3 of the 9 spleens removed, from 4 of the 7 gall-bladders and from 6 of the 7 appendices. The only case not giving a bacteriological growth was the one in which the spleen was the only specimen removed, the appendix having been removed previously. This patient had a long-standing pyorrhea, for the relief of which a number of teeth were extracted. No culture was made from the mouth.

The predominating microörganism found was the hemolytic

streptococcus, being obtained in 7 of the 9 cases, the colon bacillus in 5, the Streptococcus viridans in 4, the Staphylococcus albus in 1.

The spleens removed have shown evidence of a chronic splenitis and usually perisplenitis, indicating that a toxic or infective process had been present.

Hunter[1] claims that the tongue and mouth furnish the most important portals of entrance of bacteria or their toxins into the circulation in cases of pernicious anemia. Smithies has grown bacilli and cocci of the hemolytic variety from infected areas about the teeth, tonsils and accessory sinuses to the nose in a considerable number of cases and places particular stress upon the importance of eradicating these foci of infection.

While it is impossible to state anything definite concerning the relation of these various infections to pernicious anemia, it is an interesting observation from both the standpoint of etiology and treatment.

In view of the theory that pernicious anemia is, in all probability, a disease of infectious origin and that the spleen has an abnormal hemolytic action on the blood elements, with a late bone-marrow exhaustion, it would seem that the rational treatment should consist of three main factors: (*a*) An attempt to stimulate the production of new blood by massive stepladder transfusions of whole blood; (*b*) to overcome the absorption of hemolytic bacteria or their toxins by the radical removal of local foci of infection; (*c*) to attempt the protection of newly formed and old red cells by splenectomy in selected cases.

Each of these steps plays an important part in the treatment. The repeated blood transfusions nourish and stimulate the bone-marrow to action and help to restore the secondary changes in the various organs; the eradication of active foci of infection relieves the patient of a chronic toxemia and possibly of an etiological factor of the disease; the removal of the spleen reduces the abnormal amount of blood destruction.

For transfusion we use the plain whole blood administered

[1] Loc. cit.

by a paraffin tube method in which the air is excluded from the blood by a column of liquid paraffin, delivering the blood to the patient in as near its normal state as is possible by an indirect method. It seems more rational not to add anything to the transfused blood or take anything from it, as is done by the citration of blood or its defibrination. A higher percentage of reactions occur following citrated transfusions than when just the plain whole undiluted blood is given.

Drinker and Brittingham[1] found that the citration of blood alters the erythrocytes so as to render them more susceptible to hemolysis when injected into the circulation, and they concluded that three elements make up the final total of reactions in citrate transfusion: (*a*) Very gross incompatibilities which escape *in vitro* detection; (*b*) changes in the plates, part of the process of coagulation; (*c*) direct action of the sodium citrate on red cells promoting hemolysis. While it is evident that the reactions following the use of citrated blood do not seriously interfere with its therapeutic value, we are inclined to believe that in severely anemic patients the use of undiluted blood has an advantage.

Of the 129 cases of pernicious anemia which have come under observation during the past seven years, 77 were transfused and subjected to laparotomy, 45 were transfused and all local foci of infections in which it was possible were eradicated, and 7 cases were in such a hopeless condition that no special treatment was advised.

In analyzing the various patients that have been splenectomized it is evident that certain cases are unsuitable for operation. The degree of anemia present or the length of time it has existed is of less importance in determining whether or not operation should be done than are the clinical manifestations of the disease. Our most striking result with pernicious anemia occurred in an individual who had been sick three years and had passed from clinic to clinic as a hopeless case of pernicious anemia. At the time she came under treatment she had been bedridden for

[1] Transfusion Reactions, Arch. Int. Med., Feb. 15, 1919.

one year, weighed about 100 pounds, had a red blood cell count of 800,000, was unable to take any nourishment and was absolutely helpless. After six blood transfusions, followed by splenectomy, appendectomy, drainage of gall-bladder and removal of infected teeth, this patient made a good recovery. It is now six years since the operation, and this patient is enjoying good health and performing the duties of a farmer's wife. Her blood-count has ranged between 3,700,000 and 5,700,000, and she has gained 80 pounds in weight.

Indications for Blood Transfusion. A careful examination should be made in every case of pernicious anemia, especially searching for evidence of cerebral or spinal-cord disturbances, and also to eliminate the aplastic type. The transfusion of blood is of very little value in either case. While the aplastic type will improve during the period of transfusions, they will relapse to their former condition immediately as soon as the transfusion treatment is stopped. The group of patients which present evidence of cerebral or spinal cord degeneration do poorly following transfusions. Patients who exhibit these changes with only a moderate degree of anemia, as is often the case, are practically not benefited at all from transfusions, or, in fact, by any other form of treatment. The destructive changes in the brain or cord usually progress without interruption. If, however, there is present a marked degree of anemia, transfusion will often result in sufficient improvement of their general condition to justify the procedure. So far we have encountered only one patient in whom the result was different from the above. In February, 1918, a patient came under observation with a blood-count of 1,200,000, with definite evidence of destruction in his spinal cord. Following four blood transfusions at intervals of one week his improvement was so marked it was thought justified to do a laparotomy for removal of his infected gall-bladder. At time of operation his spleen was found to be twice its normal size, so a splenectomy, cholecystectomy and appendectomy were done. He left the hospital in one month with a blood count of 4,000,000 and pursued his farmwork for

a period of twenty-one months, when he contracted influenza. Following this attack he began to go down hill and six weeks later returned in a weakened condition, with a blood-count of 1,600,000. The patient rapidly responded to a series of four transfusions and is back doing his farm work again. The difficulty in his legs has not improved, although it is no worse.

In the majority of cases of pernicious anemia, with the exception of the aplastic type and those with brain or cord lesions, a prompt remission can be brought about by a series of blood transfusions given at intervals of a week or ten days.

The immediate effects of transfusion are usually quite striking. The red blood-count is increased, often doubling immediately if the count is very low. The hemoglobin percentage rises and the number of platelets is increased. The blast cells become more numerous, and occasionally Howell's particles will appear in the blood, indicating a stimulation of the bone-marrow.

After transfusion the patients immediately, as a rule, volunteer the information that they feel stimulated and "much stronger than they felt before." A few hours later they become ravenously hungry, while previously food had to be forced upon them. This hunger and relish of their food persists even after the red blood count begins to fall. With improvement in the appetite the mental symptoms grow better, the insomnia is relieved and the glossitis clears up. There is no doubt that the transfusion of large masses of whole blood accomplishes more than the mere mechanical addition of so much blood. This may be due to the fact that the blood-forming organs are not only overworked but are also undernourished. During the interval the patient is being transfused a careful search for local infective foci should be made. Radiographic, cultural and physical evidence of such are frequently found in the tonsils, around the teeth roots and in the accessory sinuses to the nose. When such are found they should be eradicated as far as is possible. The remission brought about in this manner may vary from a few weeks to many months, when it will be necessary to repeat the transfusion.

Indications for Laparotomy. In the absence of evidence of extensive or progressive cerebrospinal damage, laparotomy should be considered in those patients who, after a series of transfusions and the eradication of local foci of infection, are in fair physical condition and whose blood picture does not remain improved for any length of time. In cases in which there is no evidence of bone-marrow stimulation from transfusions as shown in the blood picture, laparotomy is not indicated. When it appears that local foci of infection are present in the abdomen and that there is increased blood destruction by the spleen, laparotomy is justified, provided the above contra-indications are absent. While the comprehensive laparotomy is a serious operation and must not be attempted on poor risk patients, one is often surprised at the slight amount of shock resulting when it is performed on patients prepared by preliminary step-ladder transfusions. The incision should be in the midline and not through the left rectus muscle, since the gall-bladder and appendix cannot be expeditiously excised through the left-sided incision. It is also a fact that splenectomy can be done more readily through the midline, because the splenic pedicle and the vasæ brevis can be easily secured from below.

In cases presenting an icteroid color in which hemolysis is marked, as shown by the examination of the duodenal content after the method of Schneider, laparotomy may be indicated in the absence of evidence of any pathological condition in the abdomen other than that pointing to the spleen. The operation should be exploratory in character, the procedure followed depending upon the pathological conditions found. In our cases the spleen was usually removed, but only rarely did exploration reveal that the spleen alone was involved.

In the 77 laparotomies performed, the spleen, gall-bladder and appendix were removed in 54 cases; the spleen and gall-bladder in 11; the gall-bladder and appendix in 4, and the spleen alone in 4. There were 8 deaths, or an operative mortality of 11 per cent. These included all cases that died before leaving the hospital. One death occurred four weeks and

another two months after the operation. In all cases except 3, one or more transfusions were given previous to operation. In 40 cases a transfusion was given on the table at the finish of the operation, and in 10 cases a transfusion was given during the interval between the operation and the time the patient left the hospital. Of the 69 cases that left the hospital, 5 had recurrence of symptoms at the end of four months and died at intervals of eight to twelve months. Ten had recurrence at the end of six to eight months and followed about the same course. Forty-eight were in good condition at the end of twelve months. Of these, 12 are alive at the end of two years, 9 at the end of three years, 4 at the end of four years, 5 are living nearly five years since operation and 1 a little over six years. Two of the five-year cases have been retransfused, 1 several times, the other only twice. The one living six years since operation has had no transfusion since operation. Two of the four-year cases have been back for transfusions, as have also 4 of the three-year cases, 5 of the two-year cases and 8 of the one-year cases.

The progress of the 4 cases in which the gall-bladder and appendix were removed without the spleen was not as good in any instance as was the average of other cases. They did not experience the immediate remission of the average case of the other group, and all but one had an early recurrence of their anemia which had been temporarily improved by the transfusions. The spleen was not removed in these patients because it was not enlarged and there were no adhesions to indicate that there had existed a splenitis or perisplenitis. It is evident that some of our patients should not have been operated, as undoubtedly just as good or better results would have followed transfusion alone.

Forty-five cases were treated by transfusions without other surgical procedures than those for the eradication of local foci of infection when present. In 10 of these, most of which were of the aplastic type, no marked improvement resulted. In 12 cases, all of which presented evidence of cerebral or cord involvement, some improvement was noted in the blood picture

and general condition, but the nerve destruction progressed without interruption. In 23 cases the transfusions brought about a marked improvement and in some a very rapid remission of the disease resulted. In no instance was the remission as complete as in several of the cases which were operated. The longest remission noted following a series of transfusions was eleven months, the majority, however, required repeated transfusions at much shorter intervals. Two patients are still enjoying fair health after the lapse of nearly two years since their first transfusion

It cannot be said that the regimen as outlined in this paper will result in a cure in any case of pernicious anemia. From our experience it seems reasonable to state that 25 per cent. of these individuals can be removed from an invalid class to the useful class for a few years, and that in 56 per cent. their lives can be prolonged a sufficient length of time to justify the procedures.

Sufficient time has not elapsed to determine the relative values between the treatment of pernicious anemia by transfusions alone, and that by transfusions plus splenectomy and removal of other foci of infection in the abdomen. It is our opinion, however, that in properly selected cases blood transfusions plus laparotomy, as outlined above, will give more prompt, more complete and longer remissions of the disease than transfusions alone or any other known treatment.

DISCUSSION

Dr. Albert J. Ochsner, Chicago:

I have seen all of these cases and I am perfectly certain that of the 48 cases that are now alive out of this number of 77, practically all would be dead by this time had they not been treated with transfusion of normal blood. Practically all of them came to the hospital in an absolutely hopeless condition, having been treated by internal means and abandoned, so that I believe the conclusions in the paper are very moderate. There seems to be an inability in these patients to produce as much new blood as is destroyed by the spleen, and by feeding the blood-producing organs by the transfusion of whole blood these blood-producing organs seem to acquire the ability to produce blood again after they had once lost this ability. The physiological business of the spleen seems to be to dispose of the blood that is no longer of any use, but having done this for a period during the advance of the pernicious anemia it seems to have formed a vicious habit. Then again having removed the probable cause of the infection which destroyed the blood-making power of the blood-making organs these organs have gained three very distinct advantages by this operation: first, they have been fed up; second, they are no longer retarded by the infection from these foci; and third, the blood which they produce can all be used by the body, while otherwise a portion would be unnecessarily destroyed. One case I saw repeatedly in consultation with several of the very excellent internal medical men, was simply gasping for breath and it seemed foolish to try to do anything. The woman then weighed 87 pounds, while today after six years she weighs 185 pounds. At that time she had less than 1,000,000 red blood cells, while now she has over 4,000,000. I am sure this procedure is worthy of use if done according to the method detailed.

Dr. Charles L. Gibson, New York City:

Has Dr. Percy observed any stenosis of the pylorus in these cases? Attention has been called to this condition in advanced cases of pernicious anemia.

Dr. Nelson M. Percy, Chicago (in closing):

As far as I know, pyloric stenosis was not present in any of our cases. In all cases operated the abdominal exploration included a careful examination of the stomach, and in no instance was there any tendency to stenosis of the pylorus, and in those not operated, examination did not reveal anything to indicate a stenosis might be present.

FATAL POSTOPERATIVE PULMONARY THROMBOSIS

By A. J. OCHSNER, M.D.
CHICAGO, ILL.

AND

CHESTER C. SCHNEIDER, M.D.
MILWAUKEE, WIS.

It has seemed worth while to consider our experience with postoperative pulmonary thrombosis in connection with a review of the most important papers which have been written upon this subject, with a view to bring out any points of value in the direction of prophylaxis, as none of the methods of treatment of the condition, once it has been established, seem to have proved successful.

It seems clear from all of the many careful observations that are recorded in the literature, as well as from our own experience, that the condition does not depend upon any one cause, although most observers seem to agree upon several causes which are more important than others. In order that these views may be brought out clearly, we have stated each cause, together with the name of its author, in as concise a form as possible before stating our own observations and conclusions.

Causation. The causes of pulmonary thrombosis in their order of importance are: (1) local infection; (2) anemia; (3) slowing of blood stream; (4) subnormal general physical condition; (5) cachexia; (6) microörganisms in the blood; (7) excess of white blood cells; (8) inefficient hemostasis; (9) traumatization of tissues with retractors, etc.; (10) injury to veins of

extremities, due to badly arranged operating table; (11) injury to intima of veins; (12) excess of calcium salts in the blood.

HISTORY. The condition has been recognized and discussed for generations. Van Swieten,[8] in 1705, recognized that clots occur in the vessels during the puerperium, and wrote gravely on their prognosis.

In 1784 Dr. Charles White, a distinguished London physician, did not associate pulmonary embolism with phlegmasia alba dolens.

Virchow, in Berlin, and Meigs, in Philadelphia, wrote on the subject of blood-clots stopping the stream of the circulation; Virchow advocating that the obstructing clot must always travel to the heart and the pulmonary arteries; Meigs advocating that it may be formed *in situ* in the heart or pulmonary artery as well. Virchow upheld the embolic theory, Meigs the thrombosis theory.

Virchow[29] first showed the relation between thrombosis and emboli, pointing out that emboli not infrequently have their origin in the softening, breaking down, and detachment of venous thrombi. He stated that in embolism the plug consists not of blood-clots but of so-called vegetation or concretion of fibrin which has been washed off from the valves of the heart or from the endocardium and carried forward by the arterial current until the vessels become too small in caliber to allow it to advance any further.

ANATOMY. Cohnheim and Litten[9] experimentally demonstrated the fact that the arterial ramifications of the pulmonary artery do not anastomose. They are end-arteries.

The bronchial arteries supply the parenchyma of the lung with not insignificant quantities of blood. Virchow called them the nutrient arteries of the lung. They showed that pulmonary infarcts do not result in the death of the lung when death of the animal itself does not result, but prevent the functioning of the infarcted area for purposes of oxidation.

They conclude that, despite the absence of parenchymatous changes in infarcted lungs in which the quantity of infarcted

lung is sufficient, death must result from disturbance of respiratory function. The bigger the obstructed artery or the larger the number of smaller obstructed arteries, the greater is the effect upon respiration, and so it happens that when multiple emboli occur successively, even without parenchymatous changes in the lungs, death must eventually ensue from respiratory insufficiency.

Anningson[1] claimed that in the pulmonary artery the clots are most commonly found at the point where it breaks up into its branches.

Mann[19] states that deaths due to pulmonary embolism should be divided into three groups: (1) Immediate death occurring when only a small portion of the pulmonary circulation is obstructed: (2) death caused within a few minutes and due to complete or almost complete blocking of the pulmonary circulation; (3) delayed death, the result of an increase, by thrombosis, of an initial blockage by an embolism of a portion of the pulmonary circulation.

Experimentally, it was impossible to produce death or seriously imperil the life of the animal by emboli until the pulmonary circulation was greatly obstructed.

There is a wide difference of opinion regarding the frequency with which pulmonary thrombosis occurs primarily or is due to an embolus.

Virchow[29] divided obstruction of the pulmonary artery into four groups:

1. Following compression of a branch of a pulmonary artery, coagulation of the blood may occur.

2. The introduction of a deleterious substance sets up an inflammation, and this causes coagulation of the blood.

3. Spontaneous coagulation of blood from causes within the blood itself.

4. Obstruction occurs through a more or less compact mass which is carried into the pulmonary vessels and becomes lodged in them.

The majority of plugs in the trunk or main divisions of the

pulmonary artery found in cases of sudden death present the anatomical characters of emboli, associated perhaps with secondary thrombi; but there remain a certain number of cases of sudden or gradual death from primary thrombosis of the pulmonary artery or from thrombosis extending into a main division from the embolus in a smaller branch.

Welch[32] showed that embolism of medium sized and small branches of the pulmonary artery in normal lungs, without serious impairment of the pulmonary circulation, usually causes no symptoms and no changes in the parenchyma of the lungs.

Virchow[29] pointed out that emboli fill the pulmonary arteries without adhering to the walls when they are young, while the vessel walls show no changes, but when the emboli are old they cling to the wall which shows inflammatory changes.

Emboli usually stop at the bifurcation of a large artery, usually the vessels of the second and third order (Paget). Before and behind these fresh blood coagulation may occur.

Welch[32] showed that an embolus is the starting-point of a secondary thrombosis which usually, although not always, completes the closure of the vessel, if this was not affected by the embolus itself, and extends on each side to the nearest branch.

Humphrey[1] said thrombosis occurred most commonly at the junction of the profunda and saphena veins with the femoral. The presence of valves at the meeting-point of two veins helps to bring about the condition.

Anningson[1] thought that inflammation might follow the clotting, but was not the cause of it.

Clots may be absorbed leaving the veins as normal as before.

Glynn[14] believed that emboli in the pulmonary artery may be distinguished from primary thrombi by the fact that the former are coiled or fractured or riding astride of a bifurcating vessel.

Fowler and Godley held that embolism is commoner than thrombosis (pulmonary), but spontaneous thrombosis does occur. West considers spontaneous thrombosis exceedingly rare.

Welch[32] believes in the usually accepted opinion that the majority of plugs found in the pulmonary artery and its main divisions in cases of sudden death are emboli.

Recently, Mery[14] in France, and Newton Pitt, in this country, have maintained that spontaneous thrombosis is not infrequent—that in fact it may be commoner than embolism.

Box,[5] after making careful autopsies of several cases of so-called pulmonary embolism, came to the conclusion that these cases are a combination of thrombosis with embolism. He considers that a clot first forms in the pulmonary artery or in the right side of the heart, and some sudden movement causes detachments of this clot which enters and completely plugs one or both pulmonary arteries.

He explains that a clot forming in the pulmonary artery or right ventricle very soon after the operation may become absorbed without producing symptoms, but it may increase in size, become detached and then plug the pulmonary artery.

Wilson[23] thinks it is probable that obstruction of the pulmonary artery sometimes occurs without proving fatal.

According to Foulkrod[13] embolism of the pulmonary artery is invariably fatal. When involving the small bloodvessels in the lungs it may produce atalectasis, infarct, abscess or gangrene, and the patient may recover.

Welch[32] states that asphyxia, cerebral anemia, or interference with the coronary circulation are the factors concerned, but the exact apportionment to each of its due share in the result is not easy nor very important.

Dr. William Zahn[35] made a very extensive study of the formation of thrombi. His work will always stand out as a classic upon this subject and should be studied in detail in considering this subject.

Incidence. In McLean's[20] experience emboli and embolic abscesses follow 2.2 per cent. of all laparotomies.

Ritzman[24] reported 55 cases in 6000 autopsies. All patients were over thirty years of age and most were between 50 and 70. There were as many females as males.

Bang[3] reported 88 cases of embolism, one-half of which occurred in persons between twenty to thirty-nine years of age.

In Lichtenberg's[32] collection of 23,680 operations, including

16,000 laparotomies, there were 2 per cent. of pulmonary complications and among the laparotomies 5.5 per cent.

Among 1000 operations on the vermiform appendix Muhsam[32] reported 31 cases, 5 of which were fatal.

Mauchaire[32] has collected 50 cases after the radical cure of inguinal hernia, 12 out of 25 fully reported being fatal.

The prognosis of postoperative pulmonary embolism is extremely grave in 233 cases collected by Lenormant; death occurred in 106 or 45.5 per cent.

The order of frequency in which emboli are found in the different arteries may be given as follows: Pulmonary, renal, splenic, cerebral, iliac and lower extremities, axillary and upper extremities, celiac axis with its hepatic and gastric branches, central artery of the retina, superior mesenterics, inferior mesenterics, abdominal aorta, coronary and the heart.

Lotheisen[18] collected 66 cases of pulmonary embolism of which 55 were fatal:

1. Following fractures, 36 cases; 30 fatal.
2. Contusion, 6 cases; 5 fatal.
3. Tendon and muscle lacerations, 4 cases; 4 fatal.
4. Following operations, 20 cases; 16 fatal.

Of Lotheisen's 66 cases only 6 were under thirty years, the majority being over forty. Of his 66 cases 41 were males, 22 females and 3 unspecified.

Bang[3] found 10 cases of embolus in 600 autopsies, 1.66 per cent.

According to Wilson,[33] in operations on bloodvessels, alimentary canal, and genito-urinary organs from 1.5 to 2 per cent. of all cases give more or less distinct evidence of emboli, about 7 per cent. of which are in the lungs.

About 10 per cent. of postoperative emboli which give clinical symptoms cause death.

Foulkrod[13] found 37 cases of proved or suspected pulmonary embolism, according to his observations. Thrombosis and embolism (not confined to pulmonary) occur in from 1 to 3 per cent. of cases, including both postoperative and obstetric.

Obstruction of the pulmonary circulation alone occurs in a very much smaller percentage of cases.

Beckman, quoted by Van Sweringen,[28] reports 6 cases of pulmonary embolism occurring at Rochester in the first eight months of 1910 out of 4530 consecutive cases operated upon.

Kelly and Cullen report four deaths from pulmonary embolism out of 901 hysterectomies.

Howard showed that venous thrombosis occurred 34 times in 3774 patients with appendicitis and that a little less than one-eighth of these were cases of pulmonary embolism.

Albanus found that pulmonary embolism followed in 2 per cent. of abdominal operations.

Burkhard gives in 236 operations for uterine fibroids 12 cases of embolism (Keen's *Surgery*).

In Bidwell's[5] practice pulmonary embolism or thrombosis has occurred in 0.5 per cent. of abdominal operations.

The risk of pulmonary thrombosis after an appendectomy in the quiet stage is not merely a nominal one, since 3 such cases occurred in Bidwell's practice and represent a mortality of nearly 1 per cent. after operation, the death-rate from other causes being only 0.4 per cent.

Out of 700 obstetrical cases, Church[8] saw only 1 case of pulmonary embolism.

These cases are evenly divided between primiparæ and multiparæ.

Playfair[23] states that as far as present statistics go thrombosis and embolism seem more common in primiparæ than multiparæ.

Lotheisen[18] states that emboli occur, as a rule, in adults. Only 1 case of a child with pulmonary embolism could be found in the literature—a year-and-a-half-old boy with diphtheria and pneumonia.

Bidwell[5] thinks that pulmonary embolism after abdominal operations may be more frequent than is generally supposed and that its apparent rarity may be due to the surgeon's natural dislike to attract attention to his fatal cases.

McLean's[20] studies and observations have convinced him that

a far greater percentage of postoperative ailments than we are accustomed to attribute to embolism really owe their origin to that cause.

Etiology of Thrombosis. 1. Welch[32] states that slowing and other irregularities of circulation in combination with lesions of cardiac or vascular wall, or with the presence of micro-organisms or other changes in the blood, are important predisposing causes of thrombosis and frequently determine the localization of the thrombus.

2. Changes which impair or destroy the smooth surface of the normal inner lining of the vessel play an important part in the etiology of thrombosis (inflammation, atheroma, calcification, necrosis, other degenerations, tumors, compression and injury).

3. Infective thrombi. Thrombophlebitis develops during the progress of pneumonia, typhus, acute rheumatism, erysipelas, cholera, scarlatina, variola, tuberculosis, syphilis and nearly all acute and chronic infections. Likewise in chlorosis, gout, leukemia, senile debility, and chronic wasting and cachectic diseases, particularly in cancer, thrombosis is a recognized complication.

4. Chemical changes in the blood, ferment thrombi. Alteration in the formed elements of the blood caused directly or indirectly by toxic substances are of great significance in the etiology of pulmonary thrombosis.

(*a*) Increase of blood platelets. There is a parallelism between the disposition to thrombosis and the number of platelets in certain diseases.

(*b*) Calcium content is an important factor in coagulation of blood.

As factors in the causation of thrombosis Lotheisen[18] considers

1. A change in the blood constituents.
   - (*a*) Anemia (puerperal hemorrhage or uterine hemorrhage due to myoma uteri).
   - (*b*) Gestation (physiological changes in blood and leukocytosis).

(*c*) Chlorosis.
(*d*) Prolonged fevers, malaria, cholera.
(*e*) Elephantiasis (Fayrer, 3 cases).
(*f*) Cachexia—malignant tumors.

2. Slowing of blood stream.
   (*a*) Weak heart.
   (*b*) Fatty degeneration—pregnancy.
   (*c*) Pregnancy—gravid uterus pressing on veins.
3. Change in the vessel wall.
   (*a*) Phlebitis.
   (*b*) Trauma.
   (*c*) Atheroma.

Wilson[33] states that the most important factors concerned in extensive postoperative thrombosis are:

(*a*) Injury of vascular walls.
(*b*) Slowing and stagnation of blood stream.
(*c*) Disintegration of the corpuscles of the blood from toxic substances.
(*d*) Bacteremia.

Foulkrod[13] enumerates as pathological conditions influencing coagulation the following: Preëxisting thrombosis, toxemia or infections; under this heading he includes infections of the endometrium and broad ligament veins and particularly bronchial infections, profound mental depression, placenta previa or other conditions producing excessive hemorrhage, mechanical pressure from the weight of the uterus and slowing of the heart action.

Playfair[23] believes, further, that thrombosis of the heart and pulmonary artery are sometimes due to dysentery, typhus and typhoid fever and may also cause death by thrombosis of the pulmonary artery.

According to Ritzman's[24] observations the causes were various, vitium cordis, myodegeneration, arteriosclerosis, anemia and cachexia, conditions causing phlebitis, injuries and operations. Nearly all the affections were related to vascular disease of some sort.

Church[8] claims that thrombosis is induced in the puerperal state, rheumatism, fevers and other blood dyscrasiæ such as erysipelas, diphtheria, pneumonia—increase of fibrin in the blood one-third.

Bidwell[5] says pulmonary embolism is unpreventable, since the active cause as well as the means of prevention are not known.

It is the opinion of Bidwell that thrombosis only occurs in consequence of changes in the bloodvessels, the blood or both. A thrombosis, of course, is formed by the development of fibrin; but fibrin does not exist in healthy blood but is produced by the action of fibrin ferment on fibrinogen. Fibrin ferment does not exist in the blood but is the result of a combination of calcium salts with nucleoproteid. Calcium salts are normal constituents of the blood, but nucleoproteid is not, and it is probably produced by degeneration of leukocytes and of blood-platelets. In normal circumstances a considerable quantity of nucleoproteid can be disposed of in the circulation, probably by the action of the endothelial lining of the bloodvessels; this power is, however, diminished by injury, by inflammation, and by retarding of the blood stream.

Therefore, thrombosis forms when the walls of the bloodvessels have been injured; also in cases of sepsis; by increase of CO_2 in the blood; by general conditions, such as chlorosis and anemia; and lastly by specific fevers, more especially typhoid.

Bland Sutton[6] in his *Hunterian Lecture* is convinced that the formation of thrombi in the great veins after pelvic operations is due in all cases to sepsis.

Faure[11] describes 2 fatal cases occurring within a few days operated between February 12 to 24, 1919, during the influenza epidemic after the clinic had been free from such fatalities for many months, thus attributing these cases to influenza infection. At the same time there were three additional cases of phlebitis and numerous cases of wound infection during this period, while the clinic had been free from all of these complications for months before.

McLean[20] has shown how, except in the presence of an infection, it was impossible to produce experimentally a thrombus and a resulting embolus, and for this reason claims that a perfectly aseptic operation is rarely followed by an embolic process.

He insists that endothelial damage, on which so much stress is generally laid, is not, *per se*, a cause of thrombosis. Infection and necrosis (or the toxins derived from an infectious and necrotic process) are probably the most important factors in thrombus production. A slowing of the blood stream is a contributory cause, but of itself will not cause a thrombus to form.

Fromme[12] introduced a silk thread into the jugular vein of rabbits. A sterile thread produced a thrombosis only in anemic animals or in those in bad physical conditions, while the thread impregnated with any form of bacteria regularly produced thrombi.

Talke[25] said he had placed cultures of staphylococci near 13 arteries and 31 veins in 13 animals, and he removed these after nine to twelve hours. Twenty-two veins and 11 arteries were thrombosed. The vessel wall and the surrounding tissues showed typical inflammation, but the thrombosis occurred before the microörganisms had entered the lumen of the vessel, hence seemed to be caused by the toxins.

Bidwell[5] quotes some surgeons who assert that all cases of thrombosis are really septic in origin, but states that it is difficult to agree with this statement, since it occurs in aseptic cases and in such a case as a gastric ulcer.

Libanoff[7] explained the formation of thrombokinase in large hematomata leading to the danger of local or distant thrombosis, and pointed out the necessity of evacuating these to avoid their absorption. Commenting on this Murphy asks, "Why has one clinic so many cases of thrombosis and embolism and the other clinic so few?" May it not be due to imperfect hemostasis by one operator and the perfect capillary hemostasis of the other? In the first instance large hematomata form and the latter give up the thrombokinase and thrombosis follows; while in the other no hematomata form and consequently no thrombokinase

is given out and therefore no activating of thrombogen occurs with the calcium salts to form a thrombus.

Volker[30] said he was surprised to find in necropsies on animals dead of embolism that there was invariably some brownish liquid blood in small quantities at the bottom of the wound, and it occurred to him that there might be some relation between the debris of these small hematomata and fatal embolism. He believed the debris from the hematomata should be looked upon as the cause of embolism.

Dr. Joseph Price, quoted by Volker,[30] called attention to the dangers of these small "blood pools" in the pelvis following operations as early as 1893, and placed great stress upon the danger from them and the importance of leaving the field of operation perfectly dry.

After delivery the blood dyscrasia is increased by the absorption of effete matter in the process of uterine involution. Severe hemorrhage and syncope, with slowing of the blood stream, increase the tendency to coagulation. Plugs normally found in natural labor in the open orifices of the uterine sinuses after separation of the placenta may find their way into the systemic circulation.

Zurheile[36] claims that retardation of blood stream is the main factor in the production of a thrombosis, so that the blood plates pile up mechanically in the more sluggish blood. His experiments show the uselessness of striving to prevent thrombosis by reducing the coagulating property of the blood; as we are unable to act on the blood-plates, all we can do is to prevent the blood stream from becoming sluggish.

Aschoff[2] suggests that it may be possible to prevent thrombosis by changing the physical condition in the circulation, combating any tendency to slower pulse-rate. He does not think that thrombosis is always of infectious origin, but a superimposed infection transforms a primary insignificant thrombosis into a dangerous thrombophlebitis. He supports the theory advanced by Virchow that the slowing up of the stream is the principal factor in the development of thrombi.

All cases observed by Glynn[14] of pulmonary thrombosis had been bedridden, and passive congestion of the lungs may have been a predisposing cause to thrombosis. It is also a fact that 9 cases had been anesthetized.

Bardeleben[4] showed that streptococci introduced into the blood stream produce a thrombosis only if the stream is slowed down, otherwise non-virulent varieties are destroyed while virulent varieties produce severe bacteremia if highly virulent streptococci become lodged upon the vessel wall.

Bidwell[5] points out the fact that when thrombosis attacks a femoral vein, the left is most usually affected, and this is explained by the course of the left iliac vein being less direct than that of the right and also by the fact that the flow of blood through it is likely to be retarded by the pressure of the loaded sigmoid.

Playfair[23] believes that central thrombosis (cardiac and pulmonary) should be looked upon as a complication which is liable to attend the performance of surgical operations in general, but more especially those done on cachectic subjects or those involving much shock or hemorrhage.

He also states that both thrombosis and embolism are much more common in patients who are anemic and weak either from hemorrhage or other cause.

Duncan[5] argues that it is due to anemia which so frequently affects women suffering from uterine fibroids and supports his view by quoting a case of a woman with fibroids dying from pulmonary embolism while in the hospital awaiting operation.

Clark, quoted by Van Sweringen,[28] believes that thrombosis in non-septic epigastric veins is due to propagating thrombus of the deep epigastric veins originally produced by the traumatism resulting from operative manipulations, and especially the use of heavy retractors.

Others maintain that postoperative thrombosis is caused by the pressure of retractors on the edges of the abdominal wound causing injury to the deep epigastric veins; the thrombus forms first at the seat of injury and afterward spreads down to or around to the femoral vein.

It is generally supposed that patients suffering from uterine fibroids are peculiarly liable to thrombosis and embolism; this is explained by the increase of calcium salts in the blood, as shown by the tendency to calcareous degeneration of the fibromata and (2) by some degeneration and weakening of the cardiac muscle fiber which is commonly associated with the condition, and according to several authors to the fact that the stump left after the removal of the uterus has not been carefully covered with peritoneum after accomplishing perfect hemostasis, thus favoring infection.

Anningson[1] thought it possible that the tendency to coagulation during the puerperal state and in pneumonia, erysipelas, etc., was due to excess of white corpuscles in these conditions.

Virchow[29] believed that the fibrin clots or pulmonary emboli were secondary to thrombosis elsewhere. This thrombosis occurs in the veins or right heart and is carried to the pulmonary arteries by the blood stream.

To substantiate this he reports that out of 76 sections performed in August in the morgue of the Berlin Charities he encountered 18 venous thromboses and 6 lung or pulmonary thromboses.

Obstruction may or may not cause change in the parenchyma.

When the blood in one vein clots, the coagulum extends beyond the mouth of the next vein, so that as the blood from this vein passes by, small pieces of coagulum can easily be detached. Virchow has been able to match the edge of pulmonary emboli with those of the venous thrombi from which they originated.

Wilson[33] states 80 per cent. of emboli have their source in venous thrombosis, 10 per cent. are cardiac and 10 per cent. scattered and undeterminable. Long, loosely formed thrombi from medium-sized veins are those chiefly concerned in embolism. When large, loose thrombi are formed in resting patients, any unusual exertion or change of position may cause a dislocation of large masses which become dangerous emboli.

Church,[8] quoting Playfair in his *Science and Practice of Midwifery*, says: "I have shown from a careful analysis of 25 cases

of sudden death after delivery, in which accurate postmortem examination has been made, that the cases of spontaneous thrombosis and embolism depend upon the period after delivery at which the fatal result occurs. In 7 out of these cases there was distinct evidences of embolism, and in them death occurred at a remote period after delivery, in none before the nineteenth day. This contrasts remarkably with the cases in which postmortem examinations afforded no evidence of embolism. These amounted to 15 out of 25; in all of them with one exception death occurred before the fourteenth and often on the second or third day. The reason for this seems to be that in the former, time is required to admit of degenerative changes taking place in the deposited fibrin, leading to separation of an embolus; while in the latter, the thrombosis corresponds in time and to a great extent no doubt also in cause to the original thrombosis from which in the former the embolus was derived. Many cases I have since collected illustrate the same rule in a very curious and instructive way."

Playfair[23] expressed the following opinion:

1. Obstruction of the pulmonary artery after delivery may depend upon either embolism or spontaneous thrombosis.

2. The former usually occurs at a much later period after delivery than the latter, and spontaneous thrombosis probably corresponds with and is due to some cause similar in its nature to that which produces the obstruction of the peripheral veins in true cases of embolism.

Church[8] states that thrombosis may occur simultaneously at the periphery (veins) and center (heart and lungs) of the blood stream. W. J. Playfair cites cases of pulmonary obstruction that have not proved fatal immediately, and in which shortly afterward phlegmasia dolens commenced, showing thereby that coagulum was first found in the center and then at the periphery.

"Thrombosis rarely occurs until one week after an operation; from the tenth to the fourteenth day is the usual time, but sometimes it is as late as one month. Recovery is generally

complete in two or three weeks. As a rule these cases do not suffer from pulmonary complications, and in those rare cases in which sudden death does occur after a femoral thrombosis it is probable that a thrombosis coexisted in the pulmonary artery."

ETIOLOGY. (*b*) Embolism. Lotheisen[18] makes the following observations: Most emboli originate from the veins of the lower extremity. In his 66 cases 40 originated there.

Following parturition or gynecological operations emboli have originated from thrombosis of veins about the uterus.

The hemorrhoidal plexus has also been indicted several times.

Bumm describes 2 cases following operation on the rectovaginal septum.

Embolism usually occurs after a previous period of rest in bed followed by sitting up, straining at stool or muscular effort, manipulation or massage of the leg, rubbing in ointment, or even the application of a bandage or zinc gelatin boot. (Velpeau.)

Wyder[34] saw pulmonary embolism following colpoperineal plastic.

SYMPTOMATOLOGY. (*a*) *Thrombosis.* Pain, swelling, masses in superficial veins (or deep veins).

(*b*) *Embolism.* Sudden pulse rise with normal temperature in thrombosis, later a temperature rise with embolism. After this the temperature may descend while the pulse remains elevated. (Mahler.[34])

Welch[32] gives one of the clearest descriptions of symptoms. Death may be instantaneous from syncope. More frequently the patient cries out, is seized with extreme precordial distress and violent suffocation and dies in a few seconds or minutes. Or when there is still some passage for the blood, the symptoms may be prolonged for several hours or even days before the fatal termination. The symptoms of large pulmonary embolism are the sudden appearance of a painful sense of oppression in the chest, rapid respiration, intense dyspnea, pallor followed by cyanosis, turgidity of the cervical veins, exophthalmos, dilatation of the pupils, tumultuous or weak and irregular heart action, small empty radial pulse, great restlessness, cold sweat, chills,

syncope, opisthotonos and convulsions. The intelligence may be preserved or there may be delirium, coma and other cerebral symptoms. Particularly striking is the contrast between the violence of the dyspnea and the freedom with which the air enters the lungs, and the absence of pulmonary physical signs, unless in the more prolonged cases it be the sign of edema of the lungs.

Wyder[34] enumerates the symptoms of pulmonary embolism as follows:

1. Dyspnea (cardiac apnea).
2. Anxiety.
3. Cyanosis.
4. Dilated pupils.
5. Powerful heaving of heart and irregularity.
6. Pulse imperceptible.
7. Death following syncope.

Auscultation during pulmonary embolism reveals often a blowing murmur during systole or systole and diastole at the base. Henning heard this in 4 cases out of 33.

In the author's 66 cases it was reported 3 times. Pain in the region of the scapula or in the right or left hypochondrium. Consciousness is usually retained to the last. Rarely delirium, syncope or convulsions occur. Sense of coldness complained of; they frequently shiver.

Regarding the diagnosis, Meyer[20] considers next to the clearly demonstrable enlargement of the right heart the accentuation of the second pulmonary sound of importance.

Differential Diagnosis. Wyder[34] states that atheróma of coronary arteries gives a similar picture. These patients usually give a history of previous similar attacks.

Schumacher[20] calls attention to the fact that the diagnosis of pulmonary embolism may be difficult because a suddenly occurring internal hemorrhage, also myodegeneration of the heart can produce like symptoms.

Treatment. (*a*) *Prophylactic.* Many suggestions have been made in the direction of prophylactic treatment, of which the following are the most important.

Wyder[34] lays down the following rules:

(*a*) In chlorosis give iron.

(*b*) In cases of pregnancy avoid operation in the neighborhood of the uterus, anus and vulva if possible. Such operations may cause miscarriage, which aids in liberation of emboli.

(*c*) In cases of operation avoid hematomata, because thrombosis is readily set up in the adjoining veins.

(*d*) In cases of venous stasis in the lower extremities, elastic bandages and massage are recommended to avoid thrombosis. If thrombosis is suspected, however, these should not be employed (v. Jurgensen). The authors condemn massage in all cases for fear of liberating emboli. For the same reason Puternan goes so far as to avoid massage in all cases of fracture until three weeks after injury.

(*e*) In cases of thrombosis all movements should be avoided. patients should not sit up in bed. Straining at stool should be avoided by the use of proper cathartics.

(*f*) Elevation of the leg has no value. [?]

(*g*) Cold compresses changed every hour or two and laid on the anterior surface of the leg so as not to make necessary the elevation of the leg are advised.

Rest in bed is mandatory as long as symptoms of thrombosis or capillary thrombi are present. Even after the swelling has disappeared the patient should remain in bed for several days.

Talley recommends as a prophylactic measure that good contraction of the uterus should be sought after labor.

In endocarditis undue muscular effort, including straining at stool and severe coughing, should be avoided.

Thane[27] suggests the undesirability of prolonged use of Trendelenburg position, as it may predispose to pulmonary embolism.

Ward[31] speaks of the abandonment of extensive exposure of the levator ani muscle during perineoplasty, to prevent bruising of the numerous small veins exposed.

The length of time that a limb should be kept immobilized should be gauged by the disappearance of swelling, tenderness and fever, which often takes one or two months. The return to normal activity should be by easy stages.

Grober[15] advises, when possible, the excision of the original site of thrombosis.

When thrombo-embolism occurs, keep the patient absolutely at rest in bed and give morphin for distress.

Welch[32] advises the following points in the treatment of thrombosis:

(*a*) Prophylactic measures should be directed toward maintaining good nutrition, strengthening the heart's action and warding off secondary infection.

(*b*) He mentions the use of citrated milk, 20 to 40 grains of citrate to the pint in diseases conducive to thrombosis.

(*c*) Absolute rest, suitable position and immobilization of the thrombosed extremity, and nourishing diet to ward off embolism.

Caution the patient against moving the leg; palpation of the affected limb should be of the gentlest sort, and is better omitted altogether. The patient should not be allowed to walk in less than forty days. After the danger of embolism is passed, massage and bandaging may be employed to advantage.

Wilson[33] enumerates the following precautionary measures:

(*a*) Reduction of vascular traumatism to minimum at operation.

(*b*) The encouragement of very early free movement on the part of the patient.

(*c*) The postoperative administration of drugs to increase the coagulability of the blood is of questionable value as far as thrombosis and embolism are concerned.

(*d*) Measures leading toward the reduction of bacteremia. Eliminate foci of infection, treat with vaccine, etc.

Bidwell[5] insists that methods of prevention are of more importance than methods of treatment, and these include the treatment of anemia before operation, giving excess of fluids, the use of citrates and getting the patient up as soon as possible after operation. At the same time lime salts, magnesium carbonate and milk should be avoided.

He states that the tendency to coagulation is decreased by oxygen, by improving the force of the circulation, by alcohol,

by excess fluids and reduction of solids, by citric acid, rhubarb, acid fruits and wines and by tobacco.

Wyder[34] considers the most important prophylactic measures to recognize the presence of thrombosis and avoid everything which may loosen emboli.

Thorough blood study in cases of anemia he advises, to postpone operation until this is relieved. Administer iron in these cases.

To prevent femoral thrombosis after an operation, Bidwell[5] believes that we should avoid the risk of injury to the edges of the wound by placing gauze pads beneath our retractors and by using them as gently as possible; we should avoid an exclusive milk diet; we should keep the lower bowel unloaded, so as to minimize the interference with the blood stream through the common iliac vein by pressure from the sigmoid; we should give excess of fluids especially by the rectum, and we should avoid calcium salts and carbonate of magnesia. The patient should have plenty of fresh air and should be given citrates if milk is allowed.

Th. Kocher agreed with Volker[30] and went still further, saying that he sought for locations where there may have been old thrombi, *e. g.*, in the varices of the leg. He thinks it clearly indicated to cure such varices before subjecting the patient to major operations, during which they may succumb to embolism. For this purpose he makes use of ligatures of the large saphenous by Trendelenburg's method followed by multiple intermediate ligations of the varices.

Playfair[23] agrees that the main element in the treatment of such cases is the most rigid rest and a nourishing supporting regimen.

Paul Zweifel[37] reports 18 pulmonary thrombosis deaths in 1832 cases operated upon a table interfering with the veins of the lower extremities and only 3 in 860 cases operated upon a table which did not have this feature. In the former series the deaths from this cause amounted to 1 in 100, in the latter series 1 in 286.

He advises the following precaution, which, according to his enormous clinical experience, will greatly reduce the occurrence of pulmonary thrombosis: Avoid all pressure upon the veins of the lower extremities, such as occurs from permitting the legs to hang over the lower end of the table in operations in the Trendelenburg position.

He gives further statistics, according to which he lost 5 cases from thrombosis in 450 abdominal sections; 3 in operations for uterine fibroids, 1 for carcinoma of the uterus and 1 for extirpation of a cyst in a patient seventy-five years of age. Following this high mortality, notwithstanding the fact that the extremities were not traumatized during the operation, a change in his technic was followed by only 5 deaths from thrombosis in 2060 laparotomies and only 1 in 484 operations for uterine fibroids, and this in a patient who had suffered eight weeks previously from a cerebral embolus. All the 5 deaths mentioned occurred in decrepit, anemic or cachectic patients.

The change in technic consisted in the absolute control of oozing of blood and in applying a purse-string suture covering absolutely all raw surfaces in the pelvis.

R. Olshausen[22] attributed the frequent occurrence of pulmonary thrombosis to the use of an operation table which caused the knees to be flexed in placing patients in the Trendelenburg position, causing a compression of the veins of the lower extremities. 2443 with 14 pulmonary thromboses; of these there were 571 uterine fibroids with 7 thromboses. Following these cases he reported fibroids with no thromboses in cases operated on a table without compression of the veins of the legs.

TREATMENT. (*b*) *Therapeutic*. According to Wyder,[34] upon the occurrence of pulmonary embolism rapid therapeutic measures are necessary:

1. Subcutaneous injections of ether and camphor in oil. Von Kenezy gave ether injections hourly for two days and claims that the patient felt definite alleviation after each. Oeder gave 0.2 gm. camphor every five minutes or 2.4 gm. in one hour, and claims a recovery with this. Caffein and digitalis may be used intravenously.

2. Morphin, 0.02 gm. used by most clinicians counteracts shock, and if death supervenes, makes this less painful.

After infarction, combat dyspnea and distress with opiates.

Lead acetate may be administered. He does not hold artificial respiration useful because death does not occur from respiratory obstruction but rather lack of oxygen in the blood.

Bidwell[5] states, with regard to treatment, while he recognizes that little can be done when the whole of the right pulmonary artery is blocked, oxygen, strychnin and saline injections are always given, and in 1 case life was prolonged fifteen hours.

Church[8] urges the use of oxygen gas inhalation for these patients on the basis of its demonstrated value in the treatment of pneumonia.

Meyer[20a] describes the removal of pulmonary emboli by Trendelenburg's operation in detail. Trendelenburg performed 12 operations of this kind on man without a permanent recovery.

He states that the coagulation of blood and recurrence of embolic accident can be avoided by injection of hirudin.

He distinguishes three classes of pulmonary embolism:

1. The one causing immediate exitus which evidently is due to shock, as not infrequently only a partial thrombosis of the artery may be found at autopsy.

2. The one causing death within a few minutes. Here thrombosis is perfect, separating pulmonary and greater circulation. The right heart becomes quickly overdistended.

3. The one of protracted course which is more frequently observed. Here one of the main branches of the artery and subdivisions become suddenly clogged, only gradually total obstruction sets in.

As a matter of fact only the third category will furnish cases with indication for operation and the task of establishing this indication is rendered difficult on account of the experience that some of these patients get better under conservative treatment. He considers operation imperative if medical treatment fails to bring improvement.

Four times this operation was performed at the Zurich Clinic, but the patients could not be saved.

We have reviewed the histories of all cases of death due to pulmonary thrombosis which occurred during the past five years in the Augustana Hospital following surgical operations, including the years 1915 to 1919, 8 cases. These are represented in the accompanying table. Of these 4 cases occurred

	Operations.	Obstetric deliveries.	Laparotomies.	Hysterectomies.
1915	3,665	153	1204	94
1916	3,510	187	1218	88
1917	3,303	211	927	133
1918	3,303	278	871	107
1919	2,915	270	1055	106
	16,696	1099	5275	528

7 deaths in 16,696 operations = 1 case in 2385 = 0.042 per cent.
1 death in 1,099 obstet. cases = 1 case in 1099 = 0.1 per cent.
5 deaths in 5,275 laparotomies = 1 case in 1055 = 0.1 per cent.
1 death in 528 hysterectomies = 1 case in 528 = 0.18 per cent.

in my own service (Ochsner), 3 in the service of my colleague, Dr. N. M.Percy, and 1 in the obstetrical service in a patient in whom a very extensive perineal laceration had to be repaired immediately following delivery. It is likely that the thrombosis in the obstetrical case had no relation to the operation, because deaths from this cause have occurred many times after delivery of cases in which no surgical repair was made, but in order to make our statistics complete the case had to be included.

During this period of five years we performed 16,696 operations, all in the Augustana Hospital, with 5275 laparotomies, and of these 528 were hysterectomies, which in all other statistics we have encountered showed the largest percentage of deaths from pulmonary thrombosis.

During the same period 76 cases of so-called pernicious anemia were operated for splenectomy, cholecystectomy and appendectomy in patients who, according to all statistics, should have resulted in a considerable number of deaths from pulmonary thrombosis. Among these cases, most of which were operated by my colleague, Dr. N. M. Percy, there occurred no deaths from pulmonary thrombosis.

THE FOLLOWING TABLE CONTAINS ALL DEATHS FROM PULMONARY THROMBOSIS OCCURRING IN OUR CLINIC AT THE AUGUSTANA HOSPITAL DURING THE FIVE YEARS FROM 1915 TO 1919

	Date.	No.	Sex.	Age.	Diagnosis.	Operation.	Operator.	Postoperative days.	Predisposing cause of embolism.
1	July 15, 1915	43793	M.	42	Osteochondroma of left ilium	Excision of osteochondroma	A. J. O.	4	Phlebitis.
2	Sept. 4, 1915	44273	M.	46	Gastric ulcer; cholecystitis, chronic appendicitis	Posterior gastroenterostomy; cholecystectomy; appendectomy	N. M. P.	6	Perforated ulcer with preoperative loss of weight.
3	April 13, 1916	46790	F.	33	Cholecystitis, retroversion; rectocele	Cholecystectomy, perineorrhaphy	N. M. P.	2	
4	July 7, 1916	47388	F.	44	Carcinoma of rectum	Colostomy	A. J. O.	3	
5	May 21, 1917	50718	M.	65	Hypertrophied prostate	Suprapubic prostatectomy	N. M. P.	15	Cachexia; phlebitis of left leg.
6	June 12, 1917	50802	F.	33	Gestation; 3d degree laceration of perineum	Parturition, perineorrhaphy	R. H.	14	Perineal sepsis.
7	April 28, 1918	54315	F.	51	Cholelithiasis; carcinoma of uterus	Cholecystectomy, panhysterectomy	A. J. O.	7	Anemia; cachexia.
8	Dec. 16, 1918	56932	F.	43	Floating kidney; cholelithiasis; appendicitis	Nephropexy; cholecystostomy; appendectomy	A. J. O.	12	Preoperative loss of weight 35 pounds.

In every case, however, the operation had been preceded by one or more transfusions of whole blood without the addition of citrate of soda.

Recognizing the etiological importance of the twelve conditions mentioned at the beginning of this paper, whose validity seems to have been established by many authorities noted for their keenness of observation, it would seem worth while to investigate whether death from pulmonary thrombosis could have been avoided in any or all of these cases had every possible precaution been taken to eliminate each one of these etiological factors to the greatest possible extent.

Local Infection. 1. It seems certain that even the slightest amount of local infection may cause a thrombosis in a neighboring vein which may be loosened and serve as the cause of a fatal pulmonary thrombosis when it becomes lodged in the pulmonary vein. Although there is no evidence in any one of our cases that this has actually occurred, still it seems important to still further perfect aseptic methods of operation. Of course, hemostasis must be accomplished as a result of a normal thrombosis of the ends of the cut vessels, but it does not seem likely that such a thrombus will ever become loosened if absolutely aseptic, so that it can cause death due to pulmonary thrombosis.

2. Anemia. Most of the patients, especially Cases 2, 5 and 7, showed some degrees of anemia. It seems likely that it might have been possible to correct this by more careful preliminary treatment or by transfusion of whole blood.

3. Slowing of the Blood Stream. It has been claimed that keeping patients for a long-continued operation in the Trendelenburg position would interfere with the blood stream in the extremities to such an extent that this serves as a predisposing cause. In none of our cases except Case 2 could this have been the cause, as none of the other operations were of long duration.

4. Subnormal General Physical Condition. This obtained in Cases 2, 7 and 8, but aside from the possible improvement which could have been secured by the preliminary transfusion of whole blood it is doubtful whether this cause could have been eliminated to a marked extent.

5. Cachexia. The only treatment which could be of any benefit would again be the transfusion of whole blood. Two of our own cases belonged to this group, and were similar cases to come under our care in the future, we should make use of prophylactic transfusion of whole blood.

6. Microörganisms in the Blood. None of our cases belong to this group, but we believe that in several cases of this class we have obtained great benefit by the transfusion of whole blood, although it is, of course, impossible to state that thrombosis has been prevented in any given case, although it failed to appear in any of the cases following transfusions.

7. Excess of White Blood Cells. This cause did not exist in any of our cases.

8. Inefficient Hemostasis. Until very recently we had not fully appreciated the importance of this etiological factor, and it is quite possible that some of our deaths may have been due to an error in this direction although fortunately our method of closing the stump in hysterectomy for many years has corresponded to that upon which Zweifel[37] lays so much stress, and it is possible that we may have escaped many deaths from pulmonary thrombosis in this class of cases without being entitled to any credit for this.

9. Traumatization of Tissues with Retractors, Etc. It seems likely that we have not exercised proper care in this direction, because until recently we have made use of heavy retractors for holding open the abdominal wound. These have now been discarded, and although we cannot trace any case directly to this cause, it seems likely that our technic has been bad in this direction.

10. Injury to Veins of Extremities Due to Badly Arranged Operating Table. Zweifel and others have traced a number of their deaths directly to the use of a table in which the knees are bent while the patient lies in the Trendelenburg position, so that the veins are compressed during the operation. They found a marked reduction of fatal cases upon abandoning this particular table. We have never used this type of table,

but it seems proper to again direct attention to this apparent cause.

11. Injury to Intima of Veins. Rough handling of tissue in the vicinity of the wound undoubtedly often causes an injury to the intima of veins, and it seems worth while to train one's self and one's assistants to avoid this as well as all other forms of unnecessary traumatization of tissues.

12. Excess of Calcium Salts in the Blood. So many authors mention this as an etiological factor that it may be important to consider it. So far we have paid no attention to this element.

It seems likely, from our observations, that in the future we will be justified in systematically adding the transfusion of 600 c.c. of whole blood to our preliminary treatment in a considerable proportion of cases belonging to a class which has in the past made up our list of deaths from pulmonary thrombosis and that the other precautions will be carried out with greater care.

It is likely that this will result in a considerable reduction in the death-rate from postoperative pulmonary thromboses.

It has been our practice for nearly twenty years to direct our operated patients to move about in bed, to change their position frequently and especially to move their arms and legs in order to stimulate circulation following operations. It is difficult to say whether this fact has had any influence in reducing the number of cases of pulmonary thrombosis in our clinic but it has seemed worth while to continue this plan of postoperative management.

A short analysis regarding the etiology of the thrombophlebitis as shown in our eight tabulated cases is as follows:

Case 1, a man, aged forty-three years, who had an enchondrosteoma, 21 x 11 x 7 cm., removed from the lateral surface of the left ilium. The wound was aseptic and there is nothing in the history which could serve as a predisposing factor except the fact that ten years previously the patient had suffered from thrombophlebitis of the veins in both legs and that the

venous circulation had been impaired ever since this occurrence. The wound was aseptic, but his thrombophlebitis must have lighted up again. Had this patient received careful preliminary treatment for several weeks it is quite likely that the thrombophlebitis might have been prevented.

Case 2, a man, aged forty-six years, giving a history of gastric ulcer complicated with cholecystitis and chronic appendicitis, had lost considerable in weight and was anemic as a result of loss of blood from his gastric ulcer. The gall-bladder was thick, universally adherent, sacculated and filled with black, viscid bile. The mucosa was granular. This gall-bladder was removed. The appendix was sacculated and universally adherent. In this case the patient died six days after the operation from pulmonary thrombosis. This patient had anemia and mild cachexia, also a great amount of disturbance because of the extensive operation and extensive adhesions. The operation lasted one hour and a half, consequently several factors were present which would account for the pulmonary thrombosis. A preliminary transfusion of whole blood, and performing the operation in two stages, a gastro-enterostomy at the first stage and a cholecystectomy and appendectomy after the patient had fully recovered from the first operation, would probably have prevented the unfavorable result.

Case 3, a woman, aged thirty-three years, showed nothing in her history which would predispose to the development of thrombophlebitis. She had a normal cholecystectomy for the relief of gall-stone disease, and perineorrhaphy was performed with an anterior suspension of the uterus. She died from pulmonary thrombosis two days following the operation. It seems likely that some of the veins in the vicinity of the broad ligaments or rectum must have been injured during the operation. The case emphasizes the importance of protecting the veins.

Case 4, a woman, aged forty-four years, with carcinoma of the rectum. This patient showed but very slight cachexia and was otherwise in fair condition. A simple colostomy was performed. The patient was under the influence of the anesthetic

less than half an hour, and there was nothing that one would reasonably expect to cause a thrombosis except that the mesentery of the sigmoid was transfixed and a strand of gauze and a glass tube were passed through to keep the intestine from slipping back into the abdominal cavity. Evidently a thrombus was loosened from one of these veins. Whether preliminary transfusion of whole blood might have prevented this it is difficult to say.

CASE 5, aged sixty-five years, had a simple suprapubic prostatectomy from which he made a very satisfactory recovery for fifteen days, when he died suddenly from pulmonary thrombosis. On the afternoon of the fourteenth day a phlebitis developed in the femoral vein, which undoubtedly accounts for the embolus which gave rise to pulmonary thrombosis.

CASE 6, aged thirty-three years, who suffered from a severe laceration of the perineum during delivery, which was repaired immediately, died fourteen days later from pulmonary thrombosis. In this case there was severe suppuration of the perineal wound. Whether the infection from this source was responsible for the pulmonary thrombosis or whether the latter condition resulted from a loosened thrombus from the uterus we have been unable to determine.

Case 7, aged fifty-one years, suffering from gall-stones and cancer of the uterus, with marked anemia and cachexia, died of pulmonary thrombosis seven days after the operation, which consisted of a cholecystectomy and panhysterectomy. In this patient the anemia should have been corrected by transfusion of whole blood, and panhysterectomy should have been performed at the first operation and cholecystectomy after the patient had regained strength.

Case 8, aged forty-three years, suffered from a floating kidney which could be moved over the greater portion of the abdominal cavity, from cholelithiasis and appendicitis. She had lost thirty-five pounds in weight previous to the operation. The operation performed consisted of cholecystostomy, appendectomy and suturing the kidney in place. The gall-bladder contaned a

large number of stones. In this case good judgment would undoubtedly have prevented the pulmonary thrombosis, because with the patient in this condition the appendix and gall-stones should have been removed first and the floating kidney sutured at a second operation.

Bibliography

1. Anningson: Lancet, London, 1881, i, 16.
2. Aschoff, L.: Med. Klin., November 7, 1909; Beiträge zur Thrombosenfr. 1912.
3. Bang: Afhandl. für Doktorgraden Kjobreharn, 1880.
4. Bardeleben: Arch. f. Gynec., 1907, lxxxiii, 36.
5. Bidwell: London Pract., 1909, lxxxii, 214–223.
6. Bland Sutton: Lancet, January 16, x, 1909.
7. Bumm: Centralblatt f. Gynec., 1894.
8. Church: Tr. Edinburgh Obst. Soc., 1891–2, xvii, 210–221.
9. Cohnheim and Litten: Arch. f. Anat., etc., Berlin, 1875, lxv, 99–115.
10. Cohnheim: Untersuchung über die Embolischen Processe, Berlin, 1872.
11. Faure, J.: Paris Médical, July 24, 1919.
12. Fromme: Physiol. u. Path. d. Wchnschr., Berlin, 1910, 168.
13. Foulkrod: Am. Jour. Obst., New York, 1911, lxxix, 855–857.
14. Glynn: Liverpool Med. Chir., Jour., xxvii, 204–218.
15. Grober: Deutsch med. Wchnschr., February 19, 1914.
16. Ledill: Am. Jour. Med. Sc., Philadelphia, 1872, lxiv, 325–365.
17. Libanoff: Jour. de Chir., January, 1914.
18. Lotheisen: Beitrag z. Klin. Chir. Tubing., 1901–2, xxxii, 655–686.
19. Mann, J.: Exp. Med., 1917, xxvi, 387.
20. McLean: Lancet Clinic, 1916, cxvi, 221.

20a. Meyer: Tr. Am. Surg. Assn., 1913, xxxi, 233–248.

21. Murphy: Surg., Gynec. and Obst., January 8, 1915. Practical Medicine. Series Surgery, 1915, p. 92.
22. Olshausen: Verhandl. d. Gesell. f. Chir., 1908, xxxiv, 15.
23. Playfair: Tr. Path. Soc. London, 1867, xviii, 68–75. Lancet, July 27, 1867, 94; Ibid., August 10, 1867, 153.
24. Ritzman: Berl. klin. Wchnschr., July, 1911.
25. Talke: Beitr. z. klin. Chir., 1902, xxxvi, 339.
26. Talley: Musser and Kelly, 1917, iv, 551.
27. Thane: Australian Med. Gaz., 1912, 126.
28. Van Sweringen: Jour. Indiana State Medical Association, Fort Wayne, 1912, v, 157–160.
29. Virchow: Neue Notizen Gebiet d. Natur. v. Heilkunde, 1846; Beitr. z. exp. Path. u. Phys., Berlin, 1846, 1–90.
30. Volker: Semaine Médicale, April 29, 1914.
31. Ward: Am. Jour. Obst., 1913, lxvii, 561.

32. Welch: Thrombosis and Embolism, Allbutt's System of Medicine, 1909, vi, 691–821.
33. Wilson: Ann. Surg., December, 1912, lvi, 809–817.
34. Wyder: Volkmann's Sammlung klin. Vorträge, n. f., 146, 1896.
35. Zahn: Virchow's Arch., 1875, lxii, 81.
36. Zurheule: Med. Klin., November 7, 1909.
37. Zweifel: Arch. f. Gynec., lxlii, 151; Ibid., cxi, 391.

DISCUSSION

Dr. William B. Coley, New York City:

I should like to say a word as to the frequency of pulmonary thrombosis after operations for hernia. When Dr. Hoguet and I published our results at the Hospital for Ruptured and Crippled a year ago there were 8090 cases without a single instance of pulmonary thrombosis. In 700 cases operated upon in 1919 there were 2 cases of pulmonary embolism. Up to the present time therefore we have had 2 cases in nearly 9000 operations for hernia of all kinds. Of these cases one was a very large double hernia with a great deal of trauma, in a patient in bad condition, operated upon by my colleague. At the Mayo Clinic in 1912 the frequency of this condition was brought out by Wilson who stated that there had been 47 cases of postoperative embolism in 63,575 cases of major operations.

Dr. Charles L. Gibson, New York City:

Some years ago I had an idea that possibly postoperative thrombosis might be due to the anesthetic. I can remember as an intern no case of pulmonary thrombosis; also for several years while assistant to a gentleman who had a large private practice I never saw a case. It seemed to me to come more acutely and with more frequency at the time the newer methods of anesthesia developed, that is those which depend on asphyxiation. Coincident with that we may have done more important surgery. This hunch of mine became so strong that a couple of years ago I stopped in my service entirely the routine anesthesia by any form of asphyxiation anesthesia, and decided to use ether only by the open cone and drop method. Time will show what will be the results. I have a feeling that in some way the asphyxia has something to do with it. As regards the direct cause I think the whole thing in the last analysis must come down to the traumatic conditions in the abdomen. You daily see very extensive and very large excisions in the neck and yet you practically never see any postoperative thrombosis, although all of the elements of trauma have been present. The condition is probably a good deal more frequent than we believe. Probably the younger people can survive because the vessels are elastic and some blood will slip by a small thrombus, but yet I feel there is a probability that anesthesia has something to do with it.

Dr. Joseph A. Blake, New York City:

I rather hesitate in relating my personal experience but I am one who had pulmonary thrombosis twice. Consequently I know some-

thing of the symptoms. What brings me to my feet is this, to emphasize the point that before I had pulmonary thrombosis I only recognized the cases that died, since then I have been much more interested in them and the number of cases of pulmonary thrombosis which occur I am positive greatly exceeds what we ordinarily suppose. I was led to that opinion by the fact that my first thrombosis occurred the tenth day after a chronic appendix had been removed, by gradual onset of the typical symptoms of thrombosis characterized by no sudden syncope, without pain and with a very slight hemoptysis. Although my physician tried to hide it from me I knew pretty well what was the matter. I got better with an infarct in my right chest and sat up about ten days later. That attack was the one which particularly interested me. The second I had on sitting up and was more of the typical variety, starting by a sudden syncope, and I fell off my chair, and lying on the floor from which I was lifted into my bed, I suffered terrible dyspnea, terrific pain and anxiety. The air hunger was simply terrific; I could not get any air. I only had strength to motion people away and point to the window in order to get more air and then the first word I said was morphin, and I hope you will bear this in mind. I believe if morphin is given immediately it will save a great many of these cases. If we analyze the amount of lung tissue obstructed by the ordinary thrombus we will find it comparatively small, that is compared with the rest of the breathing apparatus, and I believe it to be a pneumogastric disturbance in which the heart is involved as well as the respiration, and where everything is turned upside down and the whole organism stops; and that if you can do something to keep things on an even keel and depress the receptivity of the medulla possibly the organism will begin to steady itself and the patient work out his salvation. The effect of the morphin was marvellous, my heart steadied down and the respirations quieted, the pain and air hunger disappeared and I came out of it all right. That is one point I think worth bearing in mind, the wonderful value of morphin. In regard to the symptomatology I have carefully observed every patient I have operated on since, and I have detected time and time again a little pain in the chest, a little blood-tinged sputum with very transitory symptoms, and the careful examination of the chest has provided evidence of a small infarct. I believe there are numbers of these cases which are unrecognized. We remember all our cases of pulmonary thrombosis by the deaths and not by the careful observation of those patients who are fortunate enough to recover. I had a disturbance of the heart's action which existed until this last year, the heart going every which way, and for a year after the operation I could hardly

carry on. I had to cut out most of my work but now I feel better than I have done in years. I have heard from the Mayo Clinic that cases of double thrombosis were often attended by disturbance of the heart's action, sometimes lasting for a long while.

Dr. Charles H. Mayo, Rochester:

This is a most interesting group of cases: the patients are terribly afflicted, as Dr. Blake has shown by his graphic description of the awful air hunger, anxiety, and pain. I tell our interns that one-half of the patients with pulmonary embolism who live ten minutes will recover, since those who die die in the first attack after a few minutes. Those who live have a second attack within six or eight hours. The patient should be given morphin to stop his agony and plenty of fresh air. As Dr. Blake says, pulmonary embolism occurs in many cases in a lesser degree and is not suspected. Several of our patients have died when they were ready to leave the hospital while they were straining at stool or while getting out of bed. Since a large percentage of all our patients who die come to necropsy we are able to determine the cause of death in most cases, and sometimes we find the cause of death to be the formation of a small blood clot between the cordi tendinæ. It does not necessarily come from a distant point, but it may.

Dr. E. Wyllys Andrews, Chicago:

Nothing was said by Dr. Ochsner about the importance of fatty embolism in the lung. Numerous cases were observed a number of years ago in Cook County Hospital, and the microscopic examination demonstrated the pathology to be that of multiple fatty emboli in the smaller pulmonary vessels. It was a most interesting picture under the microscope. That was rather a new field at that time and the cases came almost entirely from fractures of the long bones. Bissell worked that out a number of years ago when he was pathologist at the Hospital, but he carried away some unfinished work on this interesting subject to the Mayo Clinic and there developed it. The work goes to prove that pulmonary embolism accompanies most of the surgical procedures to more or less extent. Bissell was able to show microphotographs of the actual development of fat emboli in vessels. This was increased in all traumas of fatty tissues, and to a certain extent the measure of the surgical shock was the measure of the seriousness of this condition.

Dr. John L. Yates, Milwaukee:

Experience in treating pulmonary injuries and the experiments of Dr. Mann have proved that it is not the degree of block in the pul-

monary circulation that produces disaster when embolism of the pulmonary artery occurs. Professor Barcroft of Cambridge offers an hypothetical explanation of the sudden or rapid fatalities, which is significant in this discussion. He thinks it probable that there are nerve endings scattered irregularly beneath the endothelial lining of the pulmonary artery which when irritated cause pain and cardiac inhibition. This would explain why fatal emboli vary so greatly in size and in the places they lodge since occlusion of the pulmonary artery to an entire lung does not embarrass the heart nor cause infarction. It also gives a physiological indication for the prompt administration of full doses of morphin when death is not immediate.

Dr. Miles F. Porter, Fort Wayne:

There are three points I wish to speak of: First, cyanosis during anesthesia, no matter what anesthetic is being given, should be more generally considered as a danger sign. Second, operations of expediency should be more generally and, if you please, more vigorously objected to and put off during epidemics such as those we have recently passed through. Third, if we get anywhere worth while in the discussion of this subject we must draw a line between embolism and thrombosis.

Dr. Albert J. Ochsner, Chicago (in closing):

This paper contains a lot of evidence confirming the statement of Dr. Yates that if the embolus becomes lodged at a distance the patient usually recovers, if lodged near the beginning of the pulmonary vein it increases in size rapidly, shutting off the vein altogether, and kills the patient immediately. Regarding Dr. Andrews' statement concerning the removal of a pulmonary thrombus by a surgical operation, the paper contains statistics of quite a number of attempts to remove the clot but so far no case has lived. There are certain cases in which a fat embolus becomes lodged across the shoulder of the first branch of the pulmonary vein and these are the cases of fractures that die from embolism. The fatty embolus, that becomes lodged at a distance, only kills the patient if he develops pneumonia. One of our cases had recovered from the operation in whom a vegetation started from the valve and got caught in the pulmonary vein, accumulated rapidly, the patient falling over dead. The symptoms which Dr. Blake has given are of tremendous value, because they are authoritative. They correspond to the symptoms which Welch and Wilson have given as quoted in this paper. There is no doubt, according to some authorities, that there are as high as 90 per cent. of recoveries of cases in whom

there is an embolus. These are cases in which the emboli are located at a distance from the beginning of the pulmonary vein. According to Dr. Blake's history his embolus must have been located very near the beginning of the vein, and I have not a particle of doubt but that the morphin kept the vein from becoming entirely occluded. We have not given attention to the matter of anesthesia, spoken of by Dr. Gibson, but will do so in the future. As to the possibility of thoracic surgery as an emergency operation to relieve this condition, I think it is possible that the next generation of surgeons will operate by lifting out the clot but at the present time these efforts have not succeeded in saving life.

ETIOLOGY, PATHOLOGY AND CLINICAL FEATURES OF BENIGN EXOSTOSES

By ELLSWORTH ELIOT, M.D.
NEW YORK

Nutritive disturbances and trauma have long been recognized as important factors in the etiology of exostoses. In the former, exostoses occasionally multiple, spring from those epiphyses which are chiefly concerned in the growth of the bone and not infrequently disappear when the nutritive disturbance is relieved or corrected. Exostoses due to trauma include chiefly those resulting from the irritation of long-continued friction such as may be observed either at or near the inner surface of the lower epiphysis of the femur, in a persistent horseback rider. The clinical features of these two groups of exostoses are so well known as to require no further consideration, although, in passing, it may not be amiss to call attention to the fact that exostoses arising from the epiphyseal line, in the subsequent growth of the bone, gradually become separated from it, in that the actual point of origin of the growth remains stationary while the epiphyseal cartilage, proper, recedes.

The study of the effect of acute trauma at a distance from the epiphyseal line and even at a time when the full growth of the bone has been attained is not without considerable interest.

Contusion of the bone, like that of the overlying soft parts, causes a variable rupture of bloodvessels with the escape of blood in the direction of least resistance. In contusion of bone this extravasated blood collects beneath the periosteum, usually in such small quantities as to cause no perceptible swelling. Subse-

quently, as in the soft parts, the clot is usually absorbed, although more slowly, and at times not without leaving slight permanent irregularities in the contour of the bone, due to the calcification of its unabsorbed portion. A gradually subsiding tenderness with, in exceptional cases, a distinct though slightly elastic swelling are its only symptoms, and ordinarily there is little intereference with locomotion or other use of the extremity.

Rarely, however, as in the case herewith reported, after a more or less localized trauma, a tender swelling develops, involving a considerable portion of the bone, which is very sensitive to the touch and deeply elastic in consistency. While this swelling does not usually suppurate the absorption of the extravasated blood may not readily take place, and its persistence, together with its gradual calcification, may cause such a degree of discomfort that the patient is impelled to seek relief. In the absence of suppuration a permanent thickening of the bone corresponding to the extent of the hematoma may ultimately be expected, differing only in degree from what ordinarily takes place in the mild type of this lesion. These permanent bony irregularities, of variable size, can in no wise be classified with pointed exostoses, although resembling, at times, the so-called ivory variety, commonly seen in the skull, which by some is considered to be of traumatic origin.

It is quite possible, however, for a subperiosteal hematoma of the smallest size to prove the starting-point of a more or less actively growing pointed exostosis that cannot be differentiated either pathologically or clinically from the classic pointed exostosis, the result of continued and repeated friction. The rapidity of growth of an exostosis from such an origin, even though based, as in the present instance, upon a single case, is particularly worthy of mention. As a class, benign tumors, especially those of bone, are of slow growth. In the case referred to, however, the pointed exostosis reached a length of two inches within thirteen months, an extremely rapid growth, and the fact that friction played no part in this unusual phenomenon is demonstrated by the statement of the patient as well as by the failure

of any bursa to develop over its pointed apex. While a rapid increase in size is the rule in malignant growths and may be expected in those exceptional benign tumors which undergo malignant change, the benign character of the exostosis in question was positively demonstrated by a subsequent careful microscopic examination.

Male, aged twenty years. December 15, 1915. Two and a half months ago, while playing football, patient was kicked in the right thigh. This was immediately followed by swelling, involving the entire thigh and knee, confining the patient to bed for one week. At the end of that time the acute pain and disability had subsided and there remained of the swelling only that part in the middle of the thigh on its outer and anterior aspect which, about four inches long, persisting up to the present time with only slight decrease in size, although it became gradually of firmer consistency. During this interval the patient has suffered from considerable pain and discomfort, especially on walking and on attempting to flex the knee. The pain has been worse at night. For the first part of this period the patient walked with crutches and latterly with a cane, there being a perceptible limp.

All attempts to relieve the pain and bring about the absorption of the swelling by massage and various forms of counterirritation having proved futile, the patient insisted on operation. Under ether, through an incision four inches long on the outer anterior aspect of the thigh, the periosteum was exposed. It was considerably thickened and on division of its outer layer an oval cavity filled with a mass of rather friable calciferous tissue and about three-quarters of an inch thick, gradually becoming thinner at either extremity, was disclosed. The demarcation between the inner layer of the periosteum and the superficial surface of this mass was well defined and easily separated with the finger. The same condition was found to exist between its surface and the adjacent layer of compact bone, so that the removal of the mass was accomplished without difficulty and in a satisfactory manner. After suture of the divided periosteum

the muscular layers were closed with chromic gut, a small rubber tissue drain being left *in situ* for twenty-four hours. Primary union was obtained and the patient was completely relieved of all discomfort.

Pathological examination of the removed tissue showed a trabeculated formation of calciferous tissue, attached to which were strands of dense connective tissue. Between the trabeculæ there had been extensive hemorrhages. No evidence of infection.

Ten months after this operation patient first noticed intermittent burning sensations in the thigh, and as these became more frequent a roentgen ray was taken three months later. This disclosed a typical pointed exostosis projecting from the outer aspect of the femur at a point opposite the lower extremity of the scar. This was found on operation to arise from the femur at a point corresponding to what had formerly been the lower end of the organized subperiosteal clot and was easily removed. There was no bursa over its irregularly pointed extremity and the bone directly above and the site of the former clot presented a normal appearance.

A microscopic examination of the exostosis differed in no particular from that ordinarily found in that condition. The patient was relieved of all discomfort and has had no trouble since.

While clinical observations of an unusual character are necessarily void of scientific application, they are not without a certain interest, and perhaps, in the present instance, the possibility of such a clinical history in a bony exostosis may prove of some value in adding another type of benign tumor to those of vascular character which, although they may exceptionally show a rapid growth, must still be retained in the benign class.

DISCUSSION

Dr. Frederic J. Cotton. Boston:

I am interested in this paper because it seems to me there is a good deal of confusion about the place in which we should put these so-called exostoses. So far as I got the detail of this paper this case is what we call myositis ossificans, and does not represent an exostosis of tumor form. We are familiar with these growths which occur nearly always in fractures or dislocations of one or another joint. The theory is that the formation is favored by the presence of synovial fluid in the presence of clot. The fluid does not seem always necessary but these growths nearly always occur at or near joints in severe traumas. I have seen several cases not near joints, subject to no friction, of the same type as in the more familiar form. Perhaps this case belongs in that class. Histologically there is no definite structure, no way of distinguishing. They have nothing to do with the friction type, show no formation of bursæ over the tumor usually, though in one case that was present. They are in no sense tumor forms and there is one very interesting clinical point about them: if you let them alone they usually get well, unless they are in the way of some motion, or in the way of some repeated trauma, in the way of blows. It is striking to see the cases in the joints, how they get well if left alone and are not subjected to motion or trauma. It is an inflammatory area and not a new growth, and if not irritated it subsides. I do not mean none of these are operable—the smaller ones around the elbow-joint not anatomically running into the muscle will subside if you give them a chance. Others I have seen have been operable cases. One followed a fracture of the pelvis, it had gone on for nearly two years, the man being entirely crippled and unable to sit down, neither could he stand up and walk very far. It had reached its limit and therefore I took it out and he is now back at work. Another followed a compound fracture of the ramus in the flare of the ilium: for a year there was a persistent sinus but since removal of the growth there has been no further trouble. One occurred in the thigh in the region of the usual rider's bone as the result of a single trauma and that was allowed to go on for about four months when it was removed and has not recurred. As a rule if you take these spurs out after they are delimited they do not recur. As to the time and operative indications, if you *x*-ray them you will find no definite limiting surface in the early stages, quite without a clear limit: later there is a cortical layer formed around the periphery of the bone-formation. Does Dr. Eliot regard this variety as the same as he is describing?

Dr. Ellsworth Eliot, New York City (in closing):

Instances of myositis ossificans are not rare. Perhaps they are seen most frequently in the dissection room where they are found in tendinous attachments close to the adjacent bone. In the present instance, an *x*-ray, prior to the first operation, clearly demonstrated the subperiosteal character of the lesion and there was no evidence at the operation, of any abnormality in the contiguous muscular attachments. Neither was there any difficulty, at the second operation, in reflecting the muscle from either side of the pointed exostosis, which presented a smooth surface and which, slightly curved at its extremity, was directly attached to the bone by a somewhat constricted base. There was not the slightest evidence of any tendinous or aponeurotic calciferous infiltration.

SARCOMA OF THE CLAVICLE—END-RESULTS FOLLOWING TOTAL EXCISION

By WILLIAM B. COLEY, M.D.
NEW YORK

In a paper read before the meeting of the American Surgical Association in Washington, May, 1910, I reported a case of total excision of the clavicle together with ten other cases of sarcoma of the clavicle that had come under my personal observation. Adding to these the cases which I was able to find in the literature, I reported a total of 63 cases, nearly all of which had been treated by total or partial resection. In many of the cases the end-results were not known. Only 2 were traced that had remained well beyond the four-year period.

In 1912 Johansson (*Deutsche Zeitschr. f. Chir.*, vol. lxviii, 1912) found 32 cases in the literature that had not appeared in my list of previously collected cases, and, in addition, he published 3 cases that had come under his own observation.

Kalus (*Inaugural Dissertation*, Royal Univ. of Greifswald, 1912) has also reported 2 cases since the publication of my earlier paper on the subject.

In addition to these, I have had under my own observation since that time 5 other cases of sarcoma of the clavicle.

Only 5 of my own series of cases have a direct bearing upon the question at issue: the end-results following total excision of the clavicle. In 2 of these cases the operation was performed by myself, and in the remaining 3 by other surgeons. *i. e.*, Dr. Maurice Richardson, Dr. Huntington, and Dr. Freeman. For a fuller history of these 3 cases I would refer you to my earlier

paper on the subject, published in the *Annals of Surgery*, December, 1910.

CASE I.—*Periosteal Round-celled Sarcoma of the Clavicle.* J. V., male, aged sixteen years, noticed pain and swelling of the left clavicle shortly after a severe strain. The tumor was of rapid growth and involved two-thirds of the inner portion of the clavicle. The diagnosis was established by physical signs and *x*-ray photographs, without an exploratory operation. On November 22, 1909, I performed a total excision of the clavicle, from which the patient made an excellent recovery. A few days later he was put upon the mixed toxins of erysipelas and bacillus prodigiosus, which were kept up for a period of three months. Almost no deformity resulted from the operation and the patient retained complete functional use of his arm. He served in the Army in France during the war, and at the time of my last examination, in February, 1918, nearly nine years later, he was in good health with perfect functional use of the arm. Microscopical examination made by Dr. James Ewing.

CASE II.—*Periosteal Round-celled Sarcoma of the Left Clavicle.* J. W. H., male, aged thirty-four years, injured the left clavicle in January, 1908, shortly after which a local swelling appeared which grew rapidly. A total excision of the clavicle was done by Dr. Maurice H. Richardson, of Boston, on May 18, 1908, the tumor being so large that the operation was very difficult. As soon as the wound healed the patient was referred to me by Dr. Richardson for prophylactic toxin treatment. The treatment was begun in New York and carried out under my direction by Dr. H. L. Trulock, of Dixmount, Maine, for a portion of two years. Dr. Richardson believed the prognosis so grave from operation alone that he stated in his letter if the man made a permanent recovery he was willing to give the entire credit to the toxin treatment. According to a letter received from the patient at the present time (April, 1920), he is still in good health without the slightest trace of a recurrence, twelve years later. Microscopic examination made by Dr. W. F. Whitney, of Massachusetts General Hospital, Boston.

CASE III.—*Periosteal Round-celled Sarcoma.* I have performed one other total excision of the clavicle since my former paper, the history of which is briefly as follows: T. M., male, aged twelve years, entered the Hospital for Ruptured and Crippled in December, 1912, and was referred to me by Dr. Whitman. The patient had always been well until five weeks previously, when he fell from a step-ladder, the inner portion of the right clavicle striking upon the corner of a wooden box. Two weeks later a swelling appeared at the site of the injury, apparently arising from the bone; no pain, but very rapid increase in size. On December 17, 1912, or three weeks from the time the swelling was first noticed, physical examination showed a large tumor about the size of a hen's egg, markedly protuberant in the region of the sternum and right clavicle, occupying the inner half of the right clavicle and apparently involving the suprasternal region. It was very soft, almost fluctuating in consistence, some areas being denser than others; the superficial veins were markedly dilated. The *x*-ray photograph showed almost complete destruction of the inner third of the right clavicle. Clinical and *x*-ray data made the diagnosis so clear that no specimen was removed for microscopic examination. I performed a total excision of the right clavicle on December 20, 1912, with practically no loss of blood, and the patient suffered very little shock. Clinically, the tumor was definitely of periosteal origin. Dr. Ewing's full report of the whole specimen is as follows:

Specimen consists of clavicle which fractured about the middle point, where it runs directly into the tumor mass. Periosteum strips easily, shaft of bone is eroded beneath it. The outer end of clavicle is largely destroyed by tumor growth which has split up layers of periosteum and bone shaft and invaded the surrounding muscle for a distance of $\frac{1}{2}$ cm., producing a rounded tumor in this region. The gross appearance is not distinctive of either central or periosteal sarcoma. The outer end of the bone is much thickened and the bone is irregularly absorbed. Through the center of the globular mass of tumor runs a sharp white line indicating periosteum, beyond which the tumor infiltrates muscle and fat.

Histology.—The tumor belongs in a class commonly called small round-celled sarcoma. Cells are small, 10 to 12 micr. in diameter. with poorly defined cytoplasm, hyperchromatic vesicular nuclei. The shape where preserved is polyhedral, cell bodies are clear, arrangement is diffuse, the cells often sheathing numerous small bloodvessels. Size of cells remarkably uniform. One large artery is filled by mural tumor thrombus. Muscle is extensively invaded and destroyed by a diffuse focal growth of tumor cells. Histological indications are highly malignant. Exact source of the cells undetermined.

Ten days after the operation there was a marked swelling at the site of the old tumor having every appearance of a local recurrence. The patient was then put upon the mixed toxins which were continued daily until a reaction of 102° to 103° was obtained. At the end of two weeks the swelling had disappeared and the patient regained his lost weight. The treatment was kept up for two months, after which he returned home for several weeks and had no treatment. He was readmitted for another course of toxins, lasting about a month. However, in the interval in which the treatment had been discontinued a local recurrence appeared just below the site of the clavicle, in the pectoral region, and also in the neck. The recurrent tumor was soft, almost semi-fluctuating and grew with great rapidity. Although the toxins were resumed and the patient was treated with radium by Dr. Abbe, nothing was able to check the rapid progress of the disease. Metastases developed in the chest shortly after and proved fatal. The total duration of life from the time the trouble was first noticed was about five months.

In this case I believe a great mistake was made in stopping the toxin treatment too soon.

Case IV.—The case of Dr. Thomas W. Huntington, of San Francisco, Cal., although published in full in my earlier paper, is worthy of special note here, inasmuch as the patient was still in good health when last traced, seven years later. A brief history is as follows: Periosteal, spindle-celled sarcoma of the right clavicle, operated upon on September 8, 1908. Immediately

after the operation Dr. Huntington wrote me inquiring as to the advisability of using the mixed toxins as a prophylactic against recurrence, and I replied that I would strongly advise their use. The treatment was begun two weeks after the operation and continued for a period of five months. When last seen by Dr. Huntington in 1915 the patient was still in good health, seven years later. (This case was one of periosteal sarcoma (spindle-celled).)

CASE V.—*Round-celled Inoperable Periosteal Sarcoma of Clavicle and Scapula Becoming Operable Under Treatment.* The history of the case as contained in a personal letter received from Dr. Freeman is as follows: H. L. S., male, aged twenty-three years. First seen by Dr. Freeman July 17, 1908. The patient had sustained a fracture of the scapula and clavicle eighteen months before; enlarged glands had appeared above the clavicle three months before. One month before he came under Dr. Freeman's care he had another injury, falling upon his back. Shortly afterward a rapidly growing tumor appeared over the right clavicular region. At the time of Dr. Freeman's examination there was a large tumor, involving the upper scapular and clavicular region and extending nearly to the spine; there also was a glandular tumor in the neck, as large as a fist, and another of equal size in the deltoid region. The glands of the left side of the neck were also enlarged and had been enlarged for four weeks; the patient had lost 14 pounds in weight. A specimen of the tumor was removed for microscopic examination and pronounced large round-celled sarcoma with some spindle cells. The case was regarded as entirely inoperable, even as regards an interscapulothoracic amputation. The patient was therefore put upon the mixed toxins of erysipelas and bacillus prodigiosus combined with *x*-rays. On September 1, or six weeks later, marked improvement had occurred; the tumor had decreased to half its original size and was much softer. Soon after the patient returned to his home in Oklahoma. Shortly after he had a severe hemorrhage and an interscapulothoracic amputation was performed.

Dr. Freeman has kindly written me from time to time, giving

the after-history of the case. In his latest letter he stated that the patient was well in 1918, ten years after the treatment.

The only case in my series which was operable at the time of observation, but in which it was decided to try radium instead of operation, is as follows:

FIG. 1.—Case VI. Two and one-half months after treatment. No evidence of lung involvement at time treatment was begun.

CASE VI.—S. L., female, aged twelve years. Family history negative. No trauma.

Patient was admitted to the Memorial Hospital in August, 1919, with a history of, one month ago, having first noticed a small nodule, the size of a marble, in the sternal portion of the right

clavicle, which grew very rapidly until it had reached the size of a small hen's egg. Physical examination at this time showed a smooth, rounded swelling of the right clavicle, symmetrical in outline, moderately firm in consistence, about 2 inches by $1\frac{1}{2}$ inches in diameter. The skin was normal in color, not adherent,

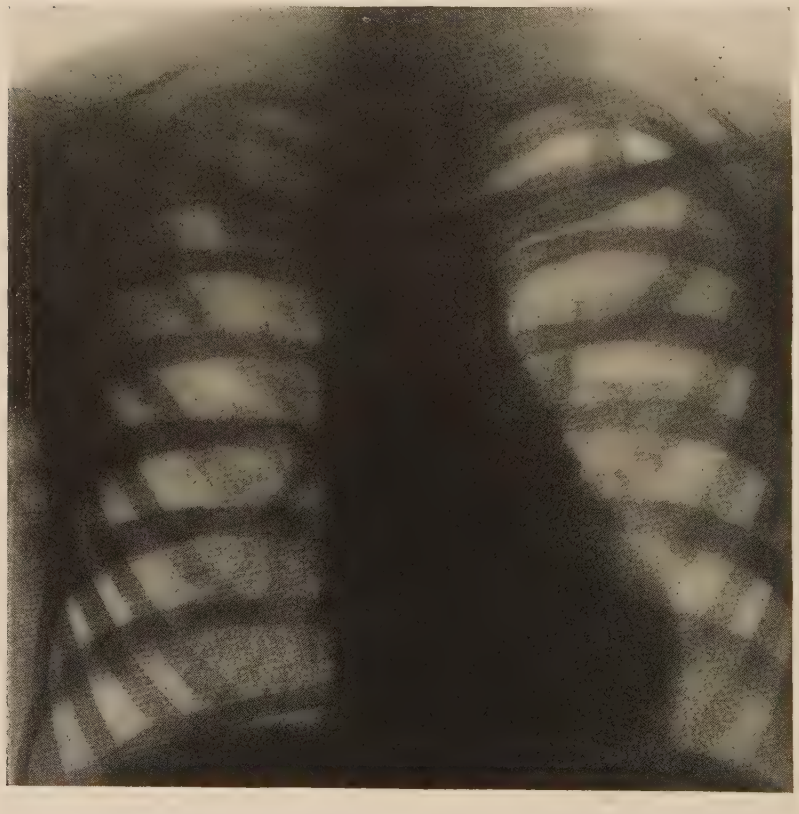

FIG. 2.—Case VI. One month later.

and there was no marked dilatation of superficial veins. An *x*-ray picture taken on August 7, 1919, showed the inner third of the clavicle involved by a rarefying process extending outward from its inner end; space between end of bone and sternum is abnormally wide; suggests beginning in clavicle; chest negative.

Although in the opinions of the surgical staff the case was clearly operable, it was decided to try the effect of radium alone with no other treatment. Accordingly, the radium treatment was begun on August 10, 1919, and given as follows by Dr. Douglas Quick:

August 8, 1919: Radium pack, 9279 mc. hours at 6 cm. distance over the clavicle.

August 14, 1919: Bare tubes containing 17 mc. of radium emanation were inserted.

August 29, 1919: A lead tray, 8000 mc. hours, at 5 cm. distance over the tumor.

October 4, 1919: Radium pack, 10,087 mc. hours at 6 cm. distance over the tumor.

November 16, 1919: Lead tray, 3000 mc. hours, at 3 cm. distance over the tumor.

In addition she received seven *x*-ray treatments over the anterior chest in November, 1919.

On August 20, 1919, the patient was discharged from the hospital with a decrease in the size of the tumor. Examination on September 2 showed improvement.

An *x*-ray picture taken on October 7, 1919, showed very little change in the condition of the clavicle. Physical examination November 7, 1919, showed the patient to be improving slowly. An *x*-ray examination was made on the following day, a report of which is as follows: "*X*-ray of chest reveals numerous well-marked metastases in lungs. Process in clavicle remains unchanged." She was readmitted to the hospital on November 11, 1919, at which time examination showed no growth in the clavicle tumor, but examination of the chest revealed metastatic nodules. Her general condition was not so good; she was anemic and had lost considerable in weight. She tired very easily and had occasional pain in the chest.

In spite of *x*-ray treatments over the chest the patient's general condition rapidly deteriorated and she died on January 20, 1920.

The entire duration of the disease in this case, from the time the tumor was first noticed, was a little over six months; and from the

time the treatment was started five months. The very rapid generalization of the disease points to a high degree of malignancy of the tumor. No exploratory operation was made and hence we do not know the histological type of the tumor. It was undoubtedly periosteal, probably round-celled. Whether the patient could have been saved had the clavicle been removed by total excision, followed by prophylactic treatment with the mixed toxins and radium, it is impossible to state. However, from the results that have been obtained in the other cases already reported, I believe that the chances of a cure would have been greater had such method of treatment been employed. While we have no evidence to show that the very rapid generalization of the disease in the lungs following so closely the introduction of bare tubes of radium in the clavicular tumor was due to the treatment there is a possibility that the introduction of these tubes and the rapid breaking down of the tumor cells may have favored the development of metastases. We have, however, used bare tubes in so many other cases in precisely the same way without any apparent influence in the development of metastases, that it is fair to state that it may have been only a coincidence in this case.

This, as far as I know, is the only case in which radium has been used in an easily operable case in this country.

However, a case of periosteal sarcoma of the clavicle, treated with radium alone, was briefly reported by Pincy, of the Radium Institute, of London, about three years ago, and a personal communication from Dr. Pinch received a few weeks ago, contains the following data:

Female, aged sixty-two years, was sent to the Institute in June, 1913, for the treatment of a large, rapidly growing periosteal sarcoma of the right clavicle, which had been present for four months. An attempt at its removal had been made in May, but the surgeon found this could only be done if Berger's operation were performed, and patient would not consent to this procedure. The growth formed a prominent tumor, filling up the right supraclavicular fossa and measuring 10.5 x 6 x 2 cm.; it was very

firmly fixed to the clavicle. Microscopic examination of portions removed showed it to be a round-celled sarcoma.

A 100 mgr. tube screened with 1 mm. of silver was buried in the tumor for twenty-four hours. The growth steadily shrank, and by the end of July no trace of it remained.

The patient was examined in January, 1918. There had been no recurrence, and all movements of the right arm could be performed fully and freely. Examination February, 1920, showed the patient perfectly well with no recurrence.

While this case in a measure offsets the distressing result obtained in the case I have just reported from the Memorial Hospital, it does not, in my opinion, furnish sufficient evidence to justify one, at the present moment, in substituting radium treatment for surgical operation in an easily operable case of sarcoma of the clavicle.

The results of excision thus far reported enable one to state definitely that the functional result following total excision is so good and the deformity so slight, that one is not warranted in taking much additional risk in attempting to save the bone. Our own case observed at the Memorial Hospital shows the great danger of general metastases developing while waiting to observe the local effect of the radium-ray treatment upon the clavicle.

We have had two border-line cases, in which the possibility of removing the clavicle was doubtful, and we decided to give the patients the combined toxin and radium treatment. In both of these cases large doses of radium, massive doses externally, and bare tubes inserted by means of a hollow needle in the tumor itself. In addition the patients were kept for long period under large doses of the mixed toxins. In both these cases the improvement following the treatment proved only temporary and metastases developed within six months, ending in death.

Case VII.—B. F., male, aged forty-nine years, referred to me on August 5, 1918, by Dr. F. H. Albee, of New York, with the following history: Eight weeks ago, while attempting to raise a window, felt sudden, sharp pain in the right shoulder, which

ceased on stopping motion and recurred on active motion of the arm. The following day he noticed a swelling over the right clavicle. An *x*-ray picture was taken, which showed a fracture. Arm and shoulder immobilized. Another *x*-ray picture was taken four weeks later, on July 1—inconclusive. Wassermann

Fig. 3.—Case VII.

reactions negative. July 20, exploratory operation by Dr. Albee. Microscopic examination of specimen removed showed large round-celled sarcoma. The report reads as follows:

Gross section is a thin section of bone with hemorrhagic streaks and on one side are pinkish-white, semi-soft, irregular tabs of

tissue. Microscopically, the entire picture is of sheets of rather polyhedral or large round cells staining darkly and frequently dividing. These sheets are held in a fibrous stroma and in an alveolar pattern, although frequently overrunning these trabeculæ or capsules as the case may be. The picture is typical of malignancy.

FIG. 4.—Case VII.

Physical examination at the time the patient came to me showed a firm tumor occupying one-half of the right clavicle, beginning at the sternoclavicular articulation and extending 3½ inches outward. Yielding on pressure shows a pathologic fracture.

The patient grew rapidly worse, and in February, 1919, his condition was hopeless.

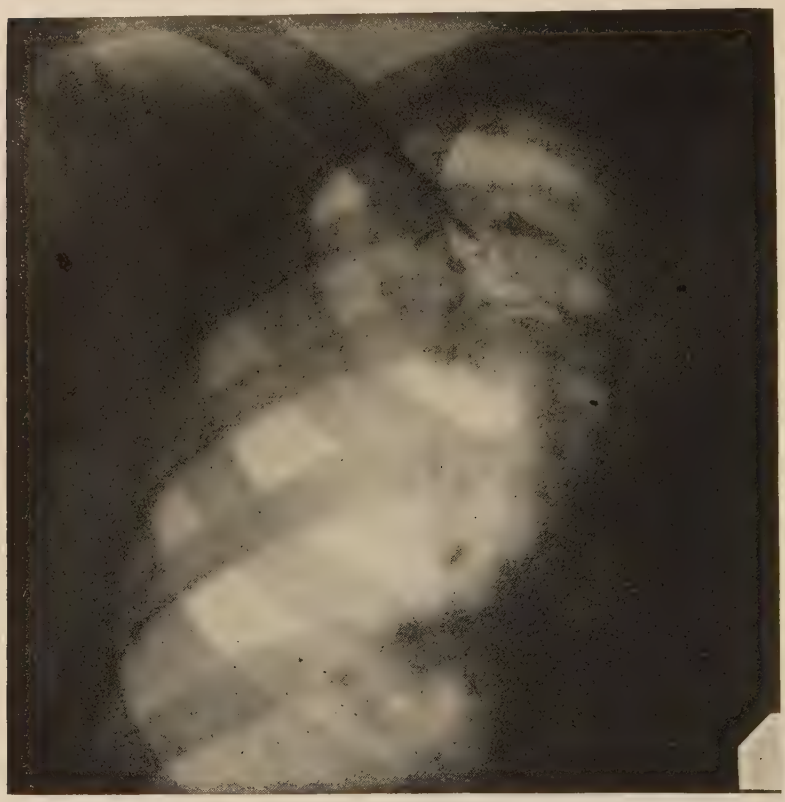

FIG. 5.—Case VII. Four months later.

CASE VIII.—C. A., male, aged fifty-seven years, referred to me by Dr. George S. King, of Bayshore, L. I., on December 26, 1918, with the following history: Patient always in good health until September, 1917, when he strained his right shoulder while cranking a car. Shortly afterward noticed pain in his neck and a swelling in the sternoclavicular articulation on the right side. The pain and tenderness decreased somewhat and there was little change for nearly a year. An *x*-ray picture taken in

December, 1918, showed some destruction of bone at the inner end of the right clavicle. A month ago the swelling began to increase more rapidly in size after slight exertion. X-ray pictures taken then showed an extension in the destructive process of the bone, with some crepitation. Wassermann reaction negative.

FIG. 6.—Case VIII.

Patient has been unable to raise his arm to a horizontal position for the past three weeks. Physical examination December 26, 1918, showed a swelling occupying the inner two-thirds of the right clavicle, extending to, and involving, the sterno-clavicular articulation. The tumor measured horizontally 5

inches and vertically 4 inches; it was firm, almost bony, in consistence and very tender on pressure, particularly over the central portion, and extended up to the cervical region several inches above the normal clavicular line. Just above the upper margin is a small, movable cervical gland, one-third inch in

Fig. 7.—Case VIII.

diameter. There is slight dilatation of superficial veins. Patient had lost 15 pounds in weight during the past year. After consultation with Dr. Downes and other members of the staff, the condition was believed inoperable, and it was decided to use the combined toxin and radium-ray treatment.

On December 31, 1918, bare tubes containing 3986 mc. hours of radium emanations were introduced into the clavicle; and on January 1, 1919, a radium pack of 9864 mc. hours at 10 cm. distance was placed over the right clavicle for nine hours.

At first there was marked diminution in size of the tumor and great improvement in the patient's ability to use the arm. After about two months, however, the swelling began to increase in size and the patient's general condition to deteriorate. In spite of continued treatment, pushing the radium to the point it was thought safe, it was impossible to gain control of the disease. The patient continued to decline and died on March 27, 1919.

The following case, like my own second case of total excision, shows the extreme malignancy of some cases of sarcoma of the clavicle. The history of this case was kindly furnished me by Dr. Walter B. James, who showed me the *x*-ray pictures and consulted me as regards treatment:

Case IX.—A. L., male, aged forty-eight years; always strong and well until September, 1913, when he fell, while playing golf, striking upon the shoulder and injuring his left clavicle, but not apparently sustaining any fracture. The arm was put in a splint for several weeks. A short time after the injury, a swelling developed in the region of the clavicle, which was first believed to be tuberculous. All tests for tubercular and specific disease proved negative. An *x*-ray picture taken in December, 1913, showed marked destruction of the inner end of the clavicle, with apparently some involvement of the mediastinal glands. Rapid decline in general health. The patient's physician, Dr. E. R. Baldwin, of Saranac Lake, on February 26, 1914, said: "The patient is now dying of slow collapse with every evidence of a dissemination of sarcoma." Death occurred two days later, making the entire course of the disease from the time of the injury to death, less than five months.

In the following case the disease ran nearly as rapid a course as in the preceding:

Case X.—A. T. B., aged forty-seven years, was referred to my service at the Memorial Hospital, on April 3, 1917, with a

history of having had an attack of influenza followed by pleurisy; was in bed for ten days. At the end of this time he first noticed symptoms in the right shoulder and outer part of clavicle, tenderness, swelling and some limitation of motion; was treated for rheumatism for a number of weeks. In the meantime the tumor

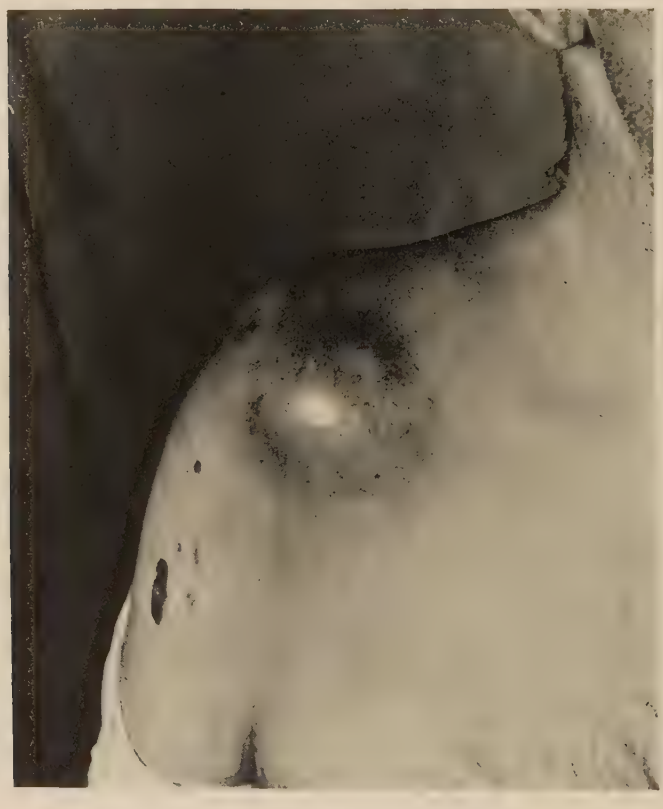

Fig. 8.—Case X.

of the clavicle rapidly increased in size. On April 3, 1917, the radiograph showed almost complete destruction of the right half of the clavicle, with extensive involvement of the roots of both lungs by metastatic nodules. He was treated for a brief period of two to three weeks with the mixed toxins of erysipelas and

bacillus prodigiosus with no appreciable effect. In view of the marked generalization of the disease, it was though unwise to continue the treatment. He died a few weeks later, the entire course of the disease being less than six months.

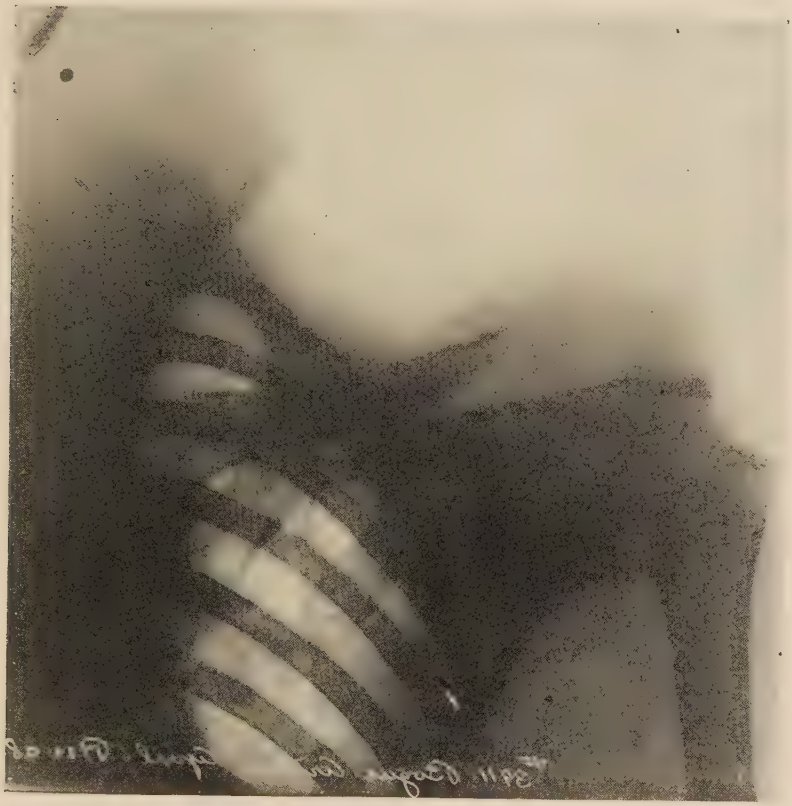

FIG. 9.—Case X.

CASE XI.—H. K., male, aged thirty-one years. In May, 1897, carried heavy piece of steel on right shoulder; one month later noticed lump directly over clavicle at the point where the steel rested. July, 1897, removal of gland below clavicle by Dr. Mayer, of Buffalo. Three weeks later a nodule appeared in the axilla. When seen by me in February, 1898, the patient's neck and

shoulder were occupied by an enormous tumor extending to sternum in front and nearly to the vertebral column behind. No treatment advised. Prognosis: Six weeks to two months' life.

FIG. 10.—Case X. Three months later.

CASE XII.—Mrs. L. C., adult, was referred to me on July 19, 1912, with the following history: In June, 1911, she had had a strain in the region of the right clavicle. Two months later a small swelling was noticed in the sternal end of the clavicle, which gradually increased in size. She was treated for rheumatism for six months. The clavicle was excised by Dr. Trout, of the Jefferson Surgical Hospital, Roanoke, Va., in May, 1912 and

a pathologic examination showed it to be an angiosarcoma involving the sternal end. As much of the surrounding tissue as possible was removed and *x*-ray treatment given; but in spite of this, a recurrence developed in a few weeks.

Physical examination, in July, 1912, at the time of my first observation, showed an inoperable recurrent mass just above the sternoclavicular articulation. The patient complained of pain and numbness in the arm. The end-result in this case has not been traced.

Case XIII.—D. B. A., male, adult. The patient first noticed a swelling in the sternal end of the right clavicle in November, 1909, for which an operation was performed in January, 1910. A second operation was performed in 1911, at which time the glands were removed. In August, 1914, a total excision was made and in the beginning of the following year, 1915, the patient noticed edema of the right arm and forearm. He was referred to me by Dr. J. B. Hulett, of Middletown, N. Y., in November, 1915, at which time physical examination showed an inoperable mass above the site of the right clavicle, extending over to the sternomastoid insertion and two inches backward. The mass was firmly fixed and quite inoperable. The patient had lost slightly in weight. I was unable to get a pathological report in this case, but the tumor was undoubtedly a malignant one. It has been impossible to trace the final result.

Case XIV.—*Round-celled Periosteal Sarcoma of the Left Clavicle.* Patient was referred to me by Dr. J. Collins Warren, of Boston. Specimen removed in October, 1903, was pronounced round-celled sarcoma. The tumor almost entirely disappeared under *x*-ray treatment, but later started to increase in size and was no longer controlled by the *x*-rays. In October, 1904, the patient was referred to me by Dr. Warren. At this time a pear-shaped tumor occupied the sternal portion of the left clavicle; there was glandular involvement above and below the clavicle and slight enlargement of left arm. From October 6 to November 26 the mixed toxins were given in conjunction with *x*-ray treatment, with slight temporary improvement only.

Case XV.—H. B., male, aged twenty-two years. No single trauma, but in habit of carrying iron pipes upon left shoulder. Pain in shoulder more than a year before tumor appeared. Small mass in outer portion of left clavicle noticed in January, 1910. Removed by Dr. Stewart, Newport, R. I., in March. Microscopic examination showed tumor to be round-celled sarcoma, periosteal. Recurrence three weeks later; rapid growth. Patient seen by me in September 15; toxins started immediately and continued to October 20, 1910, with little or no effect in controlling growth.

Patient died three months later.

Case XVI.—E. S., male, aged twenty-one years. Patient broke his left clavicle in May, 1893; one year afterward a swelling appeared at the site of the fracture and grew rapidly. Partial removal of clavicle, recurrence soon after, involving scapula. Mixed toxins tried for a short period, without success. Excision of remaining portion of clavicle; entire scapula and upper extremity removed by Dr. W. W. Keen, of Philadelphia. Death eight months later from recurrence.

Case XVII.—G. M., male, aged nineteen years. Tumor had existed for two years; first treated for rheumatism. No trauma. Came to New York Hospital in April, 1909, where Dr. Frank Hartley did a total excision. Microscopic examination made by Dr. Elsner, who reported the disease to be spindle-celled sarcoma. Three months later, local recurrence above and below the former site of the former clavicle. Patient referred to me in September, 1909, with numerous recurrent masses over the whole upper portion of the right chest. The mixed toxins were given, and while at first there was considerable decrease in the size of the various nodules and increased mobility, the improvement was temporary only and the toxins failed to control the further growths of the tumors. Patient died a few months later.

Case XVIII.—*Periosteal Sarcoma of Clavicle. Partial Resection. Death One year, in Case LXI, Tables.*

Three cases reported by Dr. H. B. Delatour, which, by an oversight, were not included in my former paper, are worthy of note.

Case I.—A. H., male, aged thirty-seven years; operated upon July 21, 1896, at the Long Island College Hospital. Antecedent trauma, May, 1894; injured left clavicle while wrestling; three months later tumor appeared at about the middle third of the bone. This grew slowly until November, 1895, when it suddenly ruptured while patient was walking on the street; hemorrhage profuse. The following day the tumor was removed. Hemorrhage during operation very severe, controlled with difficulty. Four months later, local recurrence; second operation in July, 1896; the tumor was the size of a hen's egg; veins dilated; no enlarged glands. Patient made a good recovery. The report states that thirty-three months after operation there was no evidence of a return. According to a personal communication received, the patient was alive five years later, since which time he was lost track of. The patient was able to perform the same type of work (porter in a rubber factory) as before operation, without any inconvenience. Pathological diagnosis: Type of tumor not stated, apparently of central origin.

Case II.—Female, aged twenty years; no trauma; history of swelling and neuralgic pain in the right arm for two months. There was also a tumor in the posterior surface of the clavicle. Pathological diagnosis: Osteosarcoma (Dr. Van Cott). Patient lost sight of shortly after operation.

Case III.—Sarcoma of the clavicle, involving sternum and first rib. Male, aged fifty-five years. History of a tumor of two months' duration which appeared shortly after a local injury, three months before; very rapid growth. Operation August 14, 1897. Complete extirpation of clavicle; division of rib and sternum from the left sternoclavicular articulation to the second chondrosternal articulation. Removal of a triangular portion of the sternum and inner portion of the first rib; several enlarged glands were removed from the anterior mediastinum. Patient discharged six weeks later in good condition. On December 7, 1897, the patient was admitted to the same hospital suffering from a fracture of the base of the skull, from which he died. No evidence of a return of the growth.

Case reported by Dr. George Tully Vaughan (*Med. News*, January 8, 1898).—W. S., male, aged twenty-eight years. Symptoms of seven months' duration before operation; considerable pain; tumor occupied the inner two-thirds of the clavicle. Operation at the German Hospital, Philadelphia, October 22, 1895; ether anesthesia. The entire right clavicle with tumor removed; troublesome hemorrhage, requiring 20 ligatures. Primary wound healing, except at two points. Discharged forty-one days after operation. Microscopic examination showed the tumor to be a mixed-celled (round and spindle) sarcoma. (Dr. Alfred Stengel.) One year after operation absolutely no deformity, except the absence of the clavicular prominence; patient is performing his work as fireman on a steamboat, without any inconvenience from the loss of the clavicle. Arm is free from pain and strong as ever.

A recent communication from Dr. Vaughan, dated April 16, 1920, states that the patient was perfectly well when last heard from, eighteen years after removal of the clavicle. At that time he had what his physician in the West believed to be a mild form of tuberculosis of the lung; he did not think it was metastatic or a recurrence.

Case Recently Reported and Not Included in Previous Collections. Dodd (*Ohio State Med. Jour.*, March, 1918) reports a recent case of sarcoma of the clavicle: Female, aged thirty-five years, first noticed a swelling in the right clavicle in March, 1916. This gradually increased in size until October, 1916, when it began to grow more rapidly. In February, 1917, it had reached the size of a grapefruit. The patient was seven months' pregnant. Operation was performed in February, 1917; there was some sloughing of the flap; on the fifth day the patient developed septicemia and died on the fourteenth day after operation. Microscopic examination showed the tumor tissue rich in cells: osteosarcoma with some mucoid in the cellular substance, round- and spindle-celled; no giant cells were found; tumor of periosteal origin.

In view of the great size of the tumor and the extent of the

involvement, I believe this case should have been considered an inoperable one.

Myeloma of the Clavicle. Dr. James M. Hitzrot, before the New York Surgical Society (Transactions, *Annals of Surgery*, 1918, vol. lxviii, p. 92), reported a case of myeloma of the clavicle in a male, aged forty years. The patient fractured his right clavicle near the sternal end in January, 1917. Shortly after noticed a small swelling at this site, which slowly increased in size. He was admitted to the New York Hospital on February 20, 1918; Wassermann test negative. Total excision of the clavicle was performed by Dr. Hitzrot. A microscopic examination of the tumor by Dr. Ewing showed it to be a myeloma. Five *x*-ray treatments were given in the region of the clavicle after operation as a prophylactic.

Trauma. In my own series of cases of sarcoma of the clavicle there is a history of antecedent local injury in such a large proportion of the cases that it is very difficult not to believe that trauma is an important etiologic factor in the disease. The nature of the injury varies between a strain and a blow: Case I, severe strain, tumor developing in three weeks. Case IX, fall; local injury to the clavicle; tumor in three weeks. Case VIII, shortly after a severe strain of the shoulder from cranking a car. Case VI, no trauma. Case III, is a good example of acute traumatic malignancy, inasmuch as the tumor developed two weeks after striking the clavicle upon the sharp corner of a wooden box. Case VII, severe strain, tumor two months afterward. Case VII, carrying a heavy steel bar directly over the clavicle, some distance. One month later a tumor developed at the exact site. Case XVIII, severe strain from swinging off a trolley car while in motion; tumor one month later. Case XVI, tumor at site of a fracture which had occurred one year before. Case V, injury to shoulder (fracturing clavicle and scapula) two months before. Case XI, severe bruising of shoulder while carrying steel bar, due to helper's dropping the other end. Tumor two to three weeks later, at the site of the injury. Case II, plank fell over and struck patient on left clavicle six to seven years pre-

viously. Case X, no history of trauma, but tumor developed ten days after an attack of acute influenza.

Johansson states that the great majority of these tumors are sarcomata. A very rare but interesting group of bone tumors, from a pathologico-anatomical point of view, are the so-called endotheliomata. Howard and Crile, in 1905, had collected 23 such cases, and Johansson's statistics includes two additional cases probably belonging to this group.

The so-called strumametastases form another very rare type of bone tumors. Four of these are kncwn to have occurred in the clavicle and were treated by extirpation. Histologically, they present the characteristics of adenoma. The primary tumor may be a carcinoma, Johansson states, or more rarely, also an adenoma. In a few instances no struma at all could be found; the thyroid gland was atrophic. I do not believe there has been reported a single undoubted case of primary carcinoma of the clavicle—in some cases the primary tumor was not.

Johansson reports the following three cases of malignant disease of the clavicle, two of which were operated upon at the Sabbatsberg Hospital:

Case I.—A. J., female, aged sixty-eight years; 1903. In March, 1901, patient fell and sustained a supracondylar fracture of the left humerus. In February of the following year she again fell and fractured the arm immediately above the old fracture. *X*-rays at the time had shown no suspicion of a tumor. Good union of fracture within normal time. Good apposition and function of arm. Toward the end of the same year, patient noticed swelling at the site of the fracture, accompanied by some pain. Readmitted to the hospital on February 5, 1903. Examination at this time showed a large tumor occupying the lower half of the left humerus. Diagnosis: *Osteosarcoma*. Exarticulation of humerus. Primary union. Two weeks later, swelling of right shoulder. Examination shows a tumor, nearly half the size of a hen's egg, at the acromial end of the right clavicle. Microscopical examination: Spindle-celled sarcoma, small cells. Patient discharged from hospital March 28, 1903. Death five

years later, March 2, 1908, of catarrhal enteritis. The report states that she was able to use her right arm perfectly well, and that there was no sign of a recurrence. No autopsy.

CASE II.—U. F., female, aged sixty-seven years; 1911. Patient ascribes trouble to trauma, a friend having repeatedly struck her with a board—in fun. Examination at time of admission, July 12, 1911: Firm tumor palpable over outer third of right clavicle, size of a hen's egg, attached to the bone. Diagnosis; peripheral sarcoma. July 15, extirpation of clavicle; no enlarged glands. Microscopic examination, spindle-celled sarcoma. About five months after operation, marked loss of weight, considerable coughing and pain in chest. Death of cachexia January, 1912.

CASE III.—O. B. (Military Hospital, Seraphim), male, aged fifty-eight years; 1888. Slight injury to clavicle a year ago; sensitiveness at site of injury three weeks later, swelling within one month. This grew slowly at first, then increased more rapidly in size until at time of operation, beginning of August, it had reached the size of a fist, attached to the bone; no enlarged glands. Total extirpation of clavicle plus upper right point of sternum; discharged November 19, 1888. No traced. Microscopic examination: Chondrosarcoma.

Johansson gives a brief résumé of 32 cases of tumor of the clavicle previously reported but not contained in any of the lists of collected cases so far published (see table). He also gives the references of six additional cases, stating that the respective journals were not available.

Only 3 of a series of 62 cases of bone sarcoma observed at the Sabbatsberg Hospital from 1879 to 1911 were sarcomas of the clavicle.

Age and Sex. Of 84 cases regarding which statements as to age and sex were found, 51 were males, 33 females, or about 60 per cent. of males.

Sarcoma of the clavicle is most frequently observed at the age of puberty, the eleventh to twentieth year of life. Nearly 60 per cent. of the cases occur in patients below the thirtieth year.

Localization. Statistics show the cases of malignant tumor of the clavicle to be about evenly divided between the right and the left side. Thirty occurred in the sternal end of the clavicle; 18 in the acromial end; 10 in the middle portion, and 4 involved the entire clavicle.

Three cases of metastatic sarcoma of the clavicle are on record, namely, Besson's case, in which nine years before a resection of the upper jaw had been done; Johansson's case here reported, in which the primary tumor originated in the humerus, and Jones' case, in which the original tumor started in the tibia, causing a fracture.

The desire to know whether we are dealing with a comparatively benign or a highly malignant tumor in a given case has become more pronounced since the conservative treatment of bone sarcomas, as first proposed by Mikulicz, has been gaining ground. That histological examinations are not always reliable in this respect no doubt most surgeons have had occasion to observe.

Johansson states that Ribbert and Borst have greatly advanced the study of the histology of bone sarcoma by their recent contributions to the subject. The former considers all sarcomas of the bones as originating in the spongiosa of the diaphyses, which theory seems to find support in the great significance of the *x*-rays as regards determining the degree of malignity of the tumors.

Borchard, on basis of Borst's investigations, distinguishes between a central group—from which he excludes and forms into a separate group the so-called myeloid tumors—on the one hand, and an inner or outer periosteal group—according to whether they start from the inner or outer layer of periosteum—on the other hand. In the former case they are surrounded by a bone shell.

Of the 30 cases of sarcoma of the clavicle compiled by Johansson, 9 were resections, 15 total extirpations. Of the remaining 6 cases of malignant tumor of the clavicle, 5 were treated by total extirpation, 1 by resection.

Mortality. Delatour gives the operative mortality as 18 per cent. (40 cases); Caddy, 16 per cent. (42 cases); Johansson's

collection of 31 cases operated upon (25 sarcomas) shows no mortality. The mortality on basis of 87 cases would, therefore, be 11.5 per cent. Johansson believes, however, that this percentage is too high an estimate, inasmuch as at least 3 of the cases should be excluded, namely, v. Langenbeck's and Heath's cases in which death was due to a brain tumor; and Segond's case in which visceral metastases were the cause of death. Deducting these, the above figure would be reduced to 8 per cent. Then also allowance should be made for the fact that a number of these fatal results occurred in pre-antiseptic times.

Accepting the time limit of four years, which is the latest period at which recurrences have been observed, Johansson states that only 4 cases were found to have remained free from recurrence, 1 of these (Mott's famous case) fifty-five years, another ten years, and two others upward of five years. Three of these were central sarcomas. To these should be added the Vaughan case well eighteen years, which makes 5 cases cured by total excision in a series of 90 cases.

Functional Result. Experience has shown that the functional value of the arm after extirpation of the clavicle is but little impaired in most cases. In 21 of Johansson's 36 collected cases mention is made of the functional result, and of 20 this is stated to have been good or very good. The deformity, also, is generally given as slight.

Kalus made a careful study of the literature up to 1912, which showed a total of 98 cases, 92 of which were stated to be sarcoma. He reports two cases operated upon at the Greifswald Clinic, one an osteosarcoma, the other an adenocarcinoma, which was considered to be metastatic, although the seat of the primary tumor could not be determined at the time of the operation.

In the first case (osteosarcoma of right clavicle) resection of a piece 7 cm. long was done, with Gigli's saw and bone transplantation from tibia added. The patient, a woman forty-seven years of age, was operated upon on September 18, 1910, and discharged on October 24. Six months later she returned complaining of severe pain in the right clavicle. Examination showed the presence of pseudoarthroses at the junction of clavicle and

transplanted bone. The pain is apparently due to the wire sutures. A second operation is done and the patient is dismissed on April 10, 1911, with free use of the arm, although the pseudoarthrosis persisted. There is no deformity at the site of operation. A report obtained from the local physician nine months after the second operation, states that the patient complains of pain at the site of operation and inability to use the arm for any length of time. There are no enlarged glands; no signs of a recurrence; general condition good.

In view of the splendid results obtained after resection or total extirpation of the clavicle, without bone transplantation, Kalus believes this an entirely unnecessary procedure.

Case II.—Male, aged sixty-two years. In August, 1911, laid a heavy beam upon his left shoulder in order to lift a wagon; pain and swelling followed. Was treated by physician with salve. In September was able to resume his work as mill worker. Two weeks later return of swelling, little pain, but limitation of motion of left arm. Later some loss of weight. Admission to the Greifswald Clinic November 1, 1911; operation on November 7. Removal of tumor which was the size of a man's fist; considered metastatic; primary tumor not found. Uninterrupted wound healing. Discharged December 16, 1911. Head of humerus prominent on account of absence of clavicle; active abduction in shoulder-joint; active elevation anteriorly greatly limited; rotation around axis of brachium but little interfered with. The patient was reported to have died of cachexia in the middle of September, 1912 (opening of esophagus into the stomach). Autopsy had shown a primary carcinoma of the cardia with numerous metastatic nodules in the liver.

Kalus believes this to be the first reported case of carcinoma of the clavicle which was recognized as metastatic at the time of the operation, the seat of the primary tumor (cardia) being revealed later at autopsy. I have observed two cases of secondary carcinoma of clavicle but did not operate upon either. Aimes and Delord (*Progrès Médical*, Paris, April 24, 1920, xxxv, No. 17, p. 81) found 98 cases of sarcoma in 126 cases of tumors of the clavicle.

In view of the case already referred to, that of Pinch of the Radium Institute of London, complete disappearance and apparent cure of a sarcoma of the clavicle by a single treatment with radium alone, the patient remaining well for five years—a very important question naturally arises, *i. e.*, shall we give radium treatment or toxin treatment, or a combination of both, before excision, or, shall we excise the clavicle and use the treatment, singly or combined, after operation as a prophylactic against recurrence? I have never used the toxins in operable cases of sarcoma except in such cases where operation meant the sacrifice of the limb. In sarcoma of the clavicle, the loss of the clavicle cannot in any sense be regarded as analogous to the loss of a limb. The single brilliant success of Pinch, in which no operation was performed, is offset by the Memorial Hospital case, in which radium was tried in preference to operation, with rapid generalization of the disease and a disastrous end-result. Personally, I would strongly hesitate to use radium alone, or with toxins, in any operable case of sarcoma of the clavicle, for fear that early metastases of the lungs might develop while watching the usual rapid and remarkable local disappearance of the tumor. If the clavicle were of great importance to the patient, like one of the bones of the arm or leg, I would take the chance of trying to save it by the use of toxins and radium before operating; but our own results as well as those that have been reported by other men, show that the functional use of the arm is practically normal after total excision of the clavicle and the deformity is so slight as hardly to be regarded.

In 87 cases of sarcoma of the clavicle in which the sex was noted, 49 occurred in the male, and 38 in the female, the greater number in the male being probably accounted for by the fact that the male is much more exposed to injury than the female.

As regards the age of the patient at the time the sarcoma was first noticed, our statistics show that by far the greatest proportion occurred in youth or early adult life, *e. g.*, 1 at birth; 5 between the ages of one and ten years; 29 between the ages of eleven and twenty years; 17 between the ages of twenty-one and thirty years;

16 between the ages of thirty-one and forty years; 12 between the ages of forty-one and fifty years; 10 between the ages of fifty-one and sixty years; 6 between the ages of sixty-one and seventy years; 1 over the age of seventy years.

As regards the site, as far as known 39 occurred on the right side and 33 on the left; in 41 cases at the sternal end, 16 at the middle, 18 at the outer, and in 1 case both clavicles were involved.

Regarding the duration of the disease, our statistics show 9 cases less than one month; 2 cases less than one month; 4 cases less than two months; 9 cases less than three months; 1 case less than four months; 3 cases less than five months; 7 cases less than six months; 6 cases less than seven months; 2 cases less than nine months; 4 cases less than one year; 2 cases less than one year and two months; 2 cases less than one year and six months; 7 cases less than two years; 1 case less than four years; 1 case less than five years; 1 case less than seven years; 1 case less than nine years; 1 case less than twenty years.

My own series of cases show a definite history of trauma in 12; no trauma in 3; and not stated in 3 cases.

In the total number of tabulated cases, 108, the disease was too far advanced for operation at the time of observation in 10 cases; and in 56 cases total excision, or practically total excision, was performed.

It is worthy of note that only 5 patients out of 80 treated by total or partial excision of the clavicle are known to have remained well beyond four years, while 3 out of 4 patients treated by the mixed toxins of erysipelas and B. prodigiosus as a prophylactic after total excision are alive and well from six to twelve years.

CONCLUSIONS

1. Malignant tumors of the clavicle are comparatively rare, only 16 cases having occurred in upward of 275 cases of sarcoma of the long bones personally observed. The greatest number belong to the sarcoma group, the few cases of carcinoma being

metastastatic developments from some recognized or unrecognized primary focus.

2. Sarcoma of the clavicle occurs more frequently in men than in women, probably due to the fact of the greater liability of the clavicle to injury in the male than in the female.

3. Sarcoma of the clavicle in the great majority of cases is associated with recent, antecedent, local trauma, either in the form of a direct blow or severe muscular strain.

4. *Diagnosis.* A clinical history of pain and localized swelling of the clavicle usually following recent injury, with rapid increase in size, supplemented by a fairly characteristic *x*-ray picture, will usually make an early diagnosis comparatively easy without the necessity of an exploratory operation.

5. *Treatment.* Local removal of the tumor or even a limited, partial resection should be avoided. The treatment of choice, while the tumor is in an operable stage, should be:

(*a*) Total excision of the clavicle as soon as the diagnosis is made.

(*b*) As soon as possible after operation, a course of systemic treatment with the mixed toxins of erysipelas and bacillus prodigiosus should be begun and continued for a period of at least six months. When possible this should be supplemented with local or regional treatment with radium or *x*-rays.

6. The mortality of total excision of the clavicle under modern technic is so small as to be practically disregarded and the functional use of the arm remains unimpaired.

TABLE OF REPORTED CASES OF SARCOMA OF CLAVICLE.

No.	Reporter.	Date.	Reference.	Sex.	Age.	Side	Site.	Duration	Description.	Operation.	Type.	Result.	Final report.	Remarks.
1	Mott	1829	Am Jour. Med. Sc., 1828, iii, 100	M	19	L	Beneath and adherent to clavicle	...	Size of two fists	.....	Osteo. with ulceration	Recovery	Well 50 years.	
2	Warrrn	(1832) 1837	Surg. Obs. of Tumors, p. 405	M	24	R	Inner end	...	...	Total excision	Pulsating	....	.....	Died of pleurisy 4 weeks after.
3	Travers	1838	Med. and Surg. Tr., xxi, 135	M	10	L	Inner end	1 year	...	Total excision	Osteo.	Recovery	Well 6 mos.	Trauma.
4	Liston	1844	Lancet, p 361	M	..	..	.....	...	...	Total excision	Soft	Recovery	Recurred in 3–4 mos.	
5	Chaumet	1849	Gaz. Méd. de Paris	F	18	L	Outer	9 mos.	Size of fist	Resection of external four-fifths	.....	Recovery		
6	Gallardon	1847	Gaz. des hôp.	F	45	..	Middle, sternum, 1st rib	...	...	No operation	Vascular pulsating	....	.....	Died of bronchopneumonia.
7	Rigaud	1850	Gaz Med. Strasburg. A. X, p 103	F	15	L	Inner	7 years	Size of fist	Resection of inner two-thirds	....	Recovery		
8	Owens	1854	New Orleans Med. and Surg. Jour., xi, 164	F	35	L	Inner	1 year	Egg	Excision, one-half	Osteosarcoma	Recovery	Well on tenth day	Final results not traced.
9	Langenbeck	1855	Deutsch. Klin.	F	11	L	Both ends	...	...	.....	Spindle-cell	Died on 6th day		
10	Syme	1857	Edin. Med. Jour., Pt. I, iii, 192	F	20	..	Outer end	...	3½ x 4½ cm.	Total excision	Osteo.; myeloid cells; cystic	Recovery		
11	Cooper	1858	Gaz. de hôp.	..	..	L	.....	...	...	Total resection.				
12	Esmärck	1859	Nissen. Diss. de resect. Kiliae	M	33	R	.....	...	Size of a hen's egg	.....	.....	Recovery	Recurrence; died in 4 yrs.	
13	Nélaton	1860	Thésis de Paris	F	46	R	Inner end and sternum	2 yrs.	...	.....	Myeloid	....	.....	Died of bronchitis.
14	Gosselin	1861	Bull Soc. de Chir, 2d series, vol. ii	M	37	R	Inner third	...	Size of a lemon	Resection of inner third	Fibrous elements	....	.....	Fracture.
15	Pean	1861	Gaz. de hôp., p. 419	M	37	..	.....	...	Size of a citron	.....	Spindle-cell			
16	Nélaton	1863	Bull. Soc. Anat., 2d series	F	30	..	Middle	...	...	.....	Fibrous and fibroplastic			
17	Richet	1864	Dict. de Med. et de Chir. Pratiq., viii	M	65	R	Inner third	2 years	...	Resection of inner third	Myeloid	....	Recurred 18 mos. after in scar	

18	Paquet	1867	Bull. de la Soc. Anat., p. 634	M	21	R	Inner end, sternum, 1st rib	6 mos.	12 x 8 cm.	No operation	Embryonic and myeloid	....	.....	Died.
19	Delore	1868	Gaz. Med. de Lyon, iii, 93	..	..	..	Inner end	...	...	.....	Medullary carcinoma	Recovery	....	Doubtful.
20	Morin	1868	Ibid.	..	Child	..	.....	...	...	.....	Carcinoma	....	....	Doubtful
21	Meyer	1868	Gaz. Med. de Lyon, No. 8, p. 93	..	..	..	.....	...	...	.....	.....	....	.....	Doubtful.
22	Sean and Eve	1869	Chicago Med. Exam., x, 653	M	12	L	End	14 mos.	...	Total excision Vein injured at operation	.....	....	.....	Cervical glands enlarged; died from exhaustion.
23	Cooley	1870	St. Louis Med. and Surg. Jour., p. 62.	M	30	L	Middle	...	...	.....	.....	Recovery		
24	Britton	1870	British Med. Jour., i, 518	M	35	L	Outer end	2 yrs.	Size of an orange	Resection of all except acrom. end	.....	Recovery		
25	Eve	1871	Nashville Jour. Med., and Surg., i, 68	M	13	L	.....	7 mos.	Size of an ovary	.....	Enchondroma (red, flesh-like)	Died	.....	Doubtful; spontaneous fracture.
26	Richet and Demondre	1873	Paris Thésis	F	51	L	Outer end	3 mos.	Size of an orange	Resection of outer end				
27	Tausini	1883	Gaz. degli Ospitali, Milano, No. 39, p. 306	F	30	..	Inner end	...	Size of an egg	.....	Myxedema	Healed in 15 days		
28	Deprès	1885	Bull. de Soc. de Chir., pp. 143–226	F	14	R	Outer end	...	Size of an orange	.....	Central	In hospital 31 days		
29	Segond	1885	Ibid.	M	66	..	.....	...	...	.....	.....	Died on 8th day of visceral involvement		
30	Polleaillon	1885	Bull. de Soc. de Chir., p. 146	M	16	R	Outer end	18 mos.	Size of fist	Resection of external ¾	.....	Recovery	Well 3 mos.; died of sarcoma of femur	
31	Kronlein and Ritter	1885	Inaug. Diss. Zurich.	F	17	L	Central part	...	...	Total resection	Periosteal; round-cell	....	Prompt recurrence; well 10 yrs.	
32	Wheeler	1885	Tr. Acad. Med. of Ireland	M	43	L	.....	...	...	.....	.....	....	.....	Slight blow; phthisis; imp. well 10 yrs. later.
33	Sloan	1887	Am. Jour. Med. Sc., p. 485	M	14	R	.....	...	...	.....	Carcinoma (?)	....	Recurred 6 mos. after	Doubtful.
34	Heath	1888	Lancet, i, 721	M	30	L	Outer end	3 yrs. 10 mos.	..	Excision	Spindle and round-cell	Seven days after operation developed br symptoms	Died on 11th day.	

TABLE OF REPORTED CASES OF SARCOMA OF CLAVICLE—CONTINUED.

No.	Reporter.	Date.	Reference.	Sex.	Age.	Side.	Site.	Duration	Description	Operation.	Type.	Result.	Final report.	Remarks.
35	Chiene	1888	Lancet, vol. i	F	15	..								
36	Wauscher	1889	Hosp. Tiden de Kopenhagen, Feb., i, 310	M	18	..	.....	...	...	Excision	Myelogenous	....	Soon recurred	
37	Rouse	1889	Lancet, i, 575	M	29	..	Inner end	6 wks.	Size of an egg	Resection of inner ⅔	.....	Died of sepsis	.....	Vein injured.
38	Jesset	1889	Lancet, p. 1077	F	18	R	Inner end	...	...	.....	.....	Healed in 2 mos.		
39	Harlam	1863	British Med. Jour., p. 848	M	31	..	.....	...	...	.....	Periosteal; round-cell	Primary union	Well 5 mos.	
40	Garre-Norkus	1893	Beitr. zur klin. Chir., vol. ii	F	31	R	Outer end	1 yr.	2 in. long	Total excision	Myeloid; pulsating	Immediate recovery	Well 5 yrs.	
41	Curtis-Norkus	1893	Am. Jour. Med. Sc., xxxiv 350	F	20	L	.....	5 yrs.	...	.....	Osteosarcoma	Recovery	.....	Probably syphilitic.
42	Legueu	1895	Bull. Soc. Anat.	F	24	..	.....	3 mos.	Nut	Total excision	.....	....	.....	Pulmonary tuberculosis.
43	Courtin	1897	Gaz. Hbd. des. Sc. Med. de Bordeaux, vol. xviii	F	Birth	L	Middle and inner end	...	...	.....	Osteo.	....	Lived 1 mo.	
44	Verstraete (Operator Duret)	1898	Jour. de Soc. Med. de Lille, vol. i	M	46	R	Middle and inner end, 1st and 2d ribs	7 mos.	Size of an orange	Total reection	Subperiosteal; encapsulated	Recovery	Traced 1 mo.	
45	Besson (Operator Duret)	1898	Ibid, p. 466	M	39	R	External end	7 mos.	Size of an egg	Total excision	Myeloid; perosteal round and spindle myeloplexus	Recovery	Traced only 3 wks.	Operated on 9 yrs. before for sarcoma of superior maxillary
46	Flament	1898	Ibid., vol. ii	M	10	R	External ⅔	1 mo.	Size of an egg	Resection of external ⅔	.....	Recovery	Well 1 mo.	
47	Bourg	1902	Paris Thésis	M	45	R	Middle and inner end	2 yrs.	Size of an orange	Total resection				
48	Jonnesco	1903	Bull. et mém. Soc. de Chir. de Bucarest, vi, 253	..	..	L	.....	...	...	Total resection	Osteo.	Recovery		
49	Degonville	1904	Paris Thésis	M	50	L	Middle third	2 yrs.	...	.....	Myeloid and round cell	....	.....	Fracture; multiple fractures of ribs; died before operation; weighed when removed 1600 grams.

50	Kryukoff	1904	Russk. Vrach., St. Petersburg, iii, 775	F	12	R	.....	...	...	Total resection	Round cell			
51	Buteanu	1905	Bull. Soc. de méd., et Nat. de Jassey, xix.	..	..	..	....	...	...	.....	Osteo.			
52	Coley	1909	Am. Surg., 1910 (Coley)	M	16	L	Middle portion, myelogenous, round-celled	6 wks.	Size of an English walnut	Total resection followed by toxins	Periosteal	Recovery	Well at present, 1910; 1 year later	Toxins almost immediately after operation
53	Huntington, Thos. W.	1908	Ibid.	M	39	R	Outer and middlethird	2 yrs.	English walnut in size	Total resection followed by toxins (Coley)	Spindle-celled periosteal	Recovery	Well 2 yrs.	Followed a blow.
54	Gilbert Barling, Birmingham, England; personal communication.	1889	Unpublished Ibid.	M	33	..	Inner half	Several months	...	Resection total	Spindle-celled	....	Died on 4th day from suppuration of mediastinum and pleurisy	Fracture through middle of bone.
55	Ibid.	1901	Ibid.	F	10	L	Middle and inner portion	...	...	Total excision	.....	....	Recurred 9 mos. after in scar; died a few mos. later.	
56	Richardson, M. H.; personal communication (Coley)	1908	Ibid.	M	34	L	Middle and inner third	4 mos.	...	Total excision followed by toxins (Coley)	Small, round-celled	Recovery	Well 2 years and 2 mos.	Plank fell over striking patient on left clavicle.
57	Hartley, Frank	1909	Ibid.	M	19	L	.....	2 yrs.	...	Total excision	.....	Recovery	Recurred in 3 mos in side of chest	Tox. then used; temporary; an improv. only.
58	Keen, W. W. (Coley)	1898	Ibid.	M	21	..	.....	...	...	First operation partial; second interscapular thoracic amputation; toxins	.....	Recovery	Died 8 mos. later, from recurrence	
59	Bodine (Coley)	1906	Ibid.	M	8	R	.....	3 mos.	...	First, lancing of abscess; second, partial removal of tumor	Periosteal; round-celled	....	Death in a few mos.	Received blow Oct., 1905.
60	Warren, J. Collins (Coley)	1902	Ibid.	M	46	L	.....	6 mos	...	No operation; toxins; x-ray	Periosteal; round-celled	....	Died 1 year later	Trauma; dislocation of shoulder.
61	L. L. College Hospital (Coley)	1909	Ibid.	M	78	L	Inner third	1 wk.	...	Operation; partial removal of clavicle	Rapid growth	Recurrence week later in suprasternal fossa; toxins then given with but little benefit	Died in 1 yr.	Strained shoulder.

TABLE OF REPORTED CASES OF SARCOMA OF CLAVICLE—CONTINUED. (Most of the following cases were collected by Johansson.)

No.	Reporter.	Date.	Reference.	Sex.	Age.	Side	Site.	Duration.	Description.	Operation.	Type.	Result.	Final report.	Remarks.
62	Stewart (Coley)	1910	Ibid.	M	20	L	Outer third	2 mos.	Tumor size of English walnut, outer end of clavicle	Operation; Dr. Stewart, Newport, R. I., March, 1910 (excision)	Periosteal; round-celled	Recurrence 3 wks.; very rapid growth	Mixed toxins (Coley) Sept. 15 to Oct. 15, 1910; no effect on very large tumor	No single trauma, but habitually carried iron pipes and heavy material on left shoulder. Died.
63	Coley	1898	Ibid.	M	31	R	Outer end	9 mos.	Tumor of enormous size	General conditions very bad; prognosis, few wks of life	No operation	No treatment		
64	Johansson	1903	Deutsche Ztschr. f. Chir., 1912	F	68	L	Acromial end secondary to osteo-sarcoma of hu-humerus	Few wks. after ex-articu-humerus f. osteo-sarcoma	Size of half a hen's egg	Extirpation of clavicula	Spindle-celled sarcoma; small cells	Good	Death 5 yrs. later of enteritis—no sign of recurrence	Fractured humerus twice; osteo-sarcoma exarticulation of humerus.
65	Ibid.	1911	Ibid.	F	67	R	Outer third	6 mos.	Size of a hen's egg; hard, trauma	Extirpation of clavicle	Spindle-celled sarcoma	Fair	Six mos. later death from cachexia.	
66	Ibid. (military hospital)	1888	Ibid.	M	58	R	Sternal end	...	Trauma swelling 1 mo. later	Total extirpation	Chondro-sarcoma	....	Not followed up	
67	Smith, J. W.	1902	British Med. Jour., 1902, i, 270	M	18	L	Outer two-thirds	5 mos.	Trauma	Total excision	Chondro-sarcoma	Good	Recurrence 1 year later	Death.
68	Barton	1874	Dublin Med. Jour. of Med. Sc., 1874, i, 92	F	24	L	Below left clavicle near sternal end	Little over a year	Size of cocoanut	Inoperable	*Medullary cancer	No operation	Death; duration of life, 2 yrs.	Autopsy showed metastases of lung and right humerus.
69	Jones	1880	Tr. Path. Soc., Lond., 1880, xxxii, 242	F	45	L	Primary in tibia, metastases in parietal bone and clavicle, sternal end	...	No trauma	No operation	Sarcoma			
70	Sansom	1884	Lancet, 1884, i, 963	M	40	R	Supraclavicular fossa, extending into axillary cavity	5 mos.	First noticed swelling of rt. shoulder and arm started in middle of clavicle	No operation	Mixed-celled sarcoma periosteal	....	Death	Autopsy showed metastases in kidney.

* Almost certainty sarcoma from description of case.

71	Lunn	1886	Tr. Path. Soc. Lond., 1886, xxxviii, 287	M	64	R	Right clavicle	2 wks.	Large tumor starting in periosteum	No operation (inoperable)	.....	....	Death	Autopsy showed nodules in surface of liver.
72	Sutton	1890	Lancet, 1890, ii, 821	F	26	R	Acromial half	...	...	Resection of acromial half	Myelogenous	Excellent	.....	Not traced.
73	Ollier	1891	Traité des Resections, 1891, iii, 895.	F	42	..	Sternal end	...	"Pulsating tumor"	Resection of sternal end	.....	Only fair	Death after 2 years	Nothing stated; recurrence.
74	Caddy	1892	New York Record, 1892, xliii, 586	M	26	R	Sternal end	Trauma 1 year ago	Trauma	Resection of inner two-thirds	Periosteal spindle-celled	Good	6 mos. later no recurrence	
75	Gibb	1895	Glasgow Med. Jour., 1895, xliv, 301	F	16	L	Sternal end	10 mos.	Large tumor sternal end	Resection of inner third	Spindle-celled	Good	Local recurrence 15 mos. after operation	Death.
76	Delatour	1896	Ann. of Surg., 1903, vol. xxxvii	M	37	L	Middle of clavicle	3 mos.	Trauma	Excision of clavicle after recurrence	"Osteosarcoma"	Very good	No recurrence three years later	
77	Delatour	1897	Ibid.	F	20	R	Acromial end	2 mos.	No trauma	Excision of entire clavicle	Osteosarcoma	Good	Not known.	
78	Delatour	1897	Ibid.	M	55	..	Sternal end	3 mos.	Trauma	Excision of sternal end of clavicle plus piece of sternum and of first rib	Sarcoma	Complete use of arm	4 mos. later fracture of base of skull	No evidence of return of tumor.
79	Vaughan	1898	Med. News, January 8, 1898	M	28	R	Inner ⅔ of clavicle	7 mos.	Large hard tumor	Removal of entire right clavicle with tumor	Mixed-celled, round and spindle	Excellent	Perfectly well 18 yrs. later	Personal report from Doctor Vaughan.
80	McBurney	1898	Ann Surg., xxviii, 259	M	Young	L	Sternal end	18 mos.	...	Total excision	Osteosarcoma	Almost normal	Not known	
81	Curtis	1898	.....	M	37	L	.....	Trauma 9 years ago	Trauma 9 years ago	Total excision	Osteosarcoma	Good	1 year later operation for metastasis in 7th rib of left side	Further history not known.
82	Beatson	1902	British Med. Jour., 1902, i, 129	F	16	..	Sternal end	7 mos.	No trauma	Total excision	Angiosarcoma round-celled	Almost normal	No recurrence 2 yrs. later	
83	Smith	1902	British Med. Jour., 1902, i, 720.	M	35	R	Sternal end	5 mos.	Trauma	Total excision	Chondrosarcoma	Good, little deformity	Free from recurrence when last seen, 13 mos. after operation	
84	Carson	1904	Am. Pract. Surg., vi, 420	F	18	R	Sternal end	6 mos.	No trauma	Total excision	Sarcoma	....	Not known	

TABLE OF REPORTED CASES OF SARCOMA OF CLAVICLE—CONTINUED.

No.	Reporter.	Date.	Reference.	Sex.	Age.	Side.	Site.	Duration.	Description	Operation.	Type	Result.	Final result.	Remarks.
85	Vogel	1908	Med. Klin, 1908, i, 286	M	27	R	Outer half	2 mos.	Trauma 7 mos before; size half of hen's egg	Resection of outer two-thirds bone transplanted from tibia	Round-celled sarcoma	Good	Well 2 years later, no recurrence	Transplanted bone was soon pushed off.
86	Jordan	1908	Deutsch. med. Wchnschr., 1908, i, 175	F	8	L	.....	...	...	Total excision of left clavicle, piece of scapula and 1st rib	Round-celled sarcoma	Good	Well and free from recurrence 7 mos. later.	
87	Roith	1908	Deutsch. med. Wchnschr., 1908, i, 175	F	17	..	Medial portion	...	Size of goose egg	Total excision	Cystosarcoma	Good		
88	Piperata	1909	Deutsch. Ztschr. f. Chir, 1909	M	74	L	Sternal portion	3 mos.	...	Resection of sternal end	Chondrosarcoma	....	Death after 3 years	Cause not stated
89	Piperata	1909	Bd. 102, p. 195	M	19	L	.....	7 mos.	...	Resection of left clavicle with tumor	Spindle-celled sarcoma	....	Death within a few mos.	Partly local recurrence, partly metastases.
90	Piperata	1909	Ibid.	F	23	..	.....	5 mos.	Inoperable	No operation	Sarcoma	....	Died within 10 months	
91	Ganduchean et Masson	1909	Bull. et mém. Soc Anat de Paris, 1909, p. 61	M	54	..	Middle portion	6 mos.	No trauma—size of walnut	Type of operation not stated	Periosteal round-celled sarcoma	Not stated	Not stated.	
92	Patel	1910	Lyons Méd., 1910, p. 715	M	24	L	Middle portion of left clavicle	3 mos.	Size of hen's egg	Total excision	Sarcoma osteides	Excellent, hardly noticeable defect	Not stated	Wassermann positive Hg. J. R. treatment; tumor increased in size steadily.
93	Wilson	1911	Lancet, 1911, i, 1422	F	11	..	Inner half	...	No trauma	Reaction of inner half	Sarcoma probably periosteal mixed-celled	Good	Free from recurrence 7 mos. later	
94	Schmidt	1906	(Ref. Annual Rep.)	F	57	..	.....	...	Grown into deltoid muscle, thyroid structure	Excision of clavicle	Tumor of the thyroidal structure	Good result	.....	Thyroid not enlarged.
95	Halperine	1908	(Ref. Guibé)	M	54	..	Outer end	20 years then trauma	More rapid growth after trauma; size of fist	Total excision	Thyroidal structure; struma present	....	.....	Grew rapidly after trauma.

96	Guibé	1909	Bull. et mém. Soc. Chir. de Paris, 1909, p. 117	F	51	R	Outer third	...	No trauma pulsating tumor, size of a hen's egg; no glands	Exarticulation of inner and then outer half	Glandular tissue thyroidal structure	Very good	No recurrence a little over a year later	Thyroid gland atrophic.
97	Jaboulay	1909	(Ref. Annual Rep., 1909)	M	60	..	.....	...	Struma and struma metastases	Extirpation of clavicle; 2 wks. later partial removal of struma	Struma, metastases in clavicle; spontaneous fracture of bone	Good	Not known	
98	Suchard and le Clerc	1883	Rev. de Chir., 1883, iii, 618	F	62	R	Sternal end	6 mos.	No trauma, size of a hen's egg; pulsating	Total excision	Malignant tumor cystic epithelioma	....	No recurrence obs. 10 mos. later.	
99	l'Estar and Massabuan	1908	Rev de Chir., 1508, xxxix, 343	F	50	..	Outer two-thirds	...	...	Almost total resection	Lymphangioma.			
100	A. F. Bock	1894	St. Louis Med. Jour., 1894, p. 347	M	55	R	Sternal end	3 mos.	No trauma, pain severe	Removal of tumor large size	Large round-celled sarcoma	Survived operation	.....	Author expects very little benefit from operation.
101	A. T. Bristow	1898	Blyn. Med. Jour., 1898, p. 306	M	22	L	Lower border	2–3 wks.	Painful, size of duck's egg	Removal of clavicle	Fascial sarcoma later, osteosarcoma mixed, small round cells; no spindle cells	Excellent recovery	2 wks. observation O.K.	6 mos. before amputation of arm at shoulder-joint for osteosarcoma.
102	Jas. Thorburn	1883	Canadian Pract.	M	43	R	Above sternal half	9 wks.	Trauma carried poles; size of orange	Removal of tumor	Spindle-celled sarcoma, some round cells	Good	Recent observation	Also a tumor in lumbar region found—to be operated on later, present since childhood.
103	Küttner	1909	Allg. Med. Centralztg. p. 198	..	..	..	Sternal end	...	Size of fist, spontaneous fracture	Exarticalation sterno-clavicular joint	Spindle-celled sarcoma	Good functional result.		
104	Ibid.	Ibid.	Ibid.	..	..	..	Ibid.	...	Size of a hen's egg	Total excision	Osteo-chondro-mixed sarcoma	Good functional result		
105	Pinch	..	Personal communication	F	62	R	.....	4 mos.	10 x 6 x 2 cm.	Inoperable except by Berger shoulder-joint amp.; patient refused	Round-celled sarcoma	Treated by radium only	Complete disappearance	Well 5 years.

PERSONAL CASES OBSERVED BY THE WRITER SINCE THE TIME OF HIS LAST REPORT IN 1910

No.	Name.	Year.	Sex.	Age.	Side.	Site.	Duration.	Trauma and other data.	Operation or treatment.	Type	Result functional.	Final result.	Remarks.
1	B. F.	1918	M	49	R	Sternal half	8 wks.	Strain of shoulder, patholog fracture	Exploratory by other surgeon; later toxin and radium treatment	Large round-celled sarcoma	Temporary improvement only	Death in 6 mos.	Borderline case as regards operability.
2	C. A.	1918	M	57	R	Inner two-thirds	1¼ years	Strain of shoulder	Considered inoperable; toxins and radium (Coley)	.....	Temporary improvement only	Death, March 27, 1919, a year and 5 months after the injury	Borderline case.
3	T. M.	1912	M	12	R	Inner half	5 wks.	Trauma; size of hen's egg	Total excision, recurrence; then toxins 2 mos.	Periosteal small round-celled sarcoma	Recurrence after 10 days	Temporary improvement; death 5 mos. after first noticed.	
4	S. L.	1919	F	12	R	Sternal portion	1 mo.	Size of hen's egg	Radium	Periosteal	Local improvement, but generalization of disease	Death within 6 mos. from time tumor was first noticed	This case was operable when seen, but it was decided to use radium treatment alone.

REDUCTION OF OLD DISLOCATIONS OF THE HIP BY OPEN INCISION

By J. J. BUCHANAN, M.D.
PITTSBURGH, PA.

The exact time at which an unreduced dislocation of the hip becomes old cannot be definitely stated. If the possibility of reduction by external means be made the criterion, the period, for practical purposes, is too long, because reduction by manipulation or force has been accomplished in some cases many months after dislocation has occurred.

Reports of such cases, however, should not be accepted without close scrutiny, as investigations have shown that the records of many cases before the invention of the roentgen ray were of doubtful value.

Sir Astley Cooper's opinion was that after eight weeks it would be imprudent to attempt reduction of a hip dislocation. A better standard is the pathological condition present, and this is capable of more exact investigation, in the light of animal experiments and operations performed on human beings in recent years.

Such operations show that as early as four to six weeks the acetabulum is filled with shreds of capsule and newly formed connective tissue and the head fixed in its false position by tissue of the same kind.

Experiments[1] on dogs have shown that fourteen days after

[1] Volkmann: Deutsche Ztschr. f. chir., 1893–4, xxxvii, 373.

dislocation, soft, newly formed tissue usually fills the acetabulum. This tissue is much firmer in three or four weeks and eight or ten weeks after the dislocation the mass has become so hard that replacement is impossible without clearance of the cavity. It is true that these obstacles do not in all cases preclude reduction, but they furnish important reasons for its usual lack of success.

For the purposes of this paper, and because a definite time limit must here be placed, beyond which operated cases are considered old, four weeks has been decided on—earlier cases being considered recent.

Attempts at reduction by external manipulation and by forced traction have, from the earliest times to the present, been occasionally attended by disastrous results, such as fatal hemorrhage from rupture of the great vessels and fracture of the neck or shaft of the femur.

These accidents have been reported with sufficient frequency to bring manipulation and power traction into disrepute and to give rise, since the era of antisepsis, to the belief that open operation is much to be preferred.

The first attempt to effect reduction by open operation was by Delagarde in 1861.[1]

The original injury which had occurred five months before had been complicated by a double fracture of the same femur which had subsequently united. The head lay in the sacro-sciatic notch and caused intolerable pressure on the sciatic nerve. The head could not be restored to the socket, and was, therefore, excised. The patient was relieved both of his pain and disability.

The pathological anatomy of these cases was studied in the middle of the last century, notably by Malgaigne and Tillaux, who demonstrated on the cadaver the pathology which has since been found so uniformly in operated cases.

Fortified by this knowledge, and encouraged by the measurable success at that time of the Listerian system, a few attempts

[1] St. Bartholomew's Hospital Reports, 1866, ii, 183.

at open reduction were made in the late 70's, all of which failed and ended in resection of the head of the femur, with correction of the position of the limb so as to bring the stump of the neck near to or into the acetabulum.

In 1882 the first actual reposition of the head into the acetabular cavity was made by Polaillon. Unfortunately the patient died of gas bacillus infection on the fourth day. Since that time there have been found in literature reports of 47 additional operations. To these may be added a case, not hitherto reported, in the practice of Dr. O. C. Gaub, of Pittsburgh, and the writer's case herein detailed, making 50 in all.

The first operations in this country were performed by the late Dr. Charles T. Parkes, of Chicago, and reported by Dr. A. J. Ochsner, his assistant. He not only secured excellent results in his two cases but also showed the value of levers placed under the neck to lift the head back into its socket.

The only complete paper on this subject hitherto published in the English language was contributed to the *Annals of Surgery* in 1894 by Dr. M. L. Harris, of Chicago. His operation was a success and his paper is now a classic.

It has been possible for the author to secure from the literature 48 cases, which, with Dr. Gaub's and his own make up the 50 cases which appear in the tables.

Analysis of these cases will show that while open reduction in old hip luxations is usually difficult and not altogether devoid of danger it is the operation of choice.

In a very large proportion of cases it greatly improves the use of the limb and in very many restores its complete function. When reduction is impossible resection of the head may still be done to secure improved position of the limb. This operation, however, has a higher mortality and is followed by less perfect use.

Analysis of Cases in the Table. If assorted into decades it will be found that 3 open reductions were made in the 80's, 21 in the 90's, 20 in the first decade of the present century and only 6 reported in the last ten years.

The reason for the small number of cases reported in recent years is probably the general use of the roentgen ray, which has rendered this diagnosis easy even to those not skilled in surgery.

By countries it may be said that 13 of these patients were operated in the United States, 6 in France, 6 in Great Britain, 3 in Italy, 1 in Switzerland, 14 in Germany and 7 in Austria.

Sex and Age. There were 41 males, 8 females, and in 1 case the sex was not stated.

There were:

In first decade of life	12 cases.
In second decade of life	12 "
In third decade of life	6 "
In fourth decade of life	9 "
In fifth decade of life	6 "
Above the fiftieth year	3 "
"Adult"	1 "
Not stated	1 "
	50 "

This incidence of sex and age is not markedly different from that which obtains in large collections of recent dislocations. The chief difference is in the greater number of cases in little children whose dislocations if neglected are more amenable to reduction than those of adults and whose operations are less likely to terminate in resection of the head.

DURATION OF DISLOCATION

1 to 2 months	13 cases.
2 to 3 months	12 "
3 to 4 months	5 "
4 to 5 months	7 "
5 to 6 months	1 "
6 months to 1 year	8 "
1 to 4 years	3 "
16 years	1 "
	50 "

EARLY TRIALS AT REDUCTION

Fruitless efforts immediately after dislocation	11 cases.
No early trials made	17 "
No record of early trials	17 "
Trials made within first 4 weeks	4 "
Previously reduced by operation	1 "
	50 "

FORM OF DISLOCATION

Dorsal	34 cases.
Obturator	10 "
Sciatic	3 "
Upward	2 "
Not stated	1 "
	50 "

PATHOLOGICAL CONDITION PRESENT

Acetabulum said to have been filled with connective tissue in	38 cases.
Acetabulum said to have been empty in	1 "
Head and neck said to have been bound down by fibrous tissue in	11 "
Cartilage said to have been intact in	12 "
Rim of acetabulum said to have been broken in	3 "
Fracture of cup of acetabulum reported in	3 "
Fracture of pelvis in	2 "
Head pushed through obturator membrane in	1 "
Epiphyseal separation in	1 "

OPERATIVE TECHNIC

Incision. In 32 cases in which the location of the incision was definitely stated there were done by

Langenbeck's straight incision	11 cases.
Barker's anterior incision	8 "
Kocher's angular incision	7 "
White's posterior incision	2 "
Combined anterior and posterior incision	3 "
Goblet incision	1 "

Preliminaries to Reduction. In 4 cases the trochanter was chiselled through at the base, and after reduction had been accomplished was fixed back into place, once with screws and three times with silver wire. In 11 cases all muscular attachments were separated from the great trochanter, usually subperiosteally. In 30 cases it was noted that the acetabulum was emptied of its connective-tissue filling with scissors, knife or curette. In 1 case it was said to be empty. In 1 case the acetabular content was not removed and in it recurrence of the dislocation occurred. Tenotomy of the adductors was resorted to in 1 case and the chiselling of the rim of the acetabulum in another.

Reduction. The method of reduction is stated in a minority of the cases only. In 13 cases it was by manipulation; in 3 by levers and manipulation; in 2 by strong hooks and in 1 by pulleys.

Reduction is said to have been easy in 9 cases and difficult in 8; in the remainder of the cases no statement is made on this point, but, from the description of the operation, it would seem to have been difficult.

After-treatment. Most of the patients were treated by extension, abduction and external rotation, maintained by weight and pulley, with side splint or by a plaster-of-Paris dressing.

Mortality. Only 3 patients died (6 per cent.).

1. Case of Polaillon, in 1882, died on the fourth day from gas gangrene.

2. Case of Mikulicz, in 1895, died in six weeks from sepsis with pelvic infiltration.

3. Case of De Forest Willard, published in 1904, died in one week from septic endocarditis.

FUNCTIONAL RESULT OF OPERATIONS

Of the 45 cases reported on, 36 (80 per cent.) had good results and 9 (20 per cent.) had moderate improvement or poor results as follows:

Perfect result	8	cases.
Excellent result	9	"
Good result	2	"
Great improvement	1	"
Considerable improvement	2	"
Good function but limited motion	8	"
Good function, but hip anchylosed	4	"
Greatly improved, but anchylosed	1	"
Early report, but very promising	1	"
Some improvement, but anchylosed	2	"
Slight improvement	2	"
Poor function; hip anchylosed	2	"
Very poor result	2	"
Recurrence (reoperated)	1	"
No report	2	"
Dead	3	"
Total cases	50	"

Of the 9 cases in which the operation could not be considered successful, 1 was performed on a girl of twelve for a luxation of three years' standing; 1 on a child of ten for a luxation of two and a half years' standing; in 2 cases the suppurating head required excision some months later and in 1 there was long-continued suppuration, with peroneal paralysis.

Author's Case. The young man whose case furnished the motive for this paper is nineteen years old, a machinist by trade. He was injured September 20, 1918.

An automobile in which he was riding was struck by a train and "turned turtle." The patient was found pinned under it, unconscious. He was taken to a hospital in a neighboring town where he remained unconscious for ten days, probably from cerebral concussion. A diagnosis of fracture of the pelvis was made, which later roentgen-ray plates confirmed, and he was

kept in bed for nine weeks with Buck's extension on the limb. He remained in the hospital three months when he was dismissed and taken to his home. He remained at home six weeks and then returned to the same hospital and had roentgen-ray plates taken, after which an anesthetic was given and manipulation of the limb used, with no evident result. Two weeks later (February 21, 1919) he came to Mercy Hospital, Pittsburgh, on crutches, which he had been obliged to use constantly ever since he was allowed out of bed.

Physical examination showed the usual signs of backward dislocation of the hip; shortening (one and a fourth inches), inversion, adduction. There was, however, but slight flexion. The head could be felt to roll under the fingers in the ordinary place of a dorsal dislocation. He could not bear weight on the limb, owing to the sliding upward of the head on the dorsum of the ilium.

Roentgen-ray plates were made on February 28, which showed a dorsal dislocation of the hip, with a nearly transverse fracture at the junction of the shaft with the neck. The outline of the pelvis near the acetabulum was indistinct, as though from a fracture. The fracture of the femur had united in good position.

The patient was put to bed with Buck's extension, the traction being applied to the thigh only. After prolonged use of traction with heavy weights the most that could be gained was one-half inch additional length. Operation was decided on and preparation for efficient traction and manipulation at time of operation was made three days before the time set.

This consisted in the application of a strip of adhesive plaster of triple thickness applied to each side of the thigh, each strip having fixed in its lower end a harness ring as shown in the drawing.

Operation was performed on April 19, 1919. A Kocher incision was used. Towels were fixed to the wound edges to protect from skin infection. The incision was deepened until the margin of the acetabulum could be exposed. This cavity was

roofed over and filled with dense connective tissue and shreds of capsule.

All this tissue was dissected out with strong scissors exposing the normal cartilage. The fibrous tissue was then lifted and cleared from the anterior aspect of the great trochanter and neck until the cartilaginous margin of the head was reached.

The pelvis was firmly fixed to the table by a band of webbing passing over it; the lower leaf of the table was dropped, permitting the patient's right knee to be flexed and the leg to hang.

The webbing surcingle was then adjusted to the assistant, Dr. H. G. Kuehner, passing over his left shoulder, diagonally across his back and under his right axilla, each end being furnished with a harness snap which snapped into its corresponding

harness ring above the patient's knee. The surcingle had by previous trial been adjusted to the proper length. Dr. Kuehner then passed his right forearm under the patient's left flexed knee, and by standing on a low stool with his left foot and placing his right knee against the table was able to exert the most powerful traction, both using his arm as a hook and the weight of his body as a tractive force. He was able to change the direction and force of his pull at will, using any angle of flexion, adduction, abduction or rotation, according to the varying requirements of the operator.

So firmly were the head and neck entrenched in their bed of connective tissue that they could not be delivered until this tissue was cut away by the use of curved scissors passed behind the bone. Four levers were then passed under the neck, and, by their use together with the efficient manipulation and traction of Dr. Kuehner, the head was delivered to the margin of the acetabulum and then into its cavity.

The return of the head to its socket was marked by the characteristic click which indicates the reduction of hip luxation. This click could be heard across the room. After the head was in place there seemed to be no disposition for it to leave the socket. The external branch of the Y-ligament remained intact, but the internal branch had been separated.

The cavity left by replacement of the head was drained with a cigarette drain and rubber tube and the remainder of the incision closed with buried sutures of catgut and superficial ones of silk.

Toward the close of the operation the patient's pulse became weak and rapid, due probably to shock from the forcible manipulations and loss of blood, caused by the dissection of the bone from its bed. The hemorrhage was not great and was entirely from small vessels. Later in the day he had quite an active oozing, which required removal of stitches and packing of the cavity with gauze. The effect of this loss of blood was very marked and passed off only after administration of salt solution by hypodermoclysis.

The limb was fixed in abduction to a long splint, with slight traction and the pelvis kept from tilting by applying a Buck's extension to the other limb in strong abduction.

After operation foot drop was noticed which persisted for several months, but finally disappeared. It was thought to have been caused by pressure on the sciatic nerve by the levers or more likely by traction on the external popliteal at the bend of the knee.

A tendency to eversion of the limb persisted, due to loss of the internal branch of the "Y" ligament. The pit which had been packed with iodoform gauze rapidly filled with healthy granulations and healing proceeded in an orderly manner.

In seven weeks he was fitted with a brace which reached from the brim of his pelvis to his shoe.

In eight weeks he walked about the ward, bearing weight on his limb, a partial peroneal paralysis persisting.

In ten weeks he was dismissed from the hospital, a plate taken at that time showing the head of the bone in its socket.

He returned for examination on September 16 (almost five months after operation) still wearing the brace by day and carrying a cane. There was no shortening, but still some eversion. Two weeks later he discarded the brace.

He came back six and a half months after operation and then for the first time a shortening of one-half to three-fourths inch could be demonstrated. The peroneal paralysis had disappeared and the patient walked with comfort.

On March 18 (eleven months after operation) he was examined for the last time and the shortening was one and an eighth inches, abduction 25 degrees and flexion at the hip 35 degrees. He walks with a solid gait and without pain and has for some months been working as an automobile repairsman.

Comments. Preliminary traction with Buck's extension is of great service, the adhesive plasters being invariably attached to the thigh only, never below the knee, in order to obviate injurious lengthening of the ligaments of the joint. The effect of this traction is to draw the head of the femur more nearly to

the level of the acetabulum, and not only to lengthen the connective-tissue bands which bind down the neck but also to stretch the shortened pelviofemoral muscles.

The occasional use of passive movements of the limb at the hip and knee also serves the purpose of breaking up recent and stretching old adhesions.

The question of whether to attempt reduction by external means (manipulation and traction) is very important and must be decided in each case on its own merits.

Those, like Poncet and many other eminent surgeons, who had fatalities after the most careful efforts at reposition are strongly of the opinion that the hidden danger is the one most to be feared, and that after a hip dislocation has become ancient the only safety lies in the open way.

This also is the opinion of those who have operated on such cases by open reduction and have seen the acetabulum filled with connective tissue and roofed over with shreds of capsule, and the head and neck bound down with a dense fibrous growth. These latter have usually experienced great difficulty in the return of the head to its socket even after complete dissection has been made.

On two points there will be general agreement: (1) That if efforts by the so-called bloodless method are made the most extreme care should be taken to avoid undue violence, and (2) that an interval of a number of days should elapse between the failure of such an attempt and the performance of the bloody intervention.

Conclusions. 1. Traumatic hip dislocations may be considered old at the end of four weeks.

2. Reduction by manipulation is rarely successful after that time, owing to formation of connective tissue, which fills the acetabulum and binds down the head and neck.

3. Reduction by open incision is to be preferred in nearly all cases of old hip luxations, and with modern methods is attended with but little danger.

4. Preliminary traction by Buck's extension is of advantage.

5. The actual replacement of the head, after the acetabulum has been emptied and the head and neck released, is best accomplished by manipulation or the use of levers with manual and body traction, as shown in the drawing.

6. The result is often ideal and, in the cases tabulated, has been good in 80 per cent.

Operator.	Date, sex and age.	Duration of luxation	Injury.	Early efforts at reduction.	Condition prior to operation.	Nature of luxation.	Pathological condition present.
Polaillon	Dec., 1882 Male 46 years	6 wks.	Fell from a wagon	Trials on second, eighth, thirteenth, twenty-first day	Usual condition in dorsal luxation	Dorsal converted into thyroid	Thick layers of connective tissue probably shreds of capsule covering acetabulum and head
Vecelli (Venice)	1887 Female Adult	40 days	Buried under a fallen wall	.....	.....	Double L dorsal; rt. obturator	.....
Charles T. Parkes (Chicago)	May, 1888 Male 21 years	1 year	Buried under a fall of coal	Fruitless efforts soon after injury	Limp and great pain on walking	Dorsal	Slight fracture of acetabulum; cartilage of acetabulum and head intact; acetabulum empty
Riedel (Jena)	Nov., 1889 Male 5 years	6 wks.	Caught in a wagon wheel	None	.....	Dorsal	Cartilages intact
Charles T. Parkes (Chicago)	June, 1890 Male 30 years	5 mos.	Struck on hip by a sack of wheat falling a distance of 12 feet	Immediate trial of reduction thought to be successful	Severe limp and great pain	Sciatic	Acetabulum filled with granulations; cartilage intact.
Duret	June, 1890 Female 12 years	3 yrs.	Fell on her hip	None	Shortening 7 cm.; atrophy	Dorsal	Acetabulum full of fibrous tissue.
Kirmisson	Male 19 years	4 yrs.	.....	.....	Shortening 6 cm.	Dorsal	.....
Küster (Marburg)	Sept., 1892 Male 9 years	7 wks.	Fall from a tree	None till three days before operation	Shortening 5 cm.; walks with difficulty with crutches	Dorsal	Head bound down; acetabulum full; round ligament present; cartilages intact on head lost in acetabulum
Arpad Gerster (New York)	Dec., 1892 Male 8 years	7 wks.	Run over by an express wagon	None	Inability to walk; paralysis of anterior tibial group of muscles; shortening 1⅝ inches	Dorsal	Head covered with granulations and acetabulum almost filled with them
V. P. Gibney (New York)	May, 1893 Male 8 years	7 mos.	Run over by an express wagon	Reduction by open incision at seven weeks	Recurrence of dislocation; paralysis; shortening	Dorsal	Acetabulum filled with fibrous tissue
W. G. Spencer (London)	1894 Male 7 years	5 mos.	Fell from a roller which passed over his legs	Immediate efforts at reduction thought to be successful	Very lame	Dorsal	Acetabulum filled with dense fibrous tissue.
M. L. Harris (Chicago)	Feb., 1894 Male 33 years	4 mos.	Struck on hip by 350-pound pulley	Three attempts with anesthesia four, five and seven weeks after accident	Limb atrophied and useless	Dorsal	Acetabulum filled with tough connective tissue and capsule; cartilage smooth; head of posterior-superior edge of acetabulum small piece broken from rim of acetabulum
Riedel (Jena)	Oct., 1894 Male 9 years	10 wks.	Run over by a wagon	None	No mobility; walk bad	Obturator	Acetabulum full; head normal
Mikulicz (Breslau)	May, 1895 Female 36 years	18 wks.	Run over by a sled	Unsuccessful trials two weeks after injury	Limb useless	Ischiatic	Much scar tissue; acetabulum filled.
Riedel (Jena)	Aug. 1895 Male 37 years	3 mos.	Blow from a falling tree	Not recognized for seven weeks	Walks with a cane and crutch	Obturator	Acetabulum full; head surrounded with bony shell
Mikulicz (Breslau)	Oct., 1895 Male 8 years	10 wks.	Fall	Immediate unsuccessful trials by manipulation	Very lame	Dorsal	Acetabulum full; epiphysis loose; head tightly fixed.
Mikulicz (Breslau)	Nov., 1895 Male 41 years	20 wks.	Wagon overturned and fell on him	Immediate trials at reduction thought to be successful	Very lame	Ischiatic	Head firmly bound fibrous mass in acetabulum with fragments of bone

Method of reduction.	Operative result.	Postoperative treatment.	Postoperative course.	Functional result.	Publication.
Anterior vertical incision; complete isolation of head and neck	Death from gas gangrene on fourth day	.....	.....	.....	Bull. de la Soc. de Chir. de Paris, Jan. 31, 1883, p. 110.
Posterior incisions with tenotomy; reduction easy; obturator luxation not operated	Recovery	.....	Primary union	Satisfactory gait	Archiv. d'Orthop., 1887; O. Bloch: Rev. d'Orthop., 1890.
Vertical incision over the trochanter; trochanter freed of its muscles; head pried into place with a lever easily	Recovery	Extension for eight weeks	Slight suppuration; recovery in eleven weeks	Limited movement; walks without pain or lameness	N. Am. Pract., Chicago, 1890, ii, 499.
Langenbeck's incision; trochanter freed; reduction; no sutures nor drain	Recovery	Extension	Motion in narcosis in four and a half months	Ideal result two yrs. later; all movements	Endlich in Arch. f. klin. Chir., 1898, lvi.
Vertical incision over trochanter, then curved incision forward; neck and trochanter freed; reduction with difficulty	Recovery	Extension for ten weeks; walks with crutches in fourteen weeks	Much shock; slight infection; recovery in fourteen weeks	Attitude normal; good motion	N. Amer. Pract., Chicago, 1890, ii, 499.
Incision over the trochanter; tenotomy of adductor muscles	Recovery	Extension bandage	No suppuration	Shortening 4 cm.; movements more extensive than before, but limited	Dennetieres, F.: Thése de Paris, 1890.
Lateral incision; removal of part of the head; rest replaced	Recovery	.....	Suppuration	Shortening still 6 cm.; position improved; mobility sufficient; walk easy with an elevated sole.	Soc. de Chir., March, 1892.
Langenbeck's incision; excavation of acetabulum and freeing of head and trochanter; replacement without much difficulty	Recovery	Extension in abduction; later inversion with adhesive plaster	Primary union; tendency to reluxation; in bed two months	Result ideal; full return of function when seen one year after operation	Rudolf Volkmann in Deutsche. Zeit. f. Chir., 1893, xxxvii, 373.
Five-inch incision with center at great trochanter; section of part of "Y" ligament; head easy replaced by manipulation	Recovery	Extension apparatus with abduction; no brace used after patient left his bed	Convalescence smooth; out of bed in three weeks; left hospital in two months, walking with a cane, but with paralysis of anterior tibia group	Dislocation recurred soon after leaving hospital without trauma	Ann. Surg., 1893, xvii, 586.
Incision through scar; acetabulum curetted with sharp spoon; adductors divided; head reduced with great difficulty	Recovery	Fixed dressing of plaster of Paris in abduction	Prolonged suppuration, but final closure	Head still in place five months later; foot-drop persists; hip quite stiff.	Ann. Surg., 1894, xx 621.
Straight anterior incision; acetabulum cleared out	Recovery	Fixed with plaster splint in abduction and external rotation	.....	Fibrous rigidity with slight abduction and external rotation; prognosis good	Tr. Clin. Soc., London, 1895, xxviii, 293.
Incision between tensor vaginæ, femoris and gluteus med.; all muscles attached to great trochanter and shaft as far as lesser trochanter severed subperiosteally; acetabulum cleared with sharp spoon; head replaced with difficulty by manipulation	Recovery	Limb encased in plaster cast in extension, abduction and external rotation	Considerable shock at first; on crutches in six weeks	In three months walked well with a cane; motion limited, but increasing	Ann Surg., 1894, xx, 319.
Antero-external incision; reduction easy; wound not closed	Recovery	Lateral splint	Suppuration; elimination of sequestra	Ankylosis in slight flexion; shortening none; good gait	Endlich in Arch. f. klin. Chir., 1898, lvi.
"Snuff-box" incision with osteotomy of the trochanter; evacuation of the acetabulum	Recovery	Plaster splint with inward rotation; Taylor brace applied in six weeks	Primary union	Mobility satisfactory and normal gait after four months	Drehmann in Beitr. f. klin. Chir., 1896, xvii.
Antero-external incision; acetabulum cleared. Rim of acetabulum chiseled off to permit reduction	Recovery	Out of bed in four weeks; Volkmann's splint	Long-continued discharge	Shortening of 1 cm.; flexion to 35°; walks easily for many hours	Endlich in Arch. f. klin. Chir., 1898, lvi.
Evacuation of acetabulum; transverse and vertical incision; trochanter chiseled off; reduction by manipulation; trochanter sutured	Recovery	Extension and outward rotation; splint	Primary union	Walks well in six weeks; left hospital in two and a half months	Drehmann in Beitr. f. klin. Chir., 1896, xvii.
Bow-shaped incision; trochanter chiseled off; acetabulum cleared; reposition easy; trochanter sutured	Death from infection in six weeks	Extension in outward rotation	Septic infection with secondary luxation and pelvic infiltration	.....	In Beitr. f. klin. Chir., 1896, xvii.

Operator.	Date, sex and age.	Duration of luxation	Injury.	Early efforts at reduction.	Condition prior to operation.	Nature of luxation.	Pathological condition present.
Emma S. Merritt (San Francisco)	Aug., 1896 Male 9 years	1 yr.	Fall into a well	None recorded	Could get about, but much disabled	Dorsal	Head fixed by fibrous tissue; acetabulum filled with same
Bergmann (Berlin)	Female 48 years	7½ wks.	Fall from a sled	.....	Walks only with crutches	Dorsal	Cartilages intact; capsule thickened
Bergmann (Berlin)	Male 48 years	5½ mos.	Fall from a horse	.....	Could not walk without crutches	Dorsal	Acetabulum full; erosion of cartilage
Kaufmann (Zurich)	June, 1897 Female 5½ years	4 mos.	Struck by a falling roof	Thought to have been reduced just after injury	Limps badly; united subtrochanteric fracture	Dorsal	Head and neck bound down by fibrous tissue
Chas. E. Bell	Nov., 1897 Male 13 years	5 mos.	Injured while playing foot-ball	None	Limb absolutely useless	Dorsal	Acetabulum filled with new tissue and remains of capsule; cartilage intact
H. M. Sherman (San Francisco)	Jan. 15 1898 Female 4 years	7 mos.	Fall from a gate	Efforts at reduction at once and six weeks later	Patient able to run about, but with position of iliac luxation	Dorsal	Capsule torn from femur and adherent in acetabulum; cartilage intact
Watson Cheyne	1899 Male 60 years	9 wks.	Fall	.....	Unable to stand alone	Dorsal	Acetabulum filled with soft tissue; fracture of acetabulum
Tietze (Breslau)	1899 Male 36 years	12 wks.	Struck by a rolling log and knocked down	Vain effort made eight days after injury	.....	Dorsal	Acetabulum filled
Payr	Male 20 years	1 mo.	.....	.....	.....	Dorsal	Fracture of acetabulum
Perrando	Male 10 years	2½ yrs.	.....	.....	.....	Supracotyloid	Acetabulum filled with dense connective tissu
Dollinger (Budapest)	Nov., 1900 Male 32 years	4 wks.	Fall from a tree	.....	.....	Dorsal	Acetabulum full of connective tissue and bony fragments
Jacob	April, 1901 Male 24 years	3½ mos.	Fell into a hole in the road	Fruitless trials the next day	Cannot walk	Dorsal	Capsule adherent to acetabulum, which is filled with fibrous tissue
Haedke (Schivelbein, Pomerania)	June, 1901 Male 14 years	10 wks.	Buried under a fall of earth from a wagon	None	.....	Dorsal	Acetabulum is filled with dense tissue; cartilage intact
Dollinger (Budapest)	Oct., 1901 Male 33 years	3 mos.	Fall of earth	None recorded	.....	Dorsal	Fragments of pelvis in acetabulum; fracture through acetabulum
Oberst (Halle)	Jan., 1902 Male 40 years	7½ wks.	Buried under a fall of slack	None till four wks. after injury	.....	Dorsal converted from obturator	Trochanter porotic; lig. teres thickened; acetabulum filled with fibrous tissue
Labeyrio (Nantes)	April, 1903 Female 15 years	4½ mos.	Fell when carrying a heavy weight on her shoulder	None	.....	Obturator	Acetabulum filled with connective tissue and fragments of bone
DeForest Willard (Philadelphia)	Male 28 years	8 mos.	.....	Eight attempts by eight surgeons	Hip immovable and useless	Dorsal	Acetabulum filled with tough fibrous tissue and head covered with the same
C. E. Thompson (Scranton, Pa.)	Feb., 1904 Male	8 mos.	Run over by a mine car	None	Leg amputation stump; neck of bone fractured ten days before in ineffectual efforts at reduction by manipulation	....	.....

Method of reduction.	Operative result.	Postoperative treatment.	Postoperative course.	Functional result.	Publication.
Incision along posterior border of tensor vag.fem.; head released; acetabulum cleared with sharp spoon and reduction accomplished with difficulty	Recovery	Double spica of plaster of Paris	Convalescence stormy	Joint stiff when last seen; limp present, but limb useful	Phila. Med. Jour., 1898, ii, 386 (Sherman).
Langenbeck's incision; trochanterand neck freed; reduction by manipulation	Recovery	Plaster-of-Paris dressing	Abundant secretion; stitches removed and wound packed	Walks with a cane in ten weeks; slight flexion	Engel in Langenbeck's Archives, 1897, lv, 629.
Langenbeck's incision; acetabulum scooped out; head freed from connective tissue; tampon	Recovery	Extension	Suppuration	Movements in seventy-three days; goes without cane or limp; slight flexion	Engel in Langenbeck's Archives, 1897, lv, 629.
Curved incision over trochanter	Recovery	Extension apparatus	Suppuration; elimination of sequestra	Two and a half years later anchylosis, 2 cm. short; walks without cane	Höfliger, Thése, Berne, 1900.
Anterior incision; all muscles separated from bone subperiosteally as far as lesser trochanter; acetabulum cleared with scissors and scoop; head returned by traction and manipulation	Recovery	Long splint and weight	No shock; splint removed in two mos. and crutches allowed.	In nine months had perfect motion and could stand and walk well	Lancet (London), 1898, ii, 1059.
Incision along posterior border of tensor vag. fem.; head exposed and cleared; glutei cut from trochanter; acetabulum cleared; reduction easy	Recovery	Plaster-of-Paris spica in abduction	Aseptic healing; splint removed on nineteenth day; walked with assistance on twenty-sixth day	Child walked well and had free motion at three mos.	Phila. Med. Jour., 1898, ii, 386.
Acetabulum emptied	Recovery	.....	.....	Walks well in two months. No shortening	British Med. Jour., 1899, ii, 1290.
Longitudinal and transverse incision; excavation of acetabulum; manipulation; suture	Recovery	Plaster-of-Paris dressing for six weeks in abduction	Aseptic course	Walks without support after seven weeks, motion limited, but leg is strong.	Jahres Bericht der Schles. Gesellsch., 1899, 89.
Kocher incision; reduction; two-thirds wound sewed; one-third tamponed	Recovery	Extension	Dismissed in five months	Recovery with satisfactory motion; easy gait; slight limp.	Deutsch. Zeit.f. Chir. 1900, lvii.
Anterior longitudinal incision; trochanter freed; acetabulum excavated; head modeled	Recovery	.....	Slight suppuration	Fair result	Archivo. di Orthopedia, 1900.
Anterior incision; partial incision of Y ligament; acetabulum cleared; posterior incision for head of bone; head returned by pulley traction	Recovery	Drainage; gypsum dressing	Long continued suppuration; movements at end of six weeks; *peroneal paralysis*	Ten years later has peroneal paralysis; walks on outer border of foot and limps; hip stiff	Ergebnisse der Chir. und Orth., 1911, iii, 83.
Langenbeck incision; excavation of cup; freeing of head; reduction; small part of head removed	Recovery	Splint	Primary union	Three months later no shortening; motion almost normal; no limp	La. Province Med., July and Aug.,1901, xv, 351.
Kocher incision; separation of muscles from trochanter; acetabulum freed	Recovery	Extension, four wks.	Aseptic healing	Out of bed in five and a half weeks; good motion; ideal result; no shortening	Deutsche. Zeit. f. Chir., 1902–1903, lxvi, 359.
.....	Recovery	.....	Suppuration; resection of suppurating head two and a half months later	Nine years later limps badly; 8 cm. shortening; flexion and adduction	Ergb. der Chir. und Orth., 1911, iii, 83.
Langenbeck's incision; periosteum and muscles separated from trochanter; head, neck and trochanter freed; head restored easily; tamponade and secondary suture three days later	Recovery	Passive motion begun in two weeks.	Aseptic	No shortening; anchylosis in extension; seven months later walks with a cane.	Brüning in Deutsch. Zeit. f. Chir., 1904, lxii, 412.
Posterior incision of Langenbeck; acetabulum cleared	Recovery	Plaster-of-Paris splint in abduction	Smooth healing	Walks well, but some limitation of motion	Gaz. Med. de Nantes 1903, xxi, 560.
Anterior and posterior incisions; acetabulum reamed out; head cleared and reduced with great difficulty	Death in 7 days from septic endocarditis	.....	.....	.....	Jour. Am. Med, Assn., 1904, xliii. 884
Anterior and posterior incisions; reduction with long blunt hooks; fracture nailed	Recovery	.....	.....	.....	Jour. Am. Med. Assn., 1904, xliii, 884.

Operator.	Date, sex and age.	Duration of luxation	Injury.	Early efforts at reduction.	Condition prior to operation.	Nature of luxation.	Pathological condition present.
Dollinger (Budapest)	June, 1904 Male 48 years	5 mos.	Fall of earth	None recorded	Could not walk	Obturator	Acetabulum full of connective tissue and two small pieces of bone; strong cicatrices about neck
Dollinger (Budapest)	Nov., 1905 Male 26 years	1 mo.	Fall down stairs	None recorded	Can hardly walk	Dorsal	Fracture of pelvis; acetabulum covered with thick connective tissue.
Tayloe, D. T. Washington, N. C.	Male 20 years	6 wks.	.....	.....	Totally unable to walk or even to put limb on ground	Dorsal	Acetabulum full
Aslett Baldwin	1906 Female 18 years	3½ mos.	Fell from a swing	None	Typical signs of dorsal dislocation	Dorsal	Acetabulum completely filled with new tissue and head firmly fixed in its new location
Dollinger (Budapest)	Feb., 1907 Male 22 years	11 wks.	Fall of earth	.....	.....	Obturator	Acetabulum full of fibrous tissue so fixed to cartilage that they cannot be separated
Dollinger (Budapest)	Feb., 1907 Male 8 years	3½ mos.	Fall	None recorded	Walks with difficulty with cane; violent pain when he walks much	Dorsal	Acetabulum filled with connective tissue
Gilbert Barling (Birmingham, England)	Mar., 1907 Male 13 years	5 wks.	Fell when sliding on ice	None	Stiffness, pain and swelling; boy able to get about	Upward	Head resting just above rim of acetabulum; cavity filled with thickened stump of ligamentum teres
Streissler (Craz)	Aug., 1907 Male 14 years	11 wks.	Slipped and fell with his leg abducted	Replacement attempted three weeks after accident and five wks, when fracture occurred at upper third	Walks painfully with cane	Obturator	Fracture at upper third of femur consolidated; acetabulum full of connective tissue; cartilages intact
Dollinger (Budapest)	Jan., 1908 Male 52 years	2¼ mos.	Thrown down by fall of a tree	None recorded	Very lame; peroneal paralysis	Dorsal	Cartilage normal; acetabulum filled with connective tissue; fracture of rim and cup of acetabulum
A. Gibson	May, 1912 Male 49 years	9 wks.	Struck on hip by a lifeboat	None	Usual signs of dislocation, with atrophy of thigh muscles	Dorsal	Head below tendon of obturator externus; acetabulum nearly obliterated by adherent capsule
Berard and Vignard	July, 1914 Male 31 years	7 mos.	Fall from a ladder from which he hung suspended by his foot	First by a bone-setter and three months later by surgeons	Unable to walk; limb atrophic	Intrapelvic thyroid	Acetabulum filled with fibro-cartilage; head pushed through thyroid foramen
J. B. Murphy (Chicago)	Jan., 1916 Male 36 years	16 yrs.	Fall from a wagon	Immediately after injury and one month later	Lordosis and scoliosis; pains and aches on prolonged standing or walking	Obturator	Head imbedded in dense mass of connective tissue; capsule not recognizable
Parona	1889 Male 51 years	2 mos.	.....	.....	.....	Dorsal	Acetabulum filled
Gaub (Pittsburgh)	April, 1917 Male 35 years	3 mos.	Rolled between railroad cars	None; co-existing injuries had caused the luxation to be overlooked	Bedridden by reason of other injuries; fracture of same femur, right humerus and left ilium	Anterior	Stellate fracture of acetabulum; acetabulum filled with connective tissue
Buchanan (Pittsburgh)	April, 1919 Male 18 years	7 mos.	Crushed under cap-sized automobile	None	Very lame; walks with difficulty with crutches	Dorsal	Fracture of acetabulum unitedsubtrochanteric fracture; acetabulum full and head and neck bound down

Method of reduction.	Operative result.	Postoperative treatment.	Postoperative course.	Functional result.	Publication.
Pyriformis; obturator and gemelli cut; by manipulation obturator converted into iliac and then reduced	Recovery	.....	Suppuration which soon subsided	Six and a third years later complete anchylosis; very lame; has no pain.	Ergb. d. Chir. u. Orth., 1911, iii 83.
Acetabulum cleared; reduction by manipulation	Recovery	Volkmann's apparatus for traction	Open treatment; secondary suture; crutches in twenty-three days	Normal gait; flexion only to 140°; slight abduction and adduction	Ergb. d. Chir. u. Orth., 1911, iii, 83.
Straight incision over the trochanter; muscular attachments to trochanter cut away; acetabulum cleared with sharp spoon; head returned by manipulation with great force	Recovery	Slight extension with weight and pulley	Good healing	Limb in good position; fair range of motion	Charlotte Med. Jour., 1906, xxix, 282.
Anterior incision; traction and countertraction; pressure on head; traction on neck with large hook	Recovery	Liston splint for eight days; then sandbags and passive motion.	Primary union	Movements practically perfect two and a half months later	West London Med. Jour., 1907, xii, 33.
Acetabulum reamed out; head separated from its connective tissue attachments; obturator converted into iliac and then reduced by manipulation	Recovery	.....	Suppuration; resection of suppurating head later	Three and two-third years later fairly good motion; 6 cm. shortening	Ergb. d. Chir. u. Orth., 1911, iii, 83.
Emptied acetabulum with scissors and knife; reduced luxation by circumduction	Recovery	Fixation in abduction with plaster of Paris	Superficial suppuration; splint removed and patient walking in thirty days	Perfectly normal function when seen three and a half years later	Ergb. d. Chir. u. Orth., 1911, iii, 83.
Anterior incision; partial section of "Y" ligament; acetabulum cleared with scissors and curette	Recovery	Box splint for 23 days	Could walk without assistance in six weeks	Result perfect; free motion and no lameness nine mos. later	Surg., Gynec. and Obst., 1908, vii, 566
Kocher's incision; acetabulum cleared and reduction accomplished with levers; suture in layers	Recovery	Limb fixed in extension and abduction	Primary union; sl. temporary displacement of head; later corrected	Two and a half mos. after operation walks well without support; movements moderate	Beitr. z. klin. Chir., 1908, lviii, 571.
Acetabulum cleared; replacement easy by circumduction	Recovery	Drainage; gypsum dressing	Aseptic healing; walks with crutches in eight days; plaster removed in eight weeks	One year and eight months later has very good function, but some limitation of motion; slight peroneal paralysis	Ergb. d. Chir. und Orth., 1911, iii, 83.
Kocher incision; obturator externus cut; trochanter separated at base; head protruded; acetabulum reamed out; head replaced with difficulty by leverage and manipulation; trochanter fixed with screws.	Recovery	Liston's splint for three weeks; massage; allowed up in seven weeks; canes discarded in four months	Foot-drop noticed when patient was allowed up	Functional result good; but very little motion at hip when dismissed Oct. 26	Lancet (London), Feb. 1, 1913.
Anterior incision; acetabulum reamed out; upper margin of thyroid chiseled away and head reduced	Recovery	Limb fixed in abduction and slight flexion	Slow healing due to large hematomata	Good position, but some shortening and only 30° to 40° of flexion	Lyon Med., 1914, cxxii, 707.
Goblet incision; external rotators separated from trochanter; connective tissue incised; head replaced easily by manipulation	Recovery	Immobilization in "frog" position	Patient walking with crutches in six weeks	Very promising	The Clinics of John B. Murphy, 1916, v, 731.
Fiorani incision; difficult reduction	Recovery	.....	Suppuration		
Anterior incision; acetabulum cleared; reduction accomplished with difficulty with traction and levers	Recovery	Plaster-or-Paris cast to nipple	.....	Excellent function; works now as train conductor	Personal communication.
Kocher incision; acetabulum cleared; head and neck freed; reduction with difficulty by manipulation and levers	Recovery	Long splint; traction in abduction and external rotation	Smooth healing	Good function	Herein reported.

ADVENTITIOUS LIGAMENTS SIMULATING CERVICAL RIBS

By ARTHUR AYER LAW, M.D.
MINNEAPOLIS, MINN.

Thorough study, by many observers, of the clinical entity known as cervical ribs, has crystallized into a definite symptom-complex the reaction which follows when the eighth cervical and first dorsal nerves of the brachial plexus are lifted up, stretched taut and angulated over an adventitious rib, and in addition are pinched in the angle formed by the scalenus anticus muscle and the first rib, and there subjected to the constant hammering trauma from respiratory movements during the excursion of the lungs.

With the pressure neuralgia of the brachial plexus cords there is a coincident angulation and pinching of the subclavian artery as it arches over the extra rib and is crowded forward into the angle formed by the muscle and the rib; this insult occasionally results in the symmetrical dilatation of the artery distal to the rib, which simulates a fusiform aneurysm and which has been so thoroughly studied by Keen and Halsted.

That only about 10 per cent. of the cervical ribs give local and peripheral symptoms is conceded. When these local and peripheral symptoms do occur they are manifested in the root of the neck and in the forearm and hand, and are an expression of nerve irritation, with motor and sensory changes, with loss of trophic control and with ischemia of the extremity from vasomotor changes; these symptoms are now thoroughly well established and recognized.

Minor points of discussion as to the physiological mechanics which produce these symptoms in cervical ribs still give zest to study, notably Todd's and Keith's assertion that the circulatory changes in the forearm and hand are the result of pressure upon sympathetic fibers in the lower cords of the brachial plexus, these fibers from the rami communicantes entering the plexus with the eighth cervical and first dorsal nerves. They affirm that pressure of the cervical ribs upon the lower cord of the plexus causes irritation or even obstruction of these sympathetic fibers, which produces trophic changes in the intima and media of the arteries, followed by secondary proliferation and hypertrophy of these coats, which results in a coincident pallor and coldness of the hand and upon occasion in gangrene of the finger tips. Other observers assert that the anemia of the extremity results from a mechanical obstruction and angulation of he subclavian artery in the neck at the site of the offending rib. The British have reported this same symptom-complex following pressure from a high first rib.

In 1914 and 1915, while clinically studying a series of cervical ribs, the writer noted what he finds other observers have reported, that in the cases of some of the shorter and more rudimentary ribs the forward projecting tip of these ribs was occasionally attached by a definite ligament to the first rib or to the sternum.

When, then, a case presented itself for relief from symptoms which were typically those of cervical ribs, yet in which the radiographic evidence revealed no hypertrophy or elongation of the transverse process of the seventh cervical vertebra, we remembered the ligaments attached to the rudimentary ribs, and venturing to explore the neck found a definite adventitious ligament arising from a normal seventh cervical transverse process, and being inserted into the first rib at the scalene tubercle with the scalenus anticus muscle.

This ligament was about 4 mm. wide and 2 mm. in thickness; it looked like any ligament and had definite longitudinal fibrous bands; it was as taut as a bowstring and tightly stretched

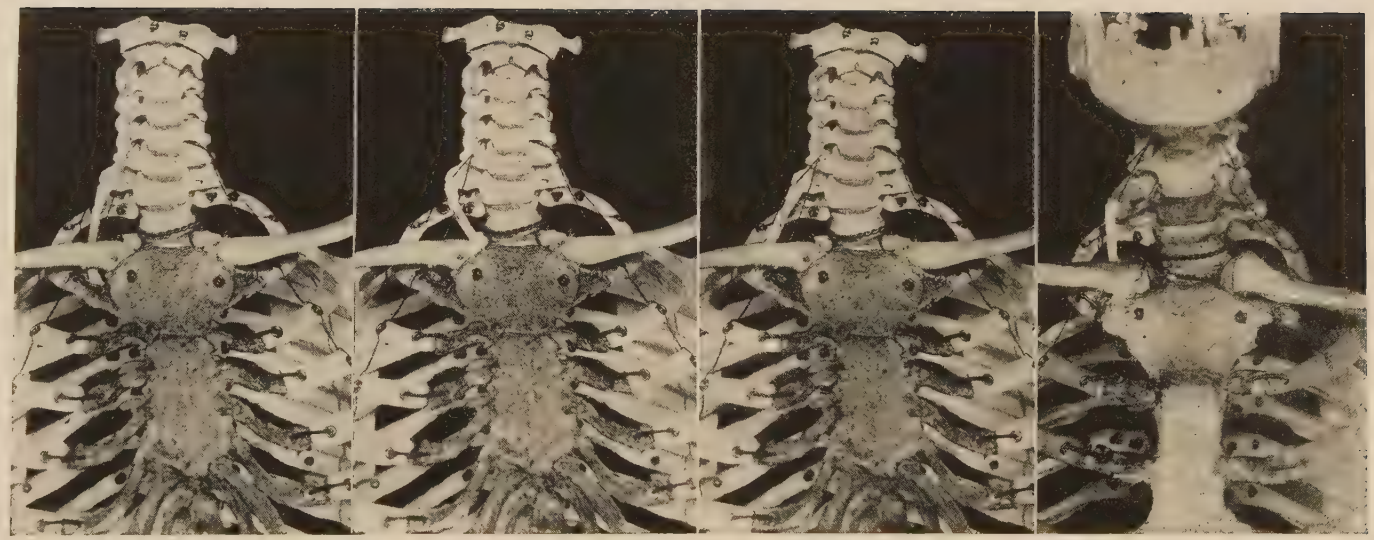

FIG. 1.—Demonstrating constant point of origin of adventitious ligaments and the different points of insertion.

over it, and sharply angulated were the two lower cords of the brachial plexus and the subclavian artery.

Mobilizing the phrenic nerve and pulling it aside the scalenus anticus muscle was sectioned and then the adventitious ligament; when the ligament was cut the marked tension upon the nerves and artery was immediately relaxed.

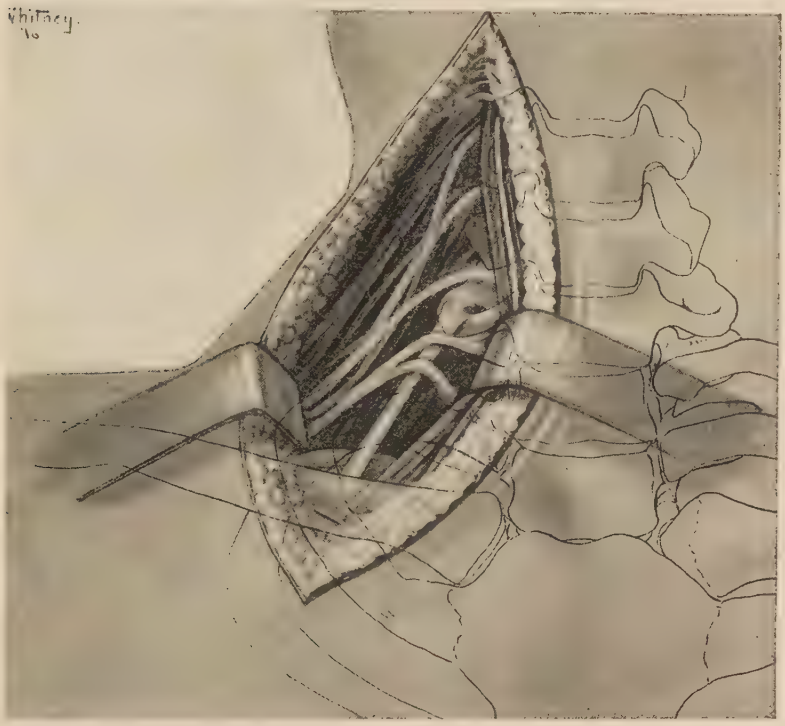

FIG. 2.—Schematic drawing showing angulation of lower cords of brachial plexus over adventitious ligament.

Since the first case noted in 1916 we have operated upon three others, differing only in minor details from the first one, while each of them gave typical cervical rib symptoms, yet in no instance were cervical ribs present.

Radiographic study, although it showed no adventitious ribs,

did show what seemed to be a tendency on the affected side to a pulling down of the last cervical transverse process closer to the transverse process of the first dorsal vertebra than was shown on

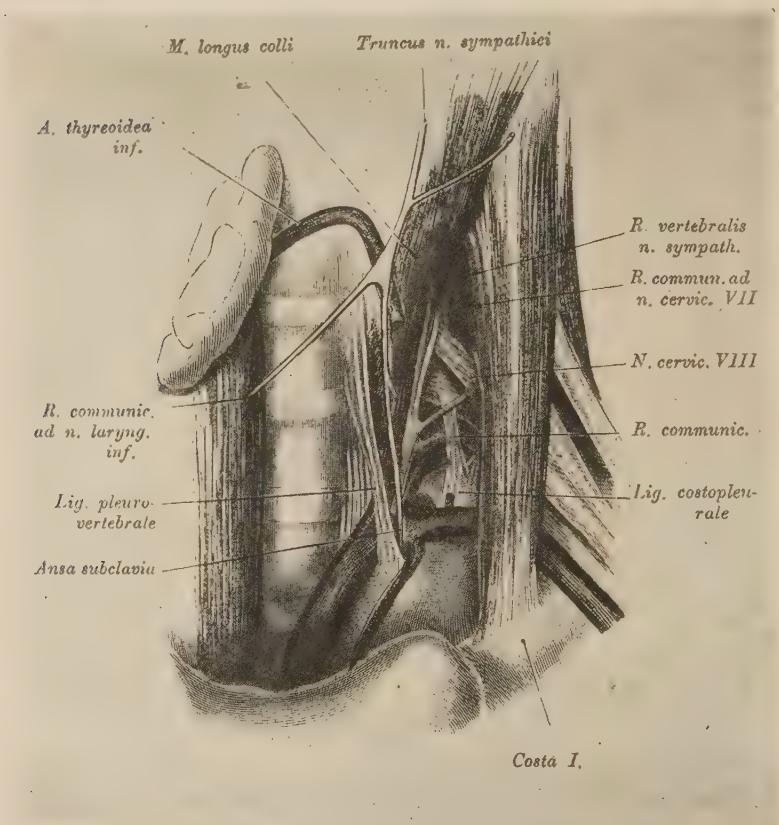

Fig. 206. Linke Pleurakuppel und deren Nachbarschaft.

FIG. 3.—Taken from Zuckerkandl showing Sibson's fascia and abnormal and inconstant ligaments inserted into dome of the pleura.

the normal side. Three cases showed no hypertrophy of the transverse processes of the last cervical vertebra, while the fourth was of the "cow-horn type," with the process slightly longer than on the other side.

There were in all four of the cases the invariable angling over the ligament and the pinching of the nerves and artery between the ligament and the scalenus anticus muscle, just as these structures are pinched between the muscle and rib in true cervical rib cases.

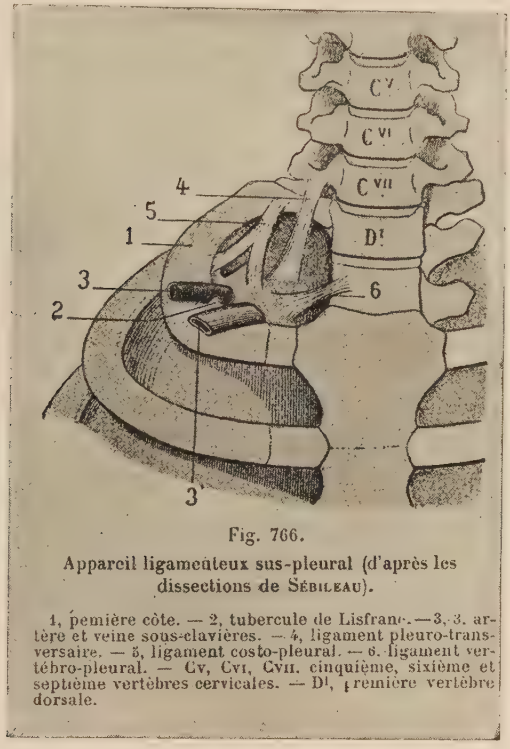

Fig. 766.

Appareil ligamenteux sus-pleural (d'après les dissections de Sébileau).

1, première côte. — 2, tubercule de Lisfranc. — 3, 3, artère et veine sous-clavières. — 4, ligament pleuro-transversaire. — 5, ligament costo-pleural. — 6, ligament vertébro-pleural. — Cv, Cvi, Cvii, cinquième, sixième et septième vertèbres cervicales. — D1, première vertèbre dorsale.

Fig. 4.—Taken from Poirier and Charpy, showing abnormal bands inserted into the dome of the pleura.

The ligaments were all tightly stretched, and while they all had their origin from the tip of the seventh cervical transverse process, they varied markedly in their point of insertion for one was inserted with the scalenus anticus muscle into the scalene tubercle of the first rib, another into the costoclavicular

ligament, the next into the sternoclavicular ligament, while the last was inserted well toward the midline into the interclavicular ligament, close to the head of the clavicle.

In none of the cases studied was there a tendency to dilatation of the subclavian arteries distal to the ligament, and only in one was the pulse appreciably weaker on the obstructed side.

Roentgen rays in one of the cases showed a marked osteoporosis of the phalanges of the ring and little finger of the affected side; this was undoubtedly trophic in origin.

FIG. 5.—Osteoporosis of phalanges of third and fourth fingers compared with normal and showing trophic changes due to pressure on brachial plexus.

The cases were equally divided between the sexes, and the ages were forty-seven and forty-eight in the males and nineteen and forty-four in the females. In each instance after operative interference, while the neuralgia persisted for a while, it promptly became less severe and ultimate and complete relief was obtained.

Searching the literature in an attempt to find etiological explanation for these bands we found that those springing from short cervical ribs were reported; the nearest description of anything resembling the complete ligaments is described by

Zuckerkandl, who, in his dissections, discovered there were certain inconstant and extremely variable bands which have been associated with Sibson's fascia, and which are occasionally found reënforcing and helping that fascia to fix the dome of the pleura.

This fascia and associated fasciculi, according to Zuckerkandl, and to the French observers, Porier and Charpy, is derived in man from a tiny rudimentary and inconstant muscle, which itself is extremely variable in its origin, distribution and insertion, the so-called scalenus minimus; this little muscle, unusual in the human, is normal to a number of the Simian species.

These bands of Sibson's fascia, as well, have been designated according to their distribution, as the pleurotransverse, the costopleural and the vertebropleural ligaments.

Whether the adventitious bands we have described are a remnant of supernumerary ribs, are a variation of the Sibson's fascia or are in themselves a distinct entity, has not been determined; we believe, however, they should take their place and be recognized as structures which are actually as definite and give as plain a symptomatology as the cervical ribs themselves.

A knowledge of their occasional presence may help to explain some of the circulatory and trophic conditions of the hand and arm of obscure etiology, which heretofore, from want of exact knowledge, we may have designated as Raynaud's disease, intermittent claudication, spontaneous gangrene or thromboangiitis.

The writer hesitates to report so meagre and so inconclusive a series of cases, but hopes that by so doing attention may be directed to a condition which, judging from the barrenness of the literature must be relatively rare or rather generally overlooked.

THE RECOGNITION OF DEAD BONE, BASED ON PATHOLOGICAL AND X-RAY STUDIES

By DALLAS B. PHEMISTER, M.D.
CHICAGO, ILL.

When bone dies rapidly and in appreciable quantity from infection in osteomyelitis, compound fractures, tuberculosis and rarely in lues, it is at first indistinguishable either by gross or roentgenological appearance from the adjacent living portions. Only after the occurrence of further changes in the living and the dead bone can its extent be determined. A detailed knowledge of these changes is essential for arriving at a diagnosis especially by means of the roentgen rays and for planning suitable and properly timed operations.

The changes in the dead bone are of great importance in establishing its identity. There are changes in color which are of assistance at operation. Dead compact bone turns white from the loss of circulation and of soft parts, but usually it requires some time for their absorption, and the difference in appearance early between it and the pinkish living bone is insufficient to make it a reliable guide for removing the dead bone before the line of separation has begun to form. Necrotic spongy bone is frequently dark brown or red, due to the presence of old blood and necrotic marrow in the cancellous spaces where it is sheltered from attack. Granulations may grow into and be removed with a spongy sequestrum, giving it a reddish color which is sometimes difficult to distinguish from living spongy bone. By holding the sequestrum under the tap, blood and granulations are readily washed out, leaving the white cancellous bone.

Granulation tissue soon attacks the dead bone but its activity becomes most marked after the acute inflammatory stage subsides. The task for the granulations is to separate the dead bone from the living, to reduce its volume or break it up by absorption and to extrude it from the field through the discharging sinuses.

Separation of dead from living bone is accomplished more rapidly than the other changes. The granulations attack cortex from both periosteal and endosteal sides, forming two irregular tortuous grooves which are gradually deepened until they meet. This results in the formation of a jagged, irregular zone of demarcation 2 to 5 mm. in width, depending on the thickness of the sequestrum. These grooves are frequently seen at early operation or in the roentgen-ray picture as a nick or uneven dotted line in the cortex before separation is complete. In the separation of dead spongy bone, because of its loose structure, a zone of granulation tissue forms simultaneously along the entire line of junction which results in early sequestration. The time required for separation is extremely variable, according to the density and thickness of the bone involved. It ranges all the way from five or six days with very thin cortex or spongiosa of the small bones to five or six months, with the thickest portions of the shaft of an adult tibia or femur.

Reduction in volume of the dead portion occurs from lacunar absorption by the granulations along its surfaces. There is no diffuse internal loss of lime salts from dead bone, so that any remaining portions retain their original density. The rate of surface destruction varies greatly in different portions and is dependent largely upon the relation of the surfaces to surrounding living bone and to the channels of purulent discharge. Where living bone is in close contact with dead portions, granulations springing from and supported by it attack the dead bone, producing an uneven worm-eaten surface in a comparatively short time. But those surfaces that lie at a considerable distance from living bone may show little or no signs of erosion even after long periods of time. Granulations arising from a soft part covering attack dead bone slowly and where they spring from the walls of a bone

cavity, will not bridge a wide gap and vigorously attack a relatively small inhabiting sequestrum. Thus the periosteal surface of dead cortex will become extensively eroded in those portions surrounded by involucrum but will remain smooth or little eroded where involucrum fails to form. Similarly the condition of the endosteal surface will vary with the degree of involvement of the shaft at any level. If less than half of its circumference dies, endosteal new bone will form from the surviving portion and maintain granulations in contact with the dead bone, destroying it from the endosteal surface. But if more than half the circumference is destroyed there will be, frequently, little or no erosion of the deeper portion of the endosteal surface. Where the entire circumference is dead the endosteal surface will remain unchanged for months or even years, except at the ends of the dead tube, where granulations will invade the canal for a short distance. When an involucrum is present destruction from the periosteal side may finally lead to perforations of the dead cortex, after which endosteal erosion from invading granulations may occur. These features are illustrated in Fig. 1, which is a composite sketch of the roentgen-ray picture in the later stage of infected compound fracture showing different conditions of surfaces in sequestra according to their relation to living bone. Fig. 2 shows a roentgen ray and Fig. 3 is a photograph of a seven-year-old sequestrum of the entire circumference of the shaft of the femur resulting from osteomyelitis at the age of ten. While markedly eroded externally it shows through a window endosteal surface and spongy bone that have never been touched by granulations.

There is little destruction of necrotic bone that occupies or borders on discharging channels as the discharging pus in which it is bathed keeps the surrounding granulation tissue unhealthy. This is frequently seen in infected fractures where the fracture surfaces of the dead ends remain sharp and uneroded for months because of the restraining action of pus escaping from the deeper portions (Figs. 1 and 12, *4*).

Because of this unequal action of granulations upon its surface

there may be marked variations in outline of different portions of a sequestrum. Where unattacked the surface will be unchanged and the volume and density of the sequestrum will be what it was at the time death occurred. Figs. 4, *a* and 12, *3*. But where extensively eroded with deep pockets and sharp, irregular projections the density will be unevenly reduced (Fig. 5, *b* and 4, *b*).

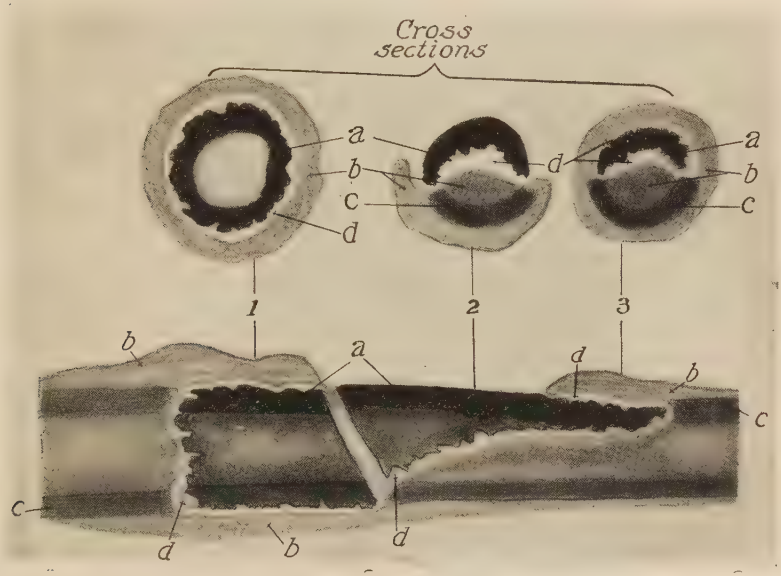

FIG. 1.—Sketch of old infected fracture showing atrophy of surviving cortex, involucrum formation and two sequestræ with well-preserved fracture lines and external surfaces that are eroded where adjacent to and little or uneroded where remote from living bone; *a*, dead bone; *b*, new bone; *c*, atrophied old bone; *d*, zone of demarcation. Cross sections show sequestration erosion along 1, external surface; 2, internal surface; and 3, both internal and external surfaces.

Any portion that remains will have its original internal structure. These are all points of the greatest value in the roentgen-ray diagnosis of dead bone.

The rate of destruction is greater while the dead piece is still attached to or incarcerated by living bone. Once it is loosened and the sequestrum moves into a freer position, especially if into

a large bone pocket, destruction proceeds at a much slower rate. Splinters killed at the onset in infected fractures may be found



FIG. 2.—Almost stationary sequestrum in osteomyelitis of seven years' standing. Broad space between sequestrum and involucrum.

little eroded at operation months afterward. In case of death of the entire circumference, with complete encirclement by

FIG. 3.—Photograph of part of sequestrum from Fig. 2. Periosteal surface markedly eroded but endosteal surface undisturbed as shown by presence of cancellous bone seen through window.

involucrum, the periosteal surface of the shaft is rapidly attacked at first, and where cortex is thin, especially in young children,

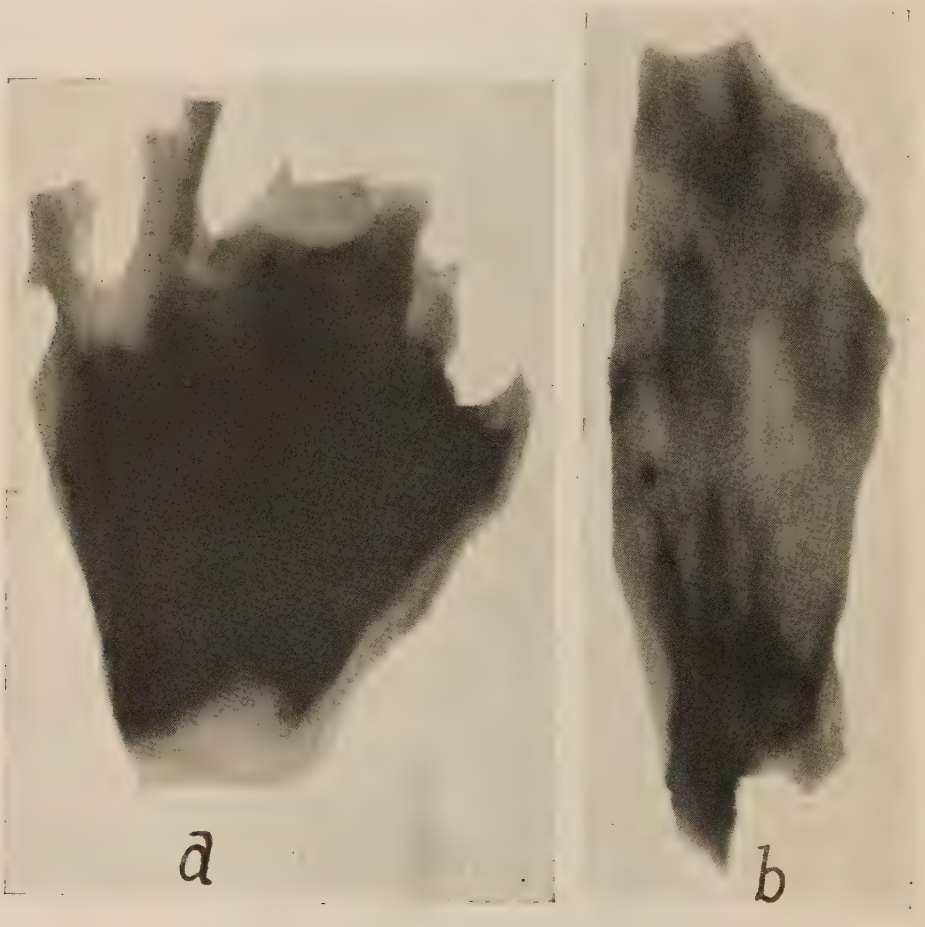

Fig. 4.—Sequestra from gunshot fracture six months old. *a*, possesses original density because uneroded along periosteal or endosteal surface; *b*, eroded by granulations and density unevenly reduced.

it may be eaten through and fragmented, after which the pieces may be destroyed or extruded through the sinuses. But where cortex is thick, continued concentric erosion gradually leads to

the development of a wide space between sequestrum and involucrum as the latter becomes dense and does not fill in about the dwindling dead piece. This retards the action of the granulations, and such loosely enclosed sequestra may then stand for

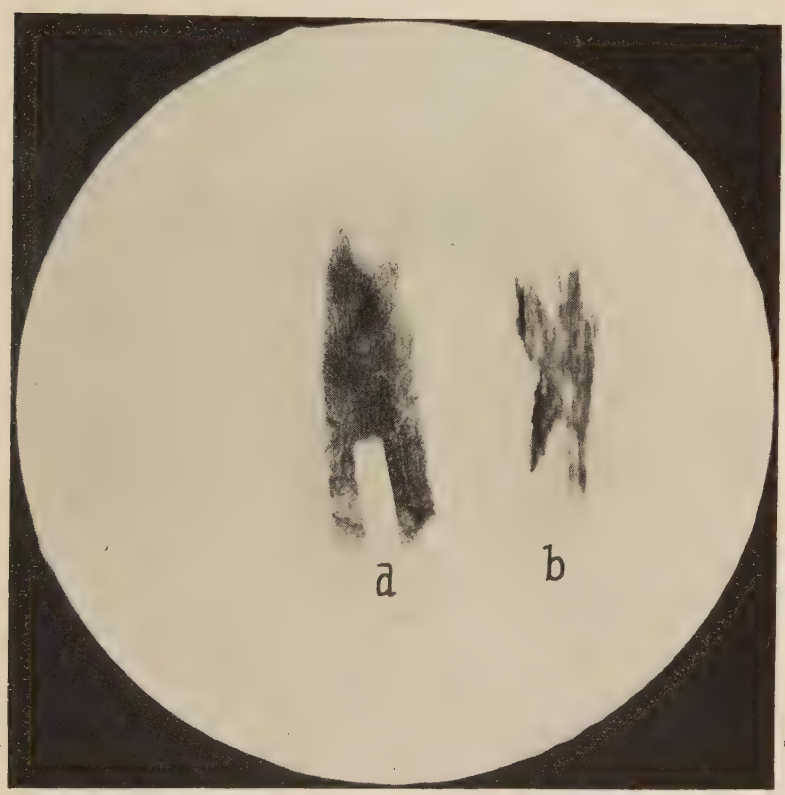

FIG. 5.—*X*-rays of *a*, involucrum from Fig. 13, No. 5, showing even, spongy character; *b*, sequestrum eroded showing reduced uneven density but compact character.

years with only slight reduction in size. This is illustrated by Fig. 2, showing a practically stationary sequestrum with a wide space between it and sclerotic involucrum.

Destruction of dead cancellous bone occurs more readily than of cortex, which usually gives rise to the first changes shown in

the roentgen ray. In acute osteomyelitis of the end of the shaft the entire cancellous portion may become necrotic, but that is not the rule. Usually the dead bone is irregularly distributed

FIG. 6.—Scattered destruction in osteomyelitis of spongy portion of bone; an indirect sign of the presence of sequestra.

and granulations developing from the adjacent surviving portions produce signs of scattered destruction. Fig. 6 shows such a condition in an eight-year-old child with osteomyelitis of the upper end of the femoral shaft of five weeks' standing and a

pathological fracture of the neck. More sequestra than could be identified in the roentgen ray were found at operation throughout the region presenting signs of destruction. Smaller areas are usually completely broken down, and it is rare to see large sequestra persist in this location. But in infected comminuted fractures of the ends of the bones, especially from gunshot wounds, large sequestra may form and persist with little more destruction than comes from formation of a wide zone of demarcation. When bordering on the joint cartilage in the presence of a complicating arthritis the sequestrum stands out prominently because of the preservation of its original density and of the rim of bone supporting the articular cartilage, which on account of its inaccessibility to granulations is not destroyed; whereas that over the remaining living cartilaginous surface is irregularly broken down (Figs. 7 and 8).

A cone-shaped area of necrosis of considerable size is not infrequent in tuberculosis of the metaphysis or epiphysis, and is usually broken down, leaving a cavity. When bordering on the articular surface of the joint such a sequestrum is more liable to persist and maintain its original density. Occasionally calcification will occur in its cancellous spaces and thereby further increase its density, so that it casts a heavier shadow than the corresponding normal area on the other side.

Changes in the Living Bone. Changes in the living bone consist in atrophy and transformation of preëxisting bone and new bone formation.

Atrophy results from disuse and is dependent on the degree and duration of loss of function. A limited osteomyelitis producing partial loss of function for a comparatively short time may produce little atrophy. Extensive osteomyelitis causing marked and prolonged loss of function produces much atrophy. Infected fractures, because of prolonged and complete loss of function produced by the fracture, infection and immobilization, frequently show, after five or six months, the highest degree of atrophy. It is regional and in the case of cortex occurs by diffuse absorption of lime salts, mainly along the course of the

Fig. 7.—Gunshot wound of hip four months old with sequestrum in head casting a more even and heavier shadow than atrophied surrounding bone. Its articular surface is preserved.

Haversian canals, which is slightly more marked on the endosteal than on the periosteal side. This produces an even loss in density which, when marked, may be striated longitudinally by

FIG. 8.—Section of sequestrum shown in Fig. 7. Interior trabeculæ intact and articular surface unbroken except in one place.

the lines of dilated canals (Fig. 9). In cancellous bone there is reduction in numbers and size of trabeculæ in a way that frequently gives a spotted appearance in the roentgen ray. Atrophy of the living bone usually occurs faster than destruction of the

FIG. 9.—*X*-ray of excised wall of tunnel: (*a*) sequestra and shell fragment in gunshot fracture of the femur six and one-half months old. Atrophied cortex of most of wall is longitudinally streaked by dilated canals; sequestra compact.

dead bone, hence after a length of time varying with the size of the bone the dead portion casts a heavier shadow in the roentgen ray than the living (Fig. 12). This relation obtains until there is resumption of function and increase in density of the atrophied portion or until there is further destruction of the dead bone. Then the two portions may be of equal density, but in the living bone it will be evenly and in the dead bone unevenly distributed.

In case of cancellous sequestra bordering on joints this process may be reversed as the texture of the dead bone is even, while the surrounding living bone shows areas of spotted atrophy and absorption from osteomyelitis. This is well illustrated in Fig. 7, of a gunshot wound of the right hip of four months' standing, with sequestrum formation in the head of the femur. Fig. 8 is of a section showing the even texture of the sequestrum.

Transformation of preëxisting bone is of less importance in the recognition of dead bone. In osteomyelitis with sequestrum and involucrum formation the old cortex at the limits of the sequestrum may develop a greater degree of porosity than the remaining living bone from the atrophy alone, and gradually shifts to align itself with the involucrum, leaving the dead cortex in its original position. This shifting occurs fairly early, especially in the thin bones of children, but so late, where thick cortex of large bones is concerned, that it is of little diagnostic value. Transformation occurs late in infected fractures, healed in malposition, but other signs make it possible to recognize the dead bone much earlier.

New Bone Formation. New bone formation occurs along the course of the dead bone from the periosteum unless its osteogenetic elements have been killed, which is frequently so in infected fractures, but rarer in osteomyelitis. It also occurs from the endosteum of the affected level unless the entire circumference has been killed. It extends back on the shaft at the limits of the dead bone and gradually tapers off at a distance, depending on the cause of the infection. The newly formed bone is spongy early, but gradually increases in density (Fig. 5, *a*). With the resumption of function it slowly assumes a lamellated

character. But if there is protracted disuse, as in ununited gunshot fractures, it may in turn undergo atrophy, vacuolation and absorption.

There is a definite line of demarcation between the newly formed bone and dead bone, but none between it and old living bone. However, peripheral callus on the ends of living cortex may be laminated, with an inner spongy and an outer compact layer, which occasionally may simulate involucrum and dead space about a sequestrum. Careful inspection of good roentgen-ray plates will show the presence of a spongy shadow, forming a narrower inner layer than is represented by the dead space about a sequestrum.

Irregular osteophytes and islands of new bone develop, especially as a result of gunshot fracture or secondary to operation, with displacement of osteogenetic elements. The islands are frequently hard to distinguish from displaced sequestra, but as a rule, have a more even density, with dull fading margins, and their spongy nature can be made out in the roentgen ray. Displaced sequestra are usually derived from cortex and have a compact texture with sharp, irregular outlines.

Secondary Bone Necrosis. Secondary necrosis is not uncommon from a flare up in the course of chronic osteomyelitis or from the spread of infection by operation in which extensive fresh-cut or denuded bony surfaces have been created. It differs from primary necrosis in that it usually occurs in atrophied old bone, spongy new bone or a combination of the two. As a rule, large sequestra do not form as the infection is limited. Also further atrophy does not ordinarily occur in the surrounding living bone as is the case after primary bone necrosis. Consequently, the shadow cast by the new sequestrum is not heavier than that of the surrounding living bone and may be even fainter, as increase in density of the latter can occur from resumption of function during the time required for sequestration. Very small secondary sequestra frequently form from the cut or denuded surfaces produced at operation in chronic osteomyelitis or infected fractures. Because of their reduced density it may

be difficult to distinguish them from islands of new bone formed from stripped-off osteogenetic elements or from small chips. The zone of separation forms faster in secondary than in primary bone necrosis because of the more porous character of the necrotic portion. Fig. 10 shows a secondary sequestrum (*a*) which separated four weeks following operation, from one wall (*b*) of a tunnel in a five months' old gunshot fracture of the femur. The wall was removed two weeks later and the sequestrum, placed alongside its defect, casts the same density as the portion from which it was separated.

Shaft that has first hypertrophied from old osteomyelitis and then become porous from years of quiescence of the infection may become reinvolved from lighting up of a neighboring focus. In this case the infection will spread and produce irregular areas of necrosis similar to that in cancellous bone of the ends of the shaft and epiphysis. The roentgen-ray appearance is quite similar in the two conditions. This is well illustrated in Fig. 11. There had been an old osteomyelitis of the lower four-fifths of the fibula beginning nineteen years before, at the age of twelve. It discharged intermittently from the middle and lower portions for four years, at which time dead bone was removed at operation and the lower portion healed. But a discharging sinus leading to the middle portion persisted. There had not been an acute exacerbation of the infection and no interference with function until three and a half weeks before, when an acute osteomyelitis developed in the lower half, leading to extensive abscess and fistula formation. Roentgen ray shows a markedly enlarged lower four-fifths of the fibula, with three distinct types of change. The upper one-fourth is enlarged and fairly evenly porous, with a smooth surface. The second fourth is hypertrophied and contains an irregular canal, with dense walls casting a heavy shadow, in which lies a sequestrum, the lower end of which protrudes through a cloaca. The old fistula leads down to this. The surface in this region is also smooth. The lower half is enlarged and spongy, but throughout there are numerous small irregular areas of reduced density and marked irregularity of the

FIG. 10.—Secondary sequestrum (*a*) from wall of tunnel; (*b*) in gunshot fracture of femur seven months old. Sequestrum resulted from denudation at operation five weeks before it and tunnel wall were recovered. Both have same density.



FIG. 11.—Old hypertrophic osteomyelitis of fibula, cancellous except about sequestrum above middle portion. Acute recurrent osteomyelitis three and one-half weeks old in lower half producing extensive irregular absorption. At operation extensive irregular necrosis was found.

surface, indicative of bone destruction. The entire hypertrophied portion, except the external malleolus, was excised subperiosteally, and the lower half found to be the seat of diffuse acute osteomyelitis, with irregularly distributed areas of necrotic bone and bone absorption. The upper fourth was cancellous but free from acute disease. No doubt the lower half possessed a similar but more marked cancellous structure, which permitted the acute infection, starting from the neighboring chronic focus, to spread throughout its entire extent.

Diagnostic Points in Septic Necrosis. To sum up, the points by which we distinguish between dead and living bone are density, demarcation and contour. These are best determined from a practical standpoint by means of the roentgen rays, and after advent of the period, when they may be of assistance in the management of the condition, can be expressed as follows:

The density of dead bone is greater than that of an equal volume of surrounding living bone. It retains its original compact texture. Living old bone had its density evenly reduced by atrophy and is frequently streaked from dilated longitudinal cannular markings. Newly formed bone is of low density and spongy in texture. These are well illustrated in Fig. 12, showing a gunshot fracture of the femur seven months old. Differences in density are striking. Eight sequestra were removed. Fig. 13 is a photograph of the four large ones that could be identified in the roentgen ray and of a piece of involucrum (5) that encased sequestrum No. 2, the surface of which is markedly eroded, while that of Nos. 1 and 3, which were not covered by involucrum, are smooth. No. 4, presenting a flat surface, was identified by its sharp fracture lines.

There are numerous variations from these general statements. Dead bone when extensively eroded has its shadow density reduced, which may be equal to or below that of the living bone, but is distinguished from the latter by its blotchy, uneven character. Secondary sequestra usually show no variation in density from the adjacent living bone. The line of demarcation between dead and living portions is usually sufficiently wide and

FIG. 12.—Gunshot fracture of 1, femur seven and one-half years old, showing extreme variations in density of dead bone, new bone and old living bone. Dense uneroded sequestra; 1 and 3, uncovered by involucrum. Eroded sequestra; 2, covered by involucrum; 5, thin sequestrum; 4; seen on flat and identified by its fracture line. Photograph in Fig. 13.

clean cut to be of great value in diagnosis, but any oblique or tortuous portions, especially when overlapped by heavy living bone, may be indistinguishable or very imperfectly made out.

FIG. 13.—Sequestra from case shown in Fig. 12. Numbers same.

Notches or unevenly streaked or dotted lines may indicate incomplete separation of the dead piece.

The outline of the sequestrum is of great diagnostic value. Its surface is smooth, sharp and straight where unattacked, but irregular and jagged where erosion has occurred. Sharp spicules, especially about the ends, are frequently to be made out. Preservation of the smooth, curved cortical rim in sequestra bordering on an articular surface and of clean-cut fracture lines late in infected fractures are points of value. The compact texture of dead bone gives its outlines a sharpness that the less dense and frequently growing living surfaces do not possess. Evidence of irregular destruction of spongy bone at the ends of the shaft in osteomyelitis is indirectly a pretty safe sign that dead portions are present even though their outlines cannot be determined.

There are many difficulties in distinguishing dead bone in the roentgen ray, the greatest of which results from overlapping of shadows of necrotic and living portions which obscures the details of each. This can usually be obviated by obtaining views from different angles. Thus a line of demarcation, a sharp point or worm-eaten surface may show plainly at one angle and faintly or not at all at another, and a flat piece of sequestrum seen from the side may show a low density and be unrecognizable, but seen on edge is easily recognized by its greater density. Thick overlying soft parts frequently obscure the finer details of internal structure of different types of bone.

The presence of dead bone can nearly always be diagnosed, but frequently the exact number of pieces cannot be determined especially when they are small. It is a not uncommon experience to find at operation in osteomyelitis and infected fractures twice as many sequestra as were suspected from the roentgen rays.

Fistulæ usually persist as long as dead bone is present, because bacteria invade its canals and cancellous spaces, rendering sterilization impossible and keeping up a discharge. In marked contrast, projectiles in gunshot wounds usually heal in after subsidence of the acute infection, as their interior contains no bacteria and surface sterilization takes place. In old gunshot

fractures it is common to see several pieces each, of dead bone with sinuses at the seat of fracture and missile fragments without sinuses in the adjacent soft parts. Wounds containing small

FIG. 14.—Two small sequestra at (1). Wound healed for three months.

sequestra may heal and remain closed indefinitely, but eventual lighting up of the infection usually occurs. Ununited fractures and defects requiring bone transplantation should be scrutinized,

FIG. 15.—View at a right angle to Fig. 14. Sequestra in fork of upper fragment.

especially for the presence of healed in sequestra, and if such be found they should be removed and the transplantation postponed until the wound has been sufficiently long healed.

FIG. 16.—Transplant of ulna ten weeks old in adult dog. Casts heavier shadow than atrophied fragments above and below.

Fig. 14 shows the roentgen ray of an ununited gunshot fracture of the humerus healed for three months. The two small sharp

Fig. 17.—Transplant *a–b* from tibia three months old in non-union of humerus. Lower 2 cm. (*a*) infected and separated as sequestrum casts a heavier shadow than the rest of the transplant which took and has been transformed.

dense spots (1) in the shadow of the upper fragment suggested dead bone, consequently a view at right angles was obtained (Fig. 15). It shows two small shadows in the fork of the upper fragment which at operation were found to be produced by two wheat-grain sized sequestra that were surrounded by moist granulations.

Density of Transplants. The difference in density between dead and living bone in septic necrosis suggested the possibility of a similar occurrence in aseptic necrosis, such as takes place in bone transplants. Histological studies have shown that nearly all of the transplanted compact bone undergoes aseptic necrosis which, after reëstablishment of the circulation, is gradually replaced, through a process of creeping substitution, by new bone formed from the surviving unossified osteogenetic elements of the transplant in case the latter takes, or growing in from the surrounding bone, where it does not take.

Atrophy would be expected to occur more rapidly in the adjacent living bone than in the transplant because time would be required for the reëstablishment of circulation and the beginning of absorption and replacement of the dead cortex by new and less dense bone. Experiments on dogs, details of which will be published later, show this to be the case. A section of ulnar shaft two-thirds to one and a half inches long, excised and reimplanted, is denser and casts a heavier shadow for four to ten weeks than the adjacent atrophied fragments. This is well shown in Fig. 16 of a ten weeks' experiment. After this time the density of the transplant gradually approaches that of the fragments.

That a difference in density gradually develops between an infected and uninfected portion of a human transplant is illustrated by the following case: A tibial inlay graft was inserted for ununited gunshot fracture of the lower end of the humerus. Mild infection occurred with fistula formation at the seat of the fracture. Fig. 17 shows the roentgen ray at the end of three months. Two centimeters of the lower end of the graft underwent septic necrosis and separated as a sequestrum. It casts a heavier shadow than the rest of the graft which took and has undergone considerable transformation.

NOTES ON CHARCOT JOINTS

By FREDERICK J. COTTON
BOSTON, MASS.

Because of disasters, everyone is afraid of the Charcot joint. Because of poor results no one is interested clinically.

I suspect we have done very badly by them.

This paper can be only the expression of a lately awakened interest on my part and can cover only the clinical aspects of a small group of cases in which treatment seems to have helped.

Already colleagues have volunteered notes of isolated like cases and perhaps a few months of further painstaking study may teach what I think we have not known—the whole "natural history" of these joints; the clinical picture; in whom they occur and why; how they progress; what speeds or stays this progress; why certain cases reach a limit of damage while others go from bad to worse; how far general or local antisyphilitic treatment or treatment of the cord lesion can help; whether they are, or can be made, reasonably safe for operative interference, etc.

We have all seen Charcot joints that had reached a certain stage of tolerance or quiescence; it was a couple of cases that showed, under salvarsan (given on general principles), a real reparative process that aroused my interest.

An astonishing proportion of the Charcot joints, as we all know, occur in cases of tabes so early as not to have been diagnosed or even suspected—so early that motor function is intact; the working problem is only that of the joint and of the preservation of its function.

The first case was that of a man, aged forty-one years, seen in 1915, who had "dislocated" a hip in bowling while in supposedly

perfect health. The hip had been "reduced;" the roentgen ray showed a supposed fracture, really a plaque of new bone. Examination showed some limitation of motion, no pain; also no knee-jerks, and a suggestion of the Argyll-Robertson pupillary reaction.

Careful questioning elicited the story of a half-forgotten infection, of twenty years before, a history of severe "neuralgia" in the legs, two years before, and in some measure to date at irregular intervals, resistant to treatment given by his physician.

There was not a trace of ataxia discoverable.

Patient lean but healthy, exceptionally vigorous and active.

Rest in bed, fixation in abduction for three weeks, then a leather pelvic "spica" belt, fixing the joints and steadying the trochanter, and crutches, then a course of salvarsan treatments by Dr. Otto Hermann.

Very enterprising, he discarded crutches for a cane earlier than I wished, and after about four months even the belt went into the discard. The process was followed with roentgen rays (many of them unavailable now, with other plates of the late Dr. Walter Dodd); destruction went on apace for a number of weeks, then, after completion of the salvarsan course it was checked and the joint, now obviously subluxated, grew firmer.

Today, after five years, he is as active as ever, does an unusual amount of walking, is known as a very successful and progressive man in his business and considers himself well, though he has a limp and carries a cane, though more from habit than from apparent necessity.

The second case, a widow, aged fifty-two years, was sent to me for results of a fracture of eight weeks' duration.

The skiagraph showed an obvious Charcot joint, and I was able to get from her doctor the first roentgen ray taken at the time of the fracture. There was a fracture of the radial styloid, but even then obvious preceding pathological changes were evident in the plate.

There was no history then or since of any knd of infection, but reflexes and pupils confirmed the story and the Wassermann

reaction was positive. She, too, had a course of salvarsan treatment by Dr. Hermann.

Then I tackled the wrist—useless, swollen, shapeless and grating—opened it, cleaned out the loose original fragment, detached plaques of new bone, loose capsular tissue, etc., closed it, and got first intention, and presently, with the aid of a steel-reinforced leather brace, a return of fair function in the hand.

She then developed a mental condition which the neurologist, Dr. J. W. Courtney, called general paralysis; this yielded only slowly to the after-course of mercurials or to time and rest.

Now, after three years, on reëxamination she is mentally normal or thereabouts, conducting her business—a lodging house—without obvious non-success, and the wrist, weak, of course, from lack of the removed section of the radial base, is at worst no worse, is without reaction of any sort and the hand is useful.

Case 3, a fireman aged forty-six years, was seen by me while I was still in military service. He had a Charcot joint of the left ankle, a sufficient history of infection of many (20 plus or minus) years ago, with some treatment, and no later signs of trouble noticed until the ankle began to give some trouble after a slight wrench.

Out of private practice at the time I referred him to the city hospital, where Dr. Nichols did a thigh amputation, precipitated by sepsis at or about the ankle. I understand that the amputated specimen showed an extraordinary degree of syphilitic endarteritis throughout.

Later he came under my care.

What is of interest in this case is the great toe of the other foot, which "went bad" shortly after the amputation and was opened up by one of the junior surgeons, without improvement, but without disaster.

The roentgen rays here shown give the before and after of a treatment with salvarsan and a reasonable protection of this joint by proper, heavy-soled shoeing (in a policeman's boot).

This patient is, or was at last report, an active citizen of the United States, now sojourning in Canada, with one artificial

leg and one police shoe, and I think the roentgen rays confirm the fact of real repair in this once sad-looking joint; function is good, with fair motion and strength, and without grating or pain: the thickening of the soft parts is nearly gone.

Next comes the case (No. 4) of a man of forty, supposedly in good health, who began to have trouble—pain and some weakness in his knee—after some unusually heavy lifting. This grew worse and he went to one of the hospitals, where a diagnosis was made on the basis of the roentgen ray of an early hypertrophic arthritis. The roentgen ray is here shown and corresponds pretty closely with that of the other knee taken at the same time. He grew less able to use the knee, though in no great pain, and when I saw him about two months after the condition clinically was obvious—a thickened knee with some fluid, nearly painless, with marked abnormal lateral mobility and no muscle spasm. The patellar reflexes were gone and the pupils were characteristic. There was not and is not now any ataxia. Nearly twenty years ago there was an infection about which he remembers little. There was no systemic treatment.

In the unfortunate shuffle of hospital responsibilities he dropped into other hands, was told the case was hopeless and no treatment was recommended. About three weeks later I saw him with his own doctor in consultation—told him of my more recent views that I am trying to express here and had him fitted to an apparatus of the "convalescent Thomas knee splint" type, with a slide-lock at the knee and with special plates and pads to correct the bow-leg deformity, which had increased in the three weeks to a marked extent. Otherwise there was no essential change in his condition. He was then put through the usual salvarsan treatment. The Wassermann reaction was positive.

The knee was kept quiet for a time, but after a month put into active moderate use, with the support of the apparatus which was modified at intervals to keep pace with the correction of the bow-leg deformity. Now the leg is practically straight, the abnormal lateral motion decreased from about 25 degrees to less

than 10 degrees and he gets about comfortably and pretty solidly. At present he is looking for a job. His general condition is excellent. The roentgen rays in this case show, what it is suspected we are going to find regularly in these cases when properly treated, a stage of disintegration before repair starts. In the last plates there is certainly an increase in density of bone and no destruction since the last plate of a month previous. This joint will never be cured, of course. Whether it will ever be good enough to go without apparatus I do not know as yet.

But at least the destruction has been checked and a derelict has been transformed into a reasonably useful citizen.

The next case (No. 5) is a tabetic, not an early case—a real advanced tabetic, diagnosed a dozen years ago—known to me for four years or more, but never a patient of mine until this winter, when I was called in to treat the results of one of his many falls. He had fallen five weeks before, striking his right shoulder from behind, injuring his left thumb at the same time.

The thumb showed thickening and subluxation of the first phalanx forward on the metacarpal, with abnormal mobility and loss of power.

The shoulder was a loose joint subluxating forward to the coracoid and back to its socket. There was much swelling—fluid—in front. Pain was little, but loss of ability to help himself about very distressing to him, as his legs and hips are not very useful and there is a good deal of ataxia of the arms. The roentgen ray taken at this time showed almost nothing in the shoulder and only the subluxation in the thumb.

Fixation in this case was very difficult, but with a shoulder cap and adhesive something was done with the shoulder, and the luxation of the thumb was reduced and held by firm adhesive strapping in spica pattern.

The collection of fluid in front of the shoulder persisted. It was tapped twice and permanently reduced. The first tap produced about two ounces of serous fluid.

Examination showed sterile culture and there were no spirochetes to be found by dark-field illumination.

He was turned over to Dr. Hermann and put through a course of salvarsan treatment.

Today his thumb is still strapped and shows thickening, but the abnormal mobility is less, the usefulness greatly better. The shoulder still shows abnormal mobility and thickening and a small collection of fluid, and the subluxation has become permanent, but at much less than its maximum range. Consequently there is some loss of forward motion of the arm, but the usefulness of the joint is much increased. He still wears a shoulder-cap held down by straps

In Case 6 there was a practically spontaneous fracture of the thigh a year before I saw him.

He was treated in the City Hospital, and roentgen rays taken at that time show no bone pathology in the first plate after fracture. Later plates show the development, promptly, of the enormous bony callus one sometimes sees in tabetic fractures. This was a fracture result of tabes, not of gumma.

A year later he came to my service with a spontaneous fracture of the other hip—intracapsular, without impaction. I was suspicious because of the lack of pain and the history, and on examination found signs of tabes and a typical Charcot joint of the great toe on the left—on the side of the first fracture. This had been opened up in another hospital six months before without disaster, and was not progressing.

The broken hip was protected with plaster and later with a Taylor hip splint. He was given salvarsan treatment as usual, though we did not get a positive Wassermann, even of the spinal fluid, and under the provocative treatment.

He is not yet bearing weight, but the abnormal mobility is less.

The series of roentgen rays show no progress of distinction about the fracture, but do show the progress of excess bone formation—in plaques—about the joint.

Case 7 was seen in consultation with Dr. McIvor Woody in February, 1920—sent to him with regard to the results of a Potts fracture dating from July, 1919.

The lateral deformity was extreme, the mechanical defect disabling through clumsiness and fatigue, though there was no pain. Wassermann reaction weakly positive. No sign of ataxia, but very weak knee-jerks and an Argyll-Robertson reaction. The roentgen ray showed a typical Charcot joint, with an old fracture of both malleoli, the internal ununited. There was also much thickening (reparative?) of the lower ends of both bones. There was a history of infection of many years before.

Salvarsan was given, and a brace that partly reduced the deformity and gave fixation of the joint, enabled him to return to active business pretty efficiently.

The eighth case is of a transition class: An Italian, speaking almost no English, was admitted to my service because of an ankle injury, sustained a year before, resulting in disability from loss of power, not pain. He showed a weakly positive Wassermann reaction, weak knee-jerks, doubtful pupils. Dr. J. J. Thomas, neurologist, says he has early tabes.

The ankle shows much thickening; no abnormal motion; no pain.

The roentgen ray shows no sign of fracture, but as you see the huge bone-thickening. There is a characteristic specific thickening on one humerus.

Perhaps this man has tabes—the joint is obviously a specific lesion rather than a typical Charcot joint

He is under salvarsan treatment; he will be given a fixation brace for walking, and observed.

In this connection two cases are of interest: Case 9, a boy of ten years, three years under treatment with salvarsan and mercury for a massive thickening of one tibia, with ulcerations of both shins. The case is an amply proved congenital syphilis. The soft part lesions are healed and the symptoms gone; but the roentgen ray shows little change in the hypertrophic bone.

Case 10, a woman, aged twenty-seven years, syphilitic but not tabetic. A year's history of trouble with one knee, weakness, catching, grating, effusion, muscle-atrophy; little pain. Various treatment without avail.

The diagnosis once made, salvarsan treatment and protection of the joint were proceeded with.

Three months brought about a complete clinical cure, save for very slight grating and a trace still of the muscle wasting.

But the roentgen ray (hardly to be distinguished from that of the middle stage in Case 3, a real Charcot joint) shows between these dates no change in the joint-bones save slight smoothing and a return of normal density.

In these two cases, in the ankle just shown, in the ankle of Case 7, in the healed thigh in Case 6, we have a parallel condition, cure of clinical symptoms (save the mechanical ones), recession of damage to soft parts, including thickening, without resorption of hypertrophic changes, and, under treatment, apparent increase of repair bone.

And this seems a common phenomenon to the conditions we call syphilitic and to those we call tabetic in origin—which suggests that after all the line between the Charcot joint and the syphilitic joint may be no line at all, as I suspect.

There is nothing new in all this, you will say, and there is not.

We have all seen the remarkable tolerance of some horrid-looking Charcot joints to prolonged use: some cases have been helped with supports; many have been given routine anti-syphilitic treatment.

All that is new is the point of view, I think.

We have thought of Charcot joints as one loss, not recoverable in the losing game of the patient with locomotor ataxia.

Please think of the lesion, as I have come to think of it, as a joint disease that occurs in syphilitics, not always or even usually crippled by ataxia—a lesion not completely curable, perhaps, but not without chance of repair, capable rather under proper handling of restoration to safe use.

Probably such early cord changes as exist are permanent: whether anti-syphilitic treatment will surely check such changes when they are is doubtful:

But as to the joints, let us handle them as syphilitic joints. They may occur only in the presence of cord changes: they

certainly are aggravated, as they are said to be caused, by the trauma of use of an insensitive joint. The changes are unlike those of any trauma I know; they occur only in syphilitics, oftenest with tabes so early as to be hard to demonstrate, are much like syphilitic cases under no suspicion of tabes, and I think of them as syphilitic joints, and think the syphilitic end should receive first attention. So treated the damage to other than bone structures repairs. The bone process reaches at least a standstill. Whether this improvement warrants daring to operate on suitable cases for ankylosing or reshaping or capsule-reefing operations it is early to say. My one operation and the two incidental ones noted on two other cases give some color to this idea.

At all events, here is a class of joint lesions mainly associated with a tabes so early as to have given no disability and no other symptoms than the joint—a class of cases hitherto usually "given up," and neglected, in which it appears that useful work can readily be done, with the prospect of better development to come.

DISCUSSION OF PAPERS ON BONE SURGERY

Dr. Carl A. Hamann, Cleveland:

With regard to Charcot's joint I would mention a case in which I resected a knee-joint in a typical instance in a man in middle life. There was a large collection of fluid. At the end of seven weeks there was no union between the bones: the skin had united, and there was a large collection of fluid but the limb was useless, so I amputated. This case confirmed me in my suspicion that there is no use resecting these knee-joints, owing to the trophic disturbances, for no union will be obtained.

Dr. Astley P. C. Ashhurst, Philadelphia:

Dr. Cotton says there is no real distinction between syphilitic and Charcot joints. Clinically this is not so, but it is a question whether there is any pathological distinction. I do not know whether anyone has examined enough Charcot joints pathologically to have determined whether the treponema is ever found in them. It is supposed to be found in syphilitic joints. I have had pathological examinations made in two cases of Charcot joint, but the pathologist (Dr. C. G. White) found no histological evidence that they were syphilitic. I believe that they depend for their existence on the spinal-cord lesions, and that there is no necessity for any local syphilitic lesions; whereas in true syphilitic arthritis the syphilitic lesions are local and the joint condition is in no way dependent on any spinal-cord lesion. In syringomyelia changes may occur in the joints very similar to those seen in tabes.

I want to say a few words about Dr. Buchanan's interesting paper. I think anyone who has operated much around the hip-joint knows how difficult some of the operations are. About fifteen years ago I helped Dr. Harte operate on a dislocation of the hip which could be reduced but would not stay fully reduced. Dr. Allis brought his apparatus (with which Dr. Buchanan tells me he has had personal experience), and tried to reduce the dislocation but failed; and both Dr. G. G. Davis and Dr. Harte were unsuccessful in securing or maintaining full reduction, and therefore operation was decided on. Dr. Harte did what I considered at the time an unnecessarily radical operation, excising the head of the bone. I thought it might have been possible to reduce the dislocation at the time; but the patient had a fracture of the upper rim of the acetabulum as well, and whatever else might have been done, the end-result is very satisfactory. This

man has been on a ranch for fifteen years, riding horseback and doing all kinds of work; so that in some cases of irreducible dislocation of the hip, the operation of excision deserves consideration. I have also helped Dr. G. G. Davis in operating on quite a number of congenital dislocations of the hip in adults; he came to the conclusion, which I think is a just one, in cases where it is not possible to secure reduction even by open operation, that you can improve the patient's condition by forming a new acetabulum just above the normal acetabulum so that the weight-bearing point will come into the midline antero-posteriorly instead of being posterior. The anterior incision, on either side of the sartorius, is that which Dr. Davis employed in most of his operations; though he also adopted occasionally Ludloff's incision along the adductors, passing beneath the pectineus muscle, or sometimes superficial to it. But none of these incisions give as adequate exposure as does that used by Lambotte of Antwerp. This passes from the anterior superior spine to the great trochanter and from there downward and forward. You cut the tensor fasciæ and the fascia lata, turn a large flap forward exposing the hip-joint just below the gluteus medius; by this incision you get a good exposure of the head of the femur and of the acetabulum.

Dr. Frederic J. Cotton, Boston:

There are some points in Dr. Phemister's paper which I would like to bring out. It seems to me that in our effort to know if dead bone is present, we are apt to fall into certain errors. The first point is that live bone which is not in contact with other bone fails to undergo the same modifications that the live bone does; if not in contact with other bone it will fail to take part in the osteoporosis as if dead. This gives a chance of confusion. I suppose it means that the bone is cut off not only from the circulation but also from any trophic influence. Varying shadows stand out in the field in a way that looks like dead bone, and I have seen them so presented as to lead to unnecessary operations. Another point is that in the osteoporotic reaction a thin bit of cortical bone seen on edge is deceptive and may be operated for as a sequestrum. The third point is that the involucrum very often as a result of simple irregularities of growth forms transparent lacunæ which we take for "Brodie abscesses." I have seen that mistake in a few instances.

Dr. Albert J. Ochsner, Chicago:

A word regarding the dislocation about which Dr. Buchanan has spoken. It is thirty-one years since I had the experience mentioned

as an assistant to Dr. Parkes. The points that impressed me were: first, the importance of preliminary traction to get as much length as possible; second, the large incision; third, getting the thigh in the approximate position it occupied when dislocation took place; fourth, loosening the adhesions which exist; fifth, absolute asepsis and sixth the use of thin steel spatulæ which the surgeon insinuates at various points until the head of the bone slips back into place.

We have had quite a little experience with Charcot joints and have been surprised at the benefits since beginning two years ago with the use of spinal puncture, immediately after making intravenous injection of neosalvarsan. The patients have done very much better since adoption of this method than they did by the use of salvarsan before. We take out 5 c.c. of fluid the first time, 10 c.c. the next time, and if no headache 15 c.c. the next and 20 c.c. the next, up to 25 or 30 c.c., but usually there is headache before this point is reached.

We give from six to twelve injections averaging 0.6 c.c. of neosalvarsan at intervals of five to ten days.

Dr. Harry M. Sherman, San Francisco:

I would like to say one word about the incision for old dislocations of the hip. I have had a couple of them. The incision from the anterior superior spine downward between the tensor vaginæ femoris and the rectus femoris cuts nothing but connective tissue and a few bloodvessels; it is not necessary to cut any muscular tissue at all to get easily at the hip-joint or between the acetabulum and the luxated head.

Dr. D. B. Phemister, Chicago (in closing):

I have obtained five Charcot joints by amputation or at autopsy, and I have examined all very carefully for evidence of lues and have found none. Three have been examined for spirochetes but none found. You see just as severe Charcot joints in syringomyelia as in tabes, and there the matter of infection is out of the question. The experiments of Eloesser, of San Francisco, on cats makes it conclusive that the Charcot joint can be produced by sectioning the posterior nerve roots destroying the protective sense of pain and leaving motor power intact. I note the fact that Oehlecker, of Hamburg, has examined a number of cases for spirochetes and has not found them. Charcot joint is more in the nature of a traumatic arthritis deformans secondary to the nerve disturbance which removes the protective sense of pain and permits the joint to be knocked to pieces. Antisyphilitic treatment may improve the nervous lesion in tabes, which

secondarily would influence the joint and mechanical support would have a favorable effect. While Dr. Cotton's results represent a definite step forward in treatment I do not believe they demonstrate definitely that Charcot's joint is a syphilitic arthritis.

Dr. Frederic J. Cotton, Boston (in closing):

I do not claim to have proved Charcot joint to be syphilitic but we get on better basing our treatment on that suspicion, rather than on the older idea of a hopeless lesion of locomotor ataxia.

DIAPHRAGMATIC HERNIA

By FRANK S. MATHEWS, M.D.

AND

H. M. IMBODEN, M.D.
NEW YORK

In view of the considerable number of recent papers dealing with the subject of hernia of the diaphragm, it will only be necessary in this article to describe a case with the roentgen-ray findings and call attention to some of the points of interest.

Mrs. W. P., aged fifty-five years, multiparous, at the time of operation was a woman in apparently good health and stout, rather than muscular, with a history of recent increase in weight. The symptoms relating to the present difficulty date back through ten years.

First, almost daily, after eating a meal, she would put her finger down her throat to encourage the expulsion of gas, which gave her a feeling of oppression in the chest.

Second, during the entire ten years, at intervals of from a day to three months, but without any regularity, she had attacks of pain following eating. The pain was severe, epigastric or higher, and largely referred to the heart. She became pale and her pulse was said to become weak. To onlookers she appeared to be strangling. She would make efforts to belch gas, and if she succeeded the pain was immediately relieved. In some cases it required an hour or two before any gas was evacuated.

Third, by degrees she learned to modify her diet so as to limit the distress after meals, though she could not prevent the acute,

severe attacks. The type of meal that gave her least discomfort was one of concentrated food and small bulk—that is, meat, potatoes and eggs, with no soups, desserts or green vegetables. These attacks began abruptly ten years ago and have continued without any noticeable change in the character, severity or frequency of the attacks.

FIG. 1.—Stomach in thorax, behind and right of heart.

Three years ago a series of roentgen-ray pictures was made, on which was based the diagnosis of diaphragmatic hernia. The patient was referred for operation by Dr. W. A. Bastedo, who confirmed the presence of the stomach in the chest by physical examination. The roentgen-ray report, made November, 1916, is as follows:

"The stomach is entirely above the diaphragm and is in the right, lower portion of the thorax, extending about two inches to the left of the left sternal line. The upper border of the stomach is about eight inches above the right diaphragm. The stomach and the colon are posterior to the heart. The opening

FIG. 2.—Stomach, side view, containing air and bismuth.

into the sac is in the posterior portion of the diaphragm near the midline. The pylorus projects down toward the pelvis, parallel to the spine. The duodenum is also directed downward. The second portion of the duodenum is directed down. The third portion is transverse and the fourth portion is directed upward

but joining the jejunum at the level of the third lumbar vertebra on the left side.

"There is no evidence of disease about the pylorus, or the first portion of the duodenum, but at no time were we able to get a satisfactory shadow of that portion of the stomach passing through the ring.

FIG. 3.—Distended colon, mainly in right chest.

"The stomach empties itself rather slowly. Seven hours p. c. there is a slight residue in the stomach.

"The meal passes rapidly through the small intestine.

"Three hours p. c. some of it is already in the hepatic flexure region.

"Thirty-six hours p. c. most of it was discharged, with the exception of a quantity in the descending colon, sigmoid and rectum.

FIG. 4.—Side view of the same.

"An opaque enema revealed an unusually long transverse colon, most of which is in the hernia sac. We found no evidence of obstruction or occlusion of the colon, though where the two limbs pass each other in the ring, they are in rather close apposition.

"Some of the plates of the colon indicated that a portion of it occasionally slips out of the sac.

"The only explanation we can give to account for the patient's discomfort is the enormous gas bag in the stomach, which lies above the esophageal opening. We fail to find any evidence of disease in any portion of the alimentary tract.

(Signed) H. M. Imboden."

Fig. 5.—One year postoperative. Stomach mainly in abdomen.

Operation (Mathews) was performed December 17, 1918, under intratracheal anesthesia. Incision eight or nine inches in length in the left midrectus line from the costal margin down-

ward. The patient was put in the position of a reversed Trendelenburg. No part of the colon was in the hernial sac. Most of the stomach was in the sac and was drawn downward entirely out of the hernia without great difficulty. Its wall was thick and leathery. The hernial opening was the enlarged esophageal one. Because of the depth of the abdomen due to the patient's large size and obesity it was not easy to expose the orifice to sight. Two mattress sutures of heavy chromic gut were with

FIG. 6.—One year postoperative. Colon entirely in abdomen.

difficulty placed at the anterior margin of the ring. The ring was at least two inches in diameter and by means of the stitches seemed to be considerably narrowed. The stomach was then sutured to the whole length of the abdominal incision. It was drawn downward as far as possible and the first suture was inserted through the posterior rectus sheath and peritoneum and included a bite of the stomach wall just in front of the lesser curvature high up toward the cardia. The suturing was con-

tinued down obliquely across the front of the stomach for a distance of about eight inches. Sutures were placed about one-half inch apart and took a firm hold on the stomach wall. The remaining layers of the abdominal wall were closed with silkworm and catgut. Patient was kept in bed two weeks, with the head of the bed elevated, and on discharge from the hospital was advised to restrict diet and encourage catharsis in order to keep down intra-abdominal tension.

At the present date, May 1, 1920, the patient has been entirely free from attacks, has abandoned her diet of small bulk, is not compelled to belch after eating and now eats anything. Her weight is considerably increased. Roentgen-rays taken after bismuth meal a few days ago by Dr. Imboden show that the stomach stands almost vertically, as though still adherent to the abdominal wall for the length of the suture line. A small portion, possibly the upper fourth, is in the chest. Bismuth enema shows that the long splenic flexure and transverse colon, which formerly entered the thorax, now lie to her left and entirely below the diaphragm.

Comment: The case is interesting from a number of standpoints—not the least being that the distressing symptoms of ten years' duration have been completely relieved by an operation of no great severity and which did not remove the sac nor could it close the ring, both because of technical difficulties and because it was the normal opening for the passage of the esophagus. The patient's milder attacks of discomfort were evidently due to an air-filled stomach occupying space intended for the lungs. The more severe attacks would seem to have been due to a greater distention of the stomach with food and air and not unlikely a mild sort of strangulation. In entering the sac the stomach seems, according to roentgen-ray evidence, to have turned over on a transverse axis, so that the greater curvature lay higher in the chest than the esophageal opening, and so kinked the entrance of the stomach that emptying itself of air through the esophagus became difficult or for a time impossible.

In the literature these hernias are generally recorded as occur-

ring through the left diaphragm and usually occupying the left part of the chest, pushing the heart to the right In this case the heart was not displaced and nearly all of the sac was in the right chest. A hand could be inserted a short distance into the hernial sac but obtained no evidence of communication with the pleura, as is at times found, especially in congenital cases.

Intratracheal anesthesia was very satisfactorily employed and is highly desirable because of a possible communication between the peritoneum and the pleura. The positive pressure in conjunction with the reversed Trendelenburg position was a great aid in keeping the contents of the sac reduced Even then there was quite a tug upon the stomach with each inspiration It is worthy of comment that this hernia of at least ten years' duration was without adhesions, though the stomach wall showed very noticeable departure from the normal, and it is rather remarkable that the colon should have been able to enter the chest to such an extent through a rigid ring and not have given rise to any symptoms. In entering the chest, it would seem to have passed up in front of the stomach, and the purpose in suturing the stomach to the abdominal wall was to keep the colon as well as the stomach from entering the hernia.

DISCUSSION

Dr. Arthur Dean Bevan, Chicago:

I laughingly told a colleague, who had referred a diaphragmatic hernia to me recently, that I was a specialist in hernias of the diaphragm; I have recently had four of them and I have to say that our experience has been very similar to the speaker's. When I operated on my first case, I was surprised to find that the opening was very easily found and very easily closed and that it was at the esophageal opening. On looking over the literature I found three different groups, the congenital, the traumatic and the acquired diaphragmatic hernia. The latter occurs always at exactly the same point, at the esophageal opening, just as an inquinal hernia is always at the external abdominal ring. The technic in operating for them has been interesting. I think a very wide exposure is necessary. We have adopted a large S-shaped incision on the left side larger than we use on the right side for complicated common duct work. The technic of pulling the contents down from the thoracic cavity is usually easy, although I have had one case where the entire omentum was in the chest and adherent, and it took twenty minutes with blunt dissection to separate the omentum and get it down. The opening was very large and we had no difficulty in taking a big bite of the pillars on each side of the diaphragm and in closing the opening with suture so that the omentum and stomach could not return into the thorax. In all our cases we have in addition to closing the opening stitched the stomach to the diaphragm, and in the last case not only did we do this but stitched the stomach, because it was difficult to prevent its slipping back even after the closure, to the anterior parietal peritoneum. Our results in the cases have been quite complete, the *x*-ray showing no stomach contents in the thoracic cavity after operation. One very interesting element in etiology developed in one case; the woman on whom we operated had a part of the stomach and transverse colon in the chest; we brought this down and without difficulty closed the opening; I noticed, however, that the colon was rather dilated and I attributed that to the displacement. She blew up after the operation and died within a short time, and at the postmortem we found a small circular carcinoma of the splenic flexure, and I submit this as an etiological factor in the production of the hernia, the gradual distention of the intestinal tract forcing an opening in the diaphragm.

Dr. James F. Mitchell, Washington:

I should like to report a case very similar to that of Dr. Mathews. This was a woman about fifty, quite stout, who had been treated for

ten years by various stomach specialists for gastric ulcer. I saw her at the end of a period of six weeks during which she had been in bed with a duodenal tube inserted through which she was being fed. I saw her at midnight when she had apparently acute obstruction with projectile vomiting in large amounts. The next morning I operated on her, not suspecting a diaphragmatic hernia. On opening the abdomen we were struck by the fact that there was no omentum in such a very stout woman. No large intestine could be seen, no stomach could be seen, and I then divined the cause. The opening was not at the esophageal opening but close to the anterior chest wall on the left side. Through this had passed the whole stomach, the transverse colon and this pulled after it the omentum. It passed anteriorly to the heart then went to the right side, filling practically the whole right chest. I could put my hand through the opening in the diaphragm, and could pass it across to the right chest, where I found the lung was contracted in the upper and median part of the right chest. It was remarkable how easy suture of this large opening was. It was closed with catgut. Being so close to the chest wall there was very little tissue on the rib side to strengthen my suture line and in order to do so I dissected back the skin flap and passed some mattress sutures through the chest wall and anchored the diaphragmatic opening to the chest wall in this way. She made a complete recovery and has been well for five years. The rapidity with which the lung, which must have been contracted for a great many years, expanded was remarkable; in six weeks it was completely expanded as shown by *x*-ray and no sign of the sac was left in the chest.

Dr. John H. Jopson, Philadelphia:

I have observed two cases of diaphragmatic hernia. The first was in a man operated on several years ago for an actively bleeding duodenal ulcer. He was seen by an expert internist who considered his condition demanded operation, although active hemorrhage was going on. He was in extremely poor condition and on opening the abdomen I found the stomach distended with blood and a perforating ulcer on the posterior wall of the pylorus adherent to the pancreas, and the entire small intestine out of sight. His condition became very bad on the table and he succumbed before further procedure was possible, but later examination showed the larger part of the small intestine had found its way into the left pleural cavity. The condition was probably congenital. The second case was seen in consultation at Base Hospital No. 18, A. E. F., the patient, a soldier, being admitted with obstruction of the bowel. Drs. Stone and Watt were the sur-

geons. They operated at a time when he had been ill for forty-eight hours. They delivered a portion of the descending colon which appeared to have been constricted somewhere in the upper left hypochondrium, and relief was thought to have taken place. For twenty-four hours he was better, then obstruction returned and several days elapsed before a second operation was done, and at this time it was found that he had a strangulated or incarcerated diaphragmatic hernia of the left side involving a considerable portion of the large bowel. By an abdominal incision supplemented by thoracotomy the bowel was delivered and the diaphragm sutured from above. The accessibility of the opening by this transthoracic route was well demonstrated, and we know it is a valuable procedure in certain cases of wounds of the diaphragm. This patient made an excellent recovery.

Dr. Frank S. Mathews, New York City:

From the discussion as well as the literature on diaphragmatic hernia, we are impressed by the great variety in type and symptoms of these cases, and secondly that the mode of attack and type of operation must vary according to the case. After a few more of them have been recorded, we are likely to begin to suspect the condition from the clinical history before the confirming *x*-ray examination is made. In the last case I have encountered the condition was revealed by *x*-ray examination made during a course of pneumonia. Some are first discovered at autopsy even in patients of advanced years, who possibly have given few symptoms during life.

ONE YEAR'S (1919) WORK IN HYSTERECTOMY IN THE LANKENAU (FORMERLY THE GERMAN) HOSPITAL, PHILADELPHIA

INCLUDING THE WRITER'S EXPERIENCE WITH RADIUM IN UTERINE CONDITIONS DURING THE YEAR

By JOHN B. DEAVER, M.D.
PHILADELPHIA, PA.

WITH REMARKS UPON PATHOLOGY BY

STANLEY P. REIMANN, M.D.

The year's (1919) work in hysterectomy at the Lankenau Hospital of Philadelphia comprises 130 operations, of which 46 were complete and 84 subtotal. Two deaths in the entire series yields a mortality of 1.5 per cent.

A complete hysterectomy was done for simple uncomplicated fibroids in 7 instances and in 14 for fibroids, with one or more complications. In addition to these there were 10 cases of prolapsus uteri, with acute or chronic inflammation of the cervix, tubes and ovaries necessitating a complete hysterectomy. The series also includes 5 cases of carcinoma of the uterus, 1 of which presented extensive ulceration, gangrene and purulent infiltration at the site of radium treatment, by no means an isolated instance of its kind that has come to my notice. The 1 death among the complete hysterectomies was due to myocarditis.

Subtotal hysterectomy for fibroid was done in 84 cases, 12 being simple non-complicated and 72 complicated, the complications being salpingitis, tuboövarian inflammation, pyo-

salpinx, anomalously located fibroids, pregnancy, nephritis, endocarditis, etc.

In this series of 84 cases there was not a fatality. Malignancy was present in 2 instances, in 1 associated with carcinoma of the breast. Sarcoma was noted in 1 case. In 7 instances degeneration of the myoma had occurred, hyaline 6 times and calcareous 1. Adenomatous polypi of the uterus, cervix or both were present 5 times.

The fatal case in this series was due to enterovaginal fistula, the result of radium treatment.

Total hysterectomy for fibroid or fibroids should be the better operation, particularly when the patient is near, at or passed the menstrual epoch, and especially when there is any doubt about the condition of the cervix or the endometrium. Were this the usual practice there would be less likelihood of subsequent carcinoma and a recurrence of the fibroid of the cervix, which I have seen, necessitating a difficult operation for its removal.

The operation I make in subtotal removal is amputation of the supravaginal cervix by a V-shaped incision, which leaves a wedge-shape cavity in the cervix, into which cavity I implant the stumps of the broad ligaments, the operation being completed by bringing over the stump and stitching to the posterior surface of the cervix, the reflected flap of the peritoneum carrying the bladder with it, the lattter being made the first stage of the operation.

In total removal of the uterus I free the upper portion of the vagina with the uterus, apply a right-angle clamp to the vagina and amputate with the actual cautery, closing the vagina by continuous suture carried around the clamp; clamp removed and ligature secured. The stumps of the broad ligament are fixed to the vaginal stump and all covered by pulling the reflected peritoneal flap backward and over the stump and stitching to the posterior wall of the vagina. This makes an extraperitoneal operation practically, and thus avoids a possible chance of infection from the vagina. I practise this operation with satis-

factory results in a percentage of cases of complete prolapse of the uterus and the vagina, or of the vagina alone.

In large soft myomas, which at times make the uterus look so much like a pregnant one, I have no hesitancy in incising through the anterior wall of the uterus, thus making sure.

My confidence in the operation of transperitoneal hysterotomy is so great that I have equal confidence in opening the uterus to the light of day under the above-mentioned conditions. The other and many complications arising in connection with this form of surgery are so familiar to you all that I will not discuss them, nor is it necessary for me to say that submucous fibroid of the uterus, that cannot be safely removed through the cervix, is best and most satisfactorily handled by making a transperitoneal hysterotomy.

When the fibroid uterus is very large or the fibroid grows chiefly from the supravaginal cervix or out into the broad ligaments, I frequently am able to shorten the operation as well as have less blood lost by amputating the supravaginal cervix from side to side, from behind forward or splitting the uterus vertically, etc. The uterus amputated, the cervix grasped and held steadily with a volsella forceps is readily removed.

The greatest danger of complete hysterectomy is, of course, the risk of injury to the ureters. But this can be avoided by exposing the ureters well back in the broad ligament and tracing them forward to the bladder, so that they are constantly in view when tieing off the vessels. But should accidental lateral ligation of the ureters occur, as it may even to the most expert operator, it manifests itself promptly and can be corrected.

Myomectomy for the subserous pedunculated fibroid is a very satisfactory procedure, but the submucous type, provided it does not present or project into the cervix, is to my mind better attacked by transperitoneal abdominal hysterotomy.

For large-sized intramural fibroids also, I believe, a subtotal or complete hysterectomy to be much less momentous, from the standpoint of immediate and of secondary bleeding, than myomectomy. So many of this class of patients are highly

anemic that there is danger in any operation that is attended by even a minimum loss of blood. Furthermore, it is my experience that most of the women with fibroid uterus are sterile, so the argument that some few become pregnant after myomectomy does not affect my view, although I admit it to be a debatable one, especially as I have known a few instances of recurrence of fibroid in a myomectomized uterus, so that this possibility must be reckoned with.

A full discussion of any one point mentioned would take more time than the rules of the Association permit. I have therefore contented myself with merely touching upon them. If I have succeeded in instilling the necessity of caution as to the use of radium into the minds of those present I shall be satisfied.

During the same year (1919) 58 cases were treated with radium, 39 for carcinoma of the cervix, 12 for carcinoma of the uterus, 5 for myoma uteri and 2 for chronic endometritis. One death makes the mortality figures about the same as in the operated series. While, of course, figures standing alone are not convincing, I believe they speak favorably for surgery in this instance. I emphasize this the more especially as I am so often confronted with the destructive action of radium, such as gangrene, ulceration and purulent infiltration at the site of the application, that I must necessarily hesitate to sound its unqualified praises.

With the introduction of any new therapeutic agent there very naturally arises the hope that the solution of a perplexing problem is at hand. Radiation in the treatment of disease of the cervix and uterus has proved no exception to this rule. More or less enthusiastically, usually more, during the past several years the roentgenologist and radium therapists have been so loud in their praise of their results that the protesting or opposing voices have been in danger of being drowned. It is not, however, as a total opponent to radiation in the treatment of these diseases that I ask to be heard at this time, but rather for the purpose of introducing a different note, perhaps in a lower key, into the melody.

First and foremost I believe that in the decision for or against the use of radium the voice of the surgeon should be accorded equal if not greater weight than that of the radiologist. Every open-minded surgeon is free and indeed glad to acknowledge that radium can control uterine bleeding, in fact arrest it; and that together with the roentgen ray the size of intramural and submucous fibroids can be reduced if not entirely dissipated. But there remains to be considered the effect of the presence of mutilated and destroyed tissues. Is not a woman better off without a uterus or with only the neck of one than she who harbors an organ that has been burned to death? Is not this a rather undesirable tenant of the human body? Better an empty house than an undesirable tenant. Moreover, radium treatment for fibroids has, in four instances that have been recently brought to my attention, been the direct cause of death, the fatal outcome being due to peritonitis in one case, rectovaginal fistula in another and extensive pelvic suppuration in the remaining two.

It is my practice to make a transperitoneal complete removal of the uterus in all cases of carcinoma of the fundus and in very early carcinoma of the cervix. I am sure this is better practice than is the use of radium in this early stage. Recalling the free lymphatic supply of the cervix and that the lymphatics pass through the broad ligaments, is not this a better surgical procedure than to apply radium? Radium should in my judgment be used only in the late cases, those in which lymphatic involvement has gone beyond the reach of the knife. In the latter class of cases, radium properly used without doubt prolongs life, but that it cures, I doubt. I have never seen a case of advanced cancer of the cervix, where the entire cervix has been involved, cured by radium. I have, under the latter circumstances, seen the cervix under the administration of radium practically returned to apparently normal conditions, but, sad to say, followed by recurrence in a comparatively short time, which recurrence in my experience is seldom benefited by the further use of radium.

Even in the non-malignant uterus with free hemorrhage, where

in the absence of appendiceal complications radium has a recognized field, the cases should be judiciously selected. Menorrhagia in a young woman is a serious matter and requires careful study. Very often hysterotomy is the better method for arriving at a correct diagnosis and determining existing pathology, and is indicated rather than curetting through the vagina or the application of radium. Too often I fear the specialist may yield to the persuasion of his clients and administer radium to relieve the inconvenience of menstruation prolonged a day or two beyond the usual time, unmindful or perhaps ignorant of the fact that the unwise use of radium in a young woman suffering from menorrhagia or metrorrhagia is liable to lead to sterility. It is against such illegitimate use of the substance that I would register a most serious protest.

While in some cases of chronic endometrial inflammation radium has proved useful, I believe here also it should be used only after all other recognized means of treatment have failed.

Very often the differentiation of quiescent appendicular inflammation and latent non-palpable tubal disease can be made only by opening the abdomen and inspection; therefore, in the presence of this uncertainty as to the propriety of using radium the knife is the better arbiter in the matter.

In a number of cases of purulent leucorrhea, radium has failed to be of value, and while curetting, cauterization of the endometrium or the application of iodin, etc., may be efficacious, there is little chance of these measures proving so on account of the probable involvement of the tissues adjacent to the endometrium, so that removal of the uterus either by the transperitoneal or the vaginal route offers the only hope of a cure.

Since the demonstration of normal cyclic changes in the endometrium, much confusion regarding hypertrophy and hyperplasia of the endometrium has been cleared up. The pathological diagnosis of hypertrophic and hyperplastic endometritis is made very much less frequently than before. That there is, however, a type of change in the endometrium consisting of both hypertrophy and hyperplasia is unquestioned, but its frequency is comparatively low. Irrespective of changes

incident to the menstrual cycle, a few uteri will show a shaggy, thickened endometrium, sometimes pale, often with small areas of congestion or even hemorrhage. This fringy condition is very often not universal but focal, and is especially seen over myomata projecting into the uterine cavity. Histologically the glands are larger, increased in apparent number, and oftentimes appear in marked corkscrew form. Excess secretion and rarely red blood cells are seen in the lumina of these glands with congestion of the interstitial tissue.

Cellular infiltrations, if due regard be paid to the menstrual cycle, are relatively uncommon. They may consist of plasma cells and inflammatory lymphocytes. At the menstrual period cellular infiltrations in which the polymorphonuclear leukocyte appears in goodly number, are, of course, the rule. Cystic changes are also occasionally seen in the hypertrophic endometrium; the cysts are microscopic and may be empty or contain varying amounts of debris.

Chronic endometritis in the sense of fibrosis and round-cell infiltration is one of the rarest of changes observed in our specimens. In several instances it was definitely associated with long-standing inflammatory processes in the adnexa. With the average run of specimens the number of times an endometritis can be diagnosed is very small. Those in which acute endometritis varying from mild to severe, almost phlegmonous, type occurs are constantly associated with acute inflammations of the adnexa.

The subject of myopathic hemorrhage has received considerable attention and quite extensive pathological and histological investigation. The consensus of opinion at the present time is that the hemorrhages are due to functional disturbances of the ovary and associated ductless glands. Certain it is that definite, constant pathological anatomical changes, either in the endometrium or ovary, are conspicuous by their absence in certain cases of uterine hemorrhage even when constitutional causes, such as incompetent myocardium, anemia, etc., can be ruled out. This explanation in a way avoids the issue; it takes the place of explanations such as apoplexia uteri, endometritis

senilis, mucoid degeneration of muscularis, etc., which were in vogue until investigated and found wanting.

The ovarian functional explanation is one which presents far more difficulties of proof or disproof than the others. Anspach from careful histological studies concluded that certain of these hemorrhages might be explained by a failure of the usual sclerotic change following childbirth. Reasoning by analogy the elastica present in the uterine wall may be expected by the very nature of the normal changes through which this organ passes during menstruation and the child-bearing act to play a very considerable part in the physiology of the vessels. Failure of this tissue to functionate may easily lead to otherwise unexplainable bleeding.

Of the action of radium on tissues two striking changes have come to notice and on which all authors agree. They are an increase of connective tissue and a decrease of parenchyma. The most complete studies have, of course, been made of its effects on carcinoma. The connective-tissue overgrowth presents the most striking picture, but recent investigations by Alter, for example, show that the destruction of the parenchymatous cells is the most important. The chromatin substance of the nuclei displays a great sensitivity toward the rays of radium and undergoes a deep-seated chemical change. The final result is a destruction of the nucleus and a scattering of the chromatin. The connective-tissue increase seems secondary; its purpose is to replace the destroyed parenchyma. There is, apparently, no stimulation of this tissue to active growth by radium.

Two specimens have been especially studied in this laboratory at periods varying from one week to five weeks after radiation. The organs were removed surgically. The first specimen was that of a squamous-cell carcinoma of the cervix. Great destruction of carcinoma cells was evident, with intense congestion and polymorphonuclear and other cell infiltration. The destructive effect was manifested through the length of the cervical canal and extending into the wall approximately one-half inch. Beyond this living carcinoma cells were plentiful. The other patient presented a continuous small amount of hemorrhage

and was suspected of having carcinoma of the fundus. The uterus was very soft and boggy and the entire uterine cavity showed an intense inflammatory reaction, with mucosa and considerable muscle immediately about the site of the radium necrotic and deeply ulcerated. The remainder of the uterine mucosa also showed ulceration extending from a part to a whole of this structure. Beyond the necrotic part, and extending throughout the entire wall of the uterus, was an extraordinarily violent inflammatory reaction. Sections from other parts of the uterus showed the same edema, pus-cell infiltration, hemorrhage and congestion, but to a less degree. Tubes and ovaries also gave evidence of acute inflammatory reaction, but to a still less degree. A small amount of fibrin was present on the peritoneal surfaces. Reparative processes were practically entirely absent. No carcinoma was found.

There can be no doubt, therefore, of the intense destructive activity of radium. If the dose can be so graduated to destroy endometrium when this is desirable its field of usefulness is, of course, established. When, however, its destructive properties are not controlled or controllable its potentialities for harm are limitless.

Since the endometrium in the cycle of its normal functions undergoes marked anatomical changes it follows that for intelligent interpretation of anatomical pictures it is essential to consider the data of menstruation with the specimen for pathological report. The age of the patient and the number of pregnancies and childbirths is also important, for these factors influence the musculature, bloodvessels and interstitial tissues. Especially is this important in the final judgment in cases of so-called myopathic hemorrhage, when all constitutional factors have been ruled out and there remains a uterus with no lesions discoverable by ordinary means.

Much of the confusion attending these diagnoses and many of the coincident questions, for example, can a hypertrophic endometrium bleed, will then be cleared up. Then the effects of therapeusis, whether by radium or surgery, can be better estimated.

DISCUSSION

Dr. Charles H. Mayo, Rochester:

I think that the use of radium is in its infancy. It took a number of years to learn about the *x*-ray, and it will take another five years to learn as much about radium.

It is interesting that whereas the action of the *x*-ray is on the protoplasm of the cell, radium controls the cell nucleus. When the nucleus stops dividing there is a check on cell growth. I do not believe that there is on record a case of cancer following radium treatment, but many cases of cancer have been recorded following *x*-ray burns. Radium is five times as potent in destroying the malignant cell as in destroying the surrounding normal cells. We use radium a great deal; its use has eliminated from surgery a large group of cases of advanced cancer of the cervix in which the growth has become fixed or in which there is extension onto the vaginal mucous membrane. Formerly we used the cautery in these cases.

Last year subtotal hysterectomy was performed at the Clinic in 320 cases of fibroid and benign disease of the uterus with a mortality of 0.9 per cent. and total hysterectomy in 96, and exploration in 6 cases of cancer of the uterus without a death. We no longer treat surgically the extensive fungous growths of the cervix in cases in which the uterus is fixed; radium stops the hemorrhage more surely and quickly than the cautery, removes the fungous mass, and contracts the cervix. I believe that radium is the best means of prolonging life but not of curing disease, and therefore in inoperable cases is far better than surgery.

Dr. Joseph Ransohoff, Cincinnati:

I am not going to speak of the influence of radium on fibroids. Is not radium the agent to use in all cases of cancer of the uterus? We have cases treated with radium well after five or six years with beginning carcinoma of the uterus. Our distinguished friend from Philadelphia speaks of the uterus being burned to death; that is not what we intend with radium but only sufficient exposure to affect the diseased tissue. If such was the result he obtained, then the radium was not properly used.

Dr. John B. Deaver, Philadelphia (in closing):

I am glad to hear that Dr. Mayo expresses a doubt. I agree with him that in advanced disease radium is a palliative but not a cure.

A lot of radium has been used in Philadelphia by the best radiologists in the country, Dr. Pancoast, Dr. Pfahler and others and in all sorts of conditions. For certain types of hemorrhage it is the *sine qua non:* it will stop them all, and in the bad cases of hemorrhages with fungating carcinomatous masses it is surprising what it will do, but I am not speaking of those cases. I am speaking of cures by radium. I congratulate Dr. Ransohoff if such a result has been his experience. This is a subject I wanted brought up before the association for discussion for the reason that every gynecologist, every radiologist, every *x*-ray man in this country is overloading his patients with radium, and not always under the best conditions, not being willing many times to accept the opinions of the surgeons who should be better qualified to express a final opinion.

SPECIAL CONSIDERATION OF TOXIC ADENOMA IN RELATION TO EXOPHTHALMIC GOITER

By GEORGE W. CRILE, M.D.
CLEVELAND, OHIO

For a long time it has been noted that, following the removal of simple goiters, especially those of large size, some patients have reported an improvement in general health beyond what one would anticipate from the mere removal of the enlarged gland. In some cases the improvement has seemed to pertain principally to the nervous system; in some cases to the heart. At first it appeared that this improvement must be in part psychic, *i. e.*, relief from the disfiguring growths; and in part mechanical—relief from pressure; relief from interference with the circulation through the large venous trunks; relief from interference with the respiratory exchange.

But with increasing experience it was realized there was like improvement in cases in which there was no psychic stress; no interference with the circulation in the venous trunks; no interference with the respiratory exchange. It appeared, therefore, that the improvement must be due to the loss of thyroid activity. A comparative study showed also that the changes referred to above more frequently followed the removal of adenomata than the removal of colloid goiters.

The only proved function of the thyroid gland is the fabrication of iodin into an iodin-containing compound which is adapted to the needs of the organism. In hyperplastic goiters this function is most active; but that adenomata also perform the charac-

teristic thyroid function has been shown by the researches of Marine and Allen Graham.

Marine has found that adenomata contain iodin, not as much as is found in colloid goiters but enough to suggest that they are functionally active; and Graham found that adenomatous tissue effects differentiation in tadpoles as it is effected by normal thyroid tissue. Clinical evidence of the functional activity of adenomata is found in the frequent development of symptoms identical with those which are characteristic of exophthalmic goiter, and in the disappearance of these symptoms after the removal of the adenoma.

In hyperthyroidism due to hyperactive adenomata either iodin or thyroid extract may cause an aggravation of the symptoms.

In view of these facts the following questions arise: Are these clinical symptoms of so-called toxic adenomata due to a degeneration of the adenoma—such as may occur as a result of the degeneration of fibroid tumors? Are they due to such changes as are produced by a chronic toxemia from infection of the gall-bladder, of the teeth, tonsils, bones, intestinal toxemia, etc.? Or are they due to the thyreo-iodin which is fabricated by the adenoma?

That the last of these queries suggests the true interpretation appears to be indicated not only by the identity of symptoms referred to above, but also by the fact that the well-developed "toxicity" from the toxic goiter produces a sensitization of the organism to adrenalin identical with that present in cases of hyperplastic goiter which are associated with exophthalmos and the other characteristic symptoms. In fact, with the exception of exophthalmos all the characteristic symptoms of true exophthalmic goiter may be present in cases of so-called "toxic adenoma"—increased basal metabolism, tachycardia, increased respiration, nervousness, tendency to fever, low thresholds, emaciation, increased appetite.

On the other hand in the toxemias from the toxins of degeneration and in chronic infections the appetite is not increased, and, as a rule, the basal metabolism is not increased. In certain cases of high blood-pressure, cases of myocarditis or of neuras-

thenia, in which the only evidence of the thyroid involvement was the presence of a small goiter, I have excised the gland with good results.

Moreover, if in a case of Graves's disease, the gland is not hyperplastic, but there is an adenoma, the removal of the adenoma relieves the patient in exactly the same way and to the same degree as the removal of the hyperplastic gland.

The removal of the adenoma gives relief also in certain cases of adenomata in which the basal metabolism is not increased, the appetite is not increased and there is no increased sensitization to adrenalin, but there is present myocarditis or a high blood-pressure or neurasthenia. It would seem as if adenomata may cause every grade of toxemia progressively from myocarditis, through increased blood-pressure, nervousness and increased metabolism to true exophthalmic goiter. These progressive stages of the disease due to adenomata are analogous to the varying grades of infection from mild oral sepsis to empyema of the gall-bladder, to acute peritonitis or to acute osteomyelitis. It would seem, therefore, that the various types of goiter should logically be regarded as varying degrees of the same or similar processes.

In view of these facts it would appear that, certainly as far as treatment is concerned, no differentiation should be made between exophthalmic goiter with hyperplasia from the so-called thyrotoxicosis from adenomata; that the same regimen of management which has proved effective in the treatment of exophthalmic goiter will produce like results in the treatment of the so-called "toxic" adenoma. It would seem that the thing that has been called toxic goiter should be regarded as varying degrees of iodism or hyperthyroidism—not toxemia.

The general management of exophthalmic goiter and the principles upon which it is based have been presented in other papers, but the line of treatment is summarized here to emphasize the importance of its inclusive application.

Special Points in Treatment. In advanced cases of hyperactive goiter, whether of the so-called adenomatous or exoph-

thalmic type, the internal respiration is abnormally sensitive, as is indicated by the adrenalin test (Goetsch), and by the adverse effects of suboxidation; of worry and anxiety; of injury.

Therefore, the operative procedure should be graded according to the severity of the disease. Since suboxidation cannot be well endured, and since every inhalation anesthesia interferes with oxidation, since therefore in grave cases the patient cannot be taken to the operating room under general anesthesia, and if taken to the operating room without anesthesia the adverse psychic influence is met, we therefore make all ligations and certain lobectomies in bed. It is rather surprising to find how easily this may be done. The patients are as a rule under only analgesia—but always under local anesthesia.

In extremely grave cases it may be necessary to diminish the thyroid activity by multiple steps; ligation of one vessel; ligation of the second vessel; partial lobectomy; complete lobectomy; allowing intervals of a month or more between two or more of these stages. If during operation the pulse runs up beyond the safety-point the operation is stopped and the wound dressed with flavin, the operation being completed after one or more days when conditions are safe. In some cases, though the thyroid is resected, it is advisable to dress the unsutured wound with flavin and make a delayed closure in bed the following day under analgesia.

If after operation there is inaugurated an excessively high temperature, with greatly increased pulse and respiration, then on the principle that heat increases chemical activity and electric conductivity, and that these in turn increase heat, such patients are literally packed in ice—packed early. This procedure has been found to exercise a remarkable control over the destroying metabolism.

This postoperative phase of exophthalmic goiter is closely analogous to heat-stroke in symptoms and in control, and both heat-stroke and the so-called postoperative hyperthyroidism are the antithesis of surgical shock in which by contrast the heat center is functionally impaired.

The principles outlined above and the development of the treatment are based on the study of my personal series of 2477 thyroidectomies, including 1306 for exophthalmic goiter. The last series since the foregoing completed plan has been routinely used, beginning February 21, 1919, and continuing to April 23, 1920, consists of 562 thyroidectomies, with 5 deaths, including 300 for exophthalmic goiter, with 3 deaths. Throughout this final series no case has been refused operation—the operability has been 100 per cent.; the mortality rate of the total series has been 0.88 per cent.; of the exophthalmic goiters, 1 per cent.

A "TOURNIQUET OPERATION" IN TOXIC AND OTHER GOITERS

By LEONARD FREEMAN, M.D.
DENVER, COLO.

When operating upon a toxic goiter it usually is better to remove a part of each lobe than the whole of one lobe, not only for cosmetic reasons, but because diseased glandular tissue is less liable to be left behind. Also, secretion is diminished in the remnants of the gland from the division of bloodvessels and from cicatricial contraction.

Hence partial, bilateral thyroidectomy is the operation of choice, and it becomes a matter of importance to develop a rapid and safe technic adapted to the limitations of the average surgeon. With this object in view, I desire to call attention to a method which I have employed for a number of years, accumulating experience having convinced me of its value. I have used it one hundred and eighty-two times and have found it applicable to all kinds of goiters—large, small, soft, vascular, and hard—with the exception of those which are calcified. In this series of cases I have never injured the recurrent laryngeal nerve or, to my knowledge, the parathyroids, and I believe such danger to be practically negligible, even with comparatively inexperienced operators.

Operative Technic.—The preliminary steps are those employed in most goiter work—collar incision, exposure of the gland and dislocation of its lobes. It seldom is necessary to divide any muscles, as is done often in other procedures.

From this point on, the technic differs. It has for its object the placing of a tourniquet around the base of each lobe, before

partial excision, so as to control hemorrhage by compression of *all* the vessels without injury to the nerves or parathyroids. This is done by means of two wires, one on either side of the base of

FIG. 1.—Showing wires, rubber band and alligator forceps.

the lobe, held in place by elastic bands passing through the glandular substance.

The necessary equipment (Fig. 1) consists of a number of ordinary rubber bands, two or three inches long and somewhat

thicker than the lead in a pencil; two pieces of wire of a similar diameter and three or four inches in length, with the ends turned over into small loops to prevent injury to gloves or tissues (large hairpins will suffice); and a pair of small alligator forceps.

The consecutive steps are as follows: (1) Elevate one of the thoroughly dislocated lobes with the fingers or with appropriate forceps. (2) Plunge the alligator forceps directly through the

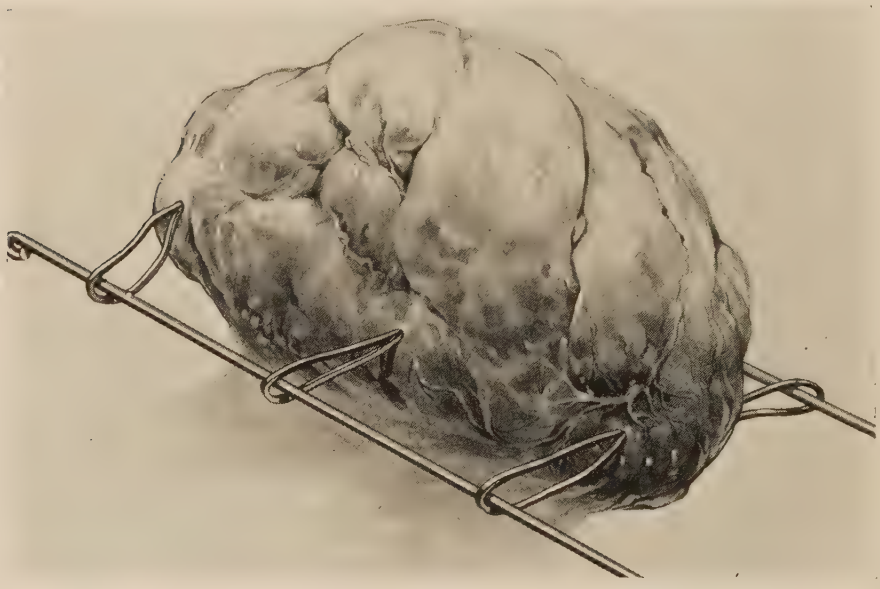

FIG. 2.—Rubber bands drawn through base of lobe and wires inserted through the projecting loops on either side.

base of the lobe near its center and close to the trachea, grasp a rubber band and pull it through, so that an end projects from either side. Repeat the maneuver near each extremity of the lobe, so that its base remains transfixed by three loops (Fig. 2). (3) The wires, which must be long enough to project well beyond the lobe at either end, are now passed through the three loops on each side (Fig. 2). (4) With the lobe well elevated, and an assistant holding the ends of the wires together, the central band

is pulled taut and clamped close to the wire with hemostatic forceps, thus binding the wires firmly together (Fig. 3). The two remaining bands are manipulated differently. After pulling on them until they are tense, each strand is wrapped in an opposite direction about the projecting ends of the wires before clamping, so as to insure the constriction of the vessels at either pole (Fig. 3). (5) The portion of the gland beyond the tourniquet is then excised with scalpel and scissors, leaving only a suffi-

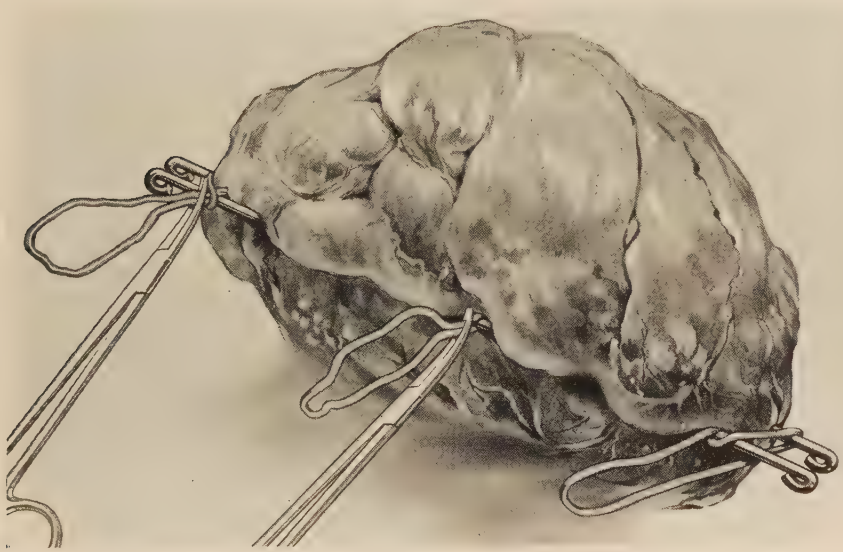

FIG. 3.—Rubber bands drawn taut and held by forceps, the end bands having been wrapped around the extremities of the wires.

cient cuff on either side for the insertion of a hemostatic suture (Fig. 4). One can take one's time in doing this, the bleeding being perfectly under control. An important point is that the elastic contraction of the rubber bands maintains the hemostatic pressure of the wires even though much tissue is removed from between them. (6) With a long catgut suture the raw area is whipped over, utilizing the lateral "cuffs" in the procedure (Fig. 4). It may be desirable to go back over the first suture-

line, so as thoroughly to control the bleeding, but it seldom is necessary to tie any vessels separately, not even the thyroidal trunks. (7) After unclasping the forceps which hold the rubber bands, the wires and bands are removed. There usually is no bleeding of consequence from the punctures through the gland substance, but if any should occur it can be checked by pressure or, if necessary, a suture. (8) The wound is then closed and drained. (9) An enlarged isthmus may require separate handling, or it may be removed along with a lateral lobe, by including it

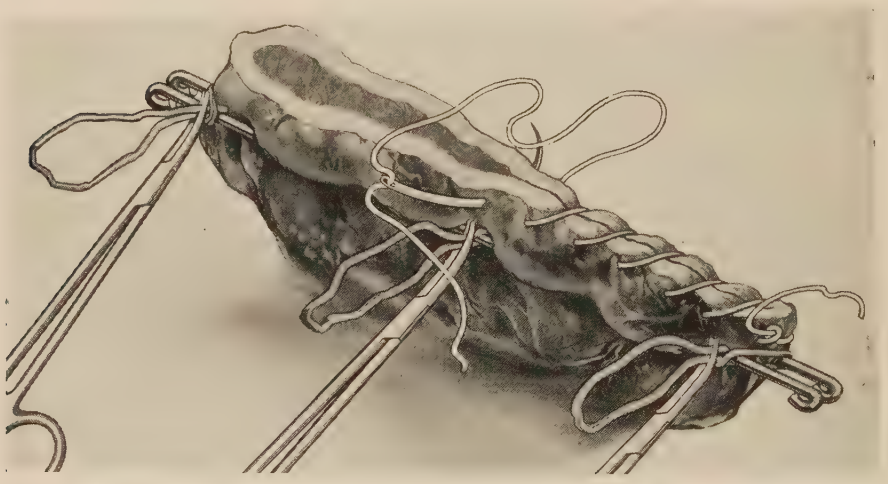

FIG. 4.—Showing wedge-shaped excision and method of inserting hemostatic suture. (For the sake of clearness the "cuff" is pictured unnecessarily wide and thick.)

within the grasp of the tourniquet, as I have often done. I do not consider it necessary to divide the isthmus in any but exceptional cases.

The advantages of this method of operating are several: (*a*) Bleeding from *all* the vessels is completely controlled. (*b*) No hemostatic forceps are required after applying the tourniquet, thus avoiding an embarrassing profusion of instruments, not to mention the danger of injuring a nerve in their application. (*c*) The wires cannot slip when the gland is cut away, because they

are held in position by the elastic bands passing through the stump. (*d*) The safety of the recurrent laryngeal nerve and parathyroids is assured by the wedge-shaped excision, and even if they should be caught in the grasp of the wires the pressure is not great enough to damage them permanently.

This constriction without crushing is important, and is one of the reasons why the wire tourniquet is superior to the use of large forceps which are sometimes similarly employed; for if the forceps are closed tightly enough to prevent slipping they will crush, which is undesirable in toxic goiter, and may injure the nerves and parathyroids. In addition, forceps occupy more room than wires and are often difficult to apply, because they cannot be bent to conform to varying conditions.

Anyone who sees fit to try this method of operating will find it easy, safe, comparatively bloodless, and surprisingly rapid. Its merits will be especially appreciated in the soft and vascular goiters of toxic type where the saving of time and trauma is so desirable.

ADENOMA WITH HYPERTHYROIDISM

By C. H. MAYO, M.D.
ROCHESTER, MINN.

The report from the Surgeon-General's Office of the physical condition of the first million draft recruits made us appreciate the fact that we have actual goiter regions in America. Goiter is most prevalent in the Northwest States and next in the Great Lakes region; in some of the Southern States and in the New England States the disease is rare.

I first operated for goiter in 1888, and I wish to express my appreciation here of the teaching of that great master surgeon, the late Theodor Kocher, who called special attention to the avoidable complications in surgery of the thyroid. Before Kocher's death approximately 5000 operations had been performed for goiter at his clinic.[16] Reports show that there are variations in the changes in the thyroid in different countries; thus cancer and simple goiter were proportionately much more common in Kocher's reports than in those of this country. It was only after 1900 that Kocher strongly advocated surgical treatment of exophthalmic goiter.[14] The condition shown by Plummer to be adenoma with hyperthyroidism had been described in foreign clinics as atypical exophthalmic goiter and was classified by various authorities into more or less ill-defined groups, designated as secondary morbus Basedow (Gauthier and Buschan), formes frustes, or incomplete (Marie)[20], goiter heart (Kraus, Gittermann, and Stern), sympathicotonic and vagotonic (Eppinger and Hess), goître basedowifié (Marie)[21] and Basedowized (Kocher).[13] These groups include psycho-

neurosis, early exophthalmic goiter and hyperthyroidism from adenoma. Gittermann more nearly than the others describes the symptoms, but he attributes the condition to a cardiac cause and recommends cardiac therapy in contradistinction to the preëxisting theory that the cause of exophthalmic goiter is to be found in the central nervous system. Adenomas with hyperthyroidism had not been definitely enough described to be commonly recognized since they were considered an atypical type. No pathologic findings other than those noted in adenoma without hyperthyroidism have been found to characterize adenoma with hyperthyroidism; the latter contains areas of varying degrees of degeneration and sometimes scattered areas of hypertrophy but similar areas are also found in the non-toxic adenomas.

Plummer has had an opportunity to observe in the Clinic not only the majority of cases of adenoma with hyperthyroidism and of exophthalmic goiter, but also several thousand cases of adolescent goiter and simple goiter in which operation was not advised. As a result of his clinical observation the present standardization of goiter has largely come about.

In 1906 Plummer noted that from 17 to 20 per cent. of the patients whose condition was clinically diagnosed at that time exophthalmic goiter had atypical symptoms; goiter, loss of weight, tachycardia, nervousness, and tremor were present without exophthalmos. These cases of adenoma with hyperthyroidism were discussed by Plummer at the meetings of the American Medical Association in 1911 and in 1912.[24]

About a century and a half ago exophthalmic goiter was described as a clinical entity by Parry, long afterward by Graves, and later by Basedow. Möbius, in 1887, suggested that in exophthalmic goiter the gland is probably overactive in secretion, and Greenfield, in 1893, observed that diffuse parenchymatous hypertrophy and hyperplasia are present and that the gland contains little colloid. Wilson, in 1908, confirmed and elaborated Möbius' theory by the publication of a report on the first large series (294 cases) studied; he also showed that in a certain percentage of cases clinically called exophthalmic goiter the

glands did not show diffuse parenchymatous hypertrophy and hyperplasia on microscopic examination.

MacCallum, in 1905, was content to place such cases in the hyperplastic class if a small amount of hyperplasia was found. Kocher did the same in 1912.[15] It should be stated that there is a small percentage of cases, an intermediate group, between exophthalmic goiter and thyrotoxic adenoma, which leans to one or the other condition, hyperplasia with adenoma or small adenomas with areas of hyperplasia.

Up to January, 1920, the surgeons of our Clinic performed 9613 operations for simple goiter, including adenoma with hyperthyroidism; 10,135 operations have been performed for exophthalmic goiter during the same period. Previous to 1912 adenomas with hyperthyroidism were included with exophthalmic goiter. Many of the patients with exophthalmic goiter had more than one operation, such as ligation, before resection.

The services of Kendall, a trained biochemist, were secured and a laboratory was opened in the Clinic for the study of the chemical nature of the gland. In December, 1914, the active principle of the thyroid gland, thyroxin, was first isolated by the use of barium salts, and three years later a small amount of thyroxin was synthesized. The synthesis was repeated and the structural formula confirmed in April, 1919.

Plummer, in 1916, presented his theory that the thyroid secretion is active in metabolism and that it vitally concerns the available energy of the cell, and during this year he started a metabolism laboratory with Dr. Boothby and Dr. Sandiford, of Boston, in charge. All varieties of goiters, including those with related complicating diseases, were studied. The basal metabolic rates in the patients with myxedema were especially helpful; by giving definite amounts of thyroxin intravenously or by mouth it was possible to bring their basal metabolic rates to normal within given periods, and by continuing the tests the rapidity with which the thyroxin is exhausted was shown. The amount burned daily, the amount in the gland, and the amount in the body of the normal person were soon determined. Pre-

vious observers, Magnus-Levy and others, have pointed out the excessive oxidation shown by metabolism in cases of hyperthyroidism, but no one had been able to state the degree from a known output and knowledge of the action of the thyroid. Plummer was enabled to determine the degree in exophthalmic goiter above the basal metabolism and to standardize the disease in appearance, severity and activity, thus standardizing also the degree of thyroid deficiency in myxedema.

Plummer in his various communications since 1909 has shown that the condition of hyperthyroidism may occur in adenoma without diffuse parenchymatous hypertrophy and hyperplasia[25]; this was supported by Goetsch in 1916, who called attention to the marked increase over normal in mitochondria in the thyroid gland in cases of exophthalmic goiter and of toxic adenoma. Bensley had shown the granules to be numerous in the thyroid cells in 1914, and others have shown that they are increased in number in the active or growing cells in general, whether representing work activity or proliferative activity is not determined.

The essential points in the clinical differentiation of exophthalmic goiter and adenoma with hyperthyroidism presented by Plummer[26] in 1913 are: (1) The difference in the average ages of the patients when the goiters were first noticed. Enlargement of the thyroid was noted from five to ten years earlier in life by the patients with non-hyperplastic goiter than by the patients with hyperplastic (exophthalmic) goiter; (2) the time elapsing between the appearance of the goiter and the onset of hyperthyroid symptoms; in cases of exophthalmic goiter the symptoms of hyperthyroidism followed the appearance of the goiter within an average of nine-tenths of a year, while in cases of non-hyperplastic adenoma with hyperthyroidism an average of fourteen and one-half years elapsed before the symptoms of hyperthyroidism appeared; and (3) the relative frequency of exophthalmos in exophthalmic goiter contrasted with its infrequency in non-hyperplastic adenomas with hyperthyroidism.

Exophthalmos occurs within three months of the appearance of hyperthyroidism in an average of 50 per cent. of the cases of

exophthalmic goiter and within two years in 87 per cent. Exophthalmos, even of questionable degree, was rarely noted in cases of non-hyperplastic adenoma with hyperthyroidism. In 1915 Plummer published a brief resumé of an immense mass of evidence to show the differences in the average blood-pressures in these two syndromes and the definite tendency to hypertension in adenoma with hyperthyroidism, which is not found in exophthalmic goiter.[27] The marked differences in the clinical pictures of exophthalmic goiter and of non-hyperplastic adenoma with hyperthyroidism led Plummer, in 1916, to point out in an extremely valuable article the probability of the different etiology in the two diseases; he had previously given the working hypothesis: "The active agent of the thyroid gland is a catalyst which accelerates the rate of formation of a quantum of potential energy in the cells of the organism." In May, 1916, Plummer presented a paper before the Association of American Physicians, in which he stated that the thyroid plays an important part in metabolism, that the evidence of high metabolism dominates the clinical syndrome of hyperthyroidism, that the rate of metabolism is dependent on the thyroid hormone and that this function is not specific for certain tissues but is common to all the cells of the organism. DuBois, in June, 1916, published the report of the results of his studies of the basal metabolism. The condition of adenoma with hyperthyroidism as described by Plummer is as follows: "Thyroid adenoma with hyperthyroidism is a disease associated with adenoma, characterized by an increased metabolic rate and excited by an excess of the normal thyroid hormone in the tissues. It is clinically evidenced by nervousness, tremor, tachycardia, loss in strength and weight and a tendency to hypertension; in the latter stages myocardial disintegration appears."[3] It is a disease of middle life. The underlying cause or stimulus activating adenomatous growth and oversecretion is not known. Pathologically the thyroid contains single or multiple adenomas in various stages of development or degeneration. The tissue outside the adenomas may be normal or colloid thyroid or contain areas of scattered hyperplasia.

The histologic classification and the cellular content are still under investigation.

In the patients with adenoma with hyperthyroidism there was a gradual and appreciable change in symptoms two or three years previous to examination, the patients became nervous and excitable, and in the early stages they were ambitious to work although unable to maintain physical or mental effort for a long period. These patients have good appetites and think they should be gaining in weight, but find that they are actually losing weight. The skin is warm, with a tendency to perspiration. The heart beats faster and harder than normally, especially on slight exertion; it later palpitates even when the patient is at rest. The blood-pressure often shows hypertension. The symptoms appear gradually and insidiously, usually becoming definitely worse about one year before the patients appear at the Clinic; later there are an increase in nervousness and mental instability, moderate tremor, loss of strength and dyspnea on exertion; the heart beats rapidly and hard, but the beat is not so accentuated as in exophthalmic goiter. In the long-standing and more severe cases there is evidence of cardiac insufficiency with more or less edema of the legs and ankles, often accompanied by myocardial disintegration, shown by irregular rhythm due to the premature contractions or auricular fibrillations. Exophthalmos and gastro-intestinal crises noted in exophthalmic goiter are absent. As the duration of hyperthyroidism is prolonged and the metabolic rate gradually increases the increased functional demand is supplemented by actual myocardial changes (Willius), resulting from the presence of an excess of the thyroid hormone.

The average age of the patients with adenoma with hyperthyroidism at the time of the examination in two groups of 201 cases and 75 cases was 47.7 and 47.4 years respectively; 77 per cent. were more than 40.

The average age of patients with adenomas without hyperthyroidism in whom the adenomas were of sufficient size to justify operation, or for whom the operation was advised as a

protection against future hyperthyroidism was slightly less, 43.8 years in a group of 167 cases; this is higher, however, than the average age of all patients with adenomas without hyperthyroidism who come to the Clinic.

Exophthalmic goiter brings the patient for examination ten years earlier in life than does thyrotoxic adenoma. Four groups of exophthalmic goiter patients averaged between thirty-three and thirty-six years of age. In thyrotoxic adenomas a goiter is present eighteen to nineteen years before the patient appears for operation; the symptoms of hyperthyroidism have been present about three and a half years, or twice as long, as even the enlarged gland has been noticed in the patients with exophthalmic goiter.

The average metabolic rate following operation and partial thyroidectomy, or removal of the adenomatous mass, falls from +35 per cent. to +7 per cent., usually within two weeks. This rapid drop in metabolism is in contrast with the result obtained from thyroidectomy in cases of exophthalmic goiter with an average basal rate of +36 before operation; the rate is within normal limits within two weeks in only 45 per cent., although it is below +14 per cent. in 76 per cent. The basal metabolic rate in a series of cases is shown in Table I.

TABLE I.—AVERAGE METABOLIC RATE AND BLOOD-PRESSURE IN ADENOMA AND EXOPHTHALMIC GOITER BEFORE AND AFTER TREATMENT.*

	Adenoma.						Exophthalmic goiter.														
	Without hyperthyroidism.			With hyperthyroidism.			Two ligations, two months' rest and thyroidectomy.							One ligation and thyroidectomy.					Thyroidectomy.	
Number of cases averaged in each group	167.0	18		201.0	75		36				55			52	22				52	
Age, years	43.8	..		47.7	47.4		35.0				36.7			38.0					33.0	
Duration of goiter, years	16.9	..		17.9	19.7		2.8 (1.6)†				3.0 (1.0)			3.5 (1.1)					3.2 (1.4)	
Age at onset of goiter, years	26.9	..		29.8	27.7		32.2 (33.4)				33.7 (35.7)			34.5 (36.9)					29.8 (31.6)	
Duration of symptoms, years	..	..		2.0	2.2		1.6 (1.3)				1.4 (1.0)			1.7 (1.3)					1.3 (1.0)	
Age at onset of symptoms, years	..	..		45.7	45.2		33.4 (33.7)				35.3 (35.7)			36.3 (36.7)					31.7 (32.0)	
Systolic blood-pressure	143	..		156	160		147				148			148					142	
Diastolic blood-pressure	85	..		86	86		73				75			76					78	
Pulse-pressure	58	..		70	74		74				73			72					64	
Pulse-rate	91	..		102	113		126				124			121					121	
Hemoglobin	75	..		73	74		70				71			74					74	
B. M. R.	+2	−4	−8	+28	+35	+7	+66	+50	+42	+19	+66	+42	+16	+52	+15	+57	+41	+16	+36	+8
Systolic blood-pressure	127	118	118	143	146	134	140	133	132	126	140	134	129	140	124	138	124	120	133	122
Diastolic blood-pressure	77	76	72	80	81	79	77	72	73	75	74	71	76	73	75	72	64	73	72	73
Pulse-pressure	50	42	46	63	65	55	63	61	59	51	66	63	53	67	49	66	60	47	61	49
Pulse-rate	78	74	72	97	102	80	122	115	108	93	122	109	90	113	90	116	109	92	109	88
Weight	..	..	..	..	..	..	51.7	48.1	55.8	..	49.2	53.9								
	Before treatment.	Before treatment.	Two weeks after thyroidectomy.	Before treatment.	Before treatment.	Two weeks after thyroidectomy.	Before treatment.	Ten days after second ligation.	After two months' rest.	Two weeks after thyroidectomy.	Before treatment.	After second ligation and two months' rest.	Two weeks after thyroidectomy.	Before treatment.	After one ligation and two weeks after thyroidectomy.	Before treatment.	Ten days after one ligation.	Two weeks after thyroidectomy.	Before treatment.	Two weeks after thyroidectomy.

* This table is extracted from a paper presented by Dr. W. M. Boothby, at the Harvard Medical Society, February 17, 1920, Boston.

† The cases in this group of more than five years' duration are omitted from the averages given in the brackets because the duration of the goiter is confused by a preëxisting adenoma.

Bibliography

1. Basedow: Exophthalmie durch Hypertrophie des Zellgewebes in der Augenhöhle. Wchnschr. f. d. ges. Heilk., 1840, vi, 197-220.

2. Bensley, R. R.: The thyroid gland of the opossum. Anat. Rec., 1914, viii, 431–440.

3. Boothby, W. M.: A study of the metabolic rates in adenoma of the thyroid with hyperthyroidism. Presented before the Harvard Medical Society, Boston, February, 1920.

4. Buschan, G.: Ueber Diagnose und Theorie der Morbus Basedowii. Deutsch. med. Wchnschr., 1895, xxi, 336–338.

5. DuBois, E. F.: Metabolism in exophthalmic goiter. Arch. Int. Med., 1916, xxvii, 915–964.

6. Eppinger, H. and Hess, L.: Vagotonia, a clinical study in vegetative neurology. Translation by W. M. Kraus and S. E. Jelliffe: Jour. Nerv. and Ment. Dis., 1915, xlii, 47–50.

7. Gauthier, G.: Des goitres exophtalmiques secondaires ou symptomatiques. Lyon méd., 1893, lxxii, 41–48; 87–89; 120–127.

8. Gittermann, W.: Struma und Herzkrankheiten. Berl. klin. Wchnschr., 1907, xliv, 1487–1490.

9. Goetsch, E.: Functional significance of mitochondria in toxic thyroid adenomata. Johns Hopkins Hosp. Bull., 1916, xxvii, 129–133.

10. Graves, R. J.: Lectures. Med. and Surg. Jour., 1835, vii, Lecture.

11. Greenfield, W. S.: Some diseases of the thyroid gland. Lancet, 1893, ii, 1493–1497; 1553–1555.

12. Kendall, E. C.: Isolation of the iodine compound which occurs in the thyroid. Jour. Biol. Chem., 1919, xxxix, 125–146.

13. Kocher: The pathology of the thyroid gland. Brit. Med. Jour., 1906, i, 1261–1266.

14. Kocher, A.: Ueber Morbus Basedowii. Mitt. a. d. Grenzgeb. d. Med. u. Chir., 1902, ix, 1–304.

15. Kocher, A.: Die histologische und chemische eränderung der Schilddrüse bei Morbus Basedowii und ihre Beziehung zur Funktion der Drüse. Virchow's Arch. f. path. Anat., 1912, ccviii, 86–296.

16. Kocher, T.: Ueber Kropf und Kropf behandlung. Deut. med. Wchnschr., 1912, xxxviii, 1312–1316.

17. Kraus: Ueber Kropfherz. Berl. klin. Wchnschr., 1906, xliii, 1413.

18. MacCallum, W. G.: The pathological anatomy of exophthalmic goiter. Johns Hopkins Hosp. Bull., 1905, xvi, 287–288.

19. Magnus-Levy: Ueber den respiratorischen Gaswechsel unter dem Einfluss der Thyroidea sowie verschiedenen pathologischen Zuständen. Berl. klin. Wchnschr., 1895, xxxii, 650.

20. Marie, P.: Contribution à l'étude et au diagnostic des formes frustes de la maladie de Basedow. Thèse de Paris, 1883.

21. Marie, P.: Maladie de Basedow et goitre basedowifie. Rev. Neurol., 1897, vi, 91.

22. Möbius: Ueber das Wesen der Basedow-Krankheit. Centralbl. f. Nervenheilk., 1887, x, 228.

23. Parry, C. H.: Enlargement of the thyroid gland in connection with enlargement or palpitation of the heart. Collections from the unpublished medical writings, London, 1825, ii, 11.

24. Plummer, H. S.: Discussion following paper by Marine, D.: The anatomic and physiologic effects of iodin on the thyroid gland of exophthalmic goiter. Jour. Am. Med. Assn., 1912, lix, 325–327.

25. Plummer, H. S.: The clinical and pathologic relationship of simple and exophthalmic goiter. Am. Jour. Med. Sc., 1913, cxlvi, 790–796.

26. Plummer, H. S.: The clinical and pathologic relationship of hyperplastic and non-hyperplastic goiter. Jour. Am. Med. Assn., 1913, lxi, 650–651.

27. Plummer, H. S.: Studies in blood-pressure. I. Blood-pressure and thyrotoxicosis. Tr. Assn. of Am. Phys., 1915, xxx, 450–457.

28. Plummer, H. S.: The function of the thyroid, normal and abnormal. Tr. Assn. of Am. Phys., 1916, xxxi, 128–133.

29. Stern, R.: Differentialdiagnose und Verlauf des Morbus Basedowii und seiner unvollkommen Formen. Jahrb. f. Psychiat., 1909, xxix, 179–273.

30. U. S. War Department. Office of Surgeon-General. Bulletin 11: Physical examination of the first million draft recruits: Methods and results. Washington Government Printing office, 1919.

31. Willius, F. A.: Auricular fibrillation and life expectancy. Minn. Med., 1920 (In press).

32. Willius, F. A.: Observations on changes in form of the initial ventricular complex in isolated derivations of the electrocardiogram. Arch. Int. Med., 1920, xxv, 550–564. (In press.)

33. Wilson, L. B.: The pathological changes in the thyroid gland as related to the varying symptoms in Graves' disease; based on the pathological findings in two hundred and ninety-four cases. Am. Jour. Med. Sc., 1908, cxxxvi, 851–861.

TOXIC GOITER

By WALLACE I. TERRY, M.D.
SAN FRANCISCO, CALIF.

It is now fairly well recognized that two distinct types of goiter may give rise to toxic symptoms, namely, the hyperplastic thyroid and adenomata. It is further recognized that the symptom-complex may be almost identical with either type of goiter, except that exophthalmos is not present in cases of adenoma of the thyroid unless there is also hyperplasia of the thyroid tissue itself. It is seldom that the adenomata will produce extreme degrees of toxicity. We owe to Plummer the recognition of the role of the adenomata in the production of toxic symptoms, and we are also indebted to Goetsch for his further researches along these lines.

There are, however, many practitioners who do not appreciate the difference between the hyperplastic goiter and the adenomata from the standpoint of treatment. They consider them entirely innocent, and advise that they be let alone or may prolong the medical treatment of them until a goiter heart has developed and a cure for the patient is no longer possible. I have thus emphasized the toxic adenomata, because, to my mind, they are not curable by medical means, including the roentgen ray. Until we have some new measure of real value at our command, it seems to me that the treatment of toxic adenomata should be surgical from the outset. In those occasional combinations of adenomata with hyperplasia, thyroid activity can be lessened by rest and suitable irradiation, but the adenomata will pursue their course despite the treatment.

We all know of apparently spontaneous cures of true exophthalmic goiter, but probably many of these relapse after some years of good health; it has been my experience to operate in two cases in which the free interval was nineteen years. It has been stated that exophthalmic goiter is a self-limiting disease and that spontaneous cures result after five or six years in from 60 to 70 per cent. of the cases. Such a statement, I think, must be founded on a rather limited experience or else the term cure does not mean all it should. Too often do we see patients with unstable nervous systems, irritable and weakened hearts, slight exophthalmos and about normal-sized thyroids, who are supposedly cured, and yet under some toxic stimulus these patients will rapidly go down hill. We see the same thing after surgical treatment, due to insufficient removal of thyroid tissue in some cases, but more often to the fact that the bad nervous systems and the bad hearts were there before the operation. To employ a Hibernianism, the treatment of toxic goiter should begin before it becomes toxic.

The surgical treatment of mildly toxic goiter is usually most gratifying, but the very severe cases require time, patience and a recourse to all sorts of expedients to tide them along to a point where it is safe to operate. This safe point is often most difficult to judge, despite the pulse record, the improved weight, the lowered basal metabolic rate, the reaction to epinephrin and the apparently strong heart. We have no accurate means of determining the resistance of an enfeebled nervous system to psychic or physical trauma, and our estimate of the resisting power of the myocardium is often inaccurate.

To consider personal statistics, up to March 31, 1920, I have done 748 operations for goiter, and of these 527 were for toxic goiters on 504 patients. There were 22 deaths among the toxic cases—a mortality rate of 4.3 per cent.—whereas there was but one death among the 216 patients with simple goiter—a mortality rate of less than 0.5 per cent. The difference is, of course, striking, but what we should expect, unless one refuses to accept bad risks along with the good ones. The good risks

may come in groups, as, for instance, during the period from January 22, 1917, to April 15, 1918, I did 108 operations on 103 patients with toxic goiter without a single fatality, whereas in the next succeeding series of 103 patients there were 8 deaths.

Since 1904, when I did my first operation for goiter, I have classified the toxic cases under four degrees of severity, namely, mild, moderate, marked and extreme. The classification may be open to question, but it was based on personal judgment, using such factors as pulse-rate, blood-count, tremors, vasomotor changes, excitability, exophthalmos and more recently basal metabolism. In accordance with this classification it is found that 155 patients were designated mildly toxic, 86 moderately, 212 markedly and 51 presented a picture of extreme degree of toxicity. There were 13 deaths among these 51 extremely toxic cases, 1 of them following the ligation of both superior thyroid arteries and 3 following the injection of boiling water. Some of the remaining 9 deaths might have been prevented by doing less severe operations than resection or lobectomies—they are evidence of the fallibility of my judgment.

Of the 504 cases of toxic goiter I have accurate pathological reports in 376. The reports show typical hyperplasia in 158 cases, to which should be added 31 cases in which the thyroid was in a resting state, approaching the normal in its microscopic picture. This resting state had been brought about either by the administration of iodin, as shown by Marine a number of years ago, or other medical measures, particularly rest, by irradiation or by minor surgical procedures. There were 172 cases of toxic adenomata and 13 cases of adenomata, with varying degrees of hyperplasia, which latter may be designated "mixed" types.

As a result of the investigation of the prevalence of goiter among army recruits, we know that it is more common in certain parts of the United States than we had anticipated. It was found, for instance, by Kerr and Addis that 20.4 per cent. of over 22,000 recruits examined had goiters—these were from 11 Northwestern and Pacific States. Only a small number of

these had toxic symptoms. If such a proportion obtains in young men it is reasonable to suppose that they are still more common in young women. It will be the work of the hygienist to solve this problem, and when it is done, there will be fewer goiters which demand surgical attention.

RESULTS OF OPERATIONS FOR ADENOMA WITH HYPERTHYROIDISM AND EXOPHTHALMIC GOITER

By E. S. JUDD, M.D.
ROCHESTER, MINN.

Before drawing conclusions with regard to the results of the treatment of goiters producing symptoms of hyperthyroidism it might be well to define the conditions as they are generally understood at the Mayo Clinic. Changes in the thyroid which apparently produce two definite clinical syndromes that are usually attributed to alterations in the secretory activity of the gland are: (1) hyperthyroidism of exophthalmic goiter in which the symptoms are characteristic (the changes in the thyroid are always the same and result in a general diffuse hypertrophy and hyperplasia of the gland), and (2) adenoma of the thyroid with hyperthyroidism, first described as a clinical entity by Plummer (1911–1912). In many respects adenoma with hyperthyroidism resembles exophthalmic goiter, but on careful examination can be readily recognized as a distinct disease. The activity of the thyroid gland in this condition is confined to the new growths or adenomas in which the hypertrophy occurs, instead of in the normally functionating part of the thyroid.

There is a third syndrome which is often mistaken for hyperthyroidism due to thyroid changes. The patients in this group present nervous manifestations, although the nervousness is of the kind seen in the psychoneurotic person, with tremor and tachycardia, although of a different kind from that met with in

hyperthyroidism. The differential diagnosis is at times difficult because the thyroid gland is generally enlarged, due to an increase in colloid; the basal metabolic rate, however, is always normal. The importance of considering this third type apart from the goiters with hyperthyroidism is evident from the fact that this latter group responds to general medical treatment, and surgery is contra-indicated.

The symptoms in cases of adenoma with hyperthyroidism apparently result from an increased production of a normal or nearly normal thyroid hormone. While organs such as the other ductless glands and certain parts of the central nervous system may also show some changes, the gross changes in the thyroid are constant and permanent and establish a basis for surgical treatment.

The presence and degree of hyperthyroidism in exophthalmic goiter may be determined by several means. The clinical features offer an accurate estimate of the amount of disturbance produced by such changes in the gland. In considering the hyperthyroid cases, the natural course of the disease must be taken into consideration first. Hyperthyroidism occurs in exacerbations. The toxic symptoms develop gradually and after a certain time, usually a few months, they reach their climax. If the patient survives the attack, the toxic features gradually subside after a short period, although there is almost never a return to normal, and definite evidence of the hyperthyroidism persists until the beginning of the next attack. Occasionally a spontaneous cure with the disappearance of all evidence of the disturbance occurs.

Loss of weight and strength, and increased pulse rate often reveal the degree to which the toxemia has progressed. The loss of body weight is particularly important, and by carefully noting this symptom, an estimate can be made not only of the degree of toxicity, but also of the relative time of the particular attack. This finding also influences the line of treatment to be followed. It is a well-recognized fact that the surgical mortality is unduly high if patients with exophthalmic

goiter are operated on while the toxemia is progressive, or at the peak of a hyperthyroid wave.

Loss of strength indicated by weakness of the extensor muscles and the patient's inability to raise his body up a step, or his inability to walk a short distance, is also an important test of the degree of toxicity. The pulse-rate, nervousness and tremor are influenced by so many other factors that they do not have the value that loss of weight and loss of strength have in determining the degree of hyperthyroidism. The most valuable means of determining the degree of hyperthyroidism is the basal metabolic rate which measures the increased metabolism, just as the thermometer measures the intensity of a febrile disease.

In a consideration of the cases of adenoma with hyperthyroidism, a different problem is presented, namely, the clinical course of the disease. The thyrotoxic cases are usually those in which an innocent enlargement of the thyroid has existed for a long time. In our series, patients with this type of goiter had had an enlargement on an average of almost twenty years before it was associated with symptoms of hyperthyroidism. In the cases of exophthalmic goiter this interval was usually less than one year. Acute crises of hyperthyroidism are not so apt to occur in cases of toxic adenoma as in cases of exophthalmic goiter; the toxic features develop more slowly and are progressively noticeable. Frequently the cardiac symptoms predominate and not infrequently those cases are regarded as "heart disease." There is also a tendency for these cases to be hypertensive. The basal metabolic rate is always increased, but does not average as high as in exophthalmic goiter.

Within recent years much attention has been given to the changes in the basal metabolic rate in both groups of hyperthyroidism, and it is contended by those who have had the most experience in this work that the basal metabolic rate is an absolutely accurate method of determining the presence and the degree of thyroid disturbance. Plummer and Boothby have carried out this study extensively and they believe that in general the thyroid is the main controlling factor in basal

metabolism, although other conditions may influence the rate to a certain degree, and that any hypertrophy in the gland will be evident by an increase in the activity, and any reduced thyroid function will be evident by a lower metabolic rate than normal. The degree of hyperthyroidism estimated from the clinical features, and the degree of hyperthyroidism determined from the changes in the basal metabolic rate practically always correspond. The adrenalin test is apparently at variance with both the clinical picture and the metabolism studies. In our experience the test when used to determine the presence of toxemia resulting from thyroid changes has responded almost the same in patients with known hypothyroidism, in normal persons, and in patients with hyperthyroidism. The psychoneurotics have seemed to give the best response to the test. It does not as yet seem advisable to employ the test to determine the presence of toxemia with a view to operative procedures, for the psychoneurotics, so far as we can determine, do not have thyroid toxemia. Studies on this subject have recently been reported from our clinic by Boothby and Sandiford, and by Sandiford.

This study of the operative results in exophthalmic goiter and adenoma with hyperthyroidism is based on two selected groups of 100 cases each; 100 consecutive cases were selected from the list of exophthalmic goiters in which operation was done in 1914, and 100 consecutive cases of adenoma with hyperthyroidism in which operation was done in 1917 and 1918. The list was chosen from 1914 for the exophthalmic group because it seemed that six years is sufficient time to demonstrate the success or failure of operative procedures. The cases in the group of adenoma with hyperthyroidism were chosen from the years 1917 and 1918 because a study of the metabolic rate had been made in all cases; the average time elapsed since operation is two years.

The cases were studied first on the basis of the clinical history and the pathologic findings, and only the cases in which these two findings agreed were selected. Diffuse parenchymatous

hypertrophy was definite in all of the thyroids removed in cases diagnosed exophthalmic goiter by the clinician. All the cases of adenoma with hyperthyroidism showed on pathologic examination adenomatous tissue of various types and sometimes scattered areas of parenchymatous hypertrophy; diffuse parenchymatous hypertrophy such as is typical of exophthalmic goiter, however, was not present.

Letters of inquiry were sent to the patients in each group. Replies were received from all the patients with adenoma with hyperthyroidism and from 88 of the patients with exophthalmic goiter. In the latter group twelve letters were returned unclaimed

Eighty-eight of the patients with adenoma with hyperthyroidism were females whose average age was forty-eight and eight-tenths years. The 12 males averaged forty-eight and four-tenths years. Eighty-three of the patients with exophthalmic goiter were females averaging thirty-four and three-tenths years, and 17 were males, averaging thirty-six and six-tenths years.

In adenoma with hyperthyroidism, as Plummer has pointed out, the adenoma usually becomes evident early in life, but the symptoms of hyperthyroidism do not develop until middle age. In this series of cases of adenoma with hyperthyroidism the goiter was first noticed at an average age of twenty-nine and eight-tenths years and the patients came for treatment nineteen years and four months later, after noticing symptoms for two years and five months. In the cases of exophthalmic goiter the enlargement was noted at an average age of thirty-one and two-tenths years; and the patients came for treatment three years and eight months later, after noticing symptoms for one year and nine months.

In the majority of cases clinical examination revealed an enlargement of both the right and left lobe of the thyroid. (Table I.)

Consistent metabolic readings were not taken in exophthalmic cases in 1914 but records of 98 preoperative and 44 postoperative cases of adenoma with hyperthyroidism were obtained. In some

cases several readings were taken and in others only one, so that the figures given represent an average of those taken in each class. The average preoperative rate was 32.7, and the average postoperative rate was 9.2. Some of the postoperative rates were obtained within three weeks after operation and others within a year or two, but the average number of days postoperatively was twenty-two. These figures agree very well with those obtained by Dr. Boothby in a careful analysis of the basal metabolic rates in adenoma and in exophthalmic goiter.

TABLE I

	Cases of exophthalmic goiter.	Cases of adenoma with hyperthyroidism.
Right and left lobes	79	49
Right lobe, isthmus, and left lobe	11	14
Right lobe	4	17
Left lobe	3	10
Isthmus	1	5
Right lobe and isthmus	..	4
Left lobe and isthmus	..	1
Not stated	2	

The choice of operation depends on several important factors and no fixed rule can be made for any group of cases. The type of operation not only varies for each group but also for each patient and the stage of the disease. Whereas in the group of cases of adenoma with hyperthyroidism thyroidectomy was done with small risk, in the group of 100 cases of exophthalmic goiter primary or secondary ligation was deemed advisable in 64. Primary thyroidectomy was performed in only 36 of this group. This is a higher percentage of ligations than we ordinarily consider necessary and indicates that this particular group of cases largely represents the severe type. While primary thyroidectomy is the operation of choice and may be done with a comparatively low mortality in the early cases of exophthalmic goiter, in our series only about one in three patients presented himself at a time in the course of the disease to warrant dispensing with the preliminary ligation.

In most cases the best operative results are obtained by subtotal thyroidectomy, which is accomplished by removing all except the posterior part of each lobe. The immediate benefit derived from the operation is greater and the recurrences fewer than if lobectomy is done.

Questions in the letters of inquiry were:

1. Do you consider yourself cured as a result of operation?
2. Do you consider yourself improved?
3. Do you consider your condition unchanged?
4. Do you consider yourself worse?

Beside these questions the patients were given a list of symptoms to report on, such as palpitation, rapid heart, and prominence of the eyes. Various factors which might have influenced their replies were considered; for instance, if the patient reported himself cured and his pulse record and symptomatic condition indicated otherwise, he was not placed among the patients cured.

In Table II are tabulated the interesting facts revealed from a study of the clinical histories with a view to ascertaining which of the most noticeable preoperative symptoms persisted after operation and which disappeared.

TABLE II.

	Symptoms in Exophthalmic Goiter.		Symptoms in Adenoma with Hyperthyroidism.	
	Preoperative cases.	Postoperative cases.	Preoperative cases.	Postoperative cases.
Nervousness	98	39	88	45
Tremor	93	21	83	6
Dyspnea	84	29	76	28
Palpitation	89	26	80	29
Tachycardia	79	24	72	23
Loss of strength	89	13	79	17
Loss of weight	89	..	92	
Vomiting	34	..	8	
Prominence of eyes	70	..	6	
Change of voice	25	12	6	11
Heart moderately enlarged	38	..	14	
Heart markedly enlarged	19	..	9	
Murmurs	33	..	28	
Edema	20	..	34	
Exophthalmos	67	25	3	
Thrill	48	..	4	
Bruit	72	..	10	
Average normal weight, pounds	137.3	Average gain in 61 cases 27.3	151.1	Average gain in 82 cases 31.6
Average weight at time of operation, pounds	121.8	Average loss in 5 cases 10.5	131.7	Average loss in 3 cases 11.5
Average pulse rate	122.6	.....	111.0	
Average systolic blood-pressure	145.2	.....	157.2	
Average diastolic blood-pressure	75.6	.....	82.4	

The most common symptoms persisting in each group are nervousness, tremor, dyspnea, palpitation, tachycardia, loss of strength, and loss of weight. It was difficult to estimate the amount of nervousness that persisted after the operation, and whether the nervousness that many of the patients spoke of was due to any remnant of the disease, because the patients who were apparently otherwise entirely well often complained of some nervousness. Practically the same may be said regarding dyspnea, palpitation and tachycardia. All patients who mentioned having any of these symptoms after operation are included regardless of the fact that most of them are entirely well.

TABLE III.—EXOPHTHALMIC GOITER.

Patients cured	58 (65.8 per cent.)
Patients markedly improved	12 (13.6 per cent.)
Patients slightly improved	5 (5.6 per cent.)
Patients died from all causes during the six years	15 (15.0 per cent.)

More than 65 per cent. of the patients suffering from exophthalmic goiter were free from all evidences of the disease six years after operation. Beside these 13.6 per cent. are markedly improved; some of them feel entirely well; 5.6 per cent. are slightly improved although they still have considerable evidence of hyperthyroidism; many of the group have only occasional acute exacerbations. Undoubtedly most of these patients would be benefited by the removal of more of the gland. Fifteen patients have died since the operation, 2 in the hospital, the others since going home. Some of these deaths were probably due to hyperthyroidism, but deaths from all causes have been included.

TABLE IV.—ADENOMA WITH HYPERTHYROIDISM.

Patients cured	83 (83 per cent.)
Patients markedly improved	5 (5 per cent.)
Patients slightly improved	1 (1 per cent.)
Patients not benefited	2 (2 per cent.)
Patients died from all causes during the two years	9 (9 per cent.)

Eighty-three per cent. of the patients with adenoma with hyperthyroidism are cured of all evidence of the disease two years after operation; 5 per cent. are markedly improved, and 1 per cent. slightly improved. Two per cent. derived no benefit from the operation. Nine patients of this group died during the two years.

CONCLUSIONS. 1. Thyroidectomy will cure more than 65 per cent. of patients with the more severe types of hyperthyroidism. If the patients could be treated early, and with a better understanding of the plan of treatment in all probability this percentage would be increased considerably.

2. More than 80 per cent. of patients with adenoma with hyperthyroidism can be relieved of their toxic symptoms and a cure obtained by thyroidectomy. A higher percentage of cures would undoubtedly be obtained if the patients were all operated on before there was any evidence of edema or terminal degeneration.

BIBLIOGRAPHY

1. Boothby, W. M.: The value of the basal metabolic rate in the treatment of diseases of the thyroid. Med. Clin. North America, 1919, iii, 603–618.

2. Boothby, W. M.: A study of the metabolic rates in adenoma of the thyroid with hyperthyroidism. Presented before the Harvard Medical Society, Boston, February, 1920.

3. Boothby, W. M. and Sandiford, Irene: The laboratory manual for the determination of the basal metabolic rate. Philadelphia, Saunders, 1920 (in press).

4. Plummer, H. S.: Discussion following paper by Marine, D.: The anatomic and physiologic effects of iodin on the thyroid gland of exophthalmic goiter. Jour. Am. Med. Assn., 1912, lix, 325–327.

5. Plummer, H. S.: The clinical and pathologic relationship of simple and exophthalmic goiter. Am. Jour. Med. Sc., 1913, cxlvi, 790–796.

6. Plummer, H. S.: The clinical and pathologic relationship of hyperplastic and non-hyperplastic goiter. Jour. Am. Med. Assn., 1913, lxi, 650–651.

7. Plummer, H. S.: Studies in blood-pressure, I. Blood-pressure and thyrotoxicosis. Tr. Assn. Am. Phys., 1915, xxx, 450–457.

8. Plummer, H. S.: The function of the thyroid, normal and abnormal. Tr. Assn. Am. Phys., 1916, xxxi, 128–133.

9. Sandiford, Irene: The basal metabolic rate in exophthalmic goiter, with a brief description of the technic used at the Mayo Clinic. Endocrinology, 1920, iv, 71–87.

GOITER: A CLINICAL STUDY OF 139 CASES

By MILES F. PORTER, M.D.
FORT WAYNE, IND.

The group of cases forming the basis of this study is made up of those cases only the records of which are on file in my office in the card system which I have been using since November, 1912. This group was chosen because it was believed that it would be thoroughly representative and especially because of the availability of the records for the purpose of study. No case is considered which presented itself after August 18, 1919. Total number of cases 139—females 121, males 18. This makes the proportion of males to females 1 to 6.7. The preponderance of females it will be noted is slightly less than that given by Dock[1] which is 6 or 8 females to 1 male. It is pretty generally believed, especially since our experience with the draft, that the preponderance of females over males is not so great as it was formerly thought to be. Of the 139 patients 74 of them presented themselves because of symptoms developing in a heretofore symptomless goiter or because a quiescent goiter had begun enlarging. In 47 of the 81 operative cases in which the history covers this point the symptoms calling for operation developed on old symptomless goiter. In 17 cases no mention is made in the histories bearing upon this point.

The youngest patient was aged sixteen years, the oldest seventy, both females. The average of all patients was 35.5 years, average age of males 33.7 years, average of females 35.8 years. Of the 121 females 82 were married, 39 were single.

[1] Modern Medicine, iv, 837.

In other words, 67.7 per cent. of the female goiter patients of this group were married. The statistics show that in Indiana about 65 per cent. of the females between fifteen and fifty are or have been married. These figures seem to indicate that the marriage state itself is not particularly conducive to the development of goiter. Fifty-nine (72 per cent.) of the married females in this group were parous and 8 (9.8 per cent.) sterile. Norris[1] says that one marriage in seven or eight is sterile and that from 50 to 75 per cent. of their sterility is due to the woman. Calculating from the figures given by Norris we find that 90.63 per cent. of married women are fruitful. In this group of cases the percentage of fruitful marriages is 18.63 per cent. less than this, viz., 72 per cent. indicating that goiter may be a causative factor in childless marriages.

Of the 139 cases 99 were treated surgically. Thyroidectomy was done in 81, injection of boiling water in 18 and in 3 cases both forms of treatment were used. In 2 of these the thyroidectomy followed the injection of boiling water and in 1 boiling water was injected into the right lobe at the time the left was removed. In one patient the right lobe was removed some months after the removal of the left by another operator. Of the cases which came to operation there were 10.8 females to 1 male—a somewhat greater preponderence of females than occurs in the same group when operative and non-operative cases are considered together. A very large proportion of the specimens removed by operation were submitted to microscopic examination—perhaps 90 per cent. or more though I cannot speak with exactitude. No case of so-called metastatic colloid goiter was encountered and I will add that I never have seen one. Five cases were pronounced malignant. All of these patients were females, all were married; 4 were multipara. One woman had been pregnant once and had aborted herself. Three of the patients presented toxic symptoms, 2 of them also had exophthalmos and 2 patients presented no toxic symptoms but came for opera-

[1] Surg., Gynec. and Obst., 1912, xv, 706.

tion because of pressure symptoms plus the disfigurement. In 4 of the patients the symptoms which caused them to consult a surgeon developed in a goiter of long standing. In 2 of these cases only the suspicion of malignancy was entertained prior to the operation, either because of the rapidity of growth or the nodular feel of the tumor, or both. The average age in these 5 malignant cases was forty years. The first of these operations was done in July, 1913, and the last in April, 1917. On one I am unable to get any report and the remaining 4 are living and well, although one of them reports that at times "it seems as though her neck is enlarged," but I have not had the opportunity to examine her. The other 3 show no signs local or otherwise of a return of the trouble, and one has passed through a normal delivery since her operation. Balfour[1] gives the cancer incidence in a group of goiter patients from the Mayo Clinic as 1.19 per cent. Ochsner and Thompson[2] say that it is less than 1 per cent. In this group of cases it is 3.64 per cent. Considering the large incidence of malignancy in this group together with the percentage (100) of cures, one is led to question the diagnosis in some at least of these cases. It is well to note here, however, that while all of these patients have passed the three-year period, only one has passed the five-year period while two are within a few months of the end of the five-year period. Microscopic sections on which the diagnosis of malignancy was based are herewith presented together with the pathologist's diagnoses. (See Figs. 1, 2, 3, 4 and 5 with accompanying legends.) Having presented the evidence, I prefer, without further argument, to leave the judgment in the case in the hands of fellows who have had a larger experience than I, simply adding that the microscopic diagnoses in 4 of the 5 cases were made by Dr. B. W. Rhamy, of Fort Wayne, who is a pathologist of large experience, and in the remaining case by Dr. B. M. Edlavitch, also of Fort Wayne, and who has had considerable experience.

[1] Collected Papers of the Mayo Clinic, x, 393.

[2] Thyroid and Parathyroid Glands, 1918, p. 33.

One patient only of the operative cases presented symptoms of parathyroid trouble after operation. They were very mild and subsided in a couple of days. In 2 of the thyroidectomies there were symptoms of injury to the recurrent laryngeal nerve. One seems to be permanent, at least she is seldom able to speak above a whisper now, more than three years after the operation;

Fig. 1.—Mrs. R., aged thirty-one years. Clinical diagnosis simple goiter. Pathologist's report: "Old mass shows marked adenomatous growth and little tendency to form gland lumen. It is the type approaching malignancy and in my humble opinion it is malignant." $\frac{1}{6}$ objective. Signed—B. W. R. Patient cannot be traced.

in the other case there was partial aphonia, which lasted but a few days. In both the posterior capsule was left at operation, and in neither did I have any suspicion that the nerve had been injured until the aphonia was noted. It is important to add that the patient with the permanent aphonia had experienced attacks of loss of voice on several occasions prior to the time she came for operation. I have not been able to trace all of

the operative cases, and therefore cannot speak with accuracy as to the results, but inasmuch as I asked all of the patients to keep me informed of their progress, and especially to inform me if they did not get as well as they thought they should and do know positively of the results in the majority, I feel warranted in saying that the operative treatment has been very satisfactory.

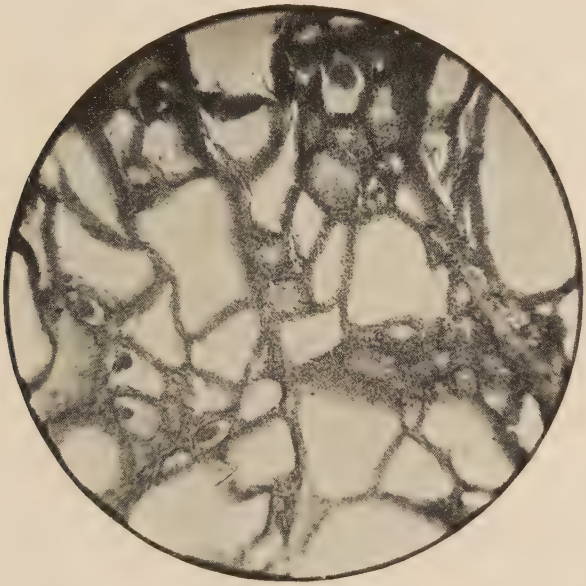

FIG. 2.—Mrs. K., aged thirty-eight years. Clinical diagnosis: Simple goiter. Pathologist's report: "Soft portion of tumor consists of closely packed adenomatous structure with very small lumen and free cellular growth in intercellular tissue. I consider this malignant."—B. W. R. $\frac{2}{3}$ objective. Patient's report: "Some pain in throat. Somewhat enlarged," four years after operation.

One patient is still suffering, after thyroidectomy, with toxic symptoms, with quite a considerable enlargement of that portion of the right lobe which was left at the time of the operation. One patient who presented a typical picture of the so-called neurotic type was, after extensive study by my confrères and myself, subjected to thyroidectomy for a small goiter which was present. Three months later he reported as having gained $11\frac{1}{2}$

pounds in weight, but as being no better so far as nervousness and weakness was concernd. In none of the cases with marked exophthalmos was this symptom entirely cured, but most of these patients declare that their eyes have always been prominent and are satisfied with the degree of retrogression that followed the treatment. There were no operative deaths attributable to

FIG. 3.—Mrs. S., aged fifty years. Clinical diagnosis: Exophthalmic toxic goiter. Malignancy suspicioned because of rapidity of growth and nodulation of tumor. Pathologist's report: "Malignant adenoma—badly broken down. Section from less degenerated portion—$\frac{1}{6}$ objective." Signed—B. W. R.

the boiling-water injections. Two patients whose goiters had been injected died some time after the last injection was given. One with pronounced cardiorenal involvement, which had existed for some months prior to her first visit to me. In this case no postmortem was made. The other patient who died following the boiling-water injections had received in all three injections. She presented the usual picture of pronounced

thyrotoxicosis, including exophthalmos. The patient presented no symptoms of reaction after either of the injections, and went to her home town and died four days after the last treatment. Postmortem examination was made by her attending physician, from whose report the following abstract is made: "Universal enlargement of the mesenteric lymph nodes. Right kidney much mottled; pyramids very dark; capsule easily stripped; left kidney

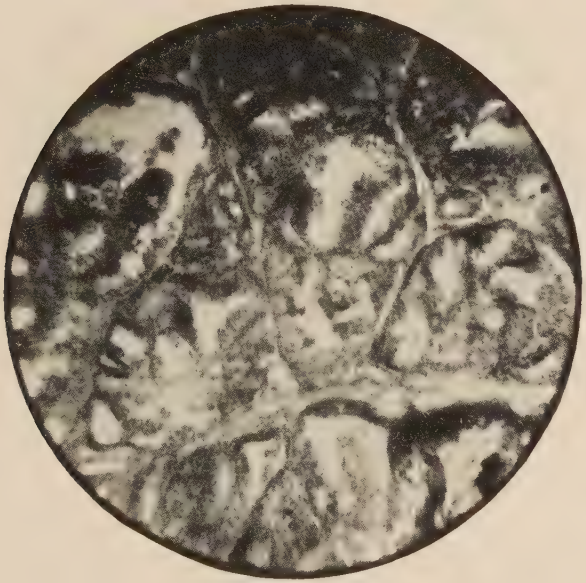

FIG. 4.—Mrs. S., aged twenty-seven years. Clinical diagnosis: Exophthalmic toxic goitre. Pathologist's report: "Adenocarcinoma—papillomatous outgrowths," $\frac{2}{3}$ objective. Signed—B. W. R.

very hard, not so large and not so much mottled. Spleen enlarged, with numerous light spots hard to the touch; left adrenal large, right not so much enlarged. Heart enlarged, muscular tissue normal. Remains of old lung and pleural lesions. The thymus gland, especially the right lobe, much enlarged, as long as the index finger. Thyroid enlarged, very firm, cuts with difficulty. Colloid material absent. Tissue has the appearance

of boiled veal or pork." Urinalysis made in this case twenty-four days before death occurred revealed a normal urine. The findings in this case indicate that the cause of the patient's death lay in the pathology found in the thymus and adrenals and raises the question as to the possibility of procuring relief through

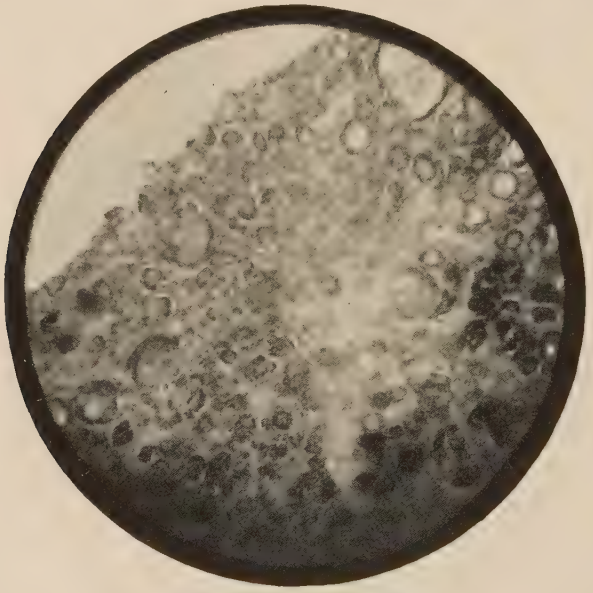

FIG. 5.—Mrs. N., aged fifty-nine years. Clinical diagnosis: Hyperthyroidism with suspicion of malignancy because of recent rapid increase in size of goiter of thirty years' standing and the nodular character of the tumor. Pathologist's report: Irregular diffuse growth of epithelial cells which are definitely malignant. These seem to originate from the cells lining the gland acini and are arranged in a rather alveolar form. There is relatively little colloid. The fibrous stroma is abundant in parts and very scant in others. Diagnosis: Carcinoma of thyroid. Signed—B. M. E.

a thymectomy.[1] At no time when I saw her did I regard her as a safe risk for even so slight an operation as ligation.

One of the patients treated with boiling-water injections was *in extremis* when I saw him with very aggravated symptoms of

[1] I have never done thymectomy in connection with thyroidectomy as I have never seen a case in which I thought such procedure necessary.

thyrotoxicosis, including anorexia, emaciation, diarrhea and mental aberration partaking of the nature of active maniacal type. After the third injection this patient went to his home town, continued to improve until he was considered a reasonably safe surgical risk, when he had a thyroidectomy at the hands of his home surgeon, with results reported to me several weeks later as entirely satisfactory. Several patients who received boiling-water injections were advised to have thyroidec omies done later. Five followed this advice; the rest were satisfied with the improvement following the boiling-water injections and refused further surgical interference, notwithstanding the fact that in several patients the goiter was large enough to be quite unsightly. There were three deaths following thyroidectomy—one death occurring during the operation, one thirty minutes after and one two hours after operation. The anesthetic used in two of these fatal cases was ether and in one novocain. Postmortem was not permitted in either case. I know now that operation should not have been attempted in either of these cases. One of the patients had been cured a year before her visit to me by boiling-water injections given by her family physician, and was very insistent that a radical operation be done if possible, and I allowed myself to be persuaded to remove her goiter under local anesthesia after twenty days' rest and treatment in the hospital. Of the other two fatal cases neither improved under rest, etc., and I was persuaded to undertake a radical operation when I should have done either a ligation or boiling-water injection. There were no fatalities after June, 1916.

In patients who are good risks and who stand thyroidectomy well, there is, in my opinion, no objection to doing other operations which are necessary at the same time. I have done hernioplasty, salpingectomy and hemorrhoidectomy immediately following thyroidectomy several times and have had no cause to regret my action. In this group of cases 65 were toxic, 26 exophthalmic, 37 simple and the remaining 11 were unclassified. The boiling-water treatment was given only in toxic and exoph-

thalmic cases. Seventeen thyroidectomies were done for simple goiter. A study of this group of cases throws no light on the question as to the relationship between goiter and local infections. Indeed, it is pertinent to say here that my whole goiter experience has left me undecided as to whether or not there is any causal relationship between local infections and goiter except infections of the thyroid itself and infections of the generative organs. There are patients in this group wherein a cure of frequent attacks of tonsillitis followed thyroidectomy and other patients in which removal of the tonsils was followed by a subsidence of the thyroid symptoms, and still others in which the thyroid symptoms were not benefited by the removal of the local infection, and again others in which the removal of the thyroid had no influence on the local infection present.

In the thyroidectomies local anesthesia was employed in 7 cases. Both local and general in 2 and in the remaining 67 cases ether was used. In no case was there any serious post-operative reaction. Routine blood examinations were not made for the reason that after quite a number of these examinations had been made the conclusion was reached that nothing of prognostic or diagnostic significance was to be gained thereby. In no case did a reaction of consequence occur and in no case was there alarming hemorrhage at the time of operation. In 2 patients, both young females, troublesome hemorrhage occurred a few hours after the operation. In one the hemorrhage was brisk and required a tampon which was removed after forty-eight hours, after which the case progressed normally. In the other case the hemorrhage partook more of the nature of an oozing, which kept up for forty-eight hours, and in spite of what seemed an ample drain of rolled rubber dam a hematoma was formed and was followed by a low-grade infection which prolonged the recovery several days. Stimulating treatment following operation was seldom used, perhaps in five or six cases all told.

DISCUSSION OF PAPERS ON TOXIC GOITER

Dr. E. Wyllys Andrews, Chicago:

In our clinic one conclusion which has been forced upon us is the decided value of the studies of metabolism, especially in the progress of exophthalmic goiter. Of course, it is true that the basal metabolism measured by the metabolic rate is not solely dependent upon goiter disease, yet as we have carried it out by studies in various clinics it certainly has developed an enormous importance as a decided influence and of prognostic value in operative work in deciding us when and when not to operate. We have found the simpler apparatus, like the Benedict, the use of a mask only, an excellent one not requiring the large box for the patients, and with a careful estimate of body interchanges we get a result approximately 90 per cent. correct. While it may be true that these gas interchanges as measured show a lot of changes not due to the endocrine organs, yet I think the experience of the whole world is that the one great pathology is that of thyrotoxosis itself. It is not of so much value as a diagnostic agent as for its prognostic value. When we find a case of hyperthyroidism with great acceleration of pulse we have proved that the metabolic rate goes 30 to 50 above normal, and this is one of the most important deciding factors for or against operative interference.

Dr. John B. Deaver, Philadelphia:

It has often occurred to me that in many, if not in all, of these adenomas would it not be the part of conservatism and not radicalism to operate them rather than to treat them medically? Especially so, as a percentage of them develop into toxic goiter as I know and as Dr. Crile has stated.

Dr. Charles A. Porter, Boston:

I have had about 200 cases of exophthalmic goiter and toxic adenoma and I want to speak of three or four things. In the first place at the Massachusetts General Hospital we are running a more or less unpleasant warfare between the surgeon, the radiologist and the medical man, there not being a perfect working arrangement between the three, but we are carrying on a definite series of *x*-ray examinations. I am perfectly convinced that the *x*-ray will cure both toxic and exophthalmic goiter in certain instances. I am in doubt as to the relation of the *x*-ray to the thymus, but we have a feeling that two or three exhibitions to the rays have a smaller mortality when operated on later. Papelli

and others have proved, in cases which have died, that the thymus is almost always large, and our one death during the last year had a large thymus. Would the obliteration of the thymus by the *x*-ray have anything to do with making the operation safer?

A word about ligation. My experience has been to do a ligation rather than to use boiling water. I have had more bad results from the use of boiling water than from the single or double ligation under local anesthesia. We are in the habit of keeping our patients in bed under medical supervision, with or without *x*-ray treatment until they are stable. When the pulse has reached the lowest rate under rest, and the metabolism has dropped to its lowest rate then we advise some sort of surgical operation, usually ligation, in cases with the metabolism rate over 50 and in which the clinical symptoms coincide with the metabolism. I agree with Crile in believing there is a judgment not to be measured by figures, but if any figures are valuable I think the metabolism rate is the most.

Dr. Albert J. Ochsner, Chicago:

I wish to say a word in regard to postoperative hyperthyroidism. At the present time I operate almost all cases under local anesthesia with novocain. For cases operated under general anesthesia I use ether by the drop method with the patient in the horizontal position giving $\frac{1}{4}$ grain of morphia and $\frac{1}{100}$ grain of atropin half an hour before beginning the anesthesia, and lifting the head of the table when full anesthesia has been produced to an angle of 45 degrees and giving no anesthesia during the operation. We have found in cases in which we have used this ether anesthesia that the postoperative hyperthyroidism is enormously decreased, in fact the cases have almost as little postoperative hyperthyroidism as those treated with local anesthesia, provided that gastric lavage is made use of with water between 105 and 110 degrees Fahrenheit immediately after the operation is finished, by which method all the mucus is washed out of the stomach and these patients go to bed with a lot of hot water in the stomach instead of mucus saturated with ether. They wake up by the time the lavage is over when they can be put to bed in the sitting position. You thus get rid of the postoperative hyperthyroidism, nevertheless lately we have operated almost all cases under local anesthesia. I wish to direct your attention to a very helpful symptom. Years ago Crile stole away his thyroids, but now with the greatest frankness he has the nurses make the patients familiar with what is to happen. Years ago, when Dr. Mayo spoke of it, we used the *x*-ray in a good many cases with good temporary results but during the past year

someone has worked out a plan of giving *x*-ray in a different manner which I think is very much better, namely, by using the Coolidge tube and by filtering the rays through 3 mm. of aluminum and 5 mm. of sole leather. With this method there is no burning of the skin and the rays are more effective. Since this method was introduced a few months ago I have used it in a few cases and believe that it will be valuable. The ice-packs spoken of by Dr. Crile are undoubtedly of great value. I have not used them in the way he suggests but for years have regularly used a very large coil of rubber tubing through which ice-water is run to cover the entire chest in cases showing post-operative hyperthyroidism. I think Crile's plan is much better.

Dr. Alexis V. Moschcowitz, New York City:

I do not remember the time when I was not greatly interested in the subject of goiter; I therefore rise to give expression to a sense of envy or jealousy of those who have been able to report literally hundreds of goiter cases. It has been my experience that in the city of New York at least, and at the present time, exophthalmic goiter is considered decidedly a medical disease, and it is only when the case has been treated by medical and physical means to the full limits, that a case is finally referred to the surgeon. Even at Mount Sinai Hospital goiters are usually admitted to the medical service of the hospital, hardly ever directly to the surgical service. One of the most important phases of the operation is that of postoperative hyperthyroidism. I believe that the avoidance of this symptom-complex is of paramount importance.

Dr. M. L. Harris, Chicago:

In regard to postoperative aphonia I think the fact that this may occur without permanent injury to the recurrent laryngeal nerve, by cutting, suturing or crushing, has not been widely enough recognized. The importance of recognizing the fact that aphonia may result has been called attention to by a suit in Chicago in which it was claimed that one of our surgeons had injured the recurrent laryngeal during thyroidectomy thus permanently destroying the voice of a vocal artist. Since operating on thyroids under nerve blocking when the condition of the voice can be tested I have seen aphonia come on gradually, the voice becoming weaker and weaker, when it was perfectly apparent that the laryngeal nerves had not come into the field of operation and when the operation was difficult, requiring considerable manipulation so that the recurrent was drawn on or displaced from its bed. This aphonia is temporary though it sometimes lasts

quite a little longer than at other times. We should recognize the fact that temporary injury to the recurrent laryngeal may occur from the manipulation necessary to the removal of the thyroid, and in cases where this is likely to occur the patient should be warned of this possibility in advance.

Dr. Charles A. Porter, Boston:

I think it is not unlikely that some of that gradual aphonia is due to the local anesthesia. I have seen that in two or three cases.

Dr. Arthur Dean Bevan, Chicago:

I would like to emphasize one fact brought out by Dr. Crile. That is the value of the careful clinical evidence obtained in these cases. I am not prepared to discuss the great value of basal metabolism but I am prepared to emphasize the great value of careful clinical evidence which overshadows everything else in the diagnosis of these cases. I was very much impressed by a recent case, a man who came to my office from a very well organized clinic in which the metabolism tests had been worked over with the greatest possible care, and he told me he had been under observation at that clinic for about a week, undergoing examinations of his eyes, nose, teeth, blood, *x*-rays of chest and abdomen, urinalyses, and when they got all through they told him there was nothing wrong with him, that he had been on too rigid a diet, had lost a good deal of weight and for him to go home and take things easier and he would be all right in a short time. As he sat in the chair facing me he pulled his handkerchief out of his pocket. He mopped the perspiration from his face and then holding the handkerchief in his trembling hand said they were wrong, that he had lost 50 pounds and could not do his work. His own story made the diagnosis of toxic goiter certain. Now you cannot practice surgery or medicine by laboratory tests or short routes. There is something in personal experience, in careful clinical observation which, after all, is of greater value than anything else. It would do us all good to read the book on the future of medicine by Sir James Mackenzie in which he emphasizes the importance of clinical observation. This man whose case I have just recounted was operated under local anesthesia, his thyroid on one side removed, and he gained 30 pounds in eight or nine weeks and has made an excellent recovery. I would emphasize the importance of individual study in each of these cases, the enormous importance of analyzing each case and carrying it along and selecting the proper time and procedure in order to cut down the mortality and cure these patients. I have not had very good success with the boiling

water treatment introduced by Dr. Porter. I have had a good deal of benefit from ligations, but you must remember as a preliminary step the ligation of a single artery must not mean that you have cut down your blood supply to any great extent. Our whole knowledge is based on the theory of Moebius and the work of Kocher, that the difficulty is due to oversecretion, and that must be diminished in some way, two ligations very often proving effective. Three ligations almost always give definite results. I am satisfied also that in serious cases the *x*-ray is of value. In the serious cases there can be no doubt but that operations under local anesthesia will give the patients more prospect of recovery.

Dr. John H. Gibbon, Philadelphia:

I should like to ask Dr. Crile in regard to the use of the ice. He speaks of it in the postoperative period for hyperthyroidism, the temperature being the indication. I would like to know if that is the only indication for its use. Can it be used before operation in very toxic cases in preparing them for operation? It has always seemed that ice has done a great deal of good before operation, though I have not employed it to the extent advocated by Crile.

Dr. L. L. McArthur, Chicago:

Regarding the point raised by Dr. Porter of Boston who says the aphonia may be due to the local anesthesia, this might be the case if one were to apply a local anesthetic strong enough to the recurrent laryngeal nerve, but in blocking for thyroid the recurrent laryngeal is not reached. One blocks the cervical plexus on both sides of the neck. Again, anesthesia is complete and the voice remains strong. Again, the aphonia does not come on until and unless sufficient traction or disturbance has been made on the recurrent laryngeal nerve, the anesthesia wears off in several hours, while the aphonia persists for several days.

Dr. George E. Brewer, New York City:

With reference to this interesting question of aphonia I have had an experience which disturbed me very much. It was in the case of a trained nurse, highly intelligent, who had seen a good deal of goiter work, and who was constantly reminded in the operating room or elsewhere of the possibility of cutting the recurrent nerve. After years of strenuous work she developed a thyroid with neurosis. Her condition was so grave that it was a question whether or not to operate. I operated upon her, and the morning after, when I visited her she was

absolutely aphonic and I naturally thought it due to division of the nerve, but upon inquiring of the night nurse found that she on coming out of ether, had screamed and cried, her voice being entirely normal, and that it was only after she regained consciousness that she developed this purely neurotic aphonia, which continued for a number of months without cessation until she began to recover from the general toxemia. She has now made a perfect recovery, has been working in France for a year and a half, and is in perfect health.

Dr. George W. Crile, Cleveland:

There is no doubt that adenomata which have no basal metabolism and no toxic symptoms are oftentimes associated with myocarditis and high blood-pressure. We have tried a series of adenomata alone, with no toxic symptoms, for the purpose of modifying the blood-pressure, but we cannot report on these cases as yet.

We make the patient very familiar with the preparation for the operation, anesthetic proceedings, etc., but we have not taken them into our confidence to quite the extent suggested by Dr. Ochsner. I am convinced that a great deal depends upon the manner in which the patient is reassured. There are cases such as that spoken of by Dr. Moschcowitz in which the patient desires the operation and has complete faith in its outcome; this contributes to the good results. The operation for toxic goiter is a difficult operation and requires the same principle of fragmenting the operation, and thus making it a safe one, that Dr. Bevan at New Orleans advocated in his paper on operations upon the large intestine. Dr. Summers carries out the same course, *i. e.*, he conserves the factor of safety in the patient.

In reply to Dr. Gibbon's question I would say that we have tried the use of the ice pack before the operation, but because these patients are so sensitized they cannot be bothered with any additional proceeding without bad results. I have thought of using a cold room, but have never been able to accomplish this. But for that intensive period after the operation when the patients are so hot with fever that they do not mind what is done for them the ice packs are very effective.

Every one interested in this subject would do well to read what Dr. Marine has done with adenomata. He believes that these adenomata can be prevented by feeding iodine to pregnant mothers living in a goiter region. If that is true, and I believe Dr. Mayo will agree that all cancers originate in fetal adenomata, then by a simple drug a goiter will be prevented by this method of giving iodine to the pregnant mother. Dr. Marine is also controlling goiter by the judicious early use of iodine in school children. It is a matter of greatest importance

that we as surgeons exert our influence so that our present knowledge may be applied for the prevention of this geological disease—the lack of iodine. It is our obligation to prevent goiter in the next generation.

Dr. Leonard Freeman, Denver:

The turn of the discussion toward the question of aphonia emphasizes the necessity of giving attention to some operation which protects the recurrent laryngeal nerve.

Dr. Charles H. Mayo, Rochester:

This discussion with its interesting questions and reports has been most illuminating. In the clinic we have endeavored to impress on our assistants that the conduct of the anesthesia is exceedingly important; in this we agree with Dr. Crile, who takes great care in the protection of his patients; the careful observation of the patient is of the utmost importance, especially for surgeons who do not operate often for goiter. Most surgeons who operate a great deal have their own technic and do not rely entirely on special methods of anesthesia, I believe, for producing good results.

The question of judgment to be used in selecting patients with goiter for operation is most important. We are not born judges; that takes years and years of experience. The older men have developed the sense by the time they are ready to drop out, when their experience would be invaluable to the younger men if it could only be transmitted. Since this is impossible we must depend upon laboratories and on our, often inadequate, judgment. The case which Dr. Bevan reported of the man who went through all the tests sounded almost as if the man in the case had been through our clinic. If his metabolic rate were now determined it probably would be found to be subnormal. A rapid gain in weight does not always mean good health; it may mean that the patient is becoming myxedematous. The inability of the body to absorb iodine means a great deal and is probably an etiologic factor in many forms of goiter. For example, in certain types of large goiter, if the patient is given 7 mg. of thyroxin intravenously the goiter will disappear in three days, and if the person is also myxedematous he will be so changed as to be hardly recognizable. Many persons with myxedema cannot absorb iodine because their intestinal cells are not functionating properly, but if the injection is given intravenously the desired result is obtained. The majority of persons can be cured by feeding thyroid tablets.

With regard to the question of high temperature: Unfortunately

all patients do not die with a high temperature; they just fade out, so the ice-pack is not necessarily indicated.

As to operating in all cases; of course this should not be done. Some patients with exophthalmic goiter recover spontaneously. That is why it is difficult to get something out of the report on *x*-ray treatment by Means and Aub of Boston. An analysis of this report does not afford much satisfaction, and yet results may be obtained in the future.

In treating patients with goiter the confidence of the patient means everything. Surgeons who have this do not need a side show. We do not refuse to operate on any patients, but we have to get around them. Recently it took me half an hour to talk a woman out of the idea of an operation. She came confident that I could lay my hands on her and cure her. I explained to her that she could be operated on but that she would not be improved and that she would run a great risk because of conditions other than the toxic adenoma. We do operate on all patients who come to the hospital, but we stop many patients at the clinic. Some patients with exophthalmic goiter when they return for a postoperative examination say they are cured of the goiter although they still have marked exophthalmos.

Exophthalmic goiter recurs in about 10 per cent. of the cases; about one-half of the patients will be reoperated on, and about one-half of those who have a second operation will have a second recurrence. Some adenomas are fetal, that is, an isolated fetal rest is present at birth which later proliferates and may form a toxic adenoma. The normal cells may suddenly become uncontrolled late in life and develop into the hyperplastic cell of exophthalmic goiter, as pointed out by Plummer. In the cases of goiter with hyperplasia there is therefore a high tendency to recurrence, due possibly to the stimulus which was the original cause of the disease.

Dr. Miles F. Porter, Fort Wayne:

I first want to speak of the point raised by Dr. Deaver. On several occasions I have made the statement, and I want to make it again, that there is just as good clinical reason for removing a quiescent goiter that has come to stay as there is for removing a wart or a mole for the purpose of preventing future trouble. In other words, if we were to remove all of the symptomless goiters we would have fewer toxic goiters to remove, and our death-rate would be reduced accordingly as well as our rate of bad postoperative results. Personally I have seen none of the risks of which Dr. Crile speaks from the high temperature but if I do I shall certainly carry out his treatment. I presume we all do, but we do not talk as if we did make any distinction

between following operation and because of operation; there are a lot of people die after thyroidectomy, after injection of boiling water, but it does not follow they die because of these procedures. I have been asked as to the relative merits of boiling water and ligation. In the ordinary small hyperplastic gland with pronounced symptoms, equal in contour and consistence, an injection of boiling water of from 20 to 40 mm. into the substance of that gland will accomplish more than by a double or single ligation and six weeks spent in bed. That is my firm conviction. As we progress the number of ligations and boiling water injections must diminish. I want to enter a protest against lobectomy except as a palliative measure. The test of an individual's voice during the process of operating or during his dreamy period after anesthesia is not necessarily conclusive. He may be able to make a noise and not be able to phonate.

ORIGINAL CONTRIBUTIONS OF AMERICA TO MEDICAL SCIENCES—A SUPPLEMENTARY NOTE

By EDMOND SOUCHON, M.D.
NEW ORLEANS, LA.

In the *Transactions of the American Surgical Association* for 1917, I published a paper entitled "Original Contributions of America to Medical Sciences."

At the meeting of the Association in 1919, Dr. W. H. Carmalt, of New Haven, Connecticut, stated that not a single statement for Connecticut purporting to be fact was true, and the article was full of mistakes historically.

In reply to this I beg leave to cite my authorities for my statements.

With regard to the older contributors from Connecticut, Dr. Beardly is quoted from the *Cyclopedia of American Medical Biography*, by Dr. Howard Kelly, 1912, vol. I, p. 67.

Dr. Cogswell, from p. 133, of the *Century of American Medicine*, 1876, Section on Surgery, by Dr. Samuel D. Gross.

For Dr. Nathan Smith, see pp. 160 and 162 of the *Century* and p. 388 of the *Cyclopedia*.

Dr. Nathan Byron Smith is credited by some to Baltimore, p. 147, of the *Century*, and p. 390, vol. II of the *Cyclopedia*.

Dr. Jonathan Wright, for Jonathan Knight, is a typographical error. Dr. Knight is quoted from p. 141 of the *Century* and p. 7, vol. II, of the *Cyclopedia*.

With regard to the more modern contributors for Connecticut, from Riggs down to Lusk, my authority is Dr. H. Fielding Garrison, principal assistant librarian in the Surgeon-General's

Library, in Washington City, who kindly furnished me with the data.

In reply to a letter from me for further explanation, Dr. Carmalt mentions as other mistakes that I say in one place that Dr. Nathan Smith was the first to reduce a hip luxation by manipulation, and that further on I say Dr. William W. Reid was the first to systematically reduce dislocations by manipulation.

Also that Dr. R. Erdman worked with Professor Harrison in New Haven.

Dr. Carmalt states that Dr. L. B. Wendel did most of his important work at the Sheffield Scientific School of Yale University at New Haven.

Dr. Graham Lusk has done his most important work in New York.

Dr. Walter T. Sedgwick has done his most important work in Boston. He received no mention of his work.

Dr. Horace Wells has done his most important work in Hartford.

That Dr. Ross G. Harrison's most important work was done at Johns Hopkins.

Lastly, that Dr. Wadsworth, who invented the tilting mirror of the ophthalmoscope, lived in Boston.

In reply to the foregoing criticisms, taking them up in the order they are mentioned in Dr. Carmalt's letter, I will state that with regard to Drs. Nathan Smith and Reid having both reduced dislocations by manipulations, it is not uncommon for two or more surgeons to claim priority. In my paper I give a number of instances. Dr. Reid is quoted from the *Century*, p. 153.

As to Dr. Erdman, my authority is Dr. H. F. Garrison, who kindly furnished me with the information

Also for Dr. L. B. Wendel. Also for Dr. Graham Lusk.

Dr. Sedgwick received no credit for his work, because he did not reply to my circular letter published at the time in the *Journal of the American Medical Association.*

As to Dr. Horace Wells, it was in Boston that he attempted to administer his anesthetic (Bigelow, *Century*, p. 82).

As to Dr. Ross G. Harrison (Germantown), his important work was published in Philadelphia in the *Journal of Experimental Zoölogy*, 1910, vol. IX, pp. 784, 846. Dr. Harrison is my authority.

Dr. Carmalt does not deny that Dr. Wadsworth invented the tilting mirror. He is more precise, that is all.

The corrections relate to small matters, to dates and localities.

Some of them are truly trivial, as Dr. Carmalt himself says in his letter (p. 5).

It is noteworthy that none of the criticisms affect the correctness of the contributions, which is the cardinal point.

Before the printing of the manuscript, Dr. William J. Mayo, of Rochester, Dr. William Halsted, of Baltimore, and Dr. H. F. Garrison, of Washington City, courteously read it, and they reported no mistakes.

On March 1 I sent a letter to all the Fellows of the Association, asking them to inform me if they had found any mistakes in the article, that I may correct them in a supplementary note.

The following are the replies I received: Dr. Harvey Cushing, now of the Harvard Medical School, states that the intestinal suture attributed to him was described by Dr. Hayward W. Cushing, of Boston; that the correct name of the incision he described for exposure of cerebellar lesions is the "cross-bow" incision.

Dr. Frederick Kammerer, of New York, claims to be the first to show that gonorrheal arthritis is due to invasion of the gonococcus. I did not get the information before.

Dr. J. Collins Warren, of Boston, sent me for the first time information that Dr. J. Mason Warren, of Boston, discovered a new operation for the closure of the hard palate. He also informs me that the full name of Dr. Morton of ether fame is William T. G. Morton. The *Cyclopedia* says Dr. William Thomas Greene Morton.

Dr. Vander Veer writes that Dr. Peaslee was the first to suggest the introduction of the rubber drainage tube for the permanent drainage of the pelvic cavity.

Also, Dr. Bull, of New York, should be given much credit for the immediate treatment of wounds of the intestines proper.

Dr. Donald C. Balfour, of Rochester, Minn., sends for the first time a record of contributions by him of recent date. These consist of a modification of operative anastomosis of sigmoid colon to the rectum, suggestions in operative treatment of goiter and new observations in abdominal surgery, and the pathology of dermoid tumors.

Dr. J. J. Buchanan, of Pittsburg, Pa., writes that on pp. 149 and 150 the correct name of Dr. Walter is Dr. Albert J. Walter, who performed the first deliberate laparotomy through the unbroken skin for accident. This consisted of an abdominal section for intraperitoneal rupture of the bladder.

Also, on p. 147, the correct name of Dr. Bedford is Dr. Gunning S. Bedford.

INDICATIONS FOR ACTIVE IMMEDIATE MOBILIZATION IN THE TREATMENT OF JOINT INJURIES*

By COLONEL CH. WILLEMS,
PROFESSOR OF CLINICAL SURGERY, UNIVERSITY OF LIEGE

I do not consider it necessary to review in detail the technic and results of this method, all of which I have already published in full in the *Transactions of the Interallied Conference on War Surgery*, in the *Bulletin of the Société de Chirurgie de Paris*, the *Bulletin of the Académie de Médecin de Paris*, the *Archives Médicales Belges*, the *Bulletin of the Académie de Médecin de Belgique* and in *Surgery, Gynecology and Obstetrics*, the *Medical Record*, etc.

But I learn by a perusal of the published observations of other surgeons that the method is almost never correctly applied. They content themselves with partial results, because these greatly excel anything obtained by the old classical methods of treatment. But this is not sufficient. In purulent arthritis, for example, it does not suffice to conserve mobility; it is necessary to prevent entirely, or almost entirely, the muscular atrophy. If muscular atrophy is present as a result, it means that the movements have been commenced too late, have been too infrequent or have not been continued long enough.

Frequently the authors indicate that these patients with purulent arthritis have begun active movements but have been obliged to discontinue them, not having the power to execute them at a given moment. In these cases one ordinarily finds evidences of pus retention the result of insufficient mobilization. To remedy this it is necessary, instead of stopping the move-

*Translation by the Editor.

ments, either to enlarge the incisions, which are often too small, or to make the movements more complete. It should be emphasized that a minimum amount of pocketing of pus suffices to arrest voluntary movements.

Further, the patient always attempts at the beginning to escape the obligation of movement, which he regards as a disagreeable task. I am not able to insist sufficiently on the capital importance of having at one's disposal a personal nursing attendant, devoted to duty and thoroughly familiar with the method, as it is on the nursing of the wounded man that the success depends in great part.

What are the indications as to active mobilization in the wounds of joints complicated by fracture? In my early publications I have said that the method was not applicable to extensively comminuted fracture of joints when the lines of fracture extended to the diaphysis. Since then the facts have made me admit we may employ it in all fractures of joints, whatever the extent of the lesions, although it must be understood in a modified form. In the elbow, for example, the major fractures admit perfectly of treatment by active limited movements. It is true the movements do not maintain the fragments in perfect reduction, but the fragments are disengaged, pushed back from the interarticular space and a sufficient regularity of the articular surfaces preserved to ensure a certain range of mobility much better than one could secure by immobilization. In certain cases the result can be improved later by the removal of an osseous spur which constitutes a mechanical obstacle.

Surgical fixation of the fragments, which reëstablishes at once the physiologic conditions, may render great service in these cases, but not when the lesion involves the cartilage, because in war wounds osteosynthesis is often followed by hyperostosis.

If the articular wound is complicated by infection in addition to fracture, mobilization is still more strongly indicated, as it alone can give drainage, which is not perfect by reason of necessary limitation of the movements, but in all cases superior to that accompanying immobilization. Osteosynthesis in the midst of

infection may facilitate the movements, but the plates will have to be removed secondarily.

With a fractured knee it is evident that it is not a question of having the patient walk immediately, but mobilization in bed is possible, especially if one adds thereto a continuous extension which furnishes a certain fixation to the fragments as well as a point of application for muscular action. This mixed method of treatment of articular wounds complicated by major fractures, by extension combined with active movements, gives functional results far superior to those obtained by other methods.

Let us examine now as to whether intra-articular fractures with destruction and removal of a large fragment of the epiphysis admit of treatment by mobilization. I am speaking now of cases in which one-third or more of a condyle has been lost. In these cases the danger lies in a lateral bowing of the joint. This danger is especially present in the knee, where lesions of this nature have been considered heretofore as calling for immediate resection. I believe that this is an error. In the elbow in cases treated conservatively after this manner, with active mobilization, I have seen sufficient strength to render good service. I have seen the knee readapt itself rapidly, permitting the patient to walk and use the joint with flexion and without pain. Sometimes it is necessary to protect the limb with a jointed brace, but at the same time the condition in walking is far superior to that accompanying an ankylosis. If unfortunately the result should turn out unsatisfactorily there is always the opportunity to practice secondary orthopedic resection.

I emphasize then that bony lesions constitute no contraindication to active mobilization, and that in such cases they give unhoped-for success.

I am now at the last class of injuries, comprising extensive destruction of the tissues uniting the joints, especially the ligaments, and particularly the anterior and crucial ligaments of the knee-joint. Whether their destruction is primary or consecutive to joint suppuration does not seem to me to interdict all movement. In cases of this type observed recently, whether

accompanied by section of the patellar ligaments or by destruction of the crucial ligaments, which have been treated with continuous extension combined with active movements, I have seen a correction of the posterior subluxation of the tibia and have obtained a cure, with partial conservation of movement, even in the presence of a simultaneous purulent arthritis. It must be understood that such treatment demands unremitting attention and perseverance on the part of surgeon and nurses.

In a *résumé* of the actual state of the question I estimate that active mobilization knows no contra-indications by reason of extent of bony lesions or extent of destruction of the ligaments. I would urge surgeons not to abandon the method at the first difficulty, but, on the contrary, to pursue it to the end, with the conviction that the functional result will be the more brilliant in the same proportion as the efforts to obtain it have been more energetic and tenacious.

TECHNICAL PROBLEMS IN THE OPERATION FOR DISCONNECTING GASTRO-ENTEROSTOMY STOMAS

By E. WYLLYS ANDREWS, M.D.
CHICAGO, ILL.

Recently we have been compelled to reoperate a considerable number of old gastro-enterostomies; in fact, this has become a fairly large percentage of the stomach surgery in our clinic. Gastric surgery, and especially gastrojejunostomy, like other good things, is often misapplied and abused, so that numberless invalids have been more invalided (when they have not died) after surgical treatment. We see many such failures and are often beseeched by suffering patients to reopen and undo the work of former operators—close gastro-enterostomy openings, reopen the occluded pylorus, etc.

Doubtless this secondary sort of work might itself become a fad and be abused by that class of surgeons one may call "routinists," but when these cases come to us from the services of our best internists with the recommendation for operation, we conclude that the need for relief is real and not imaginary. Fortunately, the operation is not formidable or dangerous. We have been able to develop a technic that is simple, safe and rapid. We have found it is possible entirely to restore the separate continuity of these organs, so that the visceral circulation is resumed exactly as if the false opening never had been made. Even when the pylorus has been occluded it is not difficult by a plastic to reopen it.

Two very positive indications have been presented to us for closing gastro-enterostomy stomas:

1. "Dumping stomach." We find no other term which will describe the postoperative conditions in which the stomach has so large a stoma that it literally dumps its whole contents instantaneously into the bowel; in other words, its retaining power is *nil*. In one such case the fluoroscopic examination showed the whole barium meal falling through the stoma in thirty seconds. It was so nearly instantaneous that the tilting fluoroscopic table could hardly be raised quickly enough to observe or photograph any of the opaque mass still in the stomach. This patient had almost a total anacidity and progressive emaciation, pain and anorexia. Others have the same phenomenon in less extreme degree.

2. Vicious circle and bile accumulation in the stomach requiring constant use of the stomach tube or causing persistent vomiting.

3. Finally, we have had to deal with neurotic and psychic individuals, persons with exalted reflex excitability, who imagine their gastrojejunostomies have done them harm instead of good. This is the class of cases we have been reluctant to treat surgically without objective evidence of structural derangement. Some of these patients have been physicians who have gone the rounds of many clinics; some were neurasthenics who rush to any new idea offering a promise of relief.

Under these three limitations it is fair to say that a considerable percentage of stomach cases will be found who have been made worse by operation and who must have their surgical work undone. It is humiliating that we are only correcting our surgical mistakes when we do this, but there is no want of candor or fairness in our attitude, since we admit the possibility of our own cases being among those requiring correction.

Broadly speaking, when gastrojejunostomy has been a failure or an injury to the digestive functions it may be assumed that it never was indicated. The best way to avoid additional mistakes is a prolonged and scientific analysis of all the factors in such cases in collaboration with internists and stomach specialists with the case under observation in a hospital. We should bear in

mind that these cases are even more liable than ordinary ones to mistakes from hasty judgment and insufficient objective evidence and lack of proper laboratory tests. The fact of one error having been made either in diagnosis or technic should warn us to regard each such case as one carrying dangerous possibilities of further errors.

Eliminating all errors and doubtful cases, and they are many, we still find a residue of proved examples of deranged function due to faulty surgery. It is the purpose of this paper to show the operative steps as worked out in our clinic and to demonstrate that the method is safe, rapid and of unfailing benefit when the pathology found clearly indicates its necessity. The problem is the simple mechanical one of closing a false opening between two hollow viscera, with or without separating them from each other, and of doing this in the quickest, most aseptic and most bloodless manner. We have been able to accomplish this with two forms of operation of somewhat opposite type:

1. Open clamp method or "reverse gastro-enterostomy."
2. Closed clamp method or angiotribe and cautery division, not exposing the lumen of either viscus.
3. "Stomaplasty" or partial closure of the false opening for the cure of "dumping stomach." This is a doubtful method in our experience and we must have more time and statistics before we can advise it unreservedly.

1. "Reverse gastrojejunostomy," or open clamp method. This was our first and is still perhaps our favorite method on account of its mechanical fitness to speed and safety. The steps are an exact reversal of the ordinary gastrojejunostomy, with certain precautions to avoid stricture of the small bowel. After lifting the transverse colon and exposing the line of union to the bowel the rubber-covered clamps are placed upon each viscus, leaving a free space for operation. The whole problem is now so to restore the jejunum as not to leave it strictured or narrowed. This would inevitably occur were we to divide the viscera along the old suture line and then close the false opening in each organ with the usual inversion. To avoid this we make the section

1 cm. upon the stomach wall away from the line of anastomosis. This means that a cuff of stomach wall will be left attached entirely around the false opening in the bowel. The fact of sacrificing this amount of stomach tissue is of no consequence, but the value of the cuff of stomach wall is apparent when we begin to close the jejunal opening, for it is just sufficient when you have made a double or triple row of inverted stitches to bring the bowel to the proper diameter. Both stomach and intestine are closed by the Vienna method of three rows of stitches or by the Connell and serous stitch, when it will be found that the two organs have been restored to their natural positions and mobility, except that the stomach remains anchored to the transverse mesocolon.

2. Closed Method: As an alternative, to make the operation more absolutely aseptic, Dr. Edmund Andrews has suggested and practised a method of separation similar to that used in resection of the stomach, namely, the use of the Péan crushing clamps, which enable us to divide both organs without exposing the lumen except along the crushed edge. If we make this division with the cautery or with the knife or scissors followed by the cautery, we have a technic theoretically more aseptic. A practical difficulty was found in one case in the lack of available space for placing the two clamps, but in other cases it was found easy of execution and very quick and satisfactory. After sterilizing the edges of each and before opening the clamps a running stitch is inserted, as in pylorectomy, and this is drawn at the moment of removal of the clamps. This suture is then buried by a second seroserous stitch, a Lembert or Cushing, when it will be found that the organs present exactly the same appearance as in the first method.

3. "Stomaplasty," or plastic closure of part of the false opening, is indicated in cases which have had pyloric obstruction either from disease or intentional closure. Should the pylorus have been found closed we are compelled to choose between a plastic operation to reopen it or a plastic partial closure of the gastro-enterostomy. It will be seen that this is a simple and

easy procedure, the only doubtful point being how much of the opening to repair and whether to accompany it with a similar plastic upon the pylorus. Our experience in this technic has been too limited and the time too short for any positive conclusions as to its merits. Mechanically speaking, the operation is simple and ought to yield good results unless the inveterate tendency of gastro-enterostomies to close up would tend to impair the permanent value of the work.

CONCLUSIONS. 1. Closing of gastro-intestinal stomas is a safe procedure and is often indicated.

2. It should become a standardized operation and will remain such as long as the indiscriminate use of gastrojejunostomy is persisted in as a cure-all for digestive troubles.

3. To avoid the danger of even this operation becoming too much a routine in uncritical hands, all these patients should be subjected to border-line examination by internists and surgeons, preferably for a considerable period and in a good hospital.

4. At least three methods are applicable in the surgical management of these cases: (*a*) Simple reversal of the steps of gastro-enterostomy; (*b*) exclusion by the crushing clamp, cautery, and closed resection; (*c*) plastic operation for partial closure of the false opening.

INDEX

ROYAL SOCIETY OF MEDICINE
16 JA 1922

A

ADENOMA, toxic, consideration of, in relation to exophthalmic goiter, 637
with hyperthyroidism and exophthalmic goiter, operations for, 662
Amputation neuromas, their development and prevention, 231
Andrews, E. Wyllys, technical problems in the operation for disconnecting gastro-enterostomy stomas, 698
discussion on operation for large ventral herniæ, 292
on pulmonary thrombosis, 497
on toxic goiter, 681
Anemia, pernicious, blood transfusion and other surgical procedures in, 451
Appendicitis, acute, causes of death after operation for, 405
Artery, deep epigastric, spontaneous rupture of, 229
Ashhurst, Astley P. C., observations on empyema, 63
discussion on bone surgery, 610
on operation for large ventral herniæ, 292
Aspiration drainage for acute empyema, the Morelli method of, 188

B

BECK, CARL, discussion on acute and chronic empyema, 227
Bevan, Arthur Dean, diverticula of the esophagus, 334, 347
discussion on toxic goiter, 684
on diaphragmatic hernia, 623
on cancer of the breast, 332
Blake, Joseph A., discussion on amputation neuromas, 271
on postoperative pulmonary thrombosis, 495
on acute and chronic empyema, 222
on pulmonary thrombosis, 495
Blair, Vilray P., discussion on operation for large ventral herniæ, 290
Bone, dead, recognition of, 574
Branchiogenetic cysts, relationship between ranula and, 417
Breast, cancer of the, technic in operations for, 314
female, traumatic fat necrosis of, and its differentiation from carcinoma, 294

Brewer, George Emerson, presidential address, 1
discussion on operation for large ventral herniæ, 293
on toxic goiter, 685
Bruce, Herbert A., restoration of function of facial nerve five years after anastomosis with hypoglossal, 228
spontaneous rupture of the deep epigastric artery, 229
Buchanan, J. J., reduction of old dislocations of the hip by open incision, 547
Bunts, Frank E., operation for empyema in young adults, 156
Burns, roentgen-ray, radical treatment of, 272

C

Cancer of the breast, technic in operations for, 314
ovary, with invasion of sigmoid flexure, 435
Carcinoma, differentiation of traumatic fat necrosis of the female breast from, 294
Cervical ribs, adventitious ligaments simulating, 566
Charcot joints, 601
Clavicle, sarcoma of, end-results following total excision for, 506
Coley, William B., sarcoma of the clavicle, end-results following total excision, 506
discussion on operation for large ventral herniæ, 291
on postoperative pulmonary thrombosis, 495
Cotton, Frederick J., notes on Charcot joints, 601, 611
discussion on benign exostoses, 504
on bone surgery, 611
Crile, George W., special consideration of toxic adenoma in relation to exophthalmic goiter, 637
discussion on amputation neuromas, 271
on acute and chronic empyema, 222
on cancer of the breast, 331
on toxic goiter, 686
on ulcer of posterior wall of stomach, 358
Cysts, branchiogenetic, relationship between ranula and, 417

D

Davis, John Staige, radical treatment of roentgen-ray burns, 272
Davis, Lincoln, the Morelli method of aspiration drainage for acute empyema 189
Dead bone, recognition of, based on pathological and *x*-ray studies, 574
Deaver, John B., one year's work (1919) in hysterectomy in the Lankenau (formerly the German) Hospital, Philadelphia, 626, 635
discussion on toxic goiter, 681
Diaphragmatic hernia, 614

Dislocations, old, of the hip, reduction by open incision, 547
Diverticula of the esophagus, 334
Drainage, aspiration, for acute empyema, the Morelli method of, 188
Dunham, E. K., discussion on acute and chronic empyema, 221

E

Eliot, Ellsworth, etiology, pathology and clinical features of benign exostoses, 500, 505
discussion on surgery of the intestines, 398
Empyema, acute, the Morelli method of aspiration drainage for, 188
acute and chronic, discussion on, 220
chronic, etiology of, 162
treatment of, 36, 204, 228
observations on, 63
in young adults, operation for, 156
syllabus of operative treatment of, 199
Esophagus, diverticula of, 334
Exostoses, benign, etiology, pathology and clinical features of, 500

F

Fat necrosis, traumatic, of the female breast, and its differentiation from carcinoma, 294
Finney, J. M. T., discussion on surgery of the intestines, 401
on ulcer of posterior wall of stomach, 357
Freeman, Leonard, "tourniquet operation" in toxic and other goiters, 642
discussion on operation for large ventral herniæ, 290
on toxic goiter, 687

G

Gastro-enterostomy stomas, technical problems in the operation for disconnecting, 698
Gibbon, John H., discussion on acute and chronic empyema, 220
on cancer of the breast, 328
on toxic goiter, 685
Gibson, Charles L., operation for cure of large ventral herniæ, 278, 293
discussion on pernicious anemia, 463
on postoperative pulmonary thrombosis, 495
Goiter, clinical study of 139 cases, 671
exophthalmic and hyperthyroidism, operations for adenoma with, 662
relation of toxic adenoma to, 637
toxic, 658
Goiters, "tourniquet operation" in toxic and other, 642

H

Halstead, Albert E., discussion on diverticula of the esophagus, 346
Hamann, Carl A., discussion on bone surgery, 610
on surgery of the intestines, 398
Harris, M. L., discussion on toxic goiter, 683
Hernia, diaphragmatic, 614
large ventral, operation for cure of, 278, 293
Heuer, George J., observations on the treatment of chronic empyema, 204
Hip, reduction of old dislocations of, by open incision, 547
Huber, G. Carl, and Lewis, Dean, amputation neuromas, their development and prevention, 231
Hyperthyroidism and exophthalmic goiter, operations for adenoma with, 662
Hysterectomy, one year's (1919) work in, at Lankenau Hospital, 626

I

Intestinal obstruction, acute, the cause of the continued high mortality and how it may be reduced, 377
Intestine (left-sided colon), failure of primary rotation of, in relation to intestinal obstruction, 368
small, hyperplastic tuberculosis of, 360

J

Jackson, Jabez N., requirement of technic in operations for cancer of the breast, 314, 332
Joints, Charcot, 601
Joint injuries, indications for active immediate mobilization in the treatment of, 694
Jopson, John H., discussion on diaphragmatic hernia, 624
Judd, E. S., results of operations for adenoma with hyperthyroidism and exophthalmic goiter, 662

L

Law, Arthur Ayer, adventitious ligaments simulating cervical ribs, 566
discussion on operation for large ventral herniæ, 290
Lee, Burton J., and Adair, Frank E., traumatic, fat necrosis of the female breast and its differentiation from carcinoma, 294, 332
Lewis, Dean, and Huber, G. Carl, amputation neuromas, their development and prevention, 231, 271
Lockwood, A. L., discussion on acute and chronic empyema, 224

Lilienthal, Howard, a syllabus of operative treatment of empyema, 199
discussion on acute and chronic empyema, 226
on surgery of the intestines, 398
Lund, Fred B., discussion on appendicitis, 416
on cancer of the breast, 329

M

McArthur, L. L., discussion on cancer of the breast, 330
on surgery of the intestines, 386
on toxic goiter, 685
MacLaren, Archibald, causes of death after operation for acute appendicitis, 405
Martin, Walton, etiology of chronic empyema, 162
discussion on acute and chronic empyema, 227
Mathews, Frank S., and Imboden, H. M., diaphragmatic hernia, 614, 625
Mesenteric thrombosis, with a report of six cases, 385
Mayo, Charles H., adenoma with hyperthyroidism, 648
discussion on diverticula of the esophagus, 347
on hysterectomy, 635
on pulmonary thrombosis, 497
on toxic goiter, 687
on ulcer of posterior wall of stomach, 359
Mayo, W. J., calloused ulcer of the posterior wall of the stomach, 348
Mitchell, James E., discussion on diaphragmatic hernia, 623
Mixter, Samuel J., discussion on cancer of the breast, 328
Morelli method of aspiration drainage for acute empyema, 189
Moschcowitz, Alexis V., discussion on acute and chronic empyema, 222
on toxic goiter, 683

N

Necrology, report of the committee on, xli
Nerve, facial, restoration of function of, five years after anastomosis with hypoglossal, 228
Neuromas, amputation, their development and prevention, 231

O

Obituaries:
Francis T. Stewart, xliii
Kenneth Alexander James Mackenzie, xliv
Charles Knox Cole, xlv
Obstruction, acute intestinal; the cause of the continued high mortality in, and how it may be reduced, 377
intestinal, failure of primary rotation of the intestine (left-sided colon) in relation to, 368

Ochsner, Albert J., and Schneider, Chester C., fatal postoperative pulmonary thrombosis, 464, 498
discussion on bone surgery, 611
on cancer of the ovary, 451
on surgery of the intestines, 386
on toxic goiter, 682
on transfusion in pernicious anemia, 463
Original contributions of America to medical sciences, 690
Ovary, cancer of, with invasion of sigmoid flexure, 435

P

Peck, Charles H., discussion on cancer of the breast, 330
on mesenteric thrombosis, 400
on surgery of the intestines, 400
Percy, Nelson Mortimer, blood transfusion in association with other surgical procedures in the treatment of pernicious anemia, 451, 463
Phemister, Dallas B., recognition of dead bone, based on pathological and *x*-ray studies, 574
discussion on bone surgery, 612
Porter, Charles A., discussion on toxic goiter, 681, 684
Porter, Miles F., goiter, a clinical study of 139 cases, 671
discussion on cancer of the breast, 331
on operation for large ventral herniæ, 291
on pulmonary thrombosis, 497
on toxic goiter, 688
Presidential address, 1
Primrose, Alexander, discussion on cancer of the breast, 332
on ulcer of posterior wall of stomach, 358
Pulmonary thrombosis, fatal postoperative, 464

R

Ransohoff, Joseph, hyperplastic tuberculosis of the small intestine, 360
discussion on acute and chronic empyema, 226
on hysterectomy, 635
Ranula and branchiogenetic cysts, relationship between, 417
Record of service during the World War of members of the American Surgical Association, 16
Report of Committee on Necrology, xli
Roentgen-ray burns, radical treatment of, 272
Ross, George G., mesenteric thrombosis, with a report of six cases, 385, 404
Rixford, Emmet, failure of primary rotation of the intestine (left-sided colon) in relation to intestinal obstruction, 368
discussion on surgery of the intestines, 402
Rupture, spontaneous, of deep epigastric artery, 229

S

SARCOMA of the clavicle, end-results following total excision, 506
Sherman, Harry M., discussion on bone surgery, 612
Souchon, Edmond, original contributions of America to medical sciences, 690
Stomach, calloused ulcer of the posterior wall of, 348
Stomas, gastro-enterostomy, technical problems in the operation for disconnecting, 698
Summers, John E., acute intestinal obstruction: the cause of the continued high mortality and how it may be reduced, 377, 403

T

TERRY, WALLACE I., toxic goiter, 658
Thompson, James E., relationship between ranula and branchiogenetic cysts, 417
discussion on surgery of the intestines, 397
Thrombosis, mesenteric: with a report of six cases, 385
pulmonary, fatal postoperative, 464
Transfusion, blood, and other surgical procedures in pernicious anemia, 451
Truesdale, P. E., cancer of the ovary, with invasion of sigmoid flexure, 435
Tuberculosis, hyperplastic, of the small intestine, 360
Tuffier, Th., treatment of chronic empyema, 36
discussion on acute and chronic empyema, 227
on operation for large ventral herniæ, 292

U

ULCER, calloused, of the posterior wall of the stomach, 348

V

VENTRAL hernia, large, operation for cure of, 278

W

WILLEMS, COLONEL CH., indications for active immediate mobilization in the treatment of joint injuries, 694
War, World, record of service of members of the American Surgical Association during the, 16

Y

YATES, JOHN L., discussion on pulmonary thrombosis, 497
on acute and chronic empyema, 223